

Case Report

Diaphragmatic rupture precipitated by intercostal chest tube drainage in a patient of blunt thoraco-abdominal trauma

Ashok Kumar Mehrotra, Asif Feroz, Sachet Dawar, Prem Kumar, Anupam Singh, Trilok Kumar Khublani

Department of Respiratory Medicine and Tuberculosis, NIMS Medical College, Jaipur, Rajasthan, India

ABSTRACT

Blunt thoraco-abdominal trauma in collision injuries in road traffic accident (RTA) occasionally results in diaphragmatic injury and rupture besides other serious multisystem injuries. These diaphragmatic injuries (DI) frequently go undetected specially when occur on the right side. DI associated with hemothorax need insertion of intercostal tube drainage (ICTD). ICTD has never been reported to precipitate diaphragmatic rupture and hernia. We are reporting such a rare case for the first time in medical literature.

KEY WORDS: Blunt thoraco-abdominal trauma, diaphragmatic rupture, hemothorax, intercostal chest tube drainage, road traffic accident

Address for correspondence: Dr. Ashok Kumar Mehrotra, 111/199 Vijay Path, Mansarovar, Jaipur - 302 020, Rajasthan, India. E-mail: mehash49@yahoo.co.in

INTRODUCTION

Traumatic diaphragmatic rupture (TDR) is known to occur as a consequence of blunt trauma in an RTA. TDR is an uncommon injury and poses a challenge to diagnose. TDR often go undetected in the acute phase, especially when it occurs on the right side, due to the management of other life threatening injuries. Right-sided TDR is less common than the left side. Hemothorax is a frequent accompaniment of diaphragmatic injury requiring ICTD insertion. ICTD has never before implicated in the precipitation of diaphragmatic rupture and hernia.

We are reporting a case of diaphragmatic rupture on right side precipitated by insertion of ICTD. We believe this to be the first case report of its kind in the medical literature.

CASE REPORT

A victim of road traffic accident was admitted to the Emergency department as a case of suspected head injury

with multiple bodily injuries in conscious but irritable state. At the time of admission his general parameters recorded were; blood pressure (BP); 130/70 mmHg, pulse; 78 per minute and regular, respiratory rate (RR); 12 per minute and regular, and pupils; semi-dilated, equal and reacting to light. There were no signs of respiratory distress, hemodynamic instability or GI discomfort. On examination, the respiratory system examination revealed that chest movements were reduced on the right lower chest with reduced air entry and bilateral occasional rhonchi.

Routine laboratory blood tests were within the normal range except, marginally raised serum glutamic oxaloacetic transaminase (SGOT) and serum glutamic pyruvic transaminase (SGPT). His hemoglobin percentage (Hb%) was 11.8 grams%. He was non-reactive to HIV and HBsAg.

The initial chest X-ray PA view [Figure 1] showed a homogeneous opacity in right lower chest and the right diaphragm was not clearly delineated. Ultrasonography

This is an open access article distributed under the terms of the Creative Commons Attribution-NonCommercial-ShareAlike 3.0 License, which allows others to remix, tweak, and build upon the work non-commercially, as long as the author is credited and the new creations are licensed under the identical terms.

For reprints contact: reprints@medknow.com

How to cite this article: Mehrotra AK, Feroz A, Dawar S, Kumar P, Singh A, Khublani TK. Diaphragmatic rupture precipitated by intercostal chest tube drainage in a patient of blunt thoraco-abdominal trauma. Lung India 2016;33:85-7.

Access this article online	
Quick Response Code: 	Website: www.lungindia.com
	DOI: 10.4103/0970-2113.173073

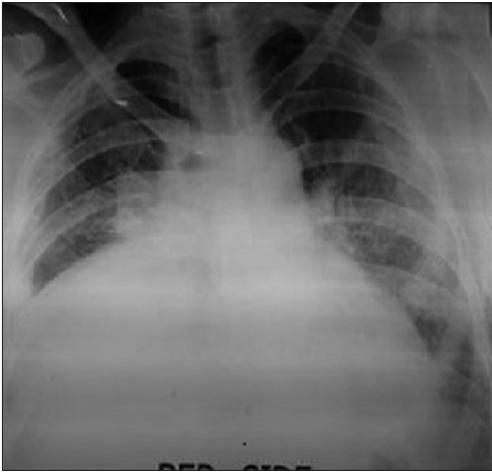


Figure 1: Chest X-ray PA view; on the day of admission, showing homogeneous opacity right mid and lower chest

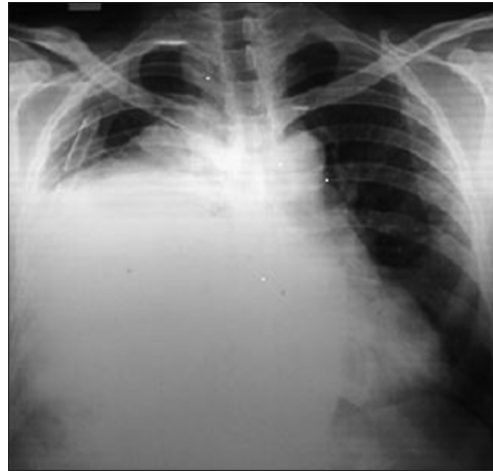


Figure 2: Chest X-ray PA view; Post-ICD day-1, showing ICD *in situ* with soft tissue density with concave margins left side in para-cardiac region extending from the abdomen into thoracic cavity

(USG) revealed fluid in the right pleural cavity and no abnormal finding in the liver or other viscera and abdominal cavity. Diagnostic pleural aspiration drained blood. ICTD drained about 200 ml of blood and became non-functional. The patient remained asymptomatic, hemodynamically stable without any respiratory or abdominal distress. Routine follow-up X-ray chest on the next day of ICTD, showed well-circumscribed soft tissue opacity with a clear-cut circular margin across the midline chest extending high up in right thorax [Figure 2]. Computerized tomogram of thorax (CT thorax) in axial view revealed high raised right diaphragm. Coronal reconstitution revealed a mid and posterior laceration of the right dome of the diaphragm with herniation of the liver, gallbladder, omentum and a segment of hepatic flexure in the right thoracic cavity with the mild superior migration of the right kidney. The ICTD was seen passing by the side of right lobe of herniated liver, reaching high in the right thoracic cavity and capsular laceration of posterior segment of right lobe of liver but no hemoperitoneum. A contrast study revealed thickened and enhancing anterior end of ruptured diaphragm and ruptured posterior leaf falling posteriorly. The patient underwent laparotomy and the CT findings were confirmed during surgery. The hernia was reduced and diaphragm repaired through abdominal route. The patient had an uneventful recovery and discharged from the surgery department after about 3 weeks of hospital stay.

DISCUSSION

Traumatic diaphragmatic rupture is an uncommon, difficult to diagnose and potentially a life-threatening injury. 0.8-5% of diaphragmatic injuries develops into diaphragmatic rupture.^[1] Blunt thoraco-abdominal trauma accounts for 74% of all diaphragmatic hernias.^[2] Most TDRs occur on the left side. Right-sided ruptures are rare due to the protective effect of the liver or the strength of the right dome of the diaphragm.^[2]

Mostly TDR presents with non-specific and vague symptoms at the time of trauma either alone or in association with symptoms related to other organ injuries. The diagnosis may be missed in the acute phase in about 30% of the cases^[3] due to management of associated serious injuries. Blunt thoraco-abdominal trauma leads to an abrupt rise in intra-abdominal pressure, resulting in stretching and rupture of the diaphragmatic muscles.^[2] Sirbu *et al.* has observed the ruptured diaphragmatic muscles may continue to provide a barrier across the two cavities until necrosis develop in devitalized muscles through which herniation of abdominal viscera occur and the symptoms are produced when obstruction occur in the incarcerated viscera.^[4] Hemothorax and or hemoperitoneum may be occasionally associated with diaphragmatic injury. Thoracostomy is the standard of care for the management of hemothorax. Thoracostomy and ICTD insertion has never before reported to precipitate diaphragmatic rupture and hernia.

In the present case diaphragmatic rupture and hernia developed immediately after the ICTD insertion without giving time for the necrosis to develop in the injured muscles. The rupture was suspected during a routine, day-one follow-up in X-ray, while the patient had absolutely no symptoms. The hernia was subsequently confirmed by USG and CT thorax [Figure 3]. We hypothesize that the collected blood in the pleural cavity maintained near normal trans-diaphragmatic pressure gradient that kept the continuity of the traumatized diaphragm. Abrupt restoration of or even creation of further negative intrapleural pressure following the ICTD insertion resulted in precipitation of DR and hernia. Meyers and McCabe (1993) were also of the opinion that the negative intrapleural pressure can be made more negative by thoracostomy tube suction.^[5] Taheri and Stern (2012) has suggested that abrupt alteration in trans-diaphragmatic pressure gradient can transform an asymptomatic rupture into a symptomatic hernia.^[6]

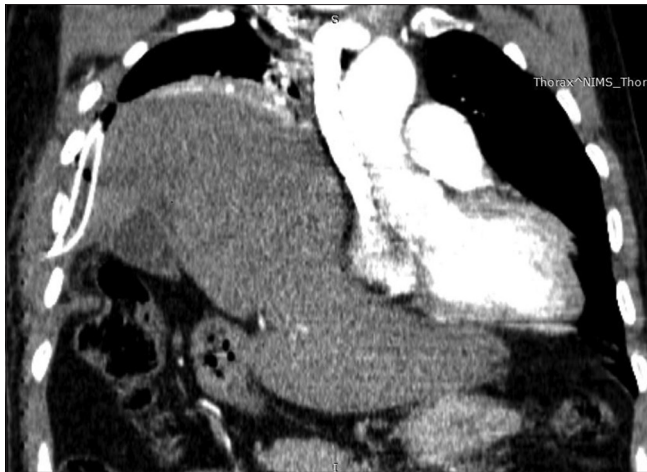

Figure 3: Coronal transformation of CT thorax, showing anterior part of ruptured leaf of the diaphragm with ICTD *in situ*, right lobe of liver, omentum, gall bladder, a segment of hepatic flexure herniating into the thoracic cavity through the vent in the diaphragm with capsular breach of the posterior part of the right lobe of liver, and collapsed lower lobe of the right lung

We presume that, had the ICTD not been attempted, the injured muscle might have continued to maintain normal trans-diaphragmatic pressure gradients and a barrier across the two cavities. There could have been a chance of natural repair by healing. This also explains why only a some cases of TDR develop hernia while others escape, as observed by Kozac *et al.*^[7]

To the best of our knowledge this mechanism of development of diaphragmatic rupture and hernia has never been reported in medical literature. We believe this to be the first case of asymptomatic progression to diaphragmatic rupture precipitated by ICTD, in the World medical literature.

Financial support and sponsorship

Nil.

Conflicts of interest

There are no conflicts of interest.

REFERENCES

1. Rossetti G, Bruscianno L, Maffetone V, Napolitano V, Sciaudone G, Del Genio G, *et al.* Giant right post-traumatic diaphragmatic hernia: Laparoscopic repair without a mesh. *Chir Ital* 2005;57:243-6.
2. Kuppusamy A, Ramanathan G, Gurusamy J, Ramamoorthy B, Parasakthi K. Delayed diagnosis of traumatic diaphragmatic rupture with herniation of the liver: A case report. *Ulus Travma Acil Cerrahi Derg* 2012;18:175-7.
3. Pappas-Gogos G, Karfis E, Kakadellis J, Tsimoyiannis EC. Intrathoracic cancer of the splenic flexure. *Hernia* 2007;11:257-9.
4. Sirbu H, Busch T, Spillner J, Schachtrupp A, Autschbach R. Late bilateral diaphragmatic rupture: Challenging diagnostic and surgical repair. *Hernia* 2005;9:90-2.
5. Meyers BF, McCabe CJ. Traumatic diaphragmatic hernia. Occult marker of serious injury. *Ann Surg* 1999;218:783-90.
6. Taheri MR, Stern EJ. Delayed right diaphragmatic rupture because of positive pressure mechanical ventilation. *Current Problems in Diagnostic Radiology* 2012;41:133-5.
7. Kozak O, Mentis O, Harlak A, Yigit T, Kilbas Z, Aslan I, *et al.* Late presentation of blunt right diaphragmatic rupture (hepatic hernia). *Am J Emerg Med* 2008;638.e3-5.