

# Intraoral Burkitt's lymphoma in an HIV positive patient

Vidya Ajila, Gopakumar R.<sup>1</sup>, Shruthi Hegde, Subhas Babu G.

Department of Oral Medicine and Radiology, A B Shetty Memorial Institute of Dental Sciences, Nitte University, Deralakatte, Mangalore, <sup>1</sup>MAHE Institute of Dental Sciences and Hospital, Chalakkara, Pallor, Mahe, India

**Address for correspondence:**

Dr. Vidya Ajila, Department of Oral Medicine and Radiology, A B Shetty Memorial Institute of Dental Sciences, Nitte University, Deralakatte, Mangalore - 575 018, India. E-mail: ajila\_v@yahoo.com

**Abstract**

Burkitt's lymphoma is an aggressive form of Non-Hodgkin's lymphoma composed of malignant cells of B lymphocyte origin. Burkitt's lymphoma is a rarity in the Indian subcontinent. Though intraoral Burkitt's lymphoma in HIV positive individuals is very uncommon, its importance lies in the fact that it is often the first sign of the underlying immunosuppression. We present a case of Burkitt's lymphoma in right maxillary region which was the first manifestation of HIV in the patient.

**Key words:** Burkitt's lymphoma, HIV, maxilla

**INTRODUCTION**

Burkitt's lymphoma (BL) is a rare, extranodal malignancy of undifferentiated B lymphocytes commonly seen in children.<sup>[1]</sup> There are three clinical variants of BL: endemic BL, sporadic BL and HIV associated BL.<sup>[2,3]</sup> These clinical variants are similar histologically and identified partly by their geographic location.<sup>[2]</sup> Endemic BL is seen in children in Africa and Papua New Guinea as jaw or orbital masses; sporadic BL has no specific age or geographic predilection and occurs with abdominal or nodal involvement.<sup>[2]</sup> Immunodeficiency associated BL is seen in individuals with HIV.<sup>[2]</sup> Intraoral presentation of HIV associated Burkitt's lymphoma has been rarely reported.<sup>[3]</sup> We present to you a case of Burkitt's lymphoma of the posterior maxilla which was the first manifestation of HIV in the patient.

**CASE REPORT**

A 42-years-old male presented with a growth in the right maxillary molar region of 2 months duration. There was initial mobility of the tooth in that region for 3-4 months followed by exfoliation of the tooth. Subsequently, he noticed a growth emerging from the area of the exfoliated tooth which enlarged slowly and gradually. The medical and dental history of the patient was not significant. He was moderately built and nourished.

On extraoral examination, there was a diffuse swelling noticed over the right malar region which was non tender on palpation. Bilateral submandibular lymph nodes were palpable, mobile and non tender. There was no generalised lymphadenopathy.

On intraoral examination, there was a solitary, well defined, pedunculated growth in the right maxillary molar region which was predominantly blackish in appearance [Figure 1]. The growth was soft and friable in consistency. The buccal mucosa adjacent to the lesion was erythematous. Intraoral radiographs showed missing maxillary right second molar with bone loss extending beyond the tooth

Access this article online	
Quick Response Code: 	Website: www.ijstd.org
	DOI: 10.4103/0253-7184.102126

**How to cite this article:**

Ajila V, Gopakumar R, Hegde S, GS. Intraoral Burkitt's lymphoma in an HIV positive patient. Indian J Sex Transm Dis 2012;33:118-20.

socket till the floor of the right maxillary sinus. Panoramic radiography showed soft tissue shadow distal to the right maxillary first molar with break in the continuity of the antral floor in the same region [Figure 2, area encircled in black]. Blood investigations detected leucopenia with a total count of 3,500/cmm. Further investigations revealed that he was HIV positive. Histopathological analysis of the lesion showed sheets of round cells with vesicular nuclei and indistinct cytoplasm interspersed with lymphocytes with condensed nuclei. Few macrophages were seen between the tumour cells [Figure 3]. These features were suggestive of Burkitt's lymphoma. Bone marrow aspirate was positive for malignant infiltrate. Unfortunately, due to certain logistical and financial reasons the patient did not report back to us and was subsequently lost to follow up.

## DISCUSSION

Human immunodeficiency virus (HIV) infection has been associated with a 60 fold increased risk of Non Hodgkin lymphoma (NHL).<sup>[4]</sup> NHL forms around one third of AIDS-related malignancies with Burkitt's Lymphoma accounting for 2.4-20% of HIV-associated NHL.<sup>[5]</sup>

Burkitt's Lymphoma (BL) was originally described by Dr Denis Burkitt in 1958 as a sarcoma of the jaw in children in endemic areas of equatorial East Africa.<sup>[1]</sup> Later on, sporadic cases were reported from Europe and America which were histologically and immunophenotypically identical and these were known as nonendemic or North American Burkitt's lymphoma.<sup>[1]</sup> The differences between the adult and pediatric variants are summarised in Table 1. The third type known as immunodeficiency associated BL, usually seen in association with human immunodeficiency virus (HIV) infection, is clinically similar to the sporadic cases but with higher incidence of lymph node and bone marrow involvement.<sup>[6]</sup> In an Indian series of solid malignant tumours, Burkitt's lymphoma had an incidence of 0.76%.<sup>[7]</sup> Burkitt's lymphoma has the highest proliferation rate of any human neoplasm, with a potential doubling time of 24 hours and a growth fraction of nearly 100%.<sup>[4,8]</sup>

The pathogenesis of BL is due to the c-myc immunoglobulin (Ig) translocation and is thought to occur as a result of an error in activation induced cytidine deaminase (AID)-mediated Ig class switch recombination in germinal centers.<sup>[2]</sup> The most common translocation in BL is the t (8;14) in which there is fusion of cMYC to the immunoglobulin (Ig)H locus.<sup>[6]</sup>

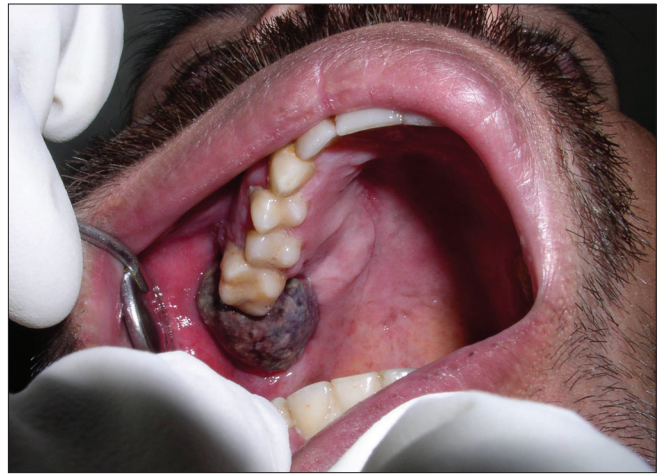

Figure 1: Clinical image showing growth in right maxillary posterior region

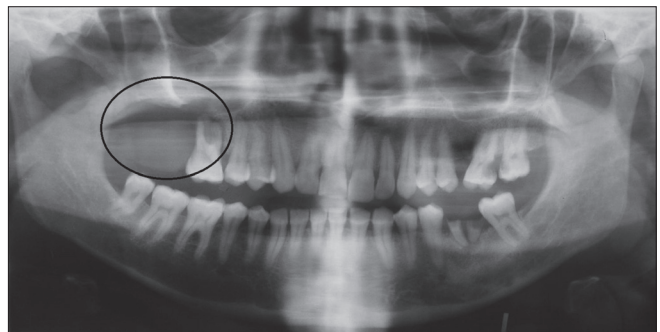


Figure 2: Panoramic radiograph showing break in continuity of antral floor, ill defined radiolucency and soft tissue shadow (encircled in black)

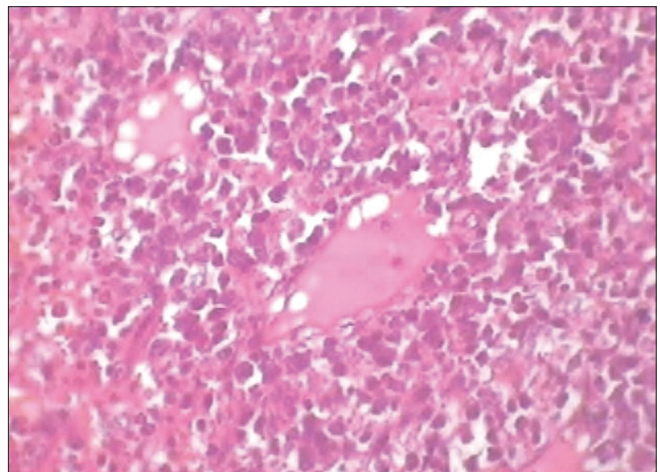


Figure 3: Photomicrograph (H and E, X 10) showing sheets of round cells with vesicular nuclei and indistinct cytoplasm interspersed with lymphocytes and macrophages

Jaw involvement is seen in approximately 60% of cases in endemic BL, while it occurs in only 15-18% of nonendemic BL.<sup>[1]</sup> The earliest clinical sign of intraoral BL is loosening and exfoliation of the teeth as the tumour enlarges.<sup>[7]</sup> We also observed similar features. In jaw lesions, the tumor can cause toothache, tooth mobility, tooth displacement,

**Table 1: Differences in adult and pediatric presentation:[7,9,10]**

	Adult	Pediatric	HIV Related
Type	American/Sporadic	African/endemic	American/Sporadic
Age of occurrence	Older individuals Mean age 11 years	3-8 yrs	Older individuals
Male: Female ratio	No gender predilection	2:1	No gender predilection
Site of occurrence	Abdomen, Bone marrow involvement	Facial bone involvement-maxilla and mandible	Lymph nodes, Bone marrow-30% cases only.
Prognosis	Inferior outcomes compared to younger patients. Overall Survival at 3 years-89%.	Survival rates exceeding 90%	Lower survival rate : 40%

intraoral and extraoral swelling, and perioral paresthesia.<sup>[6]</sup>

The differential diagnosis usually includes the following conditions: Periapical lesions, ameloblastoma, other non-Hodgkin's lymphomas, undifferentiated carcinomas and sarcomas, and leukemia.<sup>[6]</sup>

Radiographic findings in Burkitt's lymphoma include radiolucent images of bone destruction with poorly defined and irregular margins.<sup>[7,8]</sup> In children, the tumor can cause generalized destruction of the tooth crypts with loss of lamina dura and loss of trabecular pattern in the mandible and maxilla.<sup>[1]</sup> In our case, there was ill defined radiolucency of the alveolar bone posterior to the first molar tooth.

Histologically, classic BL presents with monotonous, intermediate sized neoplastic cells with round nuclei and multiple peripheral nuclei with scant cytoplasm and clear vacuoles.<sup>[6]</sup> Mitotic figures are abundant with numerous interspersed tingible body macrophages phagocytosing abundant apoptotic debris, thus creating the starry-sky pattern.<sup>[4,6]</sup>

Burkitt's lymphoma is treated preferentially with intensive chemotherapy; 5-year survival rates range between 75 and 95%, depending on the stage of the lesion at the time of diagnosis.<sup>[6]</sup> New chemotherapeutic agents such as daunorubicine, arabinoside-C, tioguanide and hydroxyurea have been added to the classical treatment scheme.<sup>[9]</sup> Surgical debulking is of benefit in large localised jaw or abdominal tumours.<sup>[7]</sup>

Prognosis improves with younger age of diagnosis, minimal tumour burden and prompt initiation of chemotherapy.<sup>[6]</sup> Relapse occurs in two third cases, usually with advanced stages.<sup>[7]</sup>

Orofacial manifestation of BL in HIV-infected individuals is very uncommon. It has been highlighted that BL in an HIV-infected person may

be one of the first clinical findings.<sup>[3]</sup> In our case also, the oral manifestation of BL was the first manifestation of HIV.

Thus, HIV positive patients present with a variety of clinical manifestations. The diagnosis of Burkitt's lymphoma in an otherwise healthy appearing individual should raise suspicion of underlying immunosuppression and appropriate investigations for HIV must be undertaken.

## REFERENCES

1. Svoboda WE, Aaron GR, Albano EA. North American Burkitt's lymphoma presenting with intraoral symptoms. *Pediatr Dent* 1991;13:52-8.
2. Guech-Ongey M, Simard EP, Anderson WF, Engels EA, Bhatia K, Devesa SS, et al. AIDS-related Burkitt lymphoma in the United States: what do age and CD4 lymphocyte patterns tell us about etiology and/or biology? *Blood* 2010;116:5600-4.
3. Chen YK, Tsu HR, Lin YJ, Lin LM. Intra-oral HIV-associated Burkitt's lymphoma with mandible involvement. *Oral Oncology Extra* 2005; 41:249-52.
4. Ojha J, Gupta A, Aziz N. Intraoral diffuse large B-cell lymphoma with Burkitt-like morphology in an HIV-positive patient--a diagnostic dilemma. *J Oral Maxillofac Surg* 2010;68:2632-8.
5. Rodrigo JA, Hicks LK, Cheung MC, Song KW, Ezzat H, Leger CS, et al. HIV-Associated Burkitt Lymphoma: Good Efficacy and Tolerance of Intensive Chemotherapy Including CODOX-M/IVAC with or without Rituximab in the HAART Era. *Adv Hematol* 2012;2012:735392.
6. Balasubramaniam R, Goradia A, Turner LN, Stoopler ET, Alawi F, Frank DM, et al. Burkitt lymphoma of the oral cavity: an atypical presentation. *Oral Surg Oral Med Oral Pathol Oral Radiol Endod* 2009;107:240-5.
7. Patil K, Mahima VG, Jayanth BS, Ambika L. Burkitt's lymphoma in an Indian girl: a case report. *J Indian Soc Pedod Prev Dent* 2007;25:194-9.
8. Freitas Rde A, Veras Barros SS, Quinderé LB. Oral Burkitt's lymphoma--case report. *Braz J Otorhinolaryngol* 2008;74:458-61.
9. Valenzuela-Salas B, Dean-Ferrer A, Alamillos-Granados FJ. Burkitt's lymphoma: a child's case presenting in the maxilla. Clinical and radiological aspects. *Med Oral Patol Oral Cir Bucal* 2010;15:e479-82.
10. Perkins AS, Friedberg JW. Burkitt lymphoma in adults. *Hematology Am Soc Hematol Educ Program* 2008;:341-8.

Source of Support: Nil. Conflict of Interest: None declared.