

Giant Sigmoid Diverticulum: A Rare Presentation of a Common Pathology

A. Guarnieri^a M. Cesaretti^a A. Tirone^a N. Francioli^a
A. Piccolomini^a G. Vuolo^b L. Verre^a V. Savelli^a
L. Di Cosmo^b A.F. Carli^a

^aU.O.C. Chirurgia 2 and ^bU.O. Nutrizione Artificiale, AOU Senese, Siena, Italy

Key Words

Giant sigmoid diverticulum · Colon surgery · Diverticular disease

Abstract

Although colonic diverticulum is a common disease, affecting about 35% of patients above the age of 60, giant sigmoid diverticulum is an uncommon variant of which only relatively few cases have been described in the literature. We report on our experience with a patient affected by giant sigmoid diverticulum who was treated with diverticulectomy. Resection of the diverticulum is a safe surgical procedure, provided that the colon section close to the lesion presents no sign of flogosis or diverticula; in addition, recurrences are not reported after 6-year follow-up.

Introduction

Diverticulosis of the colon is a common clinical entity that occurs in 30–35% of the general population, especially in people older than 60 years. Diverticula are sacs that push out from the colon walls. The disease is usually limited to the sigmoid colon, with less than 1 to 2 cm in diameter. Rarely do sigmoid diverticula enlarge to such a degree that they are termed ‘giant sigmoid diverticula’; in fact, only 113 cases of giant colonic diverticula have been reported in the literature [1]. Management of the condition is various (ranging from conservative treatment to resection) but recommended because of a high rate of complications. We report the case of a patient seen at our institution for giant sigmoid diverticulum who underwent left hemicolectomy.

Case Report

A 76-year-old man presented with a 1-month history of left lower abdominal pain of increasing intensity associated with alternating diarrhea and constipation and hypocolic stools; the patient also reported asthenia and tiredness. He denied any previous history of abdominal distress. Past medical history revealed an AR type myelodysplasia, monoclonal gammopathy. The patient had a cardiac pacemaker. Physical examination was normal, showing no signs of peritonitis or palpable mass, except for a mild abdominal tenderness in the left lower quadrant. Blood tests were normal apart from a hypochromic anemia (hemoglobin 10 g/dl) and the already diagnosed monoclonal gammopathy. Hemocult test was positive for hematochezia; tumor marker levels were normal. Colonoscopy showed a weakness in the colon wall through which a 10 × 10 cm cavity came out on the right side of the mid-sigmoid colon that was covered with mucus-purulent tissue. There was also evidence of diverticular disease throughout the left colon. In order to exclude perforation, gastrografin enema was performed which showed a 10 × 11 cm sac arising from the middle portion of the sigmoid colon and confirmed diverticular disease, but no evidence of intraperitoneal soiling ([fig. 1](#)). The patient underwent surgical treatment through a xifo-pubic median laparotomic access. A giant diverticulum developed from the antimesenteric side of the sigmoid colon and adherent to the upper wall of the proximal jejunum and to the transverse mesocolon. Because of the presence of diverticular disease in the left colon, we performed a left hemicolectomy with an end-to-end colorectal anastomosis.

Histology showed chronic inflammatory disease of the entire wall of the diverticulum, with ulcers and white cells, predominantly neutrophils. The postoperative period was uneventful and the patient was discharged on day 9.

Discussion

Giant colonic diverticulum is a rare condition related to diverticular disease; the first literature description by Bovin and Bonte dates back to 1946, while the first radiological diagnosis had been reported in 1953 by Hughes and Greene [2, 3].

Colonic diverticulum is a pseudodiverticulum because it is an outpouching of mucosa and submucosa of the bowel wall usually situated in the sigmoid colon (95% of cases) [5].

McNutt et al. divide giant diverticula into 3 types, based on their ethiological origin [6]. Type 1 (pseudodiverticulum) arises gradually, without perforation, and its wall consists of chronic granulation tissue [7, 8]. Type 2 (inflammatory diverticulum) is secondary to a perforation of the mucosa and submucosa which leads to a walled-off abscess cavity that communicates with lumen, allowing diverticulum to enlarge. In fact, the communication acts as a one-way valve. Another theory of this enlargement is secondary to gas-forming bacteria [9]. It is lined by fibrous scar tissue without intestinal layer [10]. Type 3 (true diverticulum) consists of all 4 layers of the bowel wall.

Choong and Frizelle suggest a new classification based on the histology of disease [4], and divide colonic diverticula into 2 types. Type 1 is a pseudodiverticulum whose wall consists of fibrous tissue without the presence of a muscle layer (87%) [11], and it is related to diverticular disease. Type 2 is a true diverticulum, and it is a congenital pediatric condition [12].

Diverticula incidence occurs in patients aged 32–90 years, with a maximum incidence in subjects over 70 years [13]. Common symptoms include vague abdominal pain [14] and abdominal mass [6] (71%); some patients present with diarrhea, constipation, fever, nausea and vomiting or rectal bleeding [14, 15]. Complications of giant sigmoid diverticulum (15–35%) are peritonitis, secondary to perforation, or abscess and volvulus [15].

Our case, as shown by histological findings, is a giant pseudodiverticulum (type 1, according to Choong and Frizelle [4]). The patient presented with abdominal pain, alternating diarrhea, constipation and asthenia, specific symptoms which could also be related to a colonic neoplasm. Instrumental investigations, such as gastrografin enema and colonoscopy, have contributed to the differentiation of diverticular disease from neoplastic process.

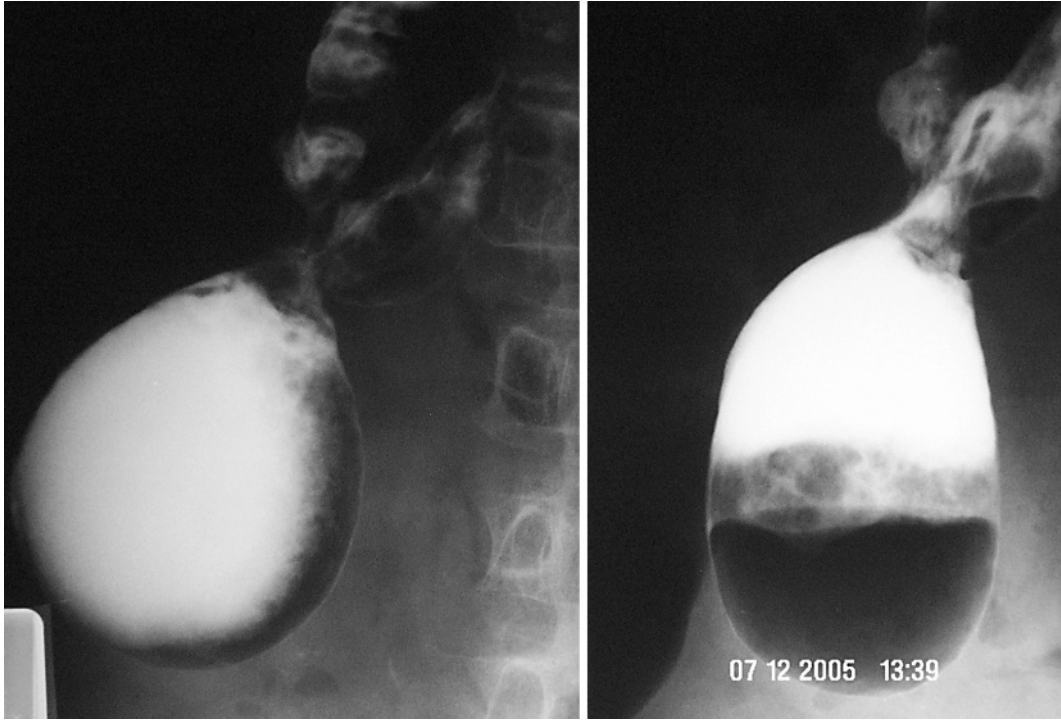
The aim of treatment is to alleviate symptoms and prevent complications, so surgical procedure is the most common performed treatment. Hemicolectomy should be performed when we find a type 1 Choong diverticula because it reduces the recurrences and the most common diverticular complications [4]. Type 2 treatment could be diverticulectomy, because the condition is congenital and usually consists of a single lesion. However, it must be considered that maximum incidence of this disease is in patients 40–50 years old, so it might possibly be an associated diverticular disease, and during surgery, congenital type and type 1 diverticula are not easy to differentiate.

We performed a left hemicolectomy that allowed us to prevent diverticular disease complications and to reduce the risk of recurrence of diverticula. Our patient underwent a laparotomic access because of the presence of adhesions to the upper wall of the proximal jejunum and the transverse mesocolon, and because of his history of heart disease.

Conclusion

Giant sigmoid diverticulum is a rare complication of sigmoid diverticulosis with high risk of complications and a variable clinical presentation. The diagnosis is confirmed by radiological investigations, especially gastrografin enema. The gold standard treatment is surgery, based on symptoms, presence of complications and concomitant diverticular disease. It consists of excision of the giant diverticulum with segmental resection of adjoining colon and primary anastomosis whenever possible.

Fig. 1. Double-contrast enema. A giant diverticulum arising from the mid-sigmoid colon.



References

- 1 Chaiyasate K, Yavuzer R, Mittal V: Giant sigmoid diverticulum. *Surgery* 2006;139:276–277.
- 2 Bonvin P, Bonte G: Diverticules géants du sigmoïde. *Arch Mal Dig Mal Nutr* 1946;35:353.
- 3 Hughes WL, Greene RC: Solitary air cyst of peritoneal cavity. *Arch Surg* 1953;74:931–936.
- 4 Choong CK, Frizelle FA: Giant colonic diverticulum: report of four cases and review of the literature. *Dis Colon Rectum* 1998;41:1178–1186.
- 5 Wallers KJ: Giant diverticulum arising from the transverse colon of a patient with diverticulosis. *Br J Rad* 1981;54:683–688.
- 6 McNutt R, Schmitt D, Schulte W: Giant colonic diverticula – three distinct entities. Report of a case. *Dis Colon Rectum* 1988;31:624–628.
- 7 Gallagher JJ, Welch JP: Giant diverticular of the sigmoid colon: a review of differential diagnosis and operative management. *Arch Surg* 1979;114:1079–1083.
- 8 Kricun R, Stasik JJ, Reither RD, Dex WJ: Giant colonic diverticulum. *AJR Am J Roentgenol* 1980;135:507–512.
- 9 Muhletaler CA, Berger JL, Robinette CL Jr: Pathogenesis of giant colonic diverticula. *Gastrointest Radiol* 1981;6:217–222.
- 10 Saha SP, Roesch CB: A giant sigmoid diverticulum: report of a case. *Dis Colon Rectum* 1972;15:63–65.
- 11 Mehta DC, Baum JA, Dave PB, Gumaste VV: Giant sigmoid diverticulum: report of two cases and endoscopic recognition. *Am J Gastroenterol* 1996;91:1269–1271.
- 12 Ryckman FC, Glenn JD, Moazam F: Spontaneous perforation of a colonic duplication. *Dis Colon Rectum* 1983;26:287–289.
- 13 Roth T, Demartines N, Gavelli A, Huguet C: Les diverticules géants du colon. A propos de deux cas. *Chirurgie* 1999;124:307–312.
- 14 Scerpella PR, Budensteiner JA: Giant sigmoid diverticula. *Arch Surg* 1989;124:1244–1246.
- 15 Naber A, Sliutz AM, Freitas H: Giant diverticulum of the sigmoid colon. *Int J Colorectal Dis* 1995;10:169–172.