

Case Report

Combination antifungal therapy without craniotomy in an immunocompromised patient with rhino-orbito-cerebral mucormycosis: A case report

Mohammadreza Salehi (MD)¹
 Farhad Shahi (MD)²
 Fatema Sadaat Rizvi³
 Sara Ghaderkhani (MD)¹
 Hamed Zainaldain³
 Sadegh Khodavaissy (Ph.D)⁴
 Saeed Reza Jamali-Moghaddam (MD)⁵
 Seyed Ali Dehghan Manshadi (MD)^{1*}
 Omid Reza Hosseini (MD)^{1,6}

1. Imam Khomeini Complex Hospital, Department of Infectious Diseases, Tehran University of Medical Sciences, Tehran, Iran

2. Department of Adult Hematology and Oncology, Imam Khomeini Complex Hospital, Tehran University of Medical Sciences, Tehran, Iran

3. School of Medicine, Tehran University of Medical Sciences, Tehran, Iran

4. Department of Medical Mycology and Parasitology, School of Public Health, Tehran University of Medical Sciences, Tehran, Iran

5. Ziaei Hospital, Department of Infectious Diseases, Tehran University of Medical Sciences, Tehran, Iran

6. Viro-immunology Research Unit, Department of Infectious Diseases 8632, Rigshospitalet, University of Copenhagen, Copenhagen, Denmark

* Correspondence:

Seyed Ali Dehghan Manshadi,
 Department of Infectious Diseases,
 Imam Khomeini Complex Hospital,
 Keshavarz Blvd, Dr Gharib Street,
 Tehran, 1419733141, Iran

E-mail: sealdema@yahoo.com

Tel: 0098 2166581598

Fax: 0098 2166581598

Received: 4 Feb 2019

Revised: 26 May 2019

Accepted: 26 June 2019

Abstract

Background: Mucormycosis is an uncommon fungal infection caused by the members of the order Mucorales. In susceptible patients, mucormycosis can infect any tissue or organ, and without suitable treatment (i.e., debridement and antifungal therapy), this infection can be fatal. Our patient was a woman with lymphoma and cerebral mucormycosis who was treated with antifungals and without any neurosurgical debridement.

Case Presentation: Herein, we present the case of a 35-year-old woman with diagnosis of B-cell lymphoma and rhino-orbito-cerebral mucormycosis (ROCM). She was a candidate for enucleation of the left eye, orbital decompression, and sinocerebral debridement. Nevertheless, the patient refused eye enucleation and craniotomy. Finally, she was treated with a combination of antifungals and sinus debridement without eye enucleation and craniotomy.

Conclusion: Endoscopic debridement, along with a combination of liposomal amphotericin B (LAMB) and posaconazole, may be a suitable therapeutic option for patients with ROCM, who are not eligible candidates for extensive surgery or craniotomy.

Keywords: Mucormycosis, Invasive fungal infection, Combination drug therapies, Liposomal amphotericin B, Posaconazole

Citation:

Salehi MR, Shahi F, Rizvi FS, et al. Combination antifungal therapy without craniotomy in an immunocompromised patient with rhino-orbito-cerebral mucormycosis: A case report. *Caspian J Intern Med* 2020; 11(2): 227-230.

Mucormycosis is an uncommon fungal infection caused by the members of the order Mucorales (1, 2). Sporangiospores are ubiquitously found in decaying organic materials and soil. Mucormycosis mostly transmits to humans via inhalation of sporangiospores, and occasionally by traumatic inoculation (3). Mucorales may also be found in the air and water of healthcare settings and tongue depressors; they are also found in the nose and mouth of healthy individuals (4). The main risk factors for mucormycosis include immunosuppressive and chemotherapy agents, poorly controlled diabetes mellitus, hematologic malignancies (e.g., leukemia and lymphoma), hematopoietic stem cell or solid organ transplantation, and some other factors (1, 5). Although Mucorales can infect any tissue, rhino-orbito-cerebral mucormycosis (ROCM), cutaneous mucormycosis, and pulmonary mucormycosis are more commonly reported. The common presentations of ROCM include perinasal cellulitis, facial pain and paresthesias, headache, lethargy, visual loss, proptosis, and/or palatal ulcer (2, 6). The mortality rate of patients with ROCM, even with treatment, is more than 60% (5). Therefore, prompt debridement of necrotic tissues, systemic administration of antifungal agents, dose reduction of immunosuppressants, and control of underlying diseases can be life-saving (1). Lipid formulations of amphotericin B are the first-line antifungal agents for the treatment of ROCM.

However, there has been a growing interest in new azoles, such as posaconazole and isavuconazole in recent years. Most of our knowledge about the treatment of mucormycosis is based on the findings of case reports (5). Therefore, experiences and rare cases of this disease are worth reporting. Herein, we present a patient with ROCM, who was treated with a combination of antifungals, i.e., liposomal amphotericin B (LAMB) plus posaconazole, and sinus debridement without craniotomy. The aim of this case report was to demonstrate the clinical course of this patient and increase the current awareness of the efficiency of combination therapy for patients with ROCM, who refuse surgery.

Case presentation

The patient was a 35-year-old woman with a confirmed diagnosis of high-grade B-cell lymphoma under rituximab, cyclophosphamide, doxorubicin, vincristine, and prednisone (R-CHOP) and cyclophosphamide, vincristine, doxorubicin, high-dose methotrexate/ifosfamide, etoposide, and high-dose cytarabine (CODOX-M/IVAC) regimens. In the final phase of chemotherapy, an infectious disease consultation was requested because of fever (axillary temperature, 38.9°C) and neutropenia (absolute neutrophil count, 200 cell/mL).

On the physical examination, the patient's left eyelid was swollen and erythematous. She also had headaches and blurred vision (figure 1).

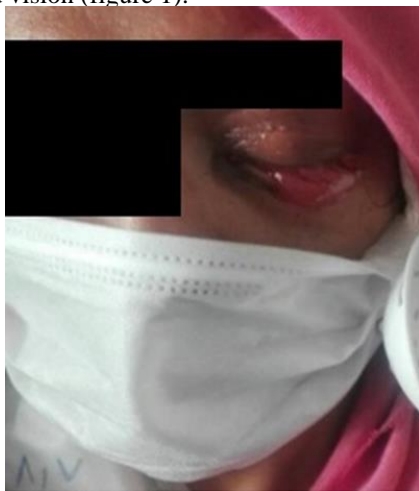

Figure 1. The swollen erythematous left eyelid

Since opportunistic infections were highly probable, chemotherapy was immediately stopped, and broad-spectrum antibiotics, including meropenem (2 g q8h), vancomycin (1 g

q12h), and LAMB (300 mg/daily), were prescribed. In addition, paranasal sinus (PNS) CT scan and brain magnetic resonance imaging (MRI) were requested. The PNS CT scan showed mucosal thickening in both maxillary sinuses (figure 2). The brain MRI images revealed an intracranial lesion (about 20×20 mm) in the left frontal cortex (MRI-T2 flair view) (figure 3). Her laboratory tests revealed C-reactive protein (CRP): +++, erythrocyte sedimentation rate (ESR): 83 mm/h, galactomannan: 0.3 and blood cultures: negative.

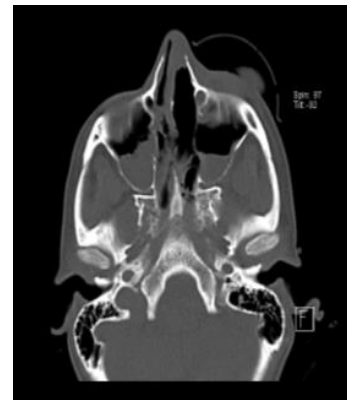

Figure 2. The PNS CT scan (axial view-without contrast) shows a mucosal thickening in both maxillary sinuses.

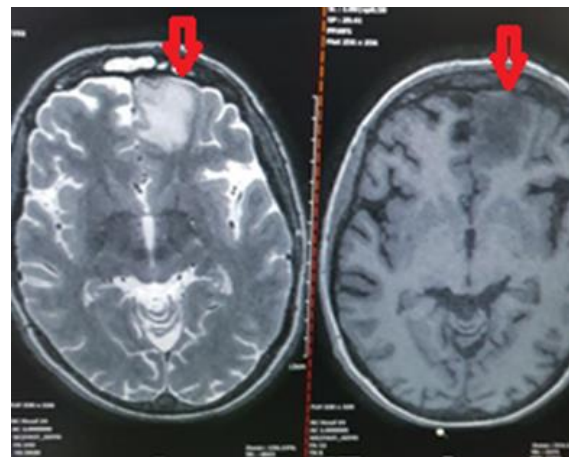


Figure 3. The brain MRI image (MRI-T2 flair view) of an intracranial hyper-intense lesion with dimensions of 20×20 mm in the left frontal lobe (Red arrow)

The findings were compatible with ROCM; accordingly, sinus endoscopic biopsy and debridement was carried out, and the specimens were sent to the laboratory. Ribbon-like hyphae, compatible with mucormycosis, were reported in the histopathological examination (figure 4). Considering the extent of ROCM, the patient was a candidate for enucleation of the left eye, orbital decompression, and sinocerebral

debridement. Nevertheless, the patient refused eye enucleation and craniotomy. Therefore, multiple endoscopic sinus debridement procedures were carried out, and posaconazole (200 mg /Q 6 hours) was added to LAMB as a combination antifungal treatment.

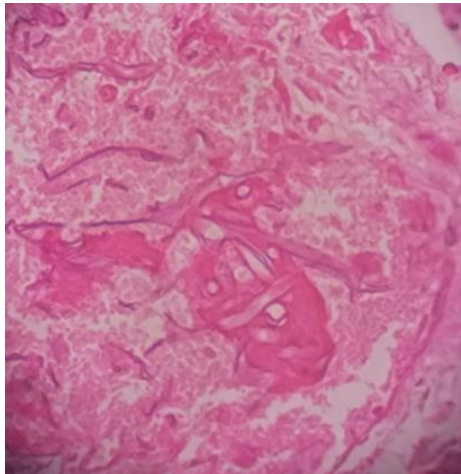


Figure 4. The histological examination of sinus debridement (aseptate ribbon-like hyphae)

During the third week of combination therapy, there was a remarkable improvement in the patient's clinical signs and symptoms. Also, in the follow-up brain MRI images, the frontal lobe lesion was completely resolved (figure 5). The combination antifungal therapy continued for four weeks, and the patient was discharged in the twelfth week. In the weekly follow-ups, no relapse in ROCM was found during the first three months of discharge. However, after three months, the patient died because of relapse in hematologic disease and bleeding due to severe thrombocytopenia.

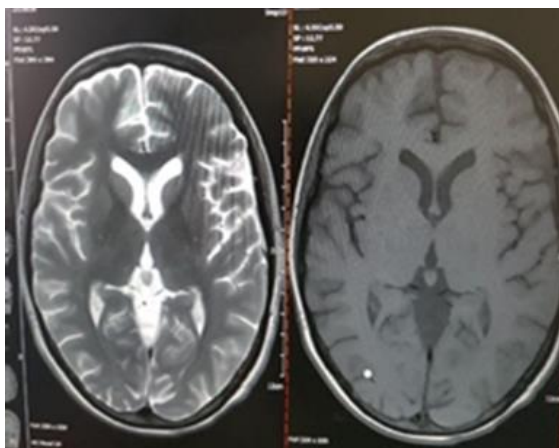


Figure 5. Follow-up MRI after three weeks of combination therapy and four sinus debridement procedures

Discussion

In recent years, the number of diagnosed cases of mucormycosis has increased probably due to increased awareness of the signs and symptoms of this infection and/or improvement of diagnostic techniques (7). Early diagnosis, debridement of necrotized tissues, and prompt initiation of antifungal therapy are the cornerstones of successful treatment for invasive mucormycosis, which can reduce the associated morbidity and mortality (1).

Although surgery is an important part of treatment for mucormycosis, some patients do not meet the essential preoperative criteria or refuse to undergo surgery (similar to our case). Generally, there is scarce information about clinical decision-making in these patients, especially when there is an intracranial invasion. Therefore, in this study, we reported our successful experience in a patient with such conditions. In our patient, a combination antifungal therapy, concomitant with multiple endoscopic sinus debridement procedures, was effective in the treatment of ophthalmic involvement and intracranial lesion, as confirmed by the follow-up MRI images.

LAMB has an excellent inhibitory concentration in the eye and brain tissues (8). Although the concentration of posaconazole in the eye and brain tissues is low, its concentration increases in inflamed tissues (8). Combination antifungal therapy with LAMB plus posaconazole has a remarkable synergistic effect on the inhibition of Mucorales species in vitro (9). One of the possible explanations for this effect is that LAMB can create membrane holes in Mucorales species and facilitate the entry of posaconazole into the cells (10). The efficacy of this regimen in patients with mucormycosis has been indicated in some previous reports (1, 11, 12).

In this regard, in a case series of 32 patients with hematologic malignancies and mucormycosis, who had received a combination of LAMB and posaconazole, favorable clinical responses were reported in 56% of patients (12). In this study, the median duration of maintenance therapy was 74 days in patients with a good therapeutic response (12). However, the mentioned study did not report the efficacy of combination therapy in the improvement of intracranial lesions without craniotomy.

In summary, endoscopic debridement, along with a combination of LAMB and posaconazole, may be a proper therapeutic option for patients with ROCM, who are not eligible candidates for extensive surgery or craniotomy.

Acknowledgments

We appreciate the utmost cooperation of the Pathology and Radiology Departments of Imam Khomeini Hospital.

Conflict of Interests: Authors have no conflict of interests related to this work.

References

1. Sipsas NV, Gamaletsou MN, Anastasopoulou A, Kontoyiannis DP. Therapy of mucormycosis. *J Fungi (Basel)* 2018; 4: E90.
2. Anand A, Anand N, Anand A. Rhinocerebral mucormycosis: Cure without surgery. *Arch Intern Med* 1996; 156: 2262, 2269.
3. Skiada A, Pagano L, Groll A, et al. Zygomycosis in Europe: analysis of 230 cases accrued by the registry of the European Confederation of Medical Mycology (ECMM) Working Group on Zygomycosis between 2005 and 2007. *Clin Microbiol Infect* 2011; 17: 1859-67.
4. Rammaert B, Lanternier F, Zahar JR, et al. Healthcare-associated mucormycosis. *Clin Infect Dis* 2012; 54: S44-54.
5. Jeong W, Keighley C, Wolfe R, et al. The epidemiology and clinical manifestations of mucormycosis: a systematic review and meta-analysis of case reports. *Clinical Microbiol Infect* 2019; 25: 26-34.
6. Kolekar JS. Rhinocerebral mucormycosis: a retrospective study. *Indian J Otolaryngolo Head Neck Surg* 2015; 67: 93-6.
7. Meletiadiis J, Roilides E. Rare Invasive fungal infections: epidemiology, diagnosis and management. *Curr Fungal Infect Rep* 2013; 7: 351-60.
8. Felton T, Troke PF, Hope WW. Tissue penetration of antifungal agents. *Clin Microbiol Rev* 2014; 27: 68-88.
9. Ballester F, Pastor FJ, Guarro J. In vitro activities of combinations of amphotericin B, posaconazole and four other agents against *Rhizopus*. *J Antimicrob Chemother* 2008; 61: 755-7.
10. Perkhofer S, Locher M, Cuenca-Estrella M, et al. Posaconazole enhances the activity of amphotericin B against hyphae of zygomycetes in vitro. *Antimicrob Agents Chemother* 2008; 52: 2636-8.
11. Mardani M, Yadegarynia D, Tehrani S. Combination antifungal treatment for sino-orbito-cerebral mucormycosis: a case report. *Arch Clin Infect Dis* 2016; 11: e28345.
12. Pagano L, Cornely OA, Busca A, et al. Combined antifungal approach for the treatment of invasive mucormycosis in patients with hematologic diseases: a report from the SEIFEM and FUNGISCOPE registries. *Haematologica* 2013; 98: e127-30.