

A case of splenogonadal fusion accompanied by accessory spleen in a 4-year-old boy

Aria Shakeri, Arash Shakeri¹, Reza Rasolmali², Saeed Shakeri³

University of Virginia School of Medicine, Charlottesville, USA, ¹School of Pharmacy, Health Sciences Campus, University of Waterloo, Waterloo, Canada, ²Department of Pathology, Shiraz Central Hospital, ³Shiraz Nephro-Urology Research Center, Department of Urology, Shiraz University of Medical Sciences, Shiraz, Iran

Abstract

Splenogonadal fusion (SGF) is a rare benign malformation in which spleen is aberrantly attached to the gonads or mesonephric derivatives. This entity often presents with scrotal mass, inguinal hernia, or cryptorchidism. Herein, we report our experience with a boy who presented with a scrotal enlargement which later turned out to be SGF. Moreover, an accessory spleen was unexpectedly found in the left inguinal canal. To the best of our knowledge, this is the first report of SGF and accessory spleen in the literature. Although rare, SGF should be included in the complete differential diagnosis list of scrotal masses, especially in children. The use of frozen section pathology if available would aid the surgeon in avoiding unnecessary orchiectomy in small testicular masses of benign origin

Keywords: Accessory spleen, scrotal mass, splenogonadal fusion

Address for correspondence: Aria Shakeri, University of Virginia School of Medicine, 1215 Lee St, Charlottesville, Virginia, USA 22908.

E-mail: as4qb@hscmail.mcc.virginia.edu

Received: 26.12.2017, **Accepted:** 29.04.2018

INTRODUCTION

Splenogonadal fusion (SGF) is a rare urologic malformation in which splenic tissue is aberrantly associated with gonads. SGF can present as a scrotal mass.^[1] Here, we present a discontinuous SGF which presented as a scrotal mass and was also accompanied by accessory spleen in the left inguinal canal.

CASE REPORT

Our patient was a 4-year-old boy who was referred to the urology clinic because of a history of nonprogressive unilateral scrotal enlargement of a few months duration. He had no notable past medical history, and there was no history of genitourinary trauma or urinary symptoms. The child was well-appearing and physical examination revealed

a left inguinal hernia. Right testis was palpable in scrotal sac and was normal. Left hemiscrotum was enlarged, and a solid nontender mass was palpable. There was no distinct border between testis and the mass.

Laboratory investigations including urinalysis, alpha-fetoprotein and human chorionic gonadotropin were normal. Ultrasonography revealed a hernial sac in the left inguinal area (31 mm × 23 mm × 12 mm) filled with bowel. Furthermore, a vascular homogenous hypochoic mass (27 mm × 18 mm × 12 mm) was found adjacent to the superior aspect of the left testicle (11 mm × 6 mm). Although the tumor markers were negative, however, there was a real risk of a malignant growth, so we decided not to do percutaneous biopsy and proceeded directly to open surgery with a presumptive diagnosis of testicular

This is an open access journal, and articles are distributed under the terms of the Creative Commons Attribution-NonCommercial-ShareAlike 4.0 License, which allows others to remix, tweak, and build upon the work non-commercially, as long as appropriate credit is given and the new creations are licensed under the identical terms.

For reprints contact: reprints@medknow.com

How to cite this article: Shakeri A, Shakeri A, Rasolmali R, Shakeri S. A case of splenogonadal fusion accompanied by accessory spleen in a 4-year-old boy. *Urol Ann* 2018;10:406-8.

Access this article online

Quick Response Code:



Website:

www.urologyannals.com

DOI:

10.4103/UA.UA_194_17

neoplasm. The patient was explored through a left-sided inguinal incision. Intraoperatively, we found a firm dark blue fleshy mass arising from the left testis and occupying most of testis volume [Figure 1]. There was also a separate smaller mass with the same characteristics located in the processus vaginalis [Figures 1 and 2]. As we did not have the facility of frozen section available and our clinical diagnosis was a tumoral growth originating from the testis, complete surgical removal with a safe margin was the best option. Radical orchiectomy was performed because there was hardly any testicular parenchyma to be salvaged; and then, surgery was finished by performing a herniotomy. Pathologic examination of the testicular mass revealed benign splenic tissue attached to a primitive nonfunctional testicular parenchyma [Figure 3]. Furthermore, the mass found in the inguinal canal was also found to be benign splenic parenchyma. Postoperative period was uneventful. The patient has been under follow-up for >1 year with no concerning issues.

DISCUSSION

SGF is a rare benign congenital anomaly. It was first described in 1883 by the German pathologist Bostroem.^[1,2] It is defined as an abnormal attachment between the splenic tissue and the gonads or mesonephric derivatives. To this day, <200 cases have been described in the scientific literature. This entity is almost entirely left-sided (98%) and demonstrates a profound male predominance (incidence ~ 16:1). Around 70% of patients are diagnosed when younger than 20 years old.^[3]

In 1956 Putschar and Manion classified SGF into two groups: continuous and discontinuous. In the continuous form, there is a cord-like connection between the orthotopic spleen and the gonad. This continuity consists of splenic or fibrous tissue or a mixture of them. Such a connection is absent in the discontinuous form of SGF. Continuous SGF is commonly found in association with a range of other malformations, such as cleft palate, micrognathia, cardiac defects, limb deformities, and anal malformations.^[4,5]

The splenic tissue is often found within the tunica vaginalis and is closely associated with the testicular parenchyma. However, a fibrous capsule often is present and prevents free intermingling of tissues.^[4]

Spleen originates from the mesenchyme of left dorsal mesogastrium. Gonads, however, are derived from the genital ridges on the posterolateral wall of the embryo.^[1,2] It has been postulated that SGF arises due to an abnormal

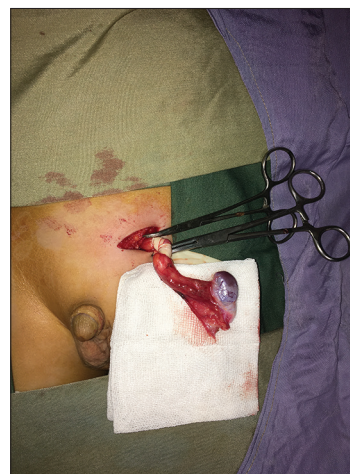

Figure 1: Inguinal incision and early clamping of the spermatic cord

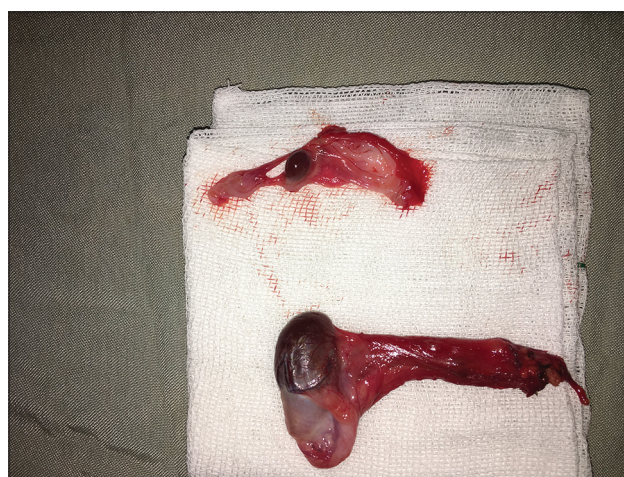


Figure 2: On the left, specimen of radical orchiectomy is shown which demonstrates the purple splenic tissue attached to the tan-white testicular remnant. On the right, the excised mass found in the inguinal canal is seen

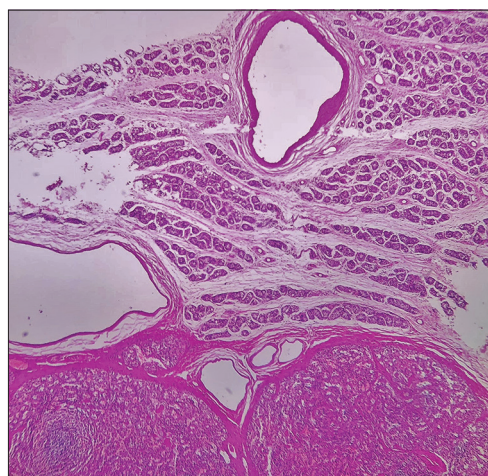


Figure 3: Histopathologic staining of the splenogonadal fusion specimen. Benign splenic parenchyma (in the bottom) juxtaposed to an atrophic testicular tissue

fusion event that happens during the 5th to 8th week of gestation. Gut rotation during this period rings the two

primordial tissues close, and a fusion event may happen. If an aberrant fusion happens, during the gonadal descent (which starts at 8th week) the splenic tissue would descend with the gonad and may be found anywhere along the normal descent path.^[3,4] This theory also is consistent with the common association of limb and jaw defects with the continuous SGF because those mesenchymal derivatives (limb buds and Meckel's cartilage) also develop during the critical fusion time window.

SGF commonly presents with inguinal hernia, cryptorchidism, or scrotal mass. This is probably because the aberrant splenic tissue interferes with the normal gonadal descent and/or the closure of processus vaginalis.^[3] As previously mentioned, continuous SGF is commonly accompanied by other congenital anomalies such as micrognathia, cleft palate, cardiac defects, and limb deformities.^[5,6] Such is not the case with the discontinuous cases of SGF. To the best of our knowledge, this is the first report of SGF and inguinal canal accessory spleen in one patient.

Diagnosis is often made during surgery for testicular mass, cryptorchidism, or hernia repair. Perioperative frozen section examination is recommended to avoid misdiagnosing SGF as a testicular tumor and performing unnecessary orchiectomies.

Various imaging modalities can be very helpful but often are not performed due to low preoperative suspicion. Doppler ultrasonography of the testis is often demonstrates a homogeneous echogenic vascular mass situated on the superior aspect of the testes.

In terms of management, if clinical diagnosis of SGF is definite, surgical exploration is not recommended in cases of small asymptomatic mass and such patients should be followed by regular physical examination, tumor markers, and ultrasound. If surgery is performed, using intraoperative frozen section pathology if available is of utmost importance and testis can often be spared if the mass is small and separable from testis and remaining testicular tissue is worth to preserve. However, radical orchidectomy is the gold standard treatment of any solid testis mass when there is a normal contralateral testis present. It has been reported that 25%–35% of SGF will necessitate orchidectomy because of testicular atrophy or inseparability of tissues.^[3,4] This was the case for our patient where the testicular remnant was very much atrophied and

later found to be of primitive histology. This was probably due to pressure applied on the testicular parenchyma by the splenic tissue enclosed within the unyielding tunica vaginalis. We did not have facilities for frozen section pathology in our operating room and could not rule out the malignant origin of the mass as well.

CONCLUSION

In conclusion, SGF is a rare benign urologic malformation that can lead to unnecessary orchiectomy. It should be considered in the complete differential diagnosis of solid left scrotal or pelvic masses. In the pediatric population, association of a left testicular mass with ipsilateral inguinal hernia should alert the urologist to the possibility of SGF. Furthermore, intraoperative frozen pathologic examination can help prevent confusion of SGF with testicular neoplasms.

Declaration of patient consent

The authors certify that they have obtained all appropriate patient consent forms. In the form the patient(s) has/have given his/her/their consent for his/her/their images and other clinical information to be reported in the journal. The patients understand that their names and initials will not be published and due efforts will be made to conceal their identity, but anonymity cannot be guaranteed.

Financial support and sponsorship

Nil.

Conflicts of interest

There are no conflicts of interest.

REFERENCES

1. Lin CS, Lazarowicz JL, Allan RW, MacLennan GT. Splenogonadal fusion. *J Urol* 2010;184:332-3.
2. Chiramonte C, Siracusa F, Li Voti G. Splenogonadal fusion: A genetic disorder? – Report of a case and review of the literature. *Urol Case Rep* 2014;2:67-9.
3. Huang G, Huang Y, Zeng L, Yuan M, Wu Y, Huang L, et al. Continuous-type splenogonadal fusion: A case report. *Exp Ther Med* 2017;13:2019-21.
4. Ugliarolo AD, Goltzman ME, Niazi M, Lehman D, Silletti J, Bjurlin MA, et al. Splenogonadal fusion presenting as an asymptomatic testicular mass. *Urology* 2016;97:1-4.
5. Alivizatos G, Skolarikos A, Sopilidis O, Ferakis N, Chorti M. Splenogonadal fusion: Report of a case and review of the literature. *Int J Urol* 2005;12:90-2.
6. Croxford WC, Pfistermuller KL, Scott F, Pope AJ. Splenogonadal fusion presenting clinically and radiologically as a seminoma. *Urol Case Rep* 2015;3:204-5.