

# Surgical Management of Neurovascular Bundle in Uterine Fibroid Pseudocapsule

Andrea Tinelli, MD, Antonio Malvasi, MD, Brad S. Hurst, MD, Daniel A. Tsin, MD, Fausto Davila, MD, Guillermo Dominguez, MD, Domenico Dell'edera, MD, Carlo Cavallotti, MD, Roberto Negro, MD, Sarah Gustapane, MD, Chris M. Teigland, MD, Liselotte Mettler, MD

## ABSTRACT

The uterine fibroid pseudocapsule is a fibro-neurovascular structure surrounding a leiomyoma, separating it from normal peripheral myometrium. The fibroid pseudocapsule is composed of a neurovascular network rich in neurofibers similar to the neurovascular bundle surrounding a prostate. The nerve-sparing radical prostatectomy has several intriguing parallels to myomectomy. It may serve either as a useful model in modern fibroid surgical removal, or it may accelerate our understanding of the role of the fibrovascular bundle and neurotransmitters in the healing and restoration of reproductive potential after intracapsular myomectomy. Surgical innovations, such as laparoscopic or robotic myomectomy applied to the intracapsular technique with magnification of the fibroid pseudocapsule surrounding a leiomyoma, originated from

the radical prostatectomy method that highlighted a careful dissection of the neurovascular bundle to preserve sexual functioning after prostatectomy. Gentle uterine leiomyoma detachment from the pseudocapsule neurovascular bundle has allowed a reduction in uterine bleeding and uterine musculature trauma with sparing of the pseudocapsule neuropeptide fibers. This technique has had a favorable impact on functionality in reproduction and has improved fertility outcomes. Further research should determine the role of the myoma pseudocapsule neurovascular bundle in the formation, growth, and pathophysiological consequences of fibroids, including pain, infertility, and reproductive outcomes.

**Key Words:** Fibroid pseudocapsule, Uterine leiomyoma, Myoma pseudocapsule, Myomectomy, Prostatectomy, Neurovascular bundle, Laparoscopy, Uterine rupture, Fertility, Sterility, Reproduction, Labor, Neurotransmitters, Neuropeptides, Intraoperative complications, Postoperative compliance, Surgical outcome.

Department of Obstetrics and Gynaecology, Vito Fazzi Hospital, Lecce, Italy (Dr. Tinelli).

Department of Obstetrics and Gynaecology, Santa Maria Hospital, Bari, Italy (Dr. Malvasi).

Assisted Reproduction Center, Carolinas Medical Center, Charlotte, North Carolina, USA (Dr. Hurst).

The Mount Sinai Hospital of Queens, Long Island City, New York, USA (Dr. Tsin).

Universidad Autonoma de Mexico, Facultad de Estudios Superiores. Iztacala, Mexico (Dr. Davila).

Fundación Hospitalaria, Buenos Aires, Argentina (Dr. Dominguez).

Unit of Cytogenetic and Molecular Genetics, Madonna delle Grazie Hospital, Matera, Italy (Dr. Dell'edera).

Department of Human Anatomy, Sapienza University, Rome, Italy (Dr. Cavallotti).

Department of Endocrinology, Vito Fazzi Hospital, Lecce, Italy (Dr. Negro).

Department of Obstetrics and Gynaecology, SS. Annunziata Hospital, Chieti, Italy (Dr. Gustapane).

Department of Urology, Carolinas Medical Center, Charlotte, North Carolina, USA and Division of Gastrointestinal and Minimally Invasive Surgery, Department of Surgery, Carolinas Medical Center, Charlotte, North Carolina, USA (Dr. Teigland).

Kiel School of Gynaecological Endoscopy, Department of Obstetrics and Gynaecology, University Hospitals Schleswig-Holstein, Campus Kiel, Germany (Dr. Mettler).

Address correspondence to: Dr. Andrea Tinelli, MD, Department of Obstetrics and Gynaecology, Division of Experimental Endoscopic Surgery, Imaging, Minimally Invasive Therapy and Technology, Vito Fazzi Hospital, Piazza Muratore, 73100 Lecce, Italy. Telephone: +39/339/2074078, Fax: +39/0832/661511, E-mail: andreatinelli@gmail.com

DOI: 10.4293/108680812X13291597716302

© 2012 by JSLS, *Journal of the Society of Laparoendoscopic Surgeons*. Published by the Society of Laparoendoscopic Surgeons, Inc.

## INTRODUCTION

Uterine fibroids affect 25% of women. They are the most common benign tumors of the female reproductive tract, and arise from the smooth-muscle cells of the uterus and may be single or multiple. Hysterectomy has been the most common treatment modality for symptomatic fibroids in the past. Based on data from 1990 to 1997, the presence of uterine fibroids was the main indication for hysterectomy in the United States. Myomectomy, the surgical removal of fibroids without hysterectomy, is the second most common surgical procedure for this condition.<sup>1</sup> Generally fibroids are benign with few symptoms, but larger fibroids can compress surrounding organs, leading to urinary, digestive, or sexual symptoms. Fibroids may negatively affect fertility, especially when large tumors are present or when the uterine cavity is distorted.<sup>1</sup> Several treatments are available to remove fibroids and alleviate symptoms, such as conservative surgery, medical therapy,<sup>2</sup> or various novel radiological interventions.<sup>3</sup> Despite the frequency with which fibroids are diagnosed and treated, there remains considerable uncertainty and con-

trovercy among clinicians and women regarding the best way to manage them. Myomectomy is the most common conservative treatment in gynecology, performed by classical open surgery or by laparoscopy.<sup>4</sup> There is support for performing myomectomy by removing the fibroid from its surrounding structure, the fibroid pseudocapsule,<sup>5</sup> an “intracapsular myomectomy.” It is performed by stretching and extracting fibroid tissue directly from the surrounding fibromuscular skeleton, breaking up the fibrous bridges. The importance of intracapsular myomectomy was described in a recent review.<sup>6</sup> Research on the pseudocapsule started with Ito et al,<sup>7</sup> who performed a histopathologic evaluation of a uterine fibroid and its pseudocapsule, to determine the scientific reason for less blood loss during an intracapsular myomectomy. They demonstrated that a pseudocapsule is formed by extracellular matrix around the myoma, separating fibroid from normal myometrium. The authors maintained that a fibroid is anchored to the pseudocapsule by connective bridges, but lacks its own true vascular pedicle.<sup>7</sup> Also Dapunt et al<sup>8</sup> showed a vascular network surrounding myoma, as a pseudocapsule, so that if the detachment of the myoma occurred into the pseudocapsule, less bleeding occurred during myomectomy. Fox et al<sup>9</sup> studied fibroids by ultrastructural microscopy and showed an anatomical structure different than the normal myometrium: fibroids had a well-defined regular outline and a surrounding pseudocapsule of compressed muscle fibers. The hypothesis of a fibroid pseudocapsule was also asserted by Vizza et al,<sup>10</sup> who demonstrated that the pseudocapsule contains fibers that tend to bulge out from the surrounding myometrium and have a firm, whorled, or trabeculate surface. Furthermore, ultrasonographic evaluations have been performed on myomas and their connecting structures: the pseudocapsule appeared as an echogenic line around the myoma, with a wall  $\leq 1$ cm and with reinforcement of distal echoes.<sup>11</sup> Additional histological investigations of the fibroid vascular pseudocapsule has led to a better understanding of the role in the modern minimally invasive myomectomy.<sup>12</sup> Macroscopic evaluation of the pseudocapsule and adjacent myometrium showed parallel arrays of extremely dense capillaries and larger vessels that form the capsule. This is separated from the myometrial vasculature by a narrow avascular cleft. Pseudocapsule vessels from the surrounding myometrium formed clusters in the center of the vascular network creating a sort of pedicle, and the veins surrounding the myoma circulated under the pseudocapsule in a plexus.<sup>12</sup> Moreover, biochemical growth factors in the pseudocapsule vessels cause intense angiogenesis in the pseudocapsule, probably promoted by the fibroids. The angiogenesis of the myoma

pseudocapsule likely leads to the formation of a “protective” vascular capsule responsible for the supply of blood to the growing tumor.<sup>13</sup> However, studies have demonstrated a dysregulation of various growth factors and their receptors in uterine myomas.<sup>12,13</sup>

## DATABASE

The idea of a neurovascular bundle surrounding myomas inside a pseudocapsule derives from a multidisciplinary discussion among gynecologists and urologists on similarities of a myoma pseudocapsule with the prostate capsule. For reducing the probability of impotence associated with prostate cancer treatment, urologists generally preserve neurovascular bundles surrounding the prostate. Anatomically, neurovascular bundles are situated on the periphery of the prostate. Neurovascular bundles are placed in the lateral pelvic fascia, deep, lateral, and cephalad to Denonvilliers' fascia, prostatic fascia, and the levator fascia.<sup>14</sup> As evidenced by Takenaka et al<sup>15</sup> and Costello et al,<sup>16</sup> cavernous branches connect the capsular arteries and veins in a spray-like distribution to form neurovascular bundles 20mm to 30mm distal to the junction of the bladder and prostate. At the apex of the prostate, branches of the nerves to the cavernous bodies and striated sphincter also have a spray-like distribution both anteriorly and posteriorly. This anatomical framework has been defined as neurovascular bundles by Walsh et al.<sup>17</sup> The neurovascular bundles pass through 2 distinct fascial planes that surround the prostate called “the prostatic fascia and levator fascia”: the nerves cross in the neurovascular bundle and innervate the corpora cavernosa, rectum, prostate, and levator ani musculature. The last 3 receive a blood supply from vessels running in the neurovascular bundle. Nowadays, in most men who undergo radical prostatectomy, it is common to preserve both neurovascular bundles. If nerve sparing is performed correctly, the prostatic fascia must remain intact. When tumor extends through the capsule, it seldom penetrates more than 1mm to 2mm. This involved tissue can often be removed with preservation of the neurovascular bundles. Even in extraprostatic extension, it is possible to partially excise the neurovascular bundle, preserve potency, and achieve negative margins of excision.<sup>18</sup>

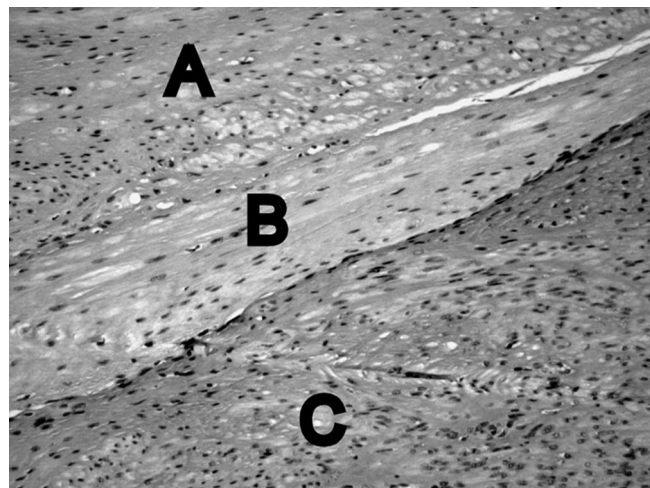
The prostatic neurovascular bundle provides both somatic and autonomic innervations for urinary continence. The excision of neurovascular bundles causes more incontinence and impotence than when the neurovascular bundles are preserved.<sup>19</sup> To spare the prostatic neurovascular

bundles, laparoscopic and robotic-assisted prostatectomy are both useful,<sup>20</sup> because magnification facilitates a more accurate dissection with less traction.<sup>21</sup> Surgically, a mid-line vertical incision is made into Denonvilliers' fascia—along the entire gland extending up the urethra—and the fascia is sharply retracted to the right and left to expose the posterior prostatic capsule. This incision must completely release the neurovascular bundles to allow correct restoration of the retractor blades and to avoid a traction injury to the bundles. Blunt or sharp dissection is needed to release the bundles far enough laterally to achieve adequate exposure to the posterior prostate base. Although these nerves are microscopic,<sup>22</sup> their anatomic location can be ascertained by using of the capsular vessels as a landmark. An opening in the levator fascia is performed by sharp incision along the anterolateral surface of the prostate starting at the base of the prostate and proceeding toward the apex. This maneuver releases the bundle laterally, making it easier for the next step in which the bundle is released posteriorly at the apex.

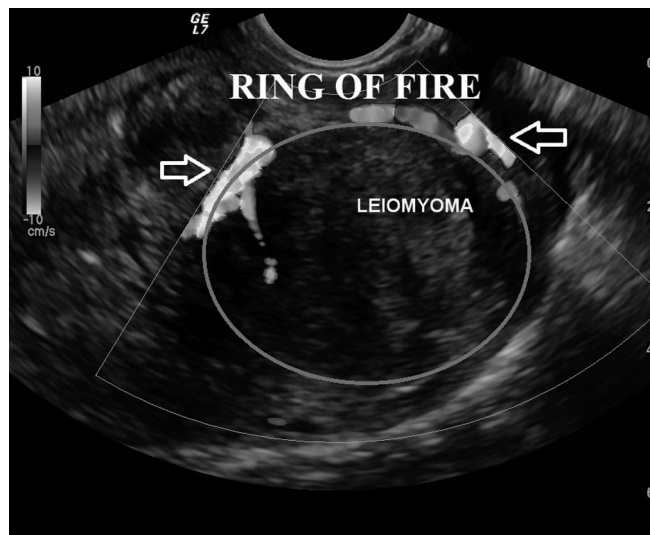Once the superficial fascia has been released, the neurovascular bundles can be identified by the presence of a thin “groove” on the posterolateral edge of the prostate. The interfascial plane (ie, between the levator and prostatic fascia) is developed by using blunt dissection with a fine curved dissector and gentle diathermocoagulation. Dissection continues in close approximation to the surface of the prostatic fascia to optimize quantitative cavernous nerve preservation. If bleeding occurs from periprostatic vessels, insufflation pressure can be increased and pressure applied to the source of bleeding with hemostatic gauze. Hemostasis with high wattage diathermocoagulation or ultrasonic heat energy should be avoided during dissection near the neurovascular bundles, because these energy sources have been shown to be injurious to cavernous nerve function in the canine model.<sup>23</sup> The neurovascular bundles may be identified through the use of ultrasound Doppler.<sup>24</sup> Based on these findings concerning the importance of the prostatic capsule and the important and physiologic role of nerve-sparing techniques for prostatectomy, the potential importance of the peripheral neurovascular bundle of uterine leiomyoma was revisited.

### ANATOMY OF THE PSEUDOCAPSULE

Microscopically, the pseudocapsule seems to be a continuous layer between the fibroid and myometrium and is made of thickened collagen fibers and blood vessels (**Figure 1**) that form a vascular ring. A sonographic “ring of fire” (**Figure 2**) by echo-color Doppler. The pseudocapsule is separated from surrounding myome-



**Figure 1.** Histological microphotograph stained by hematoxylin & eosin (H&E) at 10x, showing the myometrium of a pseudo-capsule with vascular spaces: A=myometrium, B=pseudocapsule, C=leiomyoma.

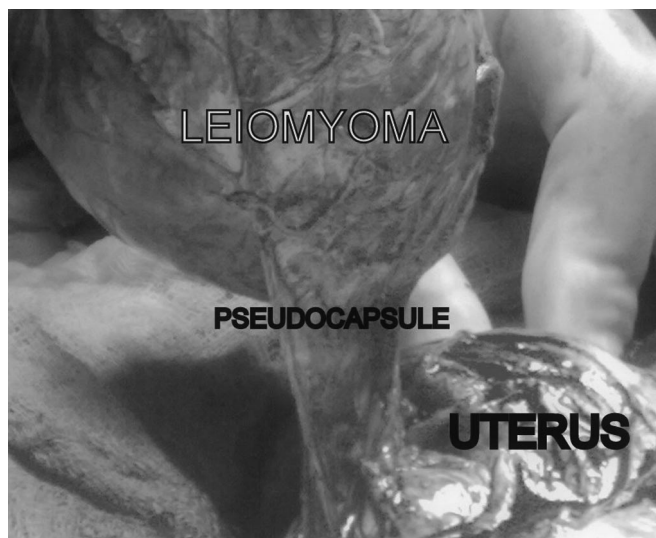

**Figure 2.** A uterine transvaginal ultrasound section evidenced the fibroid pseudocapsule by a “ring of fire” around the fibroid.

trium, forming a hyperechogenic ring that surrounds and defines the myoma.<sup>6</sup> To help understand micro-neuroanatomy of the fibroid peripheral area, we should understand the story of the pseudocapsule. An anatomical textbook, published at the end of last century, asserted that, “myoma shows a nodular aspect, a round image, well circumscribed, to enucleate even if they miss a pseudocapsule.”<sup>25</sup> These authors confirmed the existence of a fibroid pseudocapsule and identified the cleavage plane, which should be respected during myomectomy.<sup>6</sup> The first article that described a fibrovascu-

lar system over a fibroid as “a mass of proliferating arteries” was in 1944.<sup>26</sup> Farrer-Brown in 1970,<sup>27</sup> and Awataguchi in 1982<sup>12</sup> found a fibrovascular plexus around the periphery of the fibroid. Lately, Casey et al<sup>28</sup> reported significantly higher microvasculature density in the surrounding myometrium in large fibroids; the authors discovered that the vascular capsule was a substantial feature of fibroids, and that it reached the highest density of blood vessels in large tumors. Pathologists examined the relationship between ultrasound and histological findings of the fibroid’s vascular capsule in a series of women using Gn-RH analogues in preoperative treatment before myomectomy.<sup>29–31</sup>

Walocha et al<sup>32</sup> performed a microstructural evaluation of the fibroid pseudocapsule and found that the density of blood vessels increases around the myoma. As the fibroid grows, new blood vessels penetrate the tumor from its periphery where “the vascular capsule” network is formed. Some of the vessels in the pseudocapsule connect at the base of the myoma and form a little foot (**Figure 3**) that often bleeds during an extracapsular myomectomy. These authors analyzed the fibroid vascular system using corrosion casting combined with scanning electron microscopy and affirmed that the pre-existing blood vessels undergo regression and new vessels invade the tumor from the periphery during the development of myomas. Myoma pseudocapsule originates from small vessels entering the tumor from the periphery, forming a “vascular network” around the myoma, with flattened veins com-



**Figure 3.** An intraoperative image of laparotomic myomectomy showing a fibroid pseudocapsule during myoma stretching by the surgeon from myometrium.

pressed by the tumor.<sup>32</sup> Forssman et al<sup>33</sup> reported the presence of a 2cm in diameter vascular capsule surrounding the myoma and found that the inner aspect of the capsule contained large vessels that invade the capsule from the periphery.

### NEUROTRANSMITTERS, MUSCULAR HEALING, AND INTRACAPSULAR MYOMECTIONY

A growing body of research supports the importance of neuropeptides and neurotransmitters in wound healing. Evidence exists that the nervous system and its neurotransmitters, such as Substance P (SP), Vasoactive Intestinal Peptide (VIP), Neuropeptide Y (NPY), Oxytocin, Vasopressin (VP), PGP9.5, calcitonin gene-related peptide (CGRP), and growth hormone-releasing hormone (GHRH), play a role in mediating inflammation and healing.<sup>34–36</sup> Sparing these peptides enhances correct healing of a hysterotomy.

Mettler et al<sup>37</sup> studied the endocrinology of myoma pseudocapsules, affirming they have a delicate vascular network rich in neurotransmitters similar to the neurovascular bundle containing neuropeptides and related fibers surrounding the prostate.<sup>37</sup>

Malvasi et al<sup>38</sup> evaluated the distribution of 2 neuropeptides, SP and VIP, in the pseudocapsule of uterine fibroids: they showed these neurofibers are present in the fibroid pseudocapsules and in normal myometrium of the non-pregnant uterus.<sup>38</sup>

The presence of SP and VIP neurotransmitters in the fibroid pseudocapsule, like the neurovascular bundle surrounding the prostate, suggests they should be preserved with sparing of the pseudocapsule by gentle intracapsular fibroid removal. This dissection can be facilitated by a minimally invasive surgical technique like laparoscopy.<sup>37</sup>

For this reason, the fibroid pseudocapsule needs to always be gently protected during myomectomy, avoiding pretreatment destructive techniques, such as large diathermocoagulation with high electrical wattage (>30 watts).<sup>39</sup>

Neuropeptides are transported to tissues by the neurovascular network. The myoma pseudocapsule vessels can be studied with a 3-dimensional mathematical model<sup>40</sup> that shows an increase in vascular tortuosity, disarray, abnormal branching, and the presence of “cul-de-sac” pseudocapsule vessels. All of these features are similar to the features of malignant neoplastic tissue vessels present in malignant tumors. It was not possible in this study to clarify whether the pseudocapsule vasculature network could be sustained by mechanical and inflammatory effects of myoma on myometrium, or produced by a sort of

neoplastic type of neoangiogenesis due to the fibroid growth, or even by a normal muscle and tissue healing process, such as a neurovascular preparative reaction of the female body to a fibroid expulsion (pedunculated fibroids), necrosis or degeneration.

In humans, difficulties in obtaining serial samples of hysterotomic scar during myomectomy or cesarean delivery are a major barrier to our understanding of the events involved in the postmyomectomy and postpartum remodeling processes of the uterine wound after a cesarean delivery. Thus, little is known about healing of the uterine scar tissue after surgical injuries, such as myomectomy and cesarean deliveries. However, irrespective of the ultimate result, wound healing is a dynamic, interactive process involving neuromediators, angiogenetic factors, neuropeptides, blood cells, extracellular matrix, and parenchymal cells that follows 3 complex and overlapping phases: inflammation, tissue formation, and tissue remodeling.<sup>41</sup> And this healing process is also involved in post-operative adhesion development, as a consequence of myomectomy and associated with a high risk of de-novo adhesion formation, that may decrease fertility.<sup>42</sup>

The authors applied their surgical method in a series of patients to study adhesions following intracapsular laparoscopic and abdominal myomectomy (6cm to 8cm), with or without an anti-adhesion barrier, using nonsystematic second-look surgery.<sup>43</sup> When an adhesion barrier was not used, a significant rate of adhesions occurred in laparotomy (28.1%) compared to laparoscopy (22.6%). Filmy and organized adhesions were predominant with an adhesion barrier, and cohesive adhesions were more common without an adhesion barrier. Based on these data, an adhesion barrier should always be used after laparoscopic intracapsular myomectomy in women wanting pregnancy, because it appears to promote correct healing and reduces adhesion formation.

**ENDOSCOPICALLY TAILORED MICRO-SURGERY APPLIED TO PROSTATECTOMY AND MYOMECTOMY**

A radical prostatectomy must be balanced between achieving cancer control (negative surgical margins) and preservation of the neurovascular bundle to protect sexual and post-surgical function. This can be accomplished by an endoscopically tailored microsurgery, which spares nerve injuries. Likewise, myomectomy should be performed by an intracapsular method, because the uterus is fully innervated and each myomectomy site could lead to uterine neuro-anatomical damage.

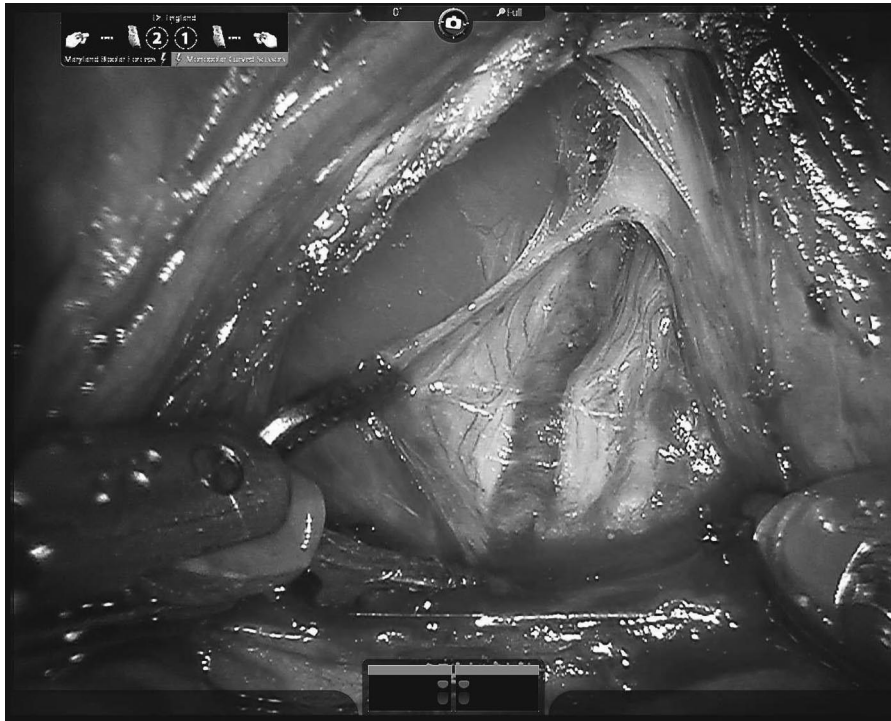
Pelvic innervations in both men and women are derived from the superior hypogastric plexus, sympathetic chain, parasympathetic fibers (S2-4), and the sacral plexus (S1-S5). The superior hypogastric plexus is the downward continuation of the inferior mesenteric plexus over the lower aorta and sacral promontory. Right and left hypogastric nerves supply the inferior hypogastric plexi over the posterior-lateral pelvis, passing behind the common iliac arteries before entering the utero-sacral and cardinal ligaments. In women, this system innervates the uterus and upper vagina. The uterus receives its primary innervations from the utero-vaginal plexus (Frankenhauser's plexus), which is located near the transverse cervical ligament lateral to the cervix. Nerve fibers are distributed throughout the myometrium with the branches of the uterine artery. There are nerve fibers throughout the basal third of the endometrium and a significant plexus at the endometrial-myometrial interface.<sup>44</sup>

Based on these neuroanatomical findings, the authors developed and standardized their intracapsular myomectomy technique (as urologists standardized prostatectomy) to preserve neurovascular bundles.

In urological surgery, the goal is to preserve the neurovascular bundle, which is located outside the prostatic capsule, to prevent erectile dysfunction (impotency) and urinary incontinence. Nerve-sparing techniques for anatomic radical prostatectomy (**Figure 4**) developed in recent years have helped to reduce complications related to injuries to the neurovascular bundle. A commonly used approach for neurovascular bundle preservation involves incision of the lateral prostatic fascia, partial mobilization of the neurovascular bundle from the apical third of the gland, and then urethral transection. Subsequent elevation of the apex of the prostate, generally with a Foley catheter for traction ensures lateralization of the neurovascular bundle and posterior dissection of the prostate. Early release of the neurovascular bundle from the apex of the prostate before beginning the posterior dissection reduces the time to recovery and improves function.<sup>45</sup>

The clinical rationale for intracapsular myomectomy can be applied to all myomectomies. It is relevant, because a proper laparoscopic myomectomy dramatically improves fertility, reduces blood loss, shortens hospital stay, and minimizes therapeutic antibiotic administration.<sup>46</sup>

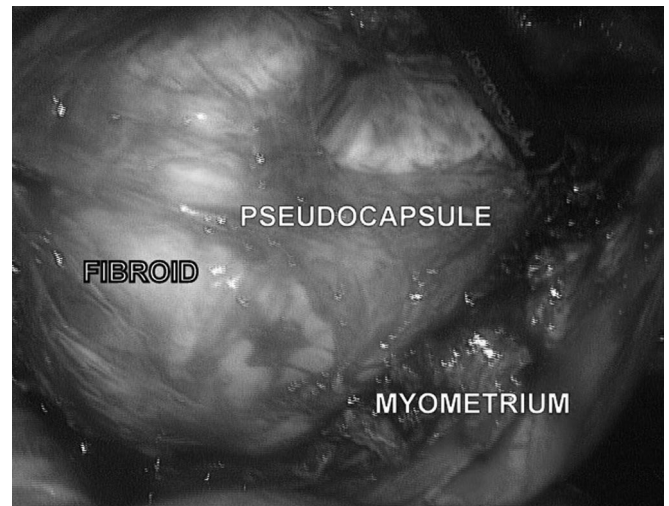Laparoscopic myomectomies are performed under general anesthesia via endotracheal intubation with a standardized 4-port approach: 1 port for the laparoscope and 3 lower quadrant ancillary ports (1 suprapubic central 10-mm port and 2 lateral 5-mm ports). The 10-mm central



**Figure 4.** A laparoscopic radical prostatectomy image by da Vinci robot, showing the prostatic vein and neurovascular bundle surrounding the prostate.

suprapubic port is often changed to 15mm to 20mm for the introduction of a morcellator at the end of the procedure. All patients receive an intrauterine manipulator prior to laparoscopy, to better mobilize the uterus. Intracapsular laparoscopic myomectomy of the submucosa and intramural fibroids is generally performed without injection of an ischemic solution into the myometrium. The visceral peritoneum is incised in the midline longitudinal plane, by monopolar scissors or crochet needle electrode, proceeding in depth into myometrium to reach the correct plane under the myometrium, to detect the myoma pseudocapsule with the fibroid below.

Once the myoma pseudocapsule is identified, it is exposed by atraumatic clamp or by irrigator cannula, to provide a panoramic laparoscopic view of the pseudocapsule of all subserous-intramural leiomyomas. Then, the surgeon affects the pseudocapsule by a longitudinal cut, using monopolar scissors or a Hook electrode at low wattage (30 watt), to expose the myoma surface (**Figure 5**). The fibroid is then secured by a myoma screw or Collins laparoscopic forceps to perform the traction necessary for its enucleation, helped by an irrigator cannula inserted in the space under the myoma pseudocapsule and fibroid. Hemostasis of small vessel bleeding is achieved by a



**Figure 5.** A laparoscopic image showing fibroid enucleating from myometrium by monopolar Hook electrode gentle cut of pseudocapsule by low-wattage energy, to expose the myoma surface, with a magnification of the pseudocapsule during myoma removal.

low-wattage bipolar clamp or by Hook electrode or monopolar scissors, always at 30 watts, to free the base of the myoma and the connective bridges from the pseudocap-

sule. In this way, complete minimal traumatic fibroid removal from its pseudocapsule is accomplished with minimal blood loss sparing of the pseudocapsule. In case of pseudo-pedunculated myomas, the pedicle is coagulated by bipolar forceps and cut by laparoscopic scissors or cut after placement of loops or staples. In cases of deep intramural myomas, chromopertubation is always applied via a cervical cannula not only to check tubal patency but also to facilitate the direct recognition of an inadvertently opened uterine cavity.

The myometrium closure is performed with a single (for subserous fibroids) or double layer (for intramurals) suture, including overlying serosa, with a round CT-1 curved needle, using intra- or extracorporeal knots. In subserosal myomectomies, the edges of the uterine defect are approximated with introflecting U-inverted stitches (myometrium/serosa-serosa/myometrium direction) with intramyometrial knot, at 1-cm increments from the edge of the incision (as a “baseball-type” suture). Closure is by surgeon’s choice: interrupted closure or traditional unidirectional running suture, started at the end of one of the hysterotomy sides.

Deep intramural fibroids require a 2-layer myometrial closure with introflecting sutures, covered by a “baseball-type” suture. If the uterine cavity is accidentally opened during fibroid enucleating, 2 to 3 deep myometrial single or continuous sutures is applied to the uterine cavity edges. After hysterorrhaphy, fibroids are usually morcellated for ease of removal.

#### **CONTROVERSIES SURROUNDING LAPAROENDOSCOPIC MYOMECTOMY**

The general myomectomy dogma is that “each surgical fibroid enucleation needs to be gently performed to enhance the correct healing process of the uterine musculature and to successively facilitate the correct restoration of the uterine musculature anatomical-functional.” During myomectomy, as stated in the literature,<sup>6,37–40,43</sup> the fibroid pseudocapsule neurovascular bundle needs to always be protected, avoiding destructive surgical procedures, such as extensive and high-wattage diathermocoagulation (>30 watt) or excessive tissue manipulation or trauma. This method of myomectomy maximally respects the fibroid pseudocapsule neurovascular bundle, rich in neurofibers that are involved in correct successful scar healing. It is thought that iatrogenic myoma pseudocapsule damage alters neurotransmitter function in the repair process, with a negative effect on uterine healing. Thus, the surgical sequels of an uncorrected myomectomy is damage to the pseudocapsule neurovascular

bundle, a reduction in the presence of neurofibers at the hysterotomy site, a deterioration in uterine musculature healing, and a deficit either in myometrial neurotransmission or in muscular impulse and contractility, with a final reduction in uterine musculature functionality.

There are many issues with modern-day myomectomy. One of the first questions concerns the current use of techniques that minimize blood loss and occlude the uterine blood supply during myomectomy, such as tourniquet methods,<sup>47,48</sup> uterine artery embolization<sup>3,49</sup> or ligation,<sup>50</sup> intrauterine injection of ischemic solutions,<sup>51,52</sup> or gonadotrophin-releasing hormone (GnRH) analogues.<sup>48,53</sup>

All these methods reduce blood flow into the pseudocapsule, by mechanical compression (the tourniquet methods), vascular occlusion, or a pharmacological blood flow decrease.

In the authors’ opinion, the main problem with these approaches is that their use could mask the musculature vascularization for vessel collapse, making selective and gentle pseudocapsule vessel hemostasis difficult during myomectomy and favoring successive intramyometrial hematomas, detected by ultrasound,<sup>54,55</sup> with impairment of the muscular healing at the hysterotomy site. On the contrary, during surgery, the fibroid pseudocapsule neurovascular bundle needs to be well exposed, by endoscopic magnification, and carefully protected, avoiding destructive procedures, such as large-scale diathermocoagulation at high wattage, favoring incorrect restoration of the uterine musculature.

Analyzing the literature on ischemic solutions to inject into the myometrium,<sup>52</sup> studies show that vasopressin decreases blood loss at the time of myomectomy by laparotomy compared with placebo or a tourniquet. On the other hand, other studies have found no difference between the use of vasopressin or a tourniquet at myomectomy performed by laparotomy.<sup>52</sup> In clinical practice, probably either technique will decrease blood loss compared with no intervention, so the greater magnification afforded by the laparoscope may allow for more precise treatment of blood vessels. In addition, the CO<sub>2</sub> pneumoperitoneum associated with laparoscopy may tamponade small vessels and, cumulatively, result in less blood loss.

Vasopressin injection unfortunately has been reported to cause pulmonary edema and, with intravenous injection, even death, while loop ligation may ultimately compromise uterine function and may reduce fertility or increase complications during pregnancy.<sup>50</sup>

Moreover, the exclusion of preoperative GnRH-analogue treatment is due to the reported increased risk of fibroid recurrence, a possible delay in the diagnosis of leiomyosarcoma, a risk of massive hemorrhage from degeneration,<sup>56</sup> and, primarily, to avoid distortion of the myoma pseudocapsule. The GnRH-analogue treatment decreases the size of the myoma, causing confluent nodular hyaline degeneration and hydropic degeneration necrosis, masking the correct cleavage plan between myoma and pseudocapsule and making myoma hooking difficult.<sup>57</sup> For this reason, the use of ischemic solutions and GnRH-analogues before surgery is useless and may even be harmful.

It is likely that the suturing technique is of secondary importance when an intracapsular myomectomy is performed well. The problem with stitches has never been approached properly with regards to the myomectomy, because of the lack of a well-stated scientific rationale. As reported in many articles,<sup>6,37–40,43</sup> the myoma pseudocapsule is a fibro neurovascular structure, a neurovascular bundle, probably created by the uterus to cope with the development and growth of fibroids. When the surgeon gently removes a myoma through the pseudocapsule, he or she preserves the muscle surrounding the myoma, returning it to normal healthy uterine tissue. The same thing happens in the lower uterine segment during pregnancy: after delivery, it disappears. For these reasons, the hysterotomy after intracapsular myomectomy needs to be closed by simply introflecting muscle edges in 1 or 2 layers. Sutures in several layers are not necessary. More suture serves as a foreign body to produce inflammatory reactions, submesothelial fibrosis, and regenerative mesothelial hyperplasia.<sup>58</sup> Intracapsular fibroid removal, which spares neurovascular fibers and neuropeptides, helps preserve uterine muscle that is not traumatized and ready for proper healing. And, if the myoma is enucleated entirely through the fibrovascular capsule opening, using blunt or sharp dissection on the surrounding myometrium, with a gentle selective low energy hemostasis on pseudocapsule vessels, the myometrial bed collapses without excessive bleeding once the myoma is removed. This is the rationale for not putting too much importance on suturing technique. Technique itself that preserves myometrial integrity and allows the restoration of uterine musculature with magnification of the pseudocapsule neurovascular bundle using laparoscopy or robotic-assisted surgery is a sort of endoscopic tailored microsurgery.

The neurovascular bundle surrounding the prostate is rich in neurotransmitters and needs to be preserved during radical prostatectomy to maintain urinary and sexual func-

tion. The uterine leiomyoma pseudocapsule has a neurovascular bundle rich in neurofibers and neuropeptides. Intracapsular myomectomy respects the leiomyoma pseudocapsule, permits better healing of the uterine scar, leading to neurotransmitter sparing at the myomectomy site, which is extremely important for successive reproductive functionality of the uterine musculature.

### NEED OF FUTURE RESEARCH

Much still needs to be learned concerning the presence of neuropeptides and neurotransmitter activity in the neurovascular bundle of fibroid pseudocapsules in each part of the uterus, the body, the isthmus, and cervix. Studies are also needed of pseudocapsule anomalous vascularization, which is similar to malignant neoplastic tissue vessels present in malignant tumors. More research needs to be directed at the impact of hormonal patterns on the origin, growth, and recurrence of the fibroid pseudocapsule, the influence of drugs, embolospheres, and magnetic resonance-guided focused ultrasound on the pseudocapsule and their effects on uterine healing. Increasing knowledge of pseudocapsule angiogenesis and neurovascular fibers could play an important role in understanding the origin, recurrence, and correct treatment of uterine leiomyomas. Therefore, more research is needed in both fertile and postmenopausal patients to demonstrate the anatomic pattern, fibroid behavior, and the involvement of the pseudocapsule in a hormonal environment. What has been said should stimulate research on the influence of angiogenic growth factors on fibroid pseudocapsule and on the neuroanatomical significance of the fibroid pseudocapsule, to explain the pathobiology of fibroid and pseudocapsule formation, the hormonal influence on pseudocapsule growth and neurovascular development, and the pseudocapsule during the postoperative course. This study suggests the need for further investigation of the fibroid pseudocapsule and its neurovascular bundle to determine the role of the myoma pseudocapsule in the formation, growth, and pathophysiologic consequences of uterine fibroids including pain, infertility, and poor reproductive outcomes.

### CONCLUSION

In recent years, new advancements in endoscopic surgery, including the use of laparoscopic or robotic surgery in fibroid removal, have been considered a true alternative to laparotomy with numerous advantages, such as short hospitalization, decreased need for postoperative analgesia, less intraoperative blood loss, and good outcomes in subsequent pregnancy.<sup>59</sup> Recent evidence on neurofibers and neuropep-



tides in the fibroid pseudocapsule suggests a new horizon in endoscopic gynecological surgery, which can be called intracapsular fibroid nerve-sparing laparoscopic “microsurgery,” or intracapsular fibroid nerve-sparing robotic-assisted “nanosurgery,” in case of robotic magnification. A great advantage of intracapsular laparoscopic myomectomy is the reproducibility of its application for all laparoscopic myomectomies as a safe, feasible, and minimally invasive technique. Intracapsular myomectomy enhances myometrium integrity peripheral to the fibroid site, by preserving the neurovascular bundle and neurotransmitters surrounding fibroids, for uterine healing and restoration of the myometrium after surgery. Moreover, allowing correct myometrial healing, intracapsular myomectomy should preserve reproductive outcomes and normal labor and delivery, for less bleeding, better neurovascular bundle sparing for scar quality, and postoperative adhesion reduction. The authors propose that their intracapsular myomectomy should always be recommended to maximize the potential for future fertility and to minimize the risk of labor dystocia or uterine rupture during pregnancy or labor.

## References:

1. Lethaby A, Vollenhoven B. Fibroids (uterine myomatosis, leiomyomas). *Clin Evid (Online)*. 2011;pii:0814.
2. Mettler L, Schollmeyer T, Tinelli A, Malvasi A, Alkatout I. Complications of uterine fibroids and their management, surgical management of fibroids, laparoscopy and hysteroscopy versus hysterectomy, haemorrhage, adhesions and complications. *Obstet Gynecol Int*. 2012; Article ID 791248 doi:10.1155/2012/791248.
3. Stovall DW. Alternatives to hysterectomy: focus on global endometrial ablation, uterine fibroid embolization, and magnetic resonance-guided focused ultrasound. *Menopause*. 2011;18(4):443–450.
4. Sami Walid M, Heaton RL. The role of laparoscopic myomectomy in the management of uterine fibroids. *Curr Opin Obstet Gynecol*. 2011;23:273–277.
5. Mais V, Ajossa S, Guerriero S, Mascia M, Solla E, Melis GB. Laparoscopic versus abdominal myomectomy. A prospective, randomized trial to evaluate benefits in early outcome. *Am J Obstet Gynecol*. 1996;174:654–658.
6. Tinelli A, Malvasi A, Rahimi S, et al. Myoma pseudocapsule: a new-old endocrino-anatomical entity to exploit in uterine myomectomy. *Gynecol Endocrinol*. 2009;25(10):661–667.
7. Ito F, Kawamura N, Ichimura T, Tsujimura A, Ishiko O, Ogita S. Ultrastructural comparison of uterine leiomyoma cells from the same myoma nodule before and after gonadotropin-releasing hormone agonist treatment. *Fertil Steril*. 2001;75:125–130.
8. Dapunt O. Studies on the structure of the myoma capsule. *Arch Gynecol*. 1965;202:492–494.
9. Fox H, Buckley CH. Benign neoplasms of the female genital tract. In: *Pathology for Gynaecologists*. Arnold ed. London, UK, 1982;8:91–97.
10. Vizza E, Motta PM. The skeleton fibrous and muscular of the uterus. In: *Atti LXXVII Congresso SIGO*. Rome: CIC Int Ed, 2001; 47–49.
11. Hsu WC, Hwang JS, Chang WC, Huang SC, Sheu BC, Torng PL. Prediction of operation time for laparoscopic myomectomy by ultrasound measurements. *Surg Endosc*. 2007;21(9):1600–1606.
12. Awataguchi K. Studies on the angioarchitecture of uterine myoma. *Nippon Ika Daigaku Zasshi*. 1982;49:225–232.
13. Stewart EA, Nowak RA. Leiomyoma-related bleeding: a classic hypothesis updated for the molecular era. *Hum Reprod Update* 1996;2(4):295–306.
14. Yucel S, Erdogru T, Baykara M. Recent neuroanatomical studies on the neurovascular bundle of the prostate and cavernosal nerves: clinical reflections on radical prostatectomy. *Asian J Androl*. 2005;7(4):339–349.
15. Takenaka A, Murakami G, Soga H, Han SH, Arai Y, Fujisawa M. Anatomical analysis of the neurovascular bundle supplying penile cavernous tissue to ensure a reliable nerve graft after radical prostatectomy. *J Urol*. 2004;172(3):1032–1035.
16. Costello AJ, Brooks M, Cole OJ. Anatomical studies of the neurovascular bundle and cavernosal nerves. *BJU Int*. 2004; 94(7):1071–1076.
17. Walsh PC. The discovery of the cavernous nerves and development of nerve sparing radical retropubic prostatectomy. *J Urol*. 2007;177(5):1632–1635.
18. Hernandez DJ, Epstein JI, Trock BJ, Tsuzuki T, Carter HB, Walsh PC. Radical retropubic prostatectomy. How often do experienced surgeons have positive surgical margins when there is extraprostatic extension in the region of the neurovascular bundle? *J Urol*. 2005;173(2):446–449.
19. Shah SJ, Goyal V, Sachar R, Nath AK, Jain N, Kapadia K. Seminal vesicle sparing laparoscopic radical prostatectomy using a low-energy source: Better continence and potency. *Indian J Urol*. 2009;25(2):199–202.
20. Han M, Kim C, Mozer P, et al. Tandem-robot assisted laparoscopic radical prostatectomy to improve the neurovascular bundle visualization: a feasibility study. *Urology*. 2011;77(2):502–506.
21. Walz J, Burnett AL, Costello AJ, et al. A critical analysis of the current knowledge of surgical anatomy related to optimization of

cancer control and preservation of continence and erection in candidates for radical prostatectomy. *Eur Urol.* 2010;57(2):179–192.

22. Lee SE, Hong SK, Han JH, et al. Significance of neurovascular bundle formation observed on preoperative magnetic resonance imaging regarding postoperative erectile function after nerve-sparing radical retropubic prostatectomy. *Urology.* 2007;69(3):510–514.

23. Tinelli A, Hurst BS, Hudelist G, Tsin DA, Stark M, Mettler L, Guido M, Malvasi A. Laparoscopic myomectomy focusing on the myoma pseudocapsule: technical and outcome reports. *Hum Reprod.* 2012;27(2):427–35.

24. Ukimura O, Gill IS. Real-time transrectal ultrasound guidance during nerve sparing laparoscopic radical prostatectomy: pictorial essay. *J Urol.* 2006;175(4):1311–1319.

25. Pasetto N, Baschieri L, Giacomello F, Ticconi C. Patologia benigna dell'utero. In: Candiani GB, Danesino V, Gastaldi C. *La Clinica Ostetrica e Ginecologica.* Milan, Italy; Masson Editore. 1992;1242–1256.

26. Faulkner RL. The blood vessels of the myomatous uteri. *Am J Obstet Gynaecol.* 1944;47:185–197.

27. Farrer-Brown G, Beilby JOW, Tarbit MH. The vascular patterns in myomatous uteri. *J Obstet Gynaecol.* 1970;77:967–975.

28. Casey R, Rogers PA, Vollenhoven BJ. An immunohistochemical analysis of fibroid vasculature. *Hum Reprod.* 2000;15(7):1469–1475.

29. Campo S, Garcea N. Laparoscopic myomectomy in premenopausal women with and without preoperative treatment using gonadotrophin-releasing hormone analogues. *Hum Reprod.* 1999;14:44–48.

30. Lethaby A, Vollenhoven B, Sowter M. Pre-operative Gn-RH analogue therapy before hysterectomy or myomectomy for uterine fibroids. *Cochrane Database Syst Rev.* 2001;2:CD000547.

31. Pinkerton JV. Pharmacological therapy for abnormal uterine bleeding. *Menopause.* 2011;18(4):459–467.

32. Walocha JA, Litwin JA, Miodonski A. Vascular system of intramural leiomyomata revealed by corrosion casting and scanning electron microscopy. *Human Reprod.* 2003;18:1088–1093.

33. Forssman L. Blood flow in myomatous uteri as measured by intraarterial 133-Xenon. *Acta Obstet Gynecol Scand.* 1976;55:21–24.

34. Hanna KR, Katz AJ. An update on wound healing and the nervous system. *Ann Plast Surg.* 2011;67(1):49–52.

35. Henderson J, Terenghi G, Ferguson MW. The reinnervation and revascularisation pattern of scarless murine fetal wounds. *J Anat.* 2011;218(6):660–667.

36. Gouin JP, Carter CS, Pournajafi-Nazarloo H, et al. Marital behavior, oxytocin, vasopressin, and wound healing. *Psychoneuroendocrinology.* 2010;35(7):1082–1090.

37. Mettler L, Tinelli A, Hurst BS, et al. Neurovascular bundle in fibroid pseudocapsule and its neuroendocrinologic implications. *Expert Rev Endocrinol Metab.* 2011;6:715–722.

38. Malvasi A, Tinelli A, Cavallotti C, et al. Distribution of Substance P (SP) and Vasoactive Intestinal Peptide (VIP) neuropeptides in pseudocapsules of uterine fibroids. *Peptides.* 2011;32(2):327–332.

39. Tinelli A, Malvasi A, Hudelist G, et al. Laparoscopic intracapsular myomectomy: comparison of single versus multiple fibroids removal. An institutional experience. *J Laparoendosc Adv Surg Tech A.* 2010;20(8):705–711.

40. Malvasi A, Tinelli A, Rahimi S, et al. A three-dimensional morphological reconstruction of uterine leiomyoma pseudocapsule vasculature by the Allen-Cahn mathematical model. *Biomed Pharmacother.* 2011;65(5):359–363.

41. Vikhareva Osser O, Valentin L. Risk factors for incomplete healing of the uterine incision after caesarean section. *BJOG.* 2010;117(9):1119–1126.

42. Kubinova K, Mara M, Horak P, Kuzel D, Dohnalova A. Reproduction after myomectomy: Comparison of patients with and without second-look laparoscopy. *Minim Invasive Ther Allied Technol.* 2011 Jul 11. [Epub ahead of print]

43. Tinelli A, Malvasi A, Guido M, et al. Adhesions formation after intracapsular myomectomy with or without adhesion barrier. *Fertil Steril.* 2011;95(5):1780–1785.

44. Quinn MJ, Kirk N. Differences in uterine innervation at hysterectomy. *Am J Obstet Gynecol.* 2002;187(6):1515–1520.

45. Masterson TA, Serio AM, Mulhall JP, Vickers AJ, Eastham JA. Modified technique for neurovascular bundle preservation during radical prostatectomy: association between technique and recovery of erectile function. *BJU Int.* 2008;101(10):1217–1222.

46. Hurst BS, Matthews ML, Marshburn PB. Laparoscopic myomectomy for symptomatic uterine myomas. *Fertil Steril.* 2005;83(1):1–23.

47. Ikechebelu JI, Ezeama CO, Obiechina NJ. The use of tourniquet to reduce blood loss at myomectomy. *Niger J Clin Pract.* 2010;13(2):154–158.

48. Al-Shabibi N, Chapman L, Madari S, Papadimitriou A, Papalampros P, Magos A. Prospective randomised trial comparing gonadotrophin-releasing hormone analogues with triple tourniquets at open myomectomy. *BJOG.* 2009;116(5):681–687.

49. Malartic C, Morel O, Fargeaudou Y, et al. Conservative two-step procedure including uterine artery embolization with embosphere and surgical myomectomy for the treatment of multiple fibroids: Preliminary experience. *Eur J Radiol.* 2012;81:1–5.

50. Chang WC, Chou LY, Chang DY, et al. Simultaneous laparoscopic uterine artery ligation and laparoscopic myomectomy for symptomatic uterine myomas with and without in situ morcellation. *Hum Reprod.* 2011;26(7):1735–1740.
51. Riess ML, Ulrichs JG, Pagel PS, Woehlck HJ. Severe vasospasm mimics hypotension after high-dose intrauterine vasopressin. *Anesth Analg.* 2011;113:1103–1105.
52. Frishman GN, Jurema MW. Myomas and myomectomy. *J Minimal Invasive Gynecol.* 2005;12:443–456.
53. Chen I, Motan T, Kiddoo D. Gonadotropin-releasing hormone agonist in laparoscopic myomectomy: systematic review and meta-analysis of randomized controlled trials. *J Minim Invasive Gynecol.* 2011;18(3):303–309.
54. Seiner P, Gaglioti P, Volpi E, Cau MA, Todros T. Ultrasound evaluation of uterine wound healing following laparoscopic myomectomy: preliminary results. *Hum Reprod.* 1999;14(10):2460–2463.
55. Chang WC, Chang DY, Huang SC, et al. Use of three-dimensional ultrasonography in the evaluation of uterine perfusion and healing after laparoscopic myomectomy. *Fertil Steril.* 2009;92(3):1110–1115.
56. Sankaran S, Manyonda IT. Medical management of fibroids. *Best Pract Res Clin Obstet Gynaecol.* 2008;22(4):655–676.
57. De Falco M, Staibano S, Mascolo M, et al. Leiomyoma pseudocapsule after pre-surgical treatment with gonadotropin-releasing hormone agonists: relationship between clinical features and immunohistochemical changes. *Eur J Obstet Gynecol Reprod Biol.* 2009;144(1):44–47.
58. Malvasi A, Tinelli A, Farine D, et al. Effects of visceral peritoneal closure on scar formation at cesarean delivery. *Int J Gynaecol Obstet.* 2009;105(2):131–135.
59. Munro MG, Critchley HO, Fraser IS. Outcomes from leiomyoma therapies: comparison with normal controls. *Obstet Gynecol.* 2011;117(4):987, author reply 987–988.