

Skin, a mirror reflecting diabetes mellitus: A longitudinal study in a tertiary care hospital in Gujarat

Roshni Vahora, Sejal Thakkar, Yogesh Marfatia

Department of Dermatology, Medical College and SSG Hospital, Vadodara, Gujarat, India

ABSTRACT

Context: Diabetes mellitus (DM) is the most common of the endocrine disorders. Mucocutaneous manifestations of diabetes mellitus are many and vary from trivial to life-threatening. Sometimes, mucocutaneous disorders may herald the onset of diabetes. **Aims:** To study the pattern of mucocutaneous manifestations in diabetics and role of it in diagnosing diabetes mellitus and its complications. **Settings and Design:** It was a longitudinal observational study of patients having diabetes with skin complaints attending skin outdoor department or admitted in wards for any reason in a tertiary care hospital. **Materials and Methods:** Total 300 patients were included in the study. Detailed history, clinical examination, and relevant investigations were done to diagnose the mucocutaneous disorders, diabetes, and diabetic complications. **Statistical Analysis Used:** The data was analyzed by using Epi info software. **Results:** Demographic profile shown majority of cases (78.66%) in more than 40 years of age with almost equal male and female preponderance. Mucocutaneous manifestations as presenting feature of diabetes were observed in 21.67% cases. Infections were most common in 119 (39.66%) cases, followed by acanthosis nigricans in 46 (15.33%) cases. Various associated complications like hypertension, retinopathy, hyperlipidemia, coronary artery disease, neuropathy, nephropathy, and diabetic ketoacidosis were observed in 160 (53.3%). **Conclusions:** Skin is the mirror, which reflects internal diseases; this aptly applies to skin and diabetes mellitus. Through awareness about cutaneous manifestations of DM, dermatologist can not only take credit for detecting DM but also facilitate early diagnosis of systemic complications of DM. This is immensely beneficial to patients in long run.

Key words: Mucocutaneous manifestations, diabetes mellitus skin- the mirror

INTRODUCTION

Diabetes mellitus (DM) is the most common of the endocrine disorders. The International Diabetes Federation (IDF) estimates the total number of diabetic subjects to be around 40.9 million in India, and this is further set to rise to 69.9 million by the year 2025.^[1]

Mucocutaneous manifestations are frequent in the DM. Sometimes, mucocutaneous disorders may herald the onset of DM. Without control of DM, mucocutaneous conditions have vulnerability to be recalcitrant. If mucocutaneous manifestations are not treated properly, sometimes the diabetes may become aggravated and uncontrollable. Therefore, proper treatment of skin manifestation is important for control of diabetes mellitus and while treating the skin manifestation, control of diabetes mellitus is important. Gilgor and Lazarus observed that at least 30% of patients with DM have some type of cutaneous involvement during the course of their chronic disease.^[2] This study was designed to know the pattern of mucocutaneous manifestations in diabetics and role of it in diagnosing diabetes mellitus and its complications.

Access this article online

Quick Response Code:



Website:
www.ijem.in

DOI:
10.4103/2230-8210.113757

Corresponding Author: Dr. Sejal Thakkar, 202, Wings Ville, 41, Arunoday Society, Alkapuri, Vadodara - 390 007, Gujarat, India.
E-mail: drsejal98@gmail.com

MATERIALS AND METHODS

The present study was a longitudinal observational study performed in a tertiary care hospital. Three hundred cases attending skin outdoor department or admitted in the wards for any reason having diabetes with skin complaints were enrolled in the study during the period of July 2005 to October 2007. Institutional ethical clearance was obtained before the start of the study. Pre-designed and pretested proforma was filled after taking informed consent. Privacy and confidentiality was maintained. Patients presenting with skin manifestations known to be associated with DM were subjected to investigation and if turned to be diabetic (FBS > 126 mg/dl and PP₂BS > 200 mg/dl), were also included in the study. Detailed histories regarding skin complaints, DM, and treatment/family history of DM were taken. The history of hypertension, ischemic heart disease, thyroid diseases, and hyperlipidemia were also asked for. Medical records were reviewed for information of duration, medications, and complications of diabetes. Information was recorded using semi-structured questionnaire guidelines by using local vernacular language. All cases were subjected to thorough cutaneous and mucosal examination. They were screened for cutaneous diseases with known/postulated/without a clear pathogenesis as well as with complications and treatment of DM.

Cases were subjected to baseline investigations like complete blood count, urine examination, fasting and post-prandial blood sugar levels, dilated fundus examination. Thyroid function test, lipid profile, and renal function tests were carried out as and when required. Relevant microbiological and histopathological investigations were done when indicated. Patients were treated accordingly. All patients were called for follow-up weekly till satisfactory improvement was achieved.

The data collected into the computer and analyzed using Epi info software.

RESULTS

Epidemiological profile revealed almost equal incidence in males and females (51% and 49%, respectively) with 51.25 ± 14.42 (mean \pm SD) years of age. Majority of cases (54.66%) were in the age group of more than 40 years, 21% were of type 1 DM, while 79% were of type 2 DM. The mean duration of DM was 7.34 ± 2.88 years. Majority (62.33%) had the duration of DM less than 6 years. In 83.7% of patients, the duration of diabetes was <10 years. Uncontrolled diabetes was seen in 55% of cases. Sixty-five (21.67%) cases presenting with mucocutaneous lesions were found to have diabetes

on investigations; [Table 1] amongst which, eight cases were of balanoposthitis. [Figure 1] Seventeen (17%) cases were having glucocorticoid induced DM, as they were on glucocorticoid for longer duration for underlying dermatological condition.

One hundred and sixty-six (55.3%) patients presented with single cutaneous manifestation, while more than one finding were seen in 134 (44.7%) patients.

One hundred and seventy-seven (59%) patients presented with cutaneous manifestations of known/postulated pathogenesis. Cutaneous infections comprised the largest group affecting 119 (39.66%) cases. Acanthosis nigricans (AN) was the second most common condition seen in 46 (15.33%) cases. [Figure 2] Xanthelasma was seen in six (2%) cases. Diabetic ulcers were present in four (1.33%) cases, from which 75% cases were of type 1 with uncontrolled blood sugar levels. Scleredema diabeticorum was noted over back and shoulders in two cases [Table 2].

In the group of patients with manifestations of diseases without clear pathogenesis, seven (2.33%) cases were of diabetic dermopathy (DD), in which 57.1% had associated retinopathy and 42.9% had hypertension. Out of eight cases of acquired perforating dermatosis (APD), 25% cases were freshly diagnosed DM and 25% had nephropathy. They had mean duration of diabetes of 9.8 years. Out of two cases of diabetic bullae, 1 had hypertension. Single case was found with granuloma annulare along with DM.

Among the cutaneous manifestations known to be associated with DM (30.6%), skin tags were observed in maximum cases (13.33%) followed by dryness (5.66%), lichen planus (LP) (4%), and vitiligo (3.33%). Out of 12 cases of LP, one case had triad of oral LP, diabetes, and hypertension, which is named as Grinspan's syndrome. Six cases had cherry angiomas, three had generalized pruritus, and one case presented with pigmented purpuric dermatoses. Rubeosis faciei was present in two cases.

Complication due to anti-diabetic treatment was

Table 1: Demographic profile

Characteristics	No.	Percentage
Total patients	300	100
Males	153	51
Females	147	49
Uncontrolled diabetes	165	55
Freshly detected diabetes	65	21.7
Age (years) (mean+standard deviation)	51.25 \pm 14.42	
Duration of diabetes (years)	7.3 \pm 2.88	

Table 2: Cutaneous manifestations of DM (n=300)*

Cutaneous manifestations	No. of cases (%)
With known/postulated pathogenesis	177 (59)
Cutaneous infections	119 (39.66)
Acanthosis nigricans	46 (15.33)
Scleredema diabeticorum	02 (0.66)
Diabetic ulcer	04 (1.33)
Xanthelasma	06 (2)
Without a clear pathogenesis	18 (6)
Diabetic dermopathy	07 (2.33)
Diabetic bullae	02 (0.66)
Acquired perforating dermatoses	08 (2.66)
Granuloma annulare	01 (0.33)
Known to be associated with DM	92 (30.6)
Skin tags	40 (13.33)
Rubeosis faciei	02 (0.66)
Pigmented purpuric dermatoses	01 (0.33)
Lichen planus	12 (4)
Vitiligo	10 (3.33)
Cherry angiomas	06 (2)
Dryness (xerosis)	17 (5.66)
Generalized pruritus	03 (1)
Bullous pemphigoid	01 (0.33)
Complication with anti-diabetics	5 (1.66)
Oral hypoglycemic agents	01 (0.33)
Insulin	04 (1.33)
Other cutaneous findings	94 (31.33)
Achard thiers syndrome	01 (0.33)
Eczema/dermatitis	46 (15.33)
Immunobullous diseases	18 (6)
Psoriasis	10 (3.33)
Urticaria	08 (2.66)
Cutaneous amyloidosis	06 (2)
LSA	01 (0.33)
Callosity	03 (1)
IGH	01 (0.33)

*Multiple responses, DM: Diabetes mellitus, LSA: Lichen Sclerosus et Atrophicus, IGH: Idiopathic Guttate Hypomelanosis

observed in 5 (1.66%) cases in form of photosensitivity (Sulfonylurea-induced), lipodystrophy and hyperpigmentation (with insulin injection).

From the miscellaneous group, 46 (15.3%) cases of eczema had associated DM. Ten cases (3.33%) were presented with psoriasis. Cutaneous amyloidosis was seen in six cases.

One case of Achard-Thiers syndrome (diabetic bearded woman) was noted in post-menopausal woman with type 2 DM, androgenetic alopecia, and hirsutism [Figure 3].

Seventeen cases were on long-term steroids for underlying dermatological conditions, and they were subjected to investigations and turned out to have DM.

One hundred and sixty patients (53.3%) showed one or the other systemic complication along with DM and cutaneous manifestation. Hypertension was the commonest (66.8%) complication followed by retinopathy (11.87%), hyperlipidemia (8.12%), coronary artery disease (6.25%),

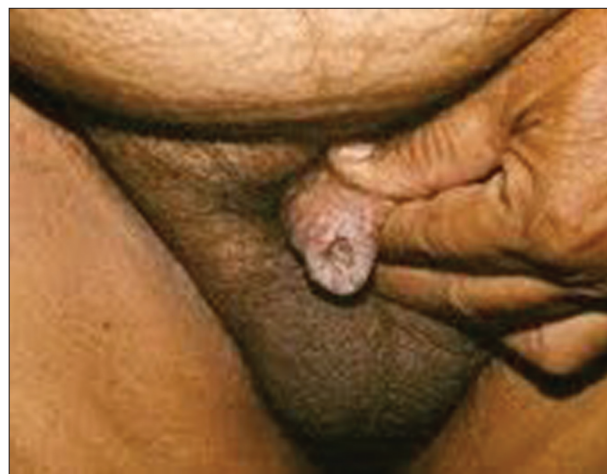

Figure 1: Balanoposthitis

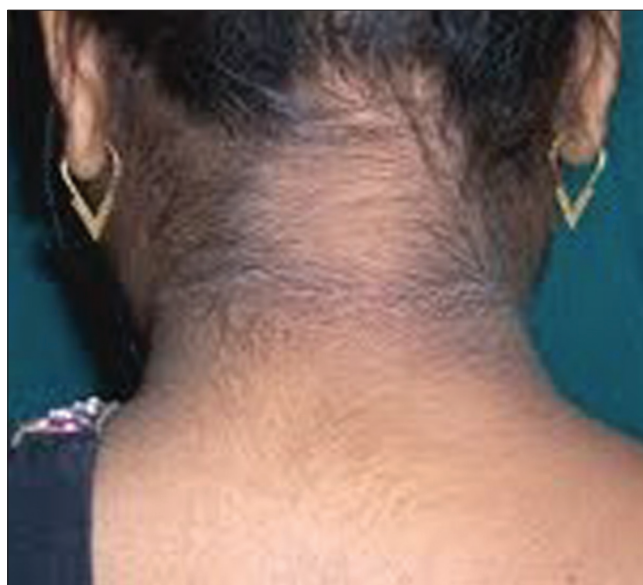

Figure 2: Acanthosis nigricans

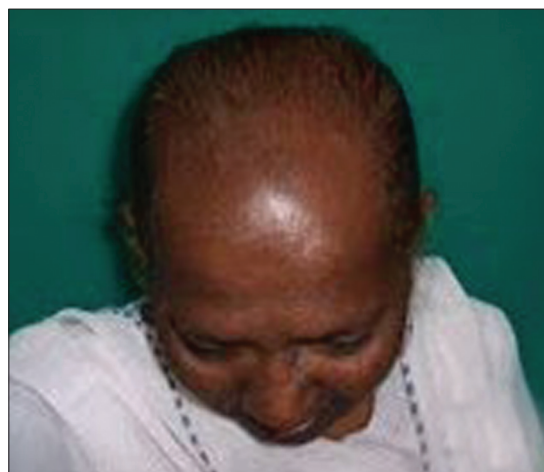


Figure 3: Achard-Thiers syndrome

neuropathy (3.12%), nephropathy (2.5%), and diabetic ketoacidosis (1.25%).

DISCUSSION

Diabetes in long run is associated with multiple degenerative alterations that affect the cardiovascular system, the central as well as peripheral nervous system, the eyes, and the skin. The effects upon the blood vessels are the cardinal pathological factors. The cutaneous complications associated with this disease are worth been studied by physicians because of their numerous and complicated repercussions. The cutaneous manifestations are classified into different categories as with known/postulated pathogenesis, without a clear pathogenesis, known to be associated with DM, with diabetic treatment and other cutaneous findings. Chronicity of the diabetes plays a big role in cutaneous manifestations. In present study, 83.7% of the patients had duration of less than 10 years. Similar observation were reported by Bhat *et al.*,^[3] Dogra *et al.*,^[4] and Rao and Pai *et al.*^[5] Uncontrolled diabetes increases the risk of development of microangiopathy and related complications or sequel. Uncontrolled diabetes was seen in 55% of cases as was found by Bhat *et al.*,^[3] Yosipovitch *et al.*,^[6] and Sawhney *et al.*^[7]

Cutaneous manifestations may serve as a marker of DM. They were observed as presenting feature of DM in 65 (21.67%) patients. Out of them, 16 (24.61%) patients had infections. Diabetes was diagnosed due to balanoposthitis in eight cases and vulvovaginitis in one case. As such candidial balanitis, balanoposthitis, and phimosis are much less common than candidial infections in women, but may be a presenting manifestation of DM in men. Fifteen (23%) patients with AN found diabetics on investigations. Seven cases with isolated finding of AN were newly diagnosed as a result of more awareness regarding its presence in metabolic disorders. Two cases of APD were newly diagnosed in present study. Seventeen cases were on long-term steroids for underlying dermatological conditions, and they were subjected to investigations and turned out to have DM. In study by Rao and Pai *et al.*,^[5] there were 19.32% newly diagnosed and 80.69% were known diabetics, and in study by Al-Mutairi *et al.*,^[8] 17% were newly diagnosed and 83% were known diabetics. Therefore, the knowledge and awareness of mucocutaneous manifestations of DM is very important.

The most common manifestation observed in present study was cutaneous infections (39.66%), similar to Mahajan *et al.*^[9] and Nigam *et al.*^[10] It is well-known that diabetic patients are susceptible to infections, probably due to hyperglycemia and defects in polymorphonuclear leukocyte function. Surprisingly, viral (herpes zoster, wart) and parasitic infections (scabies) in diabetic patients have not

been reported in previous studies while it is seen in present study in nine and seven cases, respectively. Dermatophyte infection was the most common (37.16%) followed by bacterial infection (33.78%), candida (22.97%), and viral (6.08%). Mahajan^[9] and Al-Mutairi^[8] reported bacterial infection as more common than dermatophytes, candida, and viral. As shown previously, cutaneous infections work as an important marker to diagnose DM.

Amongst 46 cases of AN, 31 (67.39%) patients were known diabetics with or without other cutaneous manifestations. Rest of the 15 (32.61%) were freshly detected cases. AN was reported in 5%, 5.3% of cases in Raghunatha *et al.*^[11] and Bhat *et al.*^[3] studies, respectively. Varthakavi *et al.*^[12] reported that 22.2% of patients with AN are overtly diabetic while glucose tolerance ranged from normal in 55.6% to impaired in 22.2% patients with AN. The first major breakthrough association of AN with insulin resistance (which may be present before the expression of DM) came from a study by Kahn.^[13] There have been suggestions that insulin at high concentrations may stimulate insulin-like growth factor receptors on keratinocytes, thereby promoting epidermal cell proliferation. So, every patient of AN should be investigated for DM, and every patient of DM should be screened for AN.

In present study, amongst eight cases of APD, two had nephropathy. Joseph *et al.*^[14] reported that 14 (66.6%) out of 21 patients of Kyrle's disease had diabetes mellitus with a mean duration of 7-10 years. Amongst them, 12 (85.7%) had some form of renal involvement (nephropathy). Six patients (50%) had overt renal failure.

Out of four cases of diabetic ulcer, three are of type 1 with uncontrolled blood sugar levels. Scleredema diabeticorum was noted over back and shoulders in two of type 1 patients.

Out of seven cases of diabetic dermaopathy, 57% (4) had associated retinopathy and 43% (3) had hypertension, while Sawhney *et al.*^[7] reported that 33.3% of patients of dermopathy with retinopathy. Out of two cases of diabetic bulla, one had hypertension.

In present study, 13.3% diabetics had skin tags. Bhargava *et al.*^[15] reported skin tags in 20% patients of overt DM, whereas impaired GTT was found in 8% patients. Acrochordon is regarded as a sign of impaired glucose tolerance, DM, and increased cardiovascular (atherogenic lipid profile) risk.^[16] Skin tag may serve as a marker of DM in compared to 4% of LP cases. Kachhawa *et al.*^[17] reported that LP was associated with 1.6% cases of DM. Dhar *et al.*^[18] reported one case of Grinspan's syndrome as similar to present study. Dermatoses with underlying

autoimmune pathogenesis like vitiligo are known to occur in DM as a part of polyglandular autoimmune syndrome. The occurrence of non-specific cutaneous disorders also has pathogenetic, prognostic, and therapeutic importance in diabetic patients. Autonomic neuropathy has been attributed to the pathogenesis of ichthyosis, xerosis, and pruritus. Rubeosis is more prominent in fair-skinned people. In our study, two patients had rubeosis and none of them had associated systemic complications like hypertension, retinopathy, or neuropathy.

Complications with anti-diabetic treatment were seen in 1.66% of patients. Mahajan *et al.*^[9] reported complication due to anti-diabetic treatment in 4.69% cases. Bhat *et al.*^[3] reported complication due to oral hypoglycemic agent in 2 (2.02%) cases and to insulin in 3 (3.03%) cases.

Achard-Thiers syndrome (diabetic bearded woman) was noted in post-menopausal woman with type 2 DM, androgenetic alopecia, and hirsutism [Figure 3]. Radhu TY^[19] reported two cases of Achard Thiers Syndrome.

Sezai *et al.*^[20] reported psoriasis co-existed with type 2 DM in 11.2% cases. There are reports of a significant association of DM and psoriasis in a large series of patients with psoriasis.^[21,22] According to Avci *et al.*,^[21] individuation of the various hues of erythema in psoriatics by careful dermatological examination or routine measurements of lesional erythema may alert the physician to possible impaired glucose tolerance in the presenting subject, and this may affect disease severity. An association between psoriasis and increased cardiovascular risk and metabolic syndrome has been reported. While treating psoriasis patients, screening for metabolic syndrome and cardiovascular risk factors is advised. Eczema/dermatitis was seen in 46 (15.33%) cases while similar finding observed by Sezai *et al.*^[20]

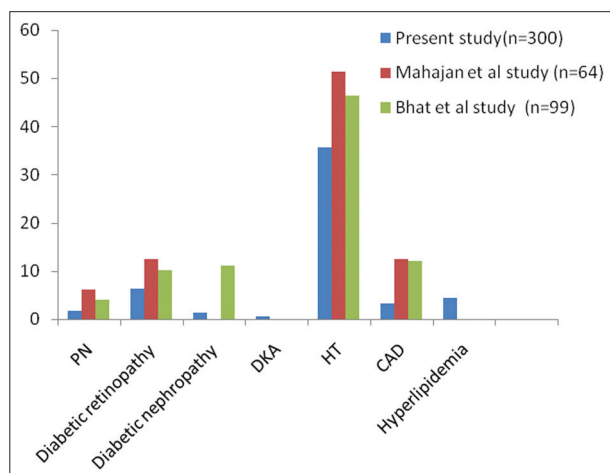


Figure 4: Complications of diabetes

Neither of the eruptive xanthoma, necrobiosis lipodicans nor waxy skin and stiff joint case was found in our study.

Various cutaneous disorders are related to diabetic complications such as microangiopathy (diabetic dermopathy, rubeosis faciei, and diabetic bullae), glycosylation of proteins (diabetic thick skin), neuropathy (diabetic foot), immunologic dysfunction (infections), insulin resistance (acanthosis nigricans), and abnormal lipid metabolism (xanthoma).

Diabetic micro- and macro angiopathies are the leading cause of morbidity and mortality amongst the diabetics. Skin manifestations of diabetic micro-angiopathy with other complications of diabetes observed in 53.3% of patients. Bhat *et al.*^[3] showed that higher percentage (87.87%) of cases with cutaneous manifestations had systemic complications like hypertension, coronary artery disease, peripheral vascular disease, nephropathy, retinopathy and neuropathy as compared to diabetic cases without cutaneous manifestations (37.24%) and Mahajan *et al.*^[9] and Schemer *et al.*^[23] reported in 89% and 55.5%, respectively. [Figure 4] Hence, the cutaneous manifestations correlate with systemic manifestations of diabetes.

A good glycemic control definitely reduces the incidence and severity of cutaneous disorders with or without known pathogenesis. Health promotion and education to control glycemia can do much to reduce the risk of these disorders. Long-term effects of DM on the microcirculation and on dermal collagen eventually result in skin disorders in almost all the diabetic patients. Thus, dermatologists play an important role in reducing the dermatologic morbidity, improvement of quality of life, and management strategy of diabetic patients.

REFERENCES

1. Sicree R, Shaw J, Zimmet P. Diabetes and impaired glucose tolerance. In: Gan D, editor. Diabetes atlas. International diabetes federation. 3rd ed. Belgium: International Diabetes Federation; 2006. p. 15-103.
2. Gilgor RS, Lazarus GS. Skin manifestations of diabetes mellitus. Diabetes mellitus. In; Rifkin H, Raskin P, editors. Louana: Brady Co; 1981. p. 313-31.
3. Bhat YJ, Gupta V, Kudiyar RP. Cutaneous manifestations of diabetes mellitus. Int J Diab Dev Ctries 2006;26:152-5.
4. Dogra S, Kumar B, Bhansali A, Chakrabarty A. Epidemiology of onychomycosis in patients with diabetes mellitus in India. Int J Dermatol 2002;41:647-51.
5. Rao GS, Pai GS. Cutaneous manifestation of diabetes mellitus. Indian J Dermatol Venereol Leprol 1997;63:232-4.
6. Yosipovitch G, Hodak E, Vardi P, Shraga I, Karp M, Sprecher E, *et al.* The prevalence of cutaneous manifestations in IDDM patients and their association with diabetes risk factors and microvascular complications. Diabetes Care 1998;21:506-9.
7. Sawhney M, Tutakne MA, Rajpathak SD, Tiwari VD. Clinical study

- of diabetic dermoangiopathy. *Indian J Dermatol Venereol Leprol* 1990;56:18-21.
8. Al-Mutairi N, Zaki A, Sharma AK, Al-Sheltawi M. Cutaneous manifestations of diabetes mellitus. *Med Princ Pract* 2006;15:427-30.
 9. Mahajan S, Karanne RV, Sharma SK. Cutaneous manifestation of diabetes mellitus. *Indian J Dermatol Venereol Leprol* 2003;69:105-8.
 10. Nigam PK, Pande S. Pattern of dermatoses in Diabetes. *Indian J Dermatol Venereol Leprol* 2003;69:83-5.
 11. Rangunatha S, Anitha B, Inamadar AC, Palit A, Devarmani SS. Cutaneous disorders in 500 diabetic patients attending diabetic clinic. *Indian J Dermatol* 2011;56:160-4.
 12. Varthakavi PK, Waingankar A, Patel KL, Wadhwa SL, Khopkar U, Sengupta RA, *et al.* Acanthosis nigricans: A dermatologic marker of metabolic disease. *Indian J Dermatol Venereol Leprol* 2002;68:67-72.
 13. Kahn CR, Flier JS, Bar RS, Archer JA, Gorden P, Martin MM, *et al.* The syndromes of insulin resistance and acanthosis nigricans: Insulin-receptor disorders in man. *N Engl J Med* 1976;294:739-45.
 14. Joseph D, Papali C, Pisharody R. Kyrle's disease: a cutaneous marker of renal disorder. *Indian J Dermatol Venereol Leprol* 1996;62:222-5.
 15. Bhargava P, Mathur D. Acrochordon, diabetes and associations. *Indian J Dermatol Venereol Leprol* 1996;62:226-8.
 16. Crook MA. Skin tags and the atherogenic lipid profile. *J Clin Pathol* 2000;53:873-4.
 17. Kachhawa D, Kachhawa V, Kalla G, Gupta L. A clinico-aetiological profile of 375 cases of lichen planus. *Indian J Dermatol Venereol Leprol* 1995;61:276-9.
 18. Dhar S, Ghosh S, Kanwar AJ, Kaur S. Grinspan's syndrome: A rare entity. *Indian J Dermatol* 1992;37:25-6.
 19. Radhu TY, Vinayak V, Garehatty RK, Banavashi SG. Study of cutaneous manifestations of diabetes mellitus. *Indian J Dermatol Venereol Leprol* 2004;49:73-5.
 20. Sasmaz S, Buyukbese MA, Cetinkaya A, Celik M, Arican O. The prevalence of skin disorders in type-2 diabetic patients. *Int J Dermatol* 2005;3:1.
 21. Avci O, Caliskan S, Caliskan M. Erythema measurements may allow early diagnosis of diabetes mellitus in adult psoriatics. *J Eur Acad Dermatol Venereol* 2003;17:280-4.
 22. Henseler T, Christophers E. Disease concomitance in psoriasis. *J Am Acad Dermatol* 1995;32:982-6.
 23. Shemer A, Bergman R, Linn S, Kantor Y, Friedman-Birnbaum R. Diabetic dermopathy and internal complications in diabetes mellitus. *Int J Dermatol* 1998;37:113-5.

Cite this article as: Vahora R, Thakkar S, Marfatia Y. Skin, a mirror reflecting diabetes mellitus: A longitudinal study in a tertiary care hospital in Gujarat. *Indian J Endocr Metab* 2013;17:659-64.

Source of Support: Nil, **Conflict of Interest:** None declared.