



Oncology

A Case Report of Giant Adrenal Ganglioneuroma



Peijie Chen^{a,b,c,1}, Canbin Lin^{a,b,c,1}, Lu Jin^{b,c}, Yu Ding^b, Jian Peng^b, Zebo Chen^b, Shangqi Yang^b, Xiangming Mao^b, Yongqing Lai^{b,*}

^aShantou University Medical College, Shantou, Guangdong, 515041, PR China

^bDepartment of Urology, Peking University Shenzhen Hospital, Shenzhen, Guangdong 518036, PR China

^cThe Guangdong and Shenzhen Key Laboratory of Male Reproductive Medicine and Genetics, Peking University Shenzhen Hospital, Institute of Urology of Shenzhen PKU-HKUST Medical Center, Shenzhen, Guangdong 518036, PR China

ARTICLE INFO

Article history:

Received 23 December 2016

Accepted 17 March 2017

Keywords:

Ganglioneuroma

Adrenal tumor

Laparoscopic adrenalectomy

ABSTRACT

Adrenal ganglioneuroma (AGN) is an extremely rare and benign entity comprising Schwann cells and ganglion cells. If the lesion approaches to 6 cm, laparoscopic resection is considered as relative contraindication. Now we present a giant adrenal AGN in a 25-year-old male patient. After abdominal computed tomography (CT) scanning, the patient underwent an exploratory laparotomy with right adrenalectomy and histopathological examination further confirmed the lesions as giant AGN, which measured 7 cm × 5 cm × 3.5 cm. Because giant AGN with lesion size greater than 6 cm should be treated by open surgery, it is significant to report the laparoscopic adrenalectomy in patients with large adrenal lesions.

© 2017 The Authors. Published by Elsevier Inc. This is an open access article under the CC BY-NC-ND license (<http://creativecommons.org/licenses/by-nc-nd/4.0/>).

Introduction

GN occurs in posterior mediastinum, retroperitoneum, adrenal glands, neck and region of the paravertebral sympathetic plexus. Adrenal ganglioneuroma (AGN) is an extremely rare and slow-growing neoplasm locating in adrenal glands, accounting for 20–30% of all GN. When the diameter of AGN reaches over 6 cm, such size will be called “giant”. Laparoscopic adrenalectomy is seldom used for large adrenal tumors because previous literature limited this approach to tumor less than 6 cm in size.¹ As the incidence of adrenal tumor increases with increasing size, laparoscopic adrenalectomy is gradually getting popularity in management of adrenal lesions. We assess the feasibility of laparoscopic resection for adrenal neoplasms more than 6 cm in size through the present study.

Case reports

In October 2013, a 23-year-old male patient was admitted to the Department of Urology of Peking University Shenzhen Hospital with a mass of the right adrenal gland that had been detected by health check for 1 month. He had no symptoms of headache,

nausea, vomiting, diarrhea, blurred vision, palpitation or chest distress, and there was no loss of appetite or weight. His past medical history includes hepatitis B. On admission, physical examination revealed that no mass in the abdomen.

A biochemical profile revealed that cortisol was 2.48 µg/dl, 23.88 µg/dl and 10.82 µg/dl at 0 h, 8 h and 16 h (normal range 0–1.54, 7.2–18.2, 2.75–6.65), fibrinogen was 1.9 g/l (2–4). Normal values included that aldosterone was 42.6 pg/ml (23.5–106.6), and ACTH was 12.6 pg/ml, 35.1 pg/ml and 26.1 pg/ml at 0 h, 8 h and 16 h (<46). Due to the result from CT performed in the local hospital, a mass larger than 6 cm in size with a well-defined border on the right adrenal gland was displayed. Because the non-functioning suprarenal tumor was presumed to be benign, laparoscopic approach was planned for definitive extirpation of right adrenal gland. After obtaining the access of transperitoneal route, a large suprarenal mass measuring 7 cm × 5 cm × 3.5 cm was identified (Fig. 1A). The lesion was completely extirpated through laparoscopic resection. The histopathological examination confirmed the lesion as adrenal ganglioneuroma, which contains mature ganglion cells admixed with Schwann cells (Fig. 1B and C). Immune-histochemical staining of the tumor cells showed that S-100, CD56, Syn and CgA were positive. After operation, supportive treatment was given and his recovery was uneventful.

Discussion

GN is an infrequent slow-growing tumor, which originates from primitive neural crest cells and is composed of Schwann cells and

* Corresponding author. Department of Urology, Peking University Shenzhen Hospital, 1120 Lianhua Road, Shenzhen, PR China.

E-mail address: yqlord@163.com (Y. Lai).

¹ Contributed equally.

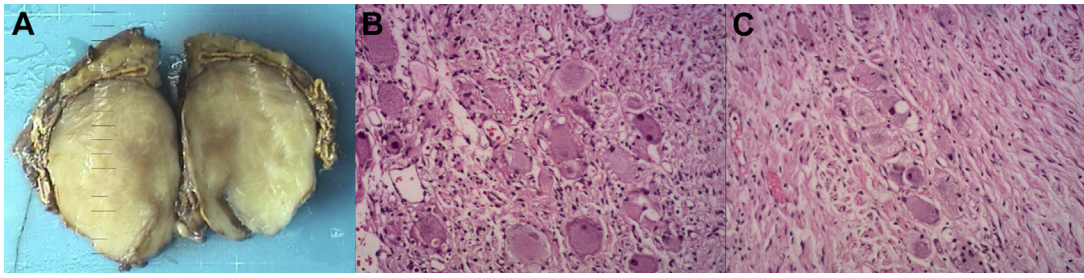


Figure 1. Excised specimen shows a giant AGN which measured 7 cm × 5 cm × 3.5 cm (A). Microscopically showed ganglion cells and Schwann cells (hematoxylin and eosin stain) (B and C).

ganglion cells. Benign GN, malignant neuroblastoma and intermediate ganglioneuroblastoma form a family originating from ganglion cells. AGN is the third most common type of GN, accounting for 21%, while 41.5% of GN located in the posterior mediastinum and 37.5% of GN located in retroperitoneum.² AGN usually occurs in patients ranging from age 10 to 40, and it most normally affects the right adrenal gland in adults.³ In present study, AGNs of patient occurs in right adrenal gland as well.

AGNs often do not exhibit any clinical manifestations even if the tumors are large. But the minority of AGN patients with abdominal mass complain of abdominal pain. Although 16% of patients were detected as abnormal catecholamine, symptoms relating to hormonal imbalance are very rare. With widely use of ultrasonography and computed tomography, more patients of AGN are detected so that incidence of AGN is gradually increasing in recent years. As a well-defined and homogenous mass with a fibrous capsule on CT scans, AGN usually surrounds major blood vessels without evidence of tumor invasion. It displays slightly hypodense with multiple punctate calcifications on the precontrast phase and increase mildly in the postcontrast phase.⁴ Microscopically, fascicles of spindle cells and ganglion cells could be found in tumor.

The tumor size over than 4.5 cm seems to be a forecast of malignancy and open surgery is recommended for resection of malignant primary adrenal tumors. Therefore, giant AGN, although benign, could resemble other adrenal malignant tumors. Because of low invasion and benign nature, laparoscopic adrenalectomy became a standard curative treatment for AGN.⁵ It is debatable that only less than 6 cm in size can laparoscopic adrenalectomy be offered for adrenal neoplasm. Abraham et al reported that the largest AGN with 17 cm in size was resected by laparoscopic approach. Reports of successful laparoscopic extirpation of giant AGN and development of laparoscopic techniques promote the choice of this approach. Likewise, the prognosis is favorable after operation.

Conclusion

Giant AGN usually was identified by an unexpected examination because it is asymptomatic in most case. Histopathological examination is the only way to confirm the diagnosis. After careful evaluation, laparoscopic resection may be a choice for AGN more than 6 cm in size. Fortunately, the prognosis of AGN is excellent after surgical resection.

Conflict of interest

There is no conflict of interest.

Acknowledgments

This work was supported by the National Natural Science Foundation of China [grant number 81101922], Science and Technology Development Fund Project of Shenzhen [grant numbers JCYJ20130402114702124, JCYJ20150403091443304] and the fund of Guangdong Key medical subject.

References

1. NIH state-of-the-science statement on management of the clinically inapparent adrenal mass ("incidentaloma"). *NIH Consens State Sci Statements*. 2002 Feb 4–6;19(2):1–25.
2. Leavitt JR, Harold DL, Robinson RB. Adrenal ganglioneuroma: a familial case. *Urology*. 2000 Sep 1;56(3):508.
3. Zhou Y, Liang Q, Ou WT, et al. Laparoscopic resection of primary adrenal ganglioneuroma: a case report and review of the literature. *Oncol Lett*. 2015 May;9(5):2167–2770.
4. Yamaguchi K, Hara I, Takeda M, et al. Two cases of ganglioneuroma. *Urology*. 2006 Mar;67(3), 622.e1–622.e4.
5. Zografos GN, Markou A, Ageli C, et al. Laparoscopic surgery for adrenal tumors. A retrospective analysis. *Hormones (Athens, Greece)*. 2006 Jan–Mar;5(1):52–56.