

Extracorporeal shock wave lithotripsy for bilateral renal stones: A case report with serious complications that could be avoided

Mohamed Mohamed Elawdy, Samer El-Halwagy, Salim Al-Khanbashi¹, Anas Akbar Aga², Yasser A. Razeq¹

Departments of Urology and ¹Radiology, Ministry of Health, Sohar Hospital, ²Oman Medical College, Sohar, Sultanate of Oman

Abstract

22-year-old male patient with irrelevant medical history presented with bilateral renal stones; multiple stones in right renal pelvis measured 10, 11, and 11mm and another one on the left side measured 12mm. Extra corporeal shock wave lithotripsy (ESWL) was done first on the left side, but after 400 shocks and total energy of 20 Storez Medical Lithotripsy Index only, the stone wasn't visible. Then, the operator switched to the right side and a he completed the session. A day after, the patient presented with bilateral renal colic, gradual rising of renal function and imaging showed bilateral steinstrasse with bilateral hydroureteronephrosis. Patient was managed with insertion of bilateral ureteric stents and had another session of ESWL on the right side. We concluded that bilateral simultaneous ESWL for bilateral renal stones doesn't affect the renal function on the long-term outcome, but still carries the risk of bilateral obstruction and acute renal injury.

Keywords: Acute renal failure, bilateral steinstrasse, extra corporeal shock wave lithotripsy, ureteric stones

Address for correspondence: Dr. Mohamed Mohamed Elawdy, Department of Urology, Ministry of Health, Sohar Hospital, Sohar, Sultanate of Oman.

E-mail: mmelawdy@gmail.com

Received: 22.05.2018, **Accepted:** 20.06.2018

INTRODUCTION

Extracorporeal shock wave lithotripsy (ESWL) is a noninvasive modality for the treatment of urinary tract calculi when it is appropriately indicated. With the recent advances in its technology, the side effects of ESWL have been minimized.^[1]

In the presence of normal contralateral kidney, common adverse effects, such as hematuria, renal colic, and perirenal hematoma, can be treated in most of the cases with conservative management.

However, performing ESWL for bilateral stones simultaneously carries serious complications such

as bilateral obstruction and acute renal injury (ARI). Steinstrasse is another rare complication (4%), and seldom is reported, causing anuria or bilateral obstruction.^[2]

Bierkens *et al.*^[3] and Kumar *et al.*^[4] do not recommend routine ureteric stenting before ESWL for solitary kidney; however, Karalezli *et al.*^[5] and Ishii *et al.*^[6] support its insertion.

We present a rare but serious complications post bilateral simultaneous ESWL. Our case was a healthy young patient who had bilateral renal stones, developed bilateral steinstrasse and ARI. We aimed to alert the urologists

This is an open access journal, and articles are distributed under the terms of the Creative Commons Attribution-NonCommercial-ShareAlike 4.0 License, which allows others to remix, tweak, and build upon the work non-commercially, as long as appropriate credit is given and the new creations are licensed under the identical terms.

For reprints contact: reprints@medknow.com

How to cite this article: Elawdy MM, El-Halwagy S, Al-Khanbashi S, Aga AA, Razeq YA. Extracorporeal shock wave lithotripsy for bilateral renal stones: A case report with serious complications that could be avoided. *Urol Ann* 2018;10:409-12.

Access this article online	
Quick Response Code:	Website: www.urologyannals.com
	DOI: 10.4103/UA.UA_69_18

regarding these serious complications because we feel that such complications could be avoided if we took the necessary precautions.

THE CASE REPORT

A 22-year-old male patient who presented with bilateral flank pain, greater on the left side. He had no medical diseases and with irrelevant surgical history. Routine laboratory investigations were done which revealed microscopic hematuria and normal renal function (70 mmol/dl). Plain X-ray showed bilateral multiple radiopaque shadows on both kidney regions [Figure 1].

Ultrasonography and computed tomography (CT) scan showed bilateral renal stones. Multiple stones in the right renal pelvis measured 10, 11, and 11 mm, another one on the left side measured 12 mm, and no ureteric stones. The patient was given the ESWL patient education form at the urology clinic.

He attended the procedure day fasting, vital signs were checked, and the laboratory workup was reviewed. He was consented for ESWL on the left side, which was more symptomatic and had a single stone. In the supine position, stone localization was done by fluoroscopy, and we used parenteral tramadol 100 mg on starting the session. The standard preparation for ESWL was followed, and Lithotripter Storz SLK machine (STORZ MEDICAL, Tägerwilten, Switzerland) was used.

After 400 shocks and 20 Storz Medical Lithotripsy Index (SMLI) only, the stone was not visible. Because the operator did not expect fragmentation of the stone on this low power, and he thought that it probably escaped to the kidney, he switched to the right side, and the patient agreed. At that time, the operator did not counsel the patient on

the possible major side effects, such as anuria, or the need for ureteric stenting. A complete session was given to the right kidney, 3000 shocks, 70% power, rate of 60/min, and SMLI of 180. Signs of fragmentations were noticed at the end of the session.

At the end of the session, the patient was monitored for 30 min in the treatment room and was given the postprocedural recommendations. The patient was given a routine follow up appointment 2 weeks later at urology clinic but was instructed to attend immediately in the presence of one of more of the alarming symptoms: significant hematuria, anuria, high fever, or severe flank pain.

The patient presented 24 h after the procedure to the emergency room with severe renal colic bilaterally with normal renal function (100 mmol/dl), and he was admitted for pain control. The next day, abdominal X-ray revealed bilateral steinstrasse with remaining renal stones [Figure 2]. CT scan revealed multiple fragmented stones in the right kidney, one single stone in the left kidney, and bilateral multiple small stones occupying distal ureters on both sides (bilateral steinstrasse) [Figure 3]. We decided for bilateral drainage when serum creatinine rose to 250 mmol/l on the 2nd day. Under general anesthesia, cystoscopic insertion of the ordinary guidewire on the left side was stopped on the level of the pelvic ureter [Figure 4]. With the help of the pediatric ureteroscopy, hydrophilic guidewire passed with insertion of 5/24 double J (DJ) stent. Retrograde pyelography showed moderate hydroureteronephrosis. The same procedure was repeated on the right side. Postoperatively, the patient had good urine output, and the renal function returned nearly to the normal level.

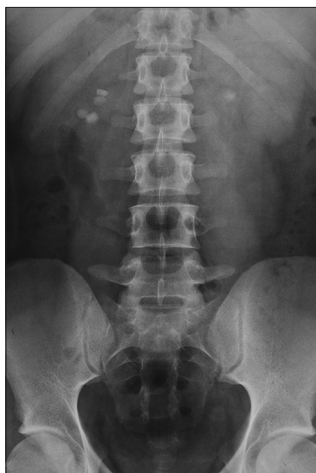

Figure 1: Plain X-ray of the abdomen (KUB) showing bilateral multiple radiopaque renal calculi, more in the right side

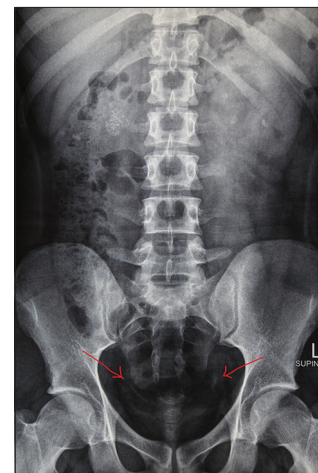


Figure 2: Plain X-ray of the abdomen (KUB) showing bilateral multiple small calculi in the lower pelvic part of both ureters (steinstrasse)

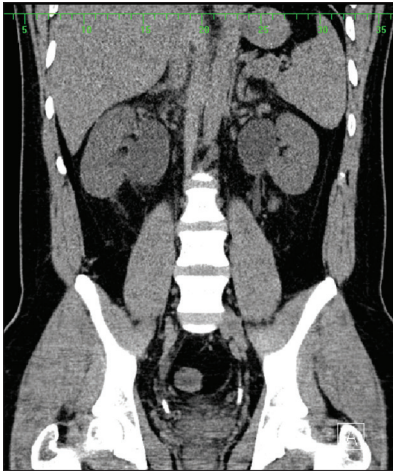


Figure 3: Noncontrast spiral computed tomography of the abdomen confirmed bilateral steinstrasse with subsequent bilateral hydroureteronephrosis

With high fluid intake, most of the small fragments in ureters passed, and the patient had one session of ESWL on the right side on multiple fragmented stones. The ureteric stents were removed under local anesthesia with flexible cystoscope.

DISCUSSION

We presented a 22-year-old healthy, young male with bilateral renal stones who developed bilateral steinstrasse and ARI as a rare complication of postbilateral simultaneous ESWL. He was managed by bilateral insertion of DJ stents with recovery of the renal function.

With the recent advances in lithotripsy technology, a better understanding of its physics, and with more experience, the associated adverse effects have been minimized.

Routine minor complications of ESWL such as red discoloration of urine and renal colic can be managed conservatively. Furthermore, small perirenal hematoma resolves spontaneously.^[1] However, performing ESWL on a solitary kidney or simultaneous bilateral renal stones carries more risks: deterioration of the renal function, ARI, bilateral obstruction, and anuria – the matter which drove the investigators for more studies.

Regarding the effect of renal function, El-Assmy *et al.*^[7] studied the effect of ESWL on the renal function in 156 patients with solitary kidney. They concluded only a small number of complications and insufficient effect on renal function. However, the long-term follow-up confirmed that ESWL is not only effective but also safe in the long-term follow-up. Similar results were mentioned by Zanetti *et al.*^[8] in 52 patients and Sarica *et al.*^[9] in 43 patients.

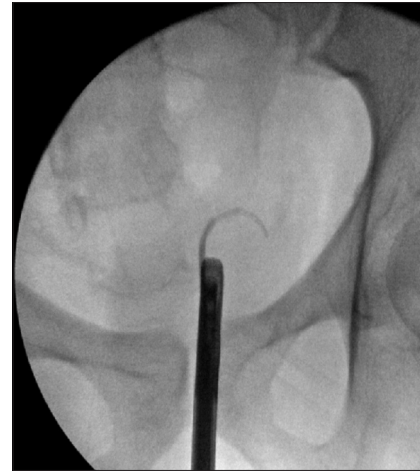

Figure 4: Intraoperative fluoroscopy image that showed failure of the guidewire to pass at the level of the steinstrasse

The matter was not only investigated in solitary kidney but also in bilateral ESWL. Pienkny and Stroom^[10] reported no clinically approved difference in the long-term effect on the renal function if bilateral renal calculi treated with ESWL in a simultaneous versus staged fashion. In accordance with Peinkny and Stroom, our case had bilateral renal stones, and we did simultaneous sessions on both sides.

Ureteric obstruction still matters. Either routine ureteric stenting could lower the complications post-ESWL and is a matter of debate in the literature.

Ishii *et al.* recommended pretreatment ureteral stenting with solitary kidney in 17 patients with sole kidney or solitary functioning kidneys. Similarly, Karalezli *et al.*^[5] inserted DJ stents in 22 solitary kidney before ESWL with no steinstrasse. Furthermore, Vuksanovic *et al.*^[11] put stent for 26 out of 38 patients.

Kumar *et al.*^[4] shocked 23 renal stones in 16 solitary functioning kidney and concluded that ESWL is safe without prophylactic stents in properly selected and closely monitored patients. Avoiding stent decreases costs, duration of treatment, and stent-related morbidity without unduly compromising safety. Furthermore, similar results were reported by Bierkens *et al.*^[3] We did not put a stent in before ESWL session.

Because our patient had bilateral steinstrasse, which seldom is reported, we concluded this based on the literature.

On a large series of 4634 patients, steinstrasse developed in 184 patients (4%), with a very few cases developing anuria ($4/184 = 0.02\%$). The authors mentioned that the stone size (>2 cm) and high power (>22 Kv) are the main risk factors for steinstrasse formation.^[2]

Al-Awadi *et al.*, in a randomized clinical trial, reported that DJ stent insertion lowers the incidence of steinstrasse (6% vs. 23%, $P = 0.05$), but the stone size is the major determinant, being 2.6% and 56% for stone burden of 1.5–2 cm and 3–3.5 cm, respectively ($P < 0.001$).^[12]

Our patient had a stone of 12 mm on the left side, and he took only 400 shocks, and SMLI of 20, so probably the stone composition had a role. On the right side, the stone burden exceeded 3 cm, which could be a factor, and this session was completed.

Although not common, anuria and ARI are possible complications of bilateral simultaneous ESWL, with few case reports in literature. Tuteja *et al.*^[13] reported a case of anuria and renal failure from massive bilateral renal hematoma following bilateral ESWL that was managed by abdominal exploration. One among five cases with anuria which required percutaneous nephrostomy insertion, reported by Numa *et al.* and Vuksanovic *et al.*,^[11] 4/34 (10%) had anuria after ESWL for solitary kidney.

We aimed on our report to alert the urologists by these major complications to be avoided in the future. Although the stone on the left side received only 20 SMLI and the operator did not expect fragmentation by this low energy, it happened. Furthermore, if bilateral ESWL would be chosen, it was better to insert a stent at least on the right side because it carried large stone burden. Taking these necessary precautions keeps the patient's safety and gives a better outcome.

CONCLUSION

Bilateral simultaneous ESWL for bilateral renal stones does not affect the renal function in the long-term outcome but still carries the risk of bilateral steinstrasse, bilateral obstruction, and ARI. These major complications could be avoided on taking the necessary precautions with at least unilateral stenting for patient's safety and better outcome.

Declaration of patient consent

The authors certify that they have obtained all appropriate patient consent forms. In the form the patient(s) has/have given his/her/their consent for his/her/their images and

other clinical information to be reported in the journal. The patients understand that their names and initials will not be published and due efforts will be made to conceal their identity, but anonymity cannot be guaranteed.

Financial support and sponsorship

Nil.

Conflicts of interest

There are no conflicts of interest.

REFERENCES

- Skolarikos A, Alivizatos G, de la Rosette J. Extracorporeal shock wave lithotripsy 25 years later: Complications and their prevention. *Eur Urol* 2006;50:981-90.
- Madbouly K, Sheir KZ, Elsobky E, Eraky I, Kenawy M. Risk factors for the formation of a steinstrasse after extracorporeal shock wave lithotripsy: A statistical model. *J Urol* 2002;167:1239-42.
- Bierkens AF, Hendriks AJ, Lemmens WA, Debruyne FM. Extracorporeal shock wave lithotripsy for large renal calculi: The role of ureteral stents. A randomized trial. *J Urol* 1991;145:699-702.
- Kumar S, Sakthivel A, Chacko KN, Kekre NS, Ganesh G. Shock wave lithotripsy in solitary functioning kidneys: Is prophylactic stenting necessary? *Urol Int* 2006;77:179-81.
- Karalezli G, Müftüoğlu YZ, Sarica K, Yaman LS, Yurdakul T, Ozdiler E, *et al.* Treatment of renal stones in a solitary functioning kidney with extracorporeal shock wave lithotripsy. *Urol Int* 1993;50:86-9.
- Ishii T, Imanishi M, Kohri K, Kurita T, Nagai N. Clinical study of extracorporeal shock wave lithotripsy for stones in solitary kidney. *Nihon Hinyokika Gakkai Zasshi* 1991;82:1466-72.
- El-Assmy A, el-Nahas AR, Hekal IA, Badran M, Youssef RF, Sheir KZ, *et al.* Long-term effects of extracorporeal shock wave lithotripsy on renal function: Our experience with 156 patients with solitary kidney. *J Urol* 2008;179:2229-32.
- Zanetti GR, Montanari E, Guarneri A, Trinchieri A, Mandressi A, Ceresoli A, *et al.* Long-term followup after extracorporeal shock wave lithotripsy treatment of kidney stones in solitary kidneys. *J Urol* 1992;148:1011-4.
- Sarica K, Köhle R, Kunit G, Frick J. Experiences with extracorporeal shock wave lithotripsy in patients with a solitary kidney. *Urol Int* 1992;48:200-2.
- Pienkny AJ, Streem SB. Simultaneous versus staged bilateral extracorporeal shock wave lithotripsy: Long-term effect on renal function. *J Urol* 1999;162:1591-3.
- Vuksanovic A, Micic S, Petronic V, Bojanic N. Solitary kidney stone treatment by extracorporeal shock wave lithotripsy. *Eur Urol* 1997;31:305-10.
- Al-Awadi KA, Abdul Halim H, Kehinde EO, Al-Tawheed A. Steinstrasse: A comparison of incidence with and without J stenting and the effect of J stenting on subsequent management. *BJU Int* 1999;84:618-21.
- Tuteja AK, Pulliam JP, Lehman TH, Elzinga LW. Anuric renal failure from massive bilateral renal hematoma following extracorporeal shock wave lithotripsy. *Urology* 1997;50:606-8.