



Since January 2020 Elsevier has created a COVID-19 resource centre with free information in English and Mandarin on the novel coronavirus COVID-19. The COVID-19 resource centre is hosted on Elsevier Connect, the company's public news and information website.

Elsevier hereby grants permission to make all its COVID-19-related research that is available on the COVID-19 resource centre - including this research content - immediately available in PubMed Central and other publicly funded repositories, such as the WHO COVID database with rights for unrestricted research re-use and analyses in any form or by any means with acknowledgement of the original source. These permissions are granted for free by Elsevier for as long as the COVID-19 resource centre remains active.

Neurology and the clinical anatomist

Tom Hughes

Abstract

Clinical examination allows the neurologist to test hypotheses generated by their interpretation of the patient's story. By eliciting abnormal clinical signs, the examining doctor works out a differential diagnosis for the part of the nervous system affected and, using information from the clinical history, a differential diagnosis of the pathology. Clinical examination also allows the clinician to observe and quantify function, hear more story and provide reassurance. The focus of the examination should be dictated by the hypothesis being tested, the patient's clinical state and the situation. Examination of the different parts of the nervous system remains very important in all clinical situations as the best available index of function of the nervous system as a whole.

Keywords Abnormal signs; anatomical localization; hypothesis testing; MRCP; neurological examination; normal signs; quantification of function

Introduction

Neurologists examine people to elicit signs, assess function and meet patients' expectations. Examination also provides an opportunity to hear more story.

There are two types of sign: normal and abnormal. An abnormal sign is a phenomenon that is absent when it should be present, or present when it should be absent. It suggests a lesion in the afferent or efferent pathway being tested, a framework of thinking as relevant to tendon reflexes and pupils as it is to language and numeracy. A thorough grounding in how normal function changes with age is necessary to be confident in declaring a sign to be abnormal. It is also important to know the likely age of the suspected signs: lesions of the central nervous system (CNS) are usually associated with increased tone and brisk reflexes but not usually in the first few hours, and months later there may be musculoskeletal complications (e.g. elbow contracture), some of which may in turn cause their own (e.g. ulnar nerve palsy) lower motor neurone complications. Comparable considerations should be factored in to the diagnosis of lower motor neurone lesions, which acutely do not produce wasting and fasciculation, and after months can be associated

Dr Tom Hughes MBBS FRCP MD is a Consultant Stroke Physician and Neurologist in the University Hospital of Wales, Honorary Senior Lecturer (Teaching) at Cardiff University, and Clinical Director of Medical Neurosciences in Cardiff and Vale Health Board, UK. He trained in medicine at the Royal London Hospital, and in Neurology and Stroke in London, Cardiff and Edinburgh. He completed an MD thesis describing indices of swallowing in health and in motor neurone disease. Competing interests: none declared.

Key points

- Clinical examination is an invaluable part of the consultation
- Examination allows anatomical localization and assessment of function
- Patients are greatly reassured by clinical examination
- The focus of examination should be to test a hypothesis generated by the clinical history
- There is no validated index of overall function of the nervous system that can be used instead of clinical examination

with contractures. In patients with established upper motor neurone lesions, predictable features such as flexor and extensor spasms develop, as do compensatory strategies used by patients with long-standing neuropathies and myopathies.

The constellation of abnormal signs allows the clinician to generate a differential diagnosis for the lesion's anatomical location and suggest particular pathologies. Clearly, a normal clinical examination does not exclude a very serious condition. Examination can also quantify impairments such as spasticity, weakness, sensory loss and disabilities, for example in speech, language and mobility. The scales used have their place, particularly in research and in communications between clinicians, but should not distract responsible clinicians from the necessary task of working out first the 'where?' and then the 'what?' of the presenting problem.

Arguably, the most important part of the neurological examination is the general medical examination, to establish first whether there is a systemic condition that explains the dysfunction of the nervous system, which at the best of times is a fussy eater. The cortical localization of cerebral function is usually considered helpful for clinicians, as detected abnormalities of language, praxis and vision facilitate prompt anatomical localization. However these cortical functions also provide a repertoire of very effective and sometimes bizarre disguises for general medical conditions manifesting as dysfunction of the brain: a urinary tract infection, for example, can present with worsening dysphasia. The same applies – with less potential for such theatrical presentations – to the spinal cord, peripheral nerves, neuromuscular junction and muscle.

The kidney, liver and lungs all have lobes but without a comparable localization of function, and in discussions of end-organ failure their overall health is relatively easy to quantify using universally familiar indices such as glomerular filtration rate, ammonia or PO₂. The dramatic range of functions localized to very different – but often neighbouring – areas of the nervous system explains the lack of a readily available or valid index for the function of the nervous system as a whole, and why clinical examination – for diagnosis and follow-up – is still such an important part of neurological practice.

The extent to which any neurological examination should always be 'full' is for the clinician to decide. It should be considered first as a tool to test a hypothesis, before it is used for

Mini-mental state examination

Time orientation: year, season, date, day, month	5
Place orientation: country, county, town, building, floor	5
Registration: name three common objects and ask the patient to repeat them	3
Attention: spell 'world' backwards	5
Recall: ask for the three objects registered above	3
Language: name two common objects	2
Language: repeat the phrase 'no ifs, ands or buts'	1
Three-stage command: take a sheet of paper in your right hand, fold it in half and put it on the desk	3
Read and obey the following: 'close your eyes'	1
Write a sentence	1
Copy a design, for example a five-point star	1
Total	30

Table 1

other reasons. In this article the author is obliged to write without a particular hypothesis in mind – an important issue that readers should be aware of – and without consideration of whether it is a new or follow-up appointment, of the location (clinic, ward, intensive care unit) or of the patient's position (chair, trolley, bed, couch). Musculoskeletal assessment (plantar flexion is very 'weak' in patients with a ruptured Achilles tendon) and psychiatric assessment (vascular and conversational insults may both flatten affect) can also be required but are not discussed further here.

General medical examination

Before a neurological examination is started, an ABC-type approach (Airway, Breathing, Circulation) is mandatory in any acute setting, followed by the traditional assessment of the cardiovascular, respiratory and abdominal systems. Examples are numerous, but if an older adult has a transient change of function and is found to be in atrial fibrillation, further diagnostic sleuthing has to be contextualized accordingly, and some priority

given to assessing whether the time remaining is spent organizing safe anticoagulation or refining the diagnosis further.

Conscious level and cognition

Conscious level can be quantified using the Glasgow Coma Scale, but this was designed for patients with head injury and is relatively insensitive to fluctuations in vigilance and attention. Cognition should be assessed using a standard screening tool such as the Mini-Mental State Examination (Table 1), which is familiar to many and comprises tests of most of the important cognitive functions; some additional probing can be rewarding clinically, as described below.

Speech is usefully described as comprising articulation (pronunciation of words), phonation ('say Ahh'), vocal resonance (changes in which are easily demonstrated by squeezing one's nose half way through a recital of the days of the week) or prosody (the melody, intonation and emphasis of speech), all of which in turn are dependent to some extent on the control of breathing; we usually speak as we breathe out.

Language refers to the meaning of the words used, written or spoken. Patients can have abnormal or absent speech but normal reading and writing. Receptive language is tested by asking the patient to complete a simple task or answer a simple question, expressive language by testing naming and the ability to describe a scene. The ability to repeat single words, and particularly a sentence (e.g. 'The orchestra played and the audience applauded') is an easy way of testing both the afferent (to Wernicke's area) and efferent (from Broca's area) pathway, and their connections (arcuate fasciculus).

Simple tests of frontal lobe function include letter fluency (ask the patient to think of words beginning with F, A and S; 20 in a minute is average) and category fluency (items one might buy in a supermarket; again around 20 is average).

Simple paper and pencil tests of language, and of other higher functions such as constructional abilities and line bisection provide a valuable record of deficits and of changes, and are easily retained within the medical notes.

Cranial nerves

It is artificial to consider that examination of things such as eye movements is testing only the integrity of the nuclei and peripheral course of cranial nerves rather than their central control, but this approach is now very well established.

The common patterns of field loss

Field defect	Site of lesion(s)	Aetiology
Homonymous hemianopia	Optic tract, optic radiation, occipital lobe	Stroke, tumour
Superior quadrantanopia	Temporal lobe	Stroke, tumour
Inferior quadrantanopia	Parietal lobe	Stroke, tumour
Bitemporal hemianopia	Optic chiasm	Pituitary adenoma, craniopharyngioma
Binasal hemianopia	Perichiasmal	Bilateral internal carotid artery aneurysms
Junctional scotoma	Junction of optic nerve and chiasm	Tumour
Bilateral scotomas	Occipital pole	Head injury

Table 2

Olfactory

The first nerve is rarely assessed in routine practice, but detecting anosmia can be a useful predictor of some degenerative diseases, for example Parkinson's disease, in congenital absence of the olfactory nerves and more recently as a complication of COVID-19.

Optic

The visual system is hard-wired, and defects are reliably localizing (Table 2). The five basic components are assessment of acuity, colour vision, blind spots and visual fields (central and peripheral), pupil reactions to light and near vision, and fundoscopy. Acuity can be quantified using a Snellen chart, or a near vision chart. Ishihara plates provide a convenient way of getting at colour vision, impairment of which may be the only residual deficit after a bout of optic neuritis, before optic atrophy is apparent.

In papilloedema the first sign is enlargement of the blind spot, which in healthy adults is more obvious below rather than above the horizontal meridian; restriction of peripheral fields is a later complication. Peripheral fields should be assessed with the examiner using both hands, positioned to start in each of the two upper or lower quadrants. Asking the patient (if they are able) to point to the wagging finger of the examiner's hand is enough to first screen for gross deficits, first with both their eyes open then with each eye separately. Right brain disease can cause profound visual field impairments without the patient being aware of a problem. If the goal is to detect peripheral constriction a moving red target should be brought in slowly from the periphery until it is seen. Common patterns of visual field loss are listed in Table 2.

A light shone into a pupil causes pupillary constriction bilaterally. If the light is removed, both pupils should dilate. If the light continues to be shone onto the pupil, it starts to oscillate (pupillary hippus). Pupils also constrict during accommodation, as the patient looks at an object brought close to them.

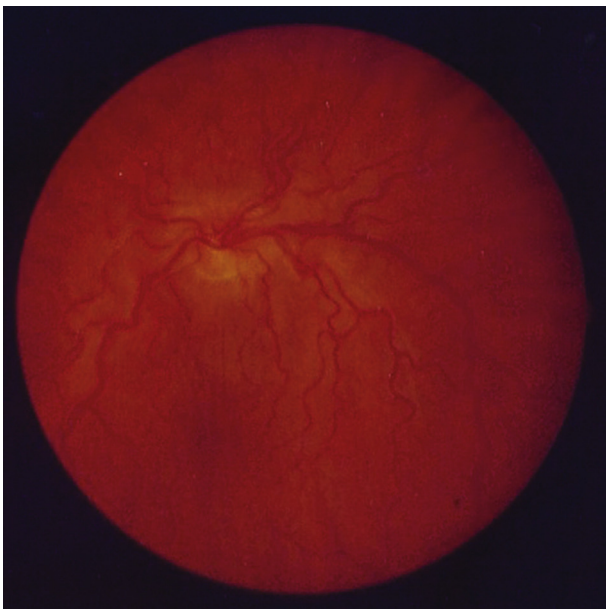


Figure 1 Papilloedema.

Fundoscopy allows inspection of the optic disc (papilloedema and optic atrophy are easily appreciated; Figures 1 and 2) and retinal vessels, which may harbour retinal emboli or have bled.

IIIrd, IVth and VIth

The extraocular muscles are supplied according to the formula LR6, SO4, R3: lateral rectus by the VIth cranial nerve, superior oblique by the IVth, and the rest by the IIIrd. The rectus muscles elevate and depress the globe in abduction, the obliques in adduction.

Examination of eye movements should start with a simple cover test to detect double vision: in whichever plane the patient reports diplopia, the fainter and furthest image disappears when the responsible eye is covered.

Eye movements are described as voluntary, pursuit or saccadic. Saccades are defined as a burst of conjugate eye movement, and are easily tested in the horizontal plane. A reduction in speed or amplitude of a horizontal saccade to one side suggests a lesion in the contralateral hemisphere or the ipsilateral pons (so-called wrong way eyes).

Nystagmus is common and a useful sign in clinical practice. The direction of nystagmus is described according to its fast phase which, like a sudden extension of the neck when napping in a chair, is the corrective movement. The patient should be asked to follow the examiner's pen as it moves out to 30° of lateral gaze, to avoid eliciting (benign) end-point nystagmus. Horizontal nystagmus that changes direction with the direction of gaze is usually central in origin; if it remains the same, it is usually peripheral, i.e. from the semicircular canals.

Trigeminal

The sensory function extends from the vertex to the angle of the jaw. Common sensation to the teeth, gums, tongue and inside of the mouth depends on the trigeminal nerve, and checking these areas is a useful way to sense check symptoms of facial numbness. The motor function produces jaw opening (lateral and medial pterygoids). The muscles of closure (temporalis, masseter) are easily palpated.

Facial

The muscles of facial expression are supplied by the facial nerve, and are easily tested by asking the patient to smile, frown and raise their eyebrows. A lower motor neurone palsy involves the upper and lower face. An upper motor neurone lesion affects mainly the lower face, although the upper face can become more active during laughter and crying.

Vestibulocochlear

Hearing should be assessed with a 512 Hz tuning fork. If the base is placed over the mastoid and held until the patient can no longer hear the note, but they can hear it if the prongs are then held over the acoustic meatus, this confirms that air conduction is greater than bone; this is normal, and is termed a positive Rinnes test. It also occurs in sensorineural deafness owing to the augmentation produced by the bones of the middle ear. Weber's test involves placing the footpad of a vibrating tuning fork on the forehead: in unilateral sensorineural hearing loss, hearing is better on the contralateral side, and in unilateral conductive hearing loss, hearing is better on the ipsilateral side.

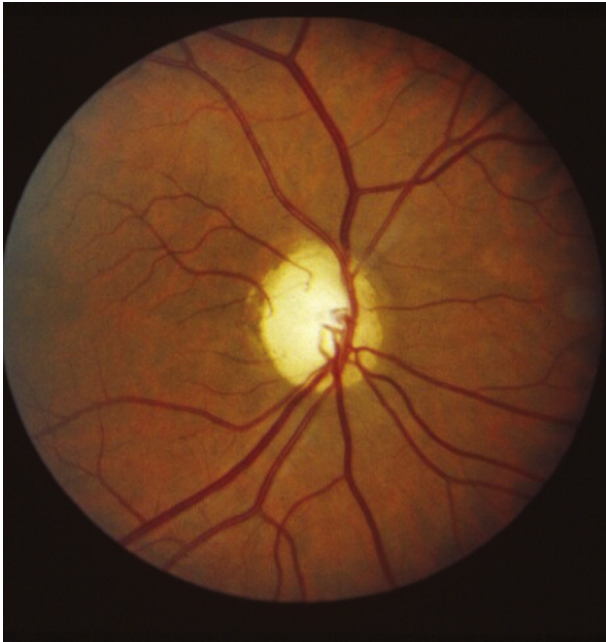

Figure 2 Optic atrophy.

In patients with episodic vertigo – defined as the hallucination of movement – a provocative test (Dix–Hallpike) designed to reproduce an episode can be very helpful diagnostically and therapeutically. The patient sits lengthways on a bed or couch, with a pillow placed so that, as they are reclined by the examiner, it supports their shoulders, allowing the patient’s head to then touch the surface of the bed with an angle of about 30° of neck extension; the examiner adds 45° of rotation to this. In patients with debris in one of their semicircular canals there follows, after a few seconds, a reproduction of symptoms associated with nystagmus, which fatigues with repeated testing. In patients with central disorders, there is typically no delay before the onset of symptoms, and no fatigability.

Glossopharyngeal

This nerve makes itself known in patients who have glossopharyngeal neuralgia, but its sensory function overlaps with the vagus so their territories are clinically indistinguishable. Its motor function involves only stylopharyngeus, which elevates the pharynx, but is not testable at the bedside.

Vagus

Movement of the palate and pharynx to one side during phonation suggests a contralateral Xth nerve lesion. Dysfunction of the

internal muscles of the larynx (false and true cords, arytenoids and epiglottis, none of which can be seen without nasendoscopy or laryngoscopy) causes dysphonia and ineffective (bovine) coughing as a result of impaired apposition of the vocal cords; it also causes impaired swallowing secondary to incomplete laryngeal closure. Aspiration into the airway is inevitable in a Xth nerve palsy, and the associated impairment of coughing makes chest infections likely.

The movement of the larynx in an upwards and forwards direction during swallowing (readers may wish to check this out with a finger on their Adam’s apple, and then a voluntary swallow) is essential for opening of the upper oesophageal sphincter; this depends on the external (suprahyoid) laryngeal muscles, which are innervated by the Vth and VIIth cranial nerves.

Accessory

The strength of sternocleidomastoid and trapezius should be tested.

Hypoglossal

Protrusion and retraction of the tongue, out of and back in to the mouth, depends on external lingual muscles, the push-me-pull-you configuration of which produces – in a hypoglossal palsy – ipsilateral deviation on protrusion, but contralateral bunching of the tongue on retraction. Rolling and folding of the tongue is dependent on the intrinsic muscles of the tongue, all of which are innervated by the XIIth nerve. The speed of movement of the tongue is sometimes easier to hear than to see, as in during the production of alternating alveolar and plosive phonemes (‘T’ and ‘C’).

The tongue should also be palpated by a gloved index finger, to check for infiltration by malignant disease, or tethering after surgery.

Examination of the limbs

Observation at rest for scars, asymmetry and movement disorders should be followed by observation during maintenance of posture, during which tremor and other movement disorders may become apparent. Pronator drift is a sign of an upper motor neurone deficit.

Tone is defined by neurologists as the resistance to passive movement. The speed and amplitude of movement should be varied in order to distinguish spasticity (velocity dependent, non-uniform throughout the range of movement) from rigidity (non-velocity dependent, relatively uniform). Involuntary resistance to passive movement (Gegenhalten) is seen in patients with frontal lobe disease, usually with primitive reflexes such as a palmo-mental reflexes and grasp response.

The testing of strength is usefully reframed as testing of whether the patient can generate force against the examiner’s resistance. It is essential to assess whether there is weakness or another problem impeding the generation of force such as pain, apraxia, ataxia or apathy, or a fracture or tendon rupture. An appreciation of the distribution of strength in a normal adult is also useful. Strength in normal adults has a pyramidal distribution. Elbow flexion is around 350 N (Newtons) in healthy adult men, elbow extension around 180 N. Shoulder adduction is

The main deep tendon reflexes

Reflex	Nerve	Root
Biceps	Musculocutaneous	C5/C6
Supinator	Radial	C5/C6
Triceps	Radial	C7
Finger flexors	Median/ulnar	C8
Knee	Femoral	L3/L4
Ankle	Tibial	S1/S2

Table 3

Gait disturbances encountered in clinical practice

Type of gait	Description	Common causes
Gait apraxia	Small shuffling steps <i>Marche à petits pas</i>	Small vessel disease Hydrocephalus
Parkinsonian	Shuffling Loss of arm swing	Idiopathic Parkinson's disease
Spastic paraparesis	Stiff walking through mud	Spinal cord lesion Parasagittal lesion
Myopathic	Waddling	Muscular dystrophy
Foot drop	Foot-slapping	Neuropathy
Spastic monoplegia	Exaggerated circumduction	Stroke
Cerebellar ataxia	Wide based 'Drunken'	Any cerebellar pathology
Sensory ataxia	Wide based Foot-slapping Deteriorates with eye closure	Subacute combined degeneration of the cord

Table 4

stronger than adduction, wrist flexion stronger than wrist extension, etc. In the lower limb a corresponding pattern exists (hip extension > hip flexion, knee extension > knee flexion, etc.). So strength has a pyramidal distribution in normal adults, something that is more readily appreciated when a given amount of central drive is removed to create, in CNS diseases, the so-called pyramidal distribution of weakness. This is relevant in the diagnosis of functional neurological disorders, in which the distribution of impairment – of force generation – is incongruent with the distribution of weakness seen in common diseases of the CNS.

Reflexes require a suitable tendon hammer and should be done with the patient relaxed or even distracted. Some find it helpful to ask the patient to contract upper limb muscles when trying to elicit lower limb reflexes (Jendrassik manoeuvre), but engagement in a distracting conversation with the examiner may be a more conducive ploy. The main tendon reflexes are summarized in [Table 3](#).

Sensation

The two systems tested are the spinothalamic (fibres cross roughly at their point of entry to the spinal cord), which carries pain and temperature, and joint position and vibration sense (all first-order neurones have a peripheral course and a central course before synapsing and decussating in the lower medulla). The patient should be asked if they can feel the sharpness of a pin and the coldness of a tuning fork, but the examiner should be aware of natural sensory variation, with enhanced sensitivity over the face, chest and genitals.

The sensory function of muscle is impossible to test at the bedside, but dysfunction is readily apparent in ataxic patients. Spiral and flower spray endings in intrafusal muscle fibres relay, through peripheral nerves and the spinocerebellar tracts, information to the cerebellum about the state of contraction or relaxation of muscle. If this pathway is interrupted, peripherally or centrally, the loss of unconscious proprioception results in sensory ataxia, even if joint position sense is preserved. Framed in this way, all ataxia is sensory, but only in patients with loss of

joint position sense (conscious proprioception) can the responsible impairment be elicited by bedside examination. Thus abnormalities of the finger–nose test and heel–shin test, in the presence of normal joint position sense, are traditionally labelled as cerebellar ataxia but can result from lesions anywhere from the muscles spindles and their spinocerebellar afferent nerves (as in Miller Fisher syndrome, associated with GQ1b antibodies) to the spinocerebellar tracts (as in spinocerebellar ataxia) or the cerebellum (infarction, alcohol, etc.).

Function

As a way of cross-checking the findings on the bed or couch the patient's ability to speak, cough, swallow, breathe and walk must be assessed. Gait in particular is very revealing and can provide a big-picture, 'lightbulb' moment in the diagnostic process. These big-picture observations can be incorporated into the informal parts of the consultation by watching the patient rise from their chair in the waiting room and walk, and by watching them unbutton and button, untie and tie, lie flat and sit up during the course of the consultation. Common gait disorders are summarized in [Table 4](#). ◆

FURTHER READING

- Geraint Fuller. *Neurological examination made easy*. 6th edn. Elsevier, 2019.
Ginsberg Lionel. *Lecture notes: neurology*. 9th edn. Wiley-Blackwell, 2010.

Acknowledgement

The figures and tables have been reproduced from Wills, A. How to perform a basic neurological examination. *Medicine* 2016; **44**: 464–68.