

Mitigating the risks of surgical smoke: positive pressure rooms and particulate air filters

doi: 10.1111/ced.14971

Dear Editor,

We thank Dr Brady for his response¹ to our article on surgical plume in dermatology,² and note his interest in investigating the difference between positive room air pressure compared with a normal pressure room.¹

In a positive air pressure room, the room is sealed and the air pressure in the room is greater than that outside, potentially pushing infectious particles such as those found in the surgical plume away from the patient and operator.³ In our paper, we discussed the use of high-efficiency particulate air (HEPA) and ultra-low particulate air (ULPA) filters.² A HEPA filter can filter particles $\geq 0.3 \mu\text{m}$ in size, and ULPA filters can filter 99.99% of particles $\geq 0.12 \mu\text{m}$.⁴ In our research, we found that particles $< 5 \mu\text{m}$ have the capacity to reach the terminal bronchioles.² The combination of a positive pressure room with HEPA and ULPA filters could have the potential to reduce the infectious and malignant capabilities of the surgical plume by facilitating both mechanical filtering as well as suction.²

This warrants further investigation to improve safety outcomes for both patients and clinicians. In the absence of positive pressure rooms (as is the case for many dermatologists), such particulate air filters, measures to reduce the generation of surgical smoke, and provision of appropriate personal protective equipment for patients and staff should mitigate the risk posed by surgical smoke.

T. Searle,¹ F. R. Ali²  and F. Al-Niaimi³

¹North Middlesex University Hospital, London, UK; ²Dermatological Surgery and Laser Unit, St John's Institute of Dermatology, Guy's Hospital Cancer Centre, Guy's and St Thomas' NHS Foundation Trust, London, UK and ³Department of Dermatology, Aalborg University Hospital, Aalborg, Denmark
E-mail: firas55@hotmail.com

Conflict of interest: the authors declare that they have no conflicts of interest.

Linked articles: Brady M. *Clin Exp Dermatol* 2021; doi: 10.1111/ced.14875.

Searle T et al. *Clin Exp Dermatol* 2020; **45**: 841–7.

Accepted for publication 3 August 2021

References

- 1 Brady M. Surgical plume in dermatology: an insidious and often overlooked hazard. *Clin Exp Dermatol* 2021. <https://doi.org/10.1111/ced.14875>
- 2 Searle T, Ali FR, Al-Niaimi F. Surgical plume in dermatology: an insidious and often overlooked hazard. *Clin Exp Dermatol* 2020; **45**: 841–7.
- 3 Apreco. Case study. Isolation rooms: positive versus negative pressure rooms. Available at: <https://apreco.com/>

blog/isolation-rooms-positive-versus-negative-pressure-rooms/?nowprocket=1 (accessed 1 September 2021).

- 4 Limchantra IV, Fong Y, Melstrom KA. Surgical smoke exposure in operating room personnel: a review. *JAMA Surg* 2019; **154**: 960–7.

Generalized bullous fixed drug eruption after Oxford–AstraZeneca (ChAdOx1 nCoV-19) vaccination

doi: 10.1111/ced.14926

Dear Editor,

A 74-year-old Thai man presented with a rash that had appeared 25 h after he had received his first dose of the adenoviral-vectored COVID-19 vaccine, ChAdOx1 nCoV-19 (Oxford–AstraZeneca). The lesions had appeared abruptly without any accompanying symptoms. The patient's medical history included end-stage renal disease, atrial fibrillation and ischaemic stroke. The patient denied taking any new drugs, supplements or foods prior to this cutaneous eruption.

Physical examination revealed multiple, well-defined, round to oval, erythematous to violaceous plaques with central dusky appearance and bullous formation on the trunk and both extremities (Fig. 1). There was no mucosal involvement.

A punch biopsy was taken, and histopathology findings were consistent with bullous fixed drug eruption (BFDE) (Fig. 2).

Laboratory investigations did not show any definite internal organ involvement.

Given the clinical and histological features, a diagnosis of generalized BFDE (GBFDE) was made. Fixed drug eruption (FDE) (not bullous or generalized) typically presents within 1–2 weeks after the initial exposure, and in < 2 days for subsequent episodes, whereas GBFDE occurs with more sudden onset and typically within 24 h.¹ Based on the temporal relationship, the ChAdOx1 nCoV-19 vaccine was considered as the eruption trigger, with a score of 5 (probable) on the Naranjo Adverse Drug Reaction Probability Scale.

Several vaccines have been implicated in triggering FDE, including the combined pentavalent DTaP-IPV-Hib (6-in-1) vaccine, yellow fever, influenza, human papillomavirus, recombinant adjuvant varicella zoster vaccine, and COVID-19 vaccines.^{2–5} Whereas FDE is usually self-limiting and has a favourable prognosis, GBFDE is considered a severe cutaneous adverse reaction (SCAR) with a high mortality rate among elderly patients.¹ Despite the wide use of the COVID-19 vaccinations, only eight cases of SCAR associated with these vaccines have been documented (Table 1).

The treatment for GBFDE treatment is cessation of the causative agents and supportive care.¹ We treated our patient with topical 0.25% desoximetasone cream. The lesions gradually resolved within 2 weeks, leaving postinflammatory hyperpigmentation.

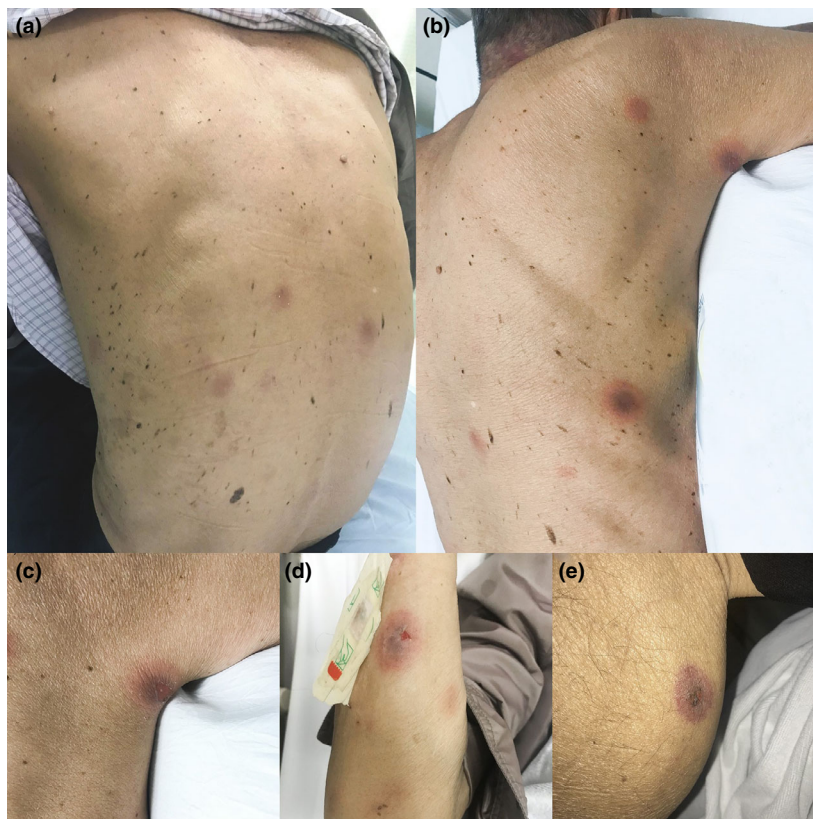

Figure 1 (a,b,d) Round to oval, erythematous to violaceous patches with central dusky appearance on the trunk and limbs; (c,d,e) large and well-demarcated central erosions were also noted on (c) the axilla and trunk; (d) right forearm and (e) right leg. No mucosal lesions were observed and the lesions were found in > 2 different sites of the body.

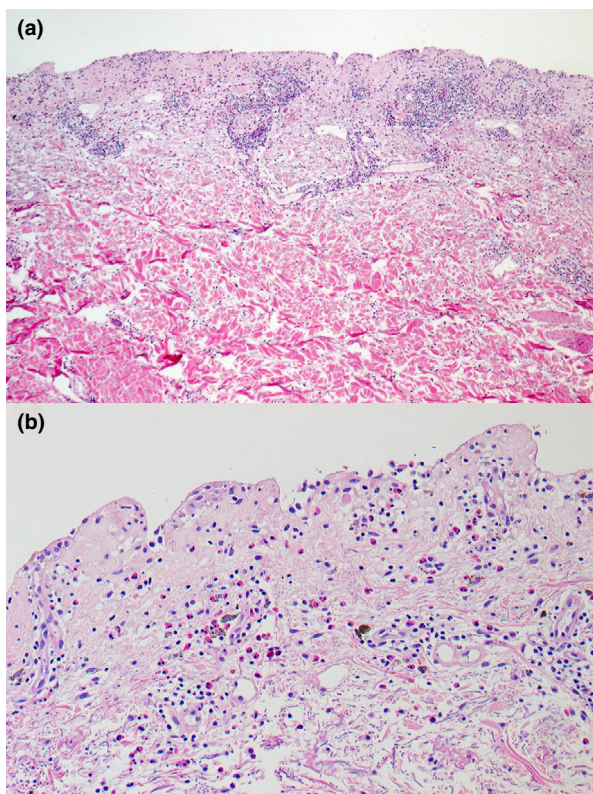


Figure 2 (a,b) Histological examination of a punch biopsy was performed from the lesion on the patient's back showed (a) subepidermal separation with superficial and deep perivascular inflammatory cell infiltration and (b) mixed inflammatory cells infiltrate, composing of lymphohistiocytes and numerous eosinophils. Melanophages were seen in the upper dermis. Haematoxylin and eosin, original magnification (a) $\times 50$; (b) $\times 200$.

Use of patch testing on an area of residual hyperpigmentation after FDE resolution was considered as a method to confirm the culprit drug; unfortunately, testing could not be performed due to limited access to the vaccine and hospital areas during the COVID-19 pandemic. As an alternative, an interferon (IFN)- γ ELISpot assay was undertaken. This technique assesses the amount of IFN- γ production from peripheral blood mononuclear lymphocytes after stimulation with the suspect agents. In this case, the vaccine excipient, polysorbate80 (dilutions of 1 : 2000 and 1 : 10 000), was tested and yielded negative results. Our patient also reported receiving an annual influenza vaccination, which contains a similar excipient (polysorbate), without any adverse reactions. This indicated that the GBFDE was a result of a hypersensitivity reaction to the ChAdOx1 nCoV-19 vaccine rather than the excipient.

To our knowledge, this is the first report of ChAdOx1 nCoV-induced GBFDE. Because of the potential recurrence

Table 1 Reported cases of severe cutaneous adverse reactions due to COVID-19 vaccine administration.

Patient	Sex	Age, years	Allergy	Vaccine platform	Dose	Timing of onset	Lag period		Clinical phenotype	Supporting investigations	Outcome	Second dose administration
							vaccination, days	after vaccination, days				
1	M	74	Sulfa drugs, amoxicillin-clavulanic acid	Viral vector vaccine (Janssen, Ad26.COVS.2.S)	First	3 days	10	AGEP	Blood test: leucocytosis with neutrophilia and eosinophilia, normal creatinine level and liver enzymes Histology: epidermal spongiosis with subcorneal neutrophilic pustules and dermal neutrophilic inflammation with eosinophils. DIF: negative	Improved with oral prednisolone 20 mg/day and topical steroid	NA	
2	F	43	NA	Viral vector vaccine (Oxford-AstraZeneca, ChAdOx1)	First	3 days	NA	AGEP	Blood test: leucocytosis with eosinophilia. Histology: lichenoid interface dermatitis, intraoral pustules, lymphocytic infiltrate with numerous eosinophils	Resolution with topical corticosteroid within 30 days	Platform changed to mRNA vaccine (Pfizer/BioNTech, BNT162b2); no recurrence of reaction	
3	F	32	No	Viral vector vaccine (Oxford-AstraZeneca, ChAdOx1)	First	3 weeks	NA	AGEP	Blood test: leucocytosis with neutrophilia	Resolution with short course systemic corticosteroid within 2 weeks	Not mentioned	
4	M	38	NA	mRNA vaccine (Pfizer/BioNTech, BNT162b2)	Second	5 days	NA	AGEP	Blood test: marked neutrophilia Histology: supportive of the diagnosis of AGEP	Resolution with topical mometasone cream	NA	
5	M	60	NA	Viral vector vaccine (Oxford-AstraZeneca, ChAdOx1)	First	3 days	7	SJS	Histology: moderate intraepidermal infiltration of lymphocytes and neutrophils with moderate spongiosis, scattered degenerated apoptotic keratinocytes, patchy areas of basal cell degeneration and interface dermatitis, perivascular and periadnexal inflammatory cell infiltrate along with extravasation of erythrocytes in dermis	Complete resolution with oral ciclosporin 300 mg/day after 7 days	Platform changed; no data on outcome	

Table 1 continued

Patient	Sex	Age, years	Allergy	Vaccine platform	Dose	Timing of onset	Lag period after vaccination, days	Clinical phenotype	Supporting investigations	Outcome	Second dose administration
6	F	Middle-aged	No	mRNA vaccine (Pfizer/BioNTech, BNT162b2)	Second	5 days	NA	SJS	NA	Treated with oral prednisolone 30 mg/day; outcome unknown	NA
7	F	49	NA	mRNA vaccine (Pfizer/BioNTech, BNT162b2)	First	7 days	NA	TEN	Histology: full-thickness epidermal necrosis along with dermal-epidermal separation and necrotic keratinocytes	Treatment with 2 doses of etanercept 50 mg/mL (on Days 1 and 3); complete resolution in 22 days	Not mentioned
8	M	66	No	mRNA vaccine (Moderna, mRNA-1273)	Second	24 h	5	GBFDE	Blood test: anti-BP180 negative (8), anti-BP230 negative (< 2) Histology: full-thickness epidermal necrosis and a very sparse lymphocytic inflammatory infiltrate	Improved with high-dose oral prednisone	NA
9 (our case)	M	74	Penicillin (swollen lips)	Viral vector vaccine (Oxford-AstraZeneca, ChAdOx1)	First	25 h	2	GBFDE	Histology: subepidermal separation with superficial and deep perivascular mixed inflammatory cells infiltration composing lymphohistiocytes and numerous eosinophils, melanophages were seen in the upper dermis IFN- γ ELISpot assay: negative for polysorbate 80	Resolution with residual hyperpigmentation with topical desoximetasone within 2 weeks	Platform changed; no data on outcome

AGEP, acute generalized exanthematous pustulosis; BP, bullous pemphigoid; DIF, direct immunofluorescence; GBFDE, generalized bullous fixed drug eruption; IFN, interferon; NA, not applicable; SJS, Stevens-Johnson syndrome; TEN, toxic epidermal necrolysis.

of SCAR, the patient was advised to switch to a different COVID-19 vaccine platform.

Acknowledgement

We thank the patient for providing informed consent for publication of their case details and images. We also thank the Skin and Allergy Research Unit for their support.

K. Wantavornprasert¹  **N. Noppakun**¹ 
J. Klaewsongkram²  and **P. Rerknimitr**¹ 

¹Division of Dermatology, Skin and Allergy Research Unit, Department of Medicine, Faculty of Medicine, Chulalongkorn University, Bangkok and ²Division of Allergy and Clinical Immunology, Skin and Allergy Research Unit, Department of Medicine, Faculty of Medicine, Chulalongkorn University, Bangkok, Thailand

E-mail: pawinee.r@chula.ac.th

Conflict of interest: the authors declare that they have no conflicts of interest.

Accepted for publication 3 September 2021

References

- 1 Patel S, John AM, Handler MZ *et al.* Fixed drug eruptions: an update, emphasizing the potentially lethal generalized bullous fixed drug eruption. *Am J Clin Dermatol* 2020; **21**: 393–9.
- 2 Savas Erdogan S, Cebeci KF. Fixed drug eruption after pentavalent diphtheria, tetanus, acellular pertussis, inactivated poliovirus and Haemophilus influenzae type b combined vaccine in an infant. *Eur J Hosp Pharm* 2021. Online ahead of print. <https://doi.org/10.1136/ejhpharm-2021-002875>
- 3 Mintoff D, Pisani D, Betts A *et al.* SARS-CoV-2 mRNA vaccine-associated fixed drug eruption. *J Eur Acad Dermatol Venereol* 2021; **35**: e560–3.
- 4 Thompson H, Nichols L, Gonzalez ST. Bullous fixed drug eruption following administration of the recombinant adjuvant Shingrix vaccine. *BMJ Case Rep* 2021; **14**: e241293.
- 5 Farinazzo E, Ponis G, Zelin E *et al.* Cutaneous adverse reactions after m-RNA COVID-19 vaccine: early reports from Northeast Italy. *J Eur Acad Dermatol Venereol* 2021; **35**: e548–51.

Intramatrix injection of anti-interleukin-17A antibody for six patients with nail psoriasis

doi: 10.1111/ced.14933

Dear Editor,

Nail psoriasis (NP) remains a challenging clinical problem. Our previous case report showed that intramatrix injection of low-dose secukinumab, an anti-interleukin (IL)-17A monoclonal antibody, could markedly improve the condition of NP.¹ However, the difference in efficacy

between the nail matrix (pitting, leuconychia, nail plate crumbling and red lunula) and nail bed (oil-drop sign, onycholysis, subungual hyperkeratosis and splinter haemorrhages) was unclear.

This protocol was approved by the local ethics committee, and all patients provided written informed consent.

We recruited six patients (three men, three women, mean \pm SD age 33.2 ± 11.1 years) with psoriasis vulgaris and NP. Duration of skin psoriasis was 8.3 ± 4.1 years and duration of NP was 3.2 ± 1.5 years. The mean Psoriasis Area and Severity Index was 2.6 ± 0.6 , and the number of involved fingernails was 9.2 ± 1.3 . Previous treatments had included mainly topical application of corticosteroid and/or vitamin D3 analogues for the psoriatic skin lesions but not for the NP. None of the patients had received any systemic treatment, including immunosuppressors and biologics, in the 3 months prior to enrolment. One patient had received narrowband ultraviolet B phototherapy 3 months prior to enrolment.

During the study treatment, each patient received local anaesthesia into the proximal nail fold with 5% lidocaine cream and 1% tetracaine hydrochloride under occlusion.¹ This was left for 1 h to take effect, then three relatively severe nails on the left hand were injected into the nail matrix with secukinumab at different concentrations (7.5, 15 and 30 mg/mL, respectively). These were prepared by diluting the original secukinumab preparation (150 mg/mL) with sterile water for injection and the dilutions were then kept at 4°C. The needle was inserted from the two sides of the proximal nail fold to form a 'V' shape (Fig. 1a).² The injection volume of each side was 0.05 mL every time.

All patients received 5–6 treatments with a 2-week interval between treatments. All nails (treated and untreated) were assessed with Nail Psoriasis Severity Index (NAPSI) from baseline to Week 12 at 2-week intervals,³ and then a final follow-up was carried out at Week 24. Because of the COVID-19 pandemic, three patients did not receive their sixth treatment and efficacy evaluation at Week 10, or their efficacy evaluation at Week 12. Because all patients refused injection of intralesional corticosteroid (the intended control), the control was the untreated symmetrical finger(s) of the right hand.

At Week 24, there was a significant ($P < 0.01$) difference in mean NAPSI between the treated ($n = 18$) and control fingernails, with a mean improvement of 73.2% and 18.3%, respectively. The treated nails were significantly better at all three concentrations, with 76.1%, 66.1% and 75.7% improvement for secukinumab 7.5, 15 and 30 mg/mL, respectively, with no significant difference between them. Significant improvements were seen in both the nail bed (onycholysis, subungual hyperkeratosis and splinter haemorrhages) and nail matrix (nail plate crumbling), and the overall clinical efficacy in nail bed was superior to nail matrix. At Week 24, mean improvement in