

## Surgical Treatment of Thoracic Meningocele Associated with Neurofibromatosis and Kyphoscoliosis

Young-Jin Kim, M.D.\*, Hyun-Min Cho, M.D.\*, Chee-Soon Yoon, M.D.\*, Chan-Kyu Lee, M.D.\*,  
Tae-Yeon Lee, M.D.\*, June-Pill Seok, M.D.\*

A 46-year-old man presented with a lateral thoracic meningocele associated with cutaneous neurofibromatosis type I and kyphoscoliosis of the thoracic spine upon medical examination. In the majority of such cases, these meningoceles remain asymptomatic, but surgery is indicated when giant or symptomatic cysts are present. The large thoracic meningocele was successfully extirpated through the transthoracic approach in combination with lumbar puncture and cerebrospinal drainage for decompression of the cyst.

Key words: 1. Mediastinal disease  
2. Cysts  
3. Thoracic meningocele

### CASE REPORT

A 46-year-old male who was previously healthy visited our hospital due to increasing chest discomfort and dyspnea on effort over the previous 3 months. At the time when the patient visited the hospital, skin lesions with brown pigmentation, moderate thoracic vertebral deformity, and a decrease in lung sounds in the right upper lung zone were noted on his physical examinations. In his first simple chest X-ray, a well defined huge mass of the right upper lung field was detected. In the chest computed tomography, there was a cyst with a density similar to cerebral spinal fluid that was connected to the intervertebral foramen between the third and fourth thoracic vertebrae. Furthermore, the cyst that had a high signal in the MRI T2 image did not have any connection with the spine (Fig. 1).

This case had compression symptoms due to the thoracic

meningocele, so we decided to do a surgical resection. After the induction of general anesthesia, the patient was positioned in the left supine position. In order to decompress the thoracic meningocele, we performed a lumbar puncture and cerebrospinal fluid (CSF) drainage. After a thoracotomy, we removed the pleural adhesions and dissected from the dura mater surrounding the thoracic meningocele including the parietal pleura to the space nearby the intervertebral foramen by extrapleural dissection. After removing the meningocele, we sutured the remaining dura mater with nonabsorbable 5-0 Prolene performing microsurgery (NC4, Kalzeiss, X20) through the intervertebral foramen. Finishing anastomosis, we filled the thoracic cavity with normal saline. Under the state of intrathoracic positive pressure, we confirmed the absence of CSF leakage. We then augmented the anastomosis site with parietal pleura and surrounding mediastinal tissues (Fig. 2). To identify the rupture of the suture site, we placed an

\*Department of Thoracic and Cardiovascular Surgery, Konyang University Hospital

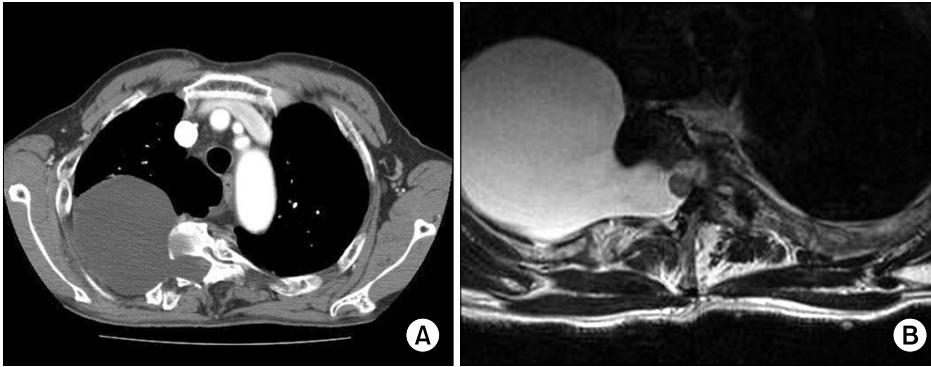
Received: October 1, 2010, Revised: July 4, 2011, Accepted: August 16, 2011

Corresponding author: Hyun-Min Cho, Department of Thoracic and Cardiovascular Surgery, Konyang University Hospital, 685, Gasuwon-dong, Seo-gu, Daejeon 302-801, Korea

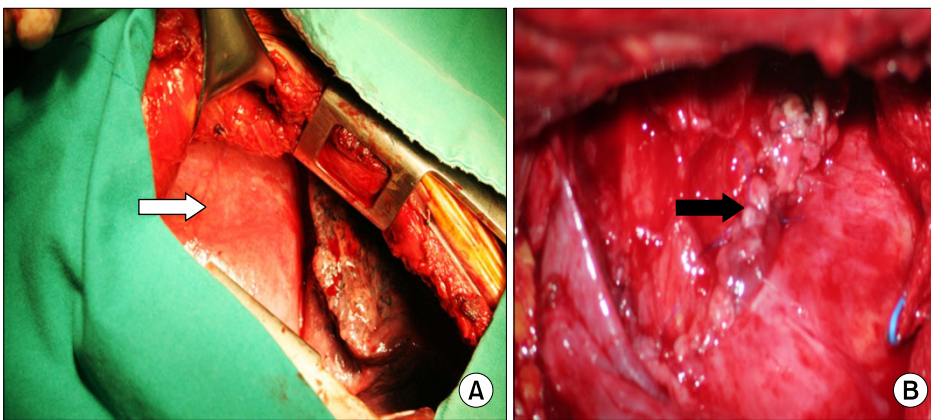
(Tel) 82-42-600-9150 (Fax) 82-42-600-9090 (E-mail) csking1@konyang.ac.kr

© The Korean Society for Thoracic and Cardiovascular Surgery. 2011. All right reserved.

© This is an open access article distributed under the terms of the Creative Commons Attribution Non-Commercial License (<http://creativecommons.org/licenses/by-nc/3.0>) which permits unrestricted non-commercial use, distribution, and reproduction in any medium, provided the original work is properly cited.

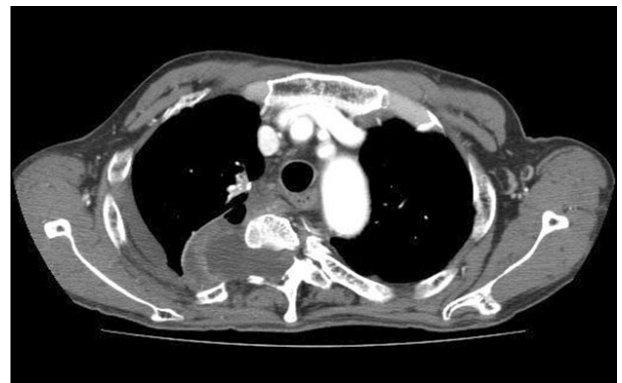

**Fig. 1.** Preoperative chest computed tomogram (A) shows an approximately 7.5-cm cystic mass arising from the right side of the T4 spinal canal. A T2-weighted magnetic resonance image (B) shows CSF signal intensity meningeal protruded cystic lesion(s) through the right neural foramen at T2 (1.5×0.9 cm).



**Fig. 2.** Intraoperative findings. (A) A huge cystic mass is located in the upper posterior mediastinum (white arrow). (B) After excision of the mass, the dura mater was carefully repaired under microscopy and reinforced with the mediastinal pleura (black arrow).

intrathoracic drainage tube near the suture site and sutured the thoracotomy site. We prevented an abrupt CSF pressure elevation by keeping a constant pressure level of the suture site by controlling the amount drainage from the CSF drainage tube after the surgery. The patient was extubated immediately after the operation, stayed in the intensive care unit (ICU) without any problems and was transferred to a general ward the next day. We removed the chest tube on the seventh postoperative day after confirming that there were no complications such as suture site rupture or CSF leakage by chest computed tomography (Fig. 3). After the surgery, the patient did not suffer from chest discomfort or dyspnea anymore. He was discharged from the hospital on the fourteenth postoperative day and is now receiving regular outpatient follow-up care. He is doing well, and other than pain on the surgery site, he is without any complications such as the recurrence of thoracic meningocele or rupture of the suture site at one year follow-up.



**Fig. 3.** Postoperative chest computed tomogram shows a markedly decreased cystic mass of the posterior mediastinum and no sign of CSF leakage.

## DISCUSSION

A thoracic meningocele is a cyst which is filled with CSF and arises in the posterior mediastinum. The mechanism by

which a thoracic meningocele develops is the protrusion of the dura mater through an abnormally enlarged intervertebral foramen, which is caused by bony defects or vertebral deformities. Phol reported the first case in 1993 [1]. A congenital meningocele develops rarely compared to an acquired meningocele, which can often occur after post-laminectomy. In fact, only 150 cases of thoracic meningocele had been reported up to 2003 [2]. Type I neurofibromatosis can be combined with it in 60-85% of all patients [3], and there are some combined musculoskeletal deformities such as scoliosis, kyphosis, kyphoscoliosis, and developmental impairment of the muscles of nearby vertebrae [2,4]. Thoracic mucocèles are commonly detected in those aged in their thirties to fifties. They are also known to be slightly female predominant. However, there have been cases reported at ages ranging from two months to 73 years old. Though there are many cases of asymptomatic thoracic meningoceles, it can cause symptoms such as thoracic vertebral pain, radicular pain, headache, cough, dyspnea, or dysphagia due to pulmonary or mediastinal compression. It can also cause sensory abnormalities when it is involved in the spine. There have been rare reports of spontaneous rupture of a cyst [3,5]. If a patient has symptoms of a thoracic meningocele, surgical therapy can be considered [4,6]. Various surgical techniques can be applied according to the size of the cyst. If the cyst is small, it can be removed through a posterior laminectomy and when a cyst is medium or large, surgery can be performed through a costotransversectomy [5,7]. However, when it comes to a case combined with kyphoscoliosis, it is not easy to suture the meningocele through a posterior laminectomy. In addition, it can bring about instability of the vertebrae after the removal of the meningocele; posterior spinal arthrodesis as well as anterior spinal arthrodesis might be needed. The approach of thoracotomy for surgical thoracic meningocele removal or ligation is especially useful whenever a wider operative field is needed for complete resection of the cyst and anastomosis of the dura mater. However, this method has the drawback of requiring chest tube drainage and introducing the possibility of intrathoracic CSF fistula if the anastomosis of the dura mater is not complete. Recently, there was a report of shunting between a cyst and the peritoneum because the cyst was huge enough to involve the whole thoracic cavity and too

large for the patient to complain of dyspnea at rest [6,8].

In the present case, the cyst was relatively large and there were adhesions between the cyst and pleura, so we concluded that a thoracotomy would be needed for complete resection of the cyst. We performed lumbar puncture and CSF drainage for proper control of the intracystic pressure level and the minimization of spinal injury. The dura mater was anastomosed through a microscopic surgery after the resection of the cyst. Then under positive intrathoracic pressure, we confirmed no leakage of CSF and we augmented the anastomosis site with parietal pleura, mediastinal pleura, and nearby soft tissues. We kept the lumbar CSF drainage tube during the recovery period to prevent the suture site from rupture by an abrupt increase in the intraspinal pressure level. Among the surgical therapies for thoracic meningocele, obtaining a broad operative field through thoracotomy is a good method for simplifying the resection of a cyst, suturing the dura mater, identifying the leakage of the anastomosis site, and performing a supplementary augmentation for leakage. As postoperative CSF leakage is the most serious potential complication, doing both a lumbar puncture and CSF drainage at the same time is helpful for maintaining constant intraspinal pressure and minimizing the ischemic injury and herniation of the spine. In the end, they can help to prevent postoperative complications and improve the result of the treatment.

According to the review of the literature, there have been two cases of recurrence [7,8]; both of them were huge meningoceles and they recurred by the dysplasia of the remaining dura mater. Therefore, the authors recommended that immediate postoperative myelotomography should be performed. So as to prevent recurrence and reduce complications after surgery, we think that it is advantageous to leave relatively normal dural tissues, to suture them, to augment the suture site with surrounding mediastinal tissues including parietal pleura, and to perform both lumbar puncture and CSF drainage at the same time during the operation.

In this case, postoperative chest computed tomography showed a remaining cystic lesion in the mediastinum. We believe that this was the protrusion of the suture site, in which there was a cystic lesion that remained during the suture, using relatively normal tissues, and was caused by the increase of intraspinal pressure during the operation. For the patient,

regular check-ups would be needed to screen for recurrence from the remaining cystic lesion or occurrence of a meningo-pleural fistula.

## REFERENCES

1. Phol R. *Meningocele in brustraum uter dem bilde eines intra-thoraken rundschantens*. Rontgenpraxis 1933;5:747-9.
2. Calzabara PG, Caralion A, Anzola GP, Pasolini MP. *Segmental neurofibromatosis: case report and review of the literature*. Neurofibromatosis J 1988;1:318-22.
3. De Andrede GC, Braga OP, Hisatugo MK, De Paiva Neto MA, Succi E, Braga FM. *Giant intrathoracic meningoceles associated with cutaneous neurofibromatosis type I*. Arq Neuropsiquiatr 2003;61:677-81.
4. Geerts Y, Marchau M. *Intrathoracic meningocele*. J Spinal Disord 1992;5:116-21.
5. Ebara S, Yuzawa Y, Kinoshita T, et al. *A neurofibromatosis type I patient with severe kyphoscoliosis and intrathoracic meningocele*. J Clin Neurosci 2003;10:268-72.
6. Vanhauwaert DJ, Deruytter MJ. *Cystoperitoneal shunt as alternative treatment for a giant thoracic meningocele in a patient with neurofibromatosis*. Surg Neurol 2008;69:535-7.
7. Bogedain W, Carpathios J, Lawand F. *Intrathoracic meningocele: case report with preoperative diagnosis*. Am Rev Resp Dis 1963;87:757-61.
8. Eideken J, Lee F, Libshitz H. *Intrathoracic meningocele*. Am J Roentg Rad Nucl Med 1969;106:381-4.