

Single stage ventral onlay buccal mucosal graft urethroplasty for navicular fossa strictures

Puskar Shyam Chowdhury, Prasant Nayak, Sujata Mallick¹, Srinivasan Gurumurthy, Deepak David, A. Mossadeq

Departments of Urology, and ¹Pathology, Mahatma Gandhi Medical College and Research Institute, Puducherry, India

ABSTRACT

Introduction: The correction of fossa navicularis strictures poses a distinct reconstructive challenge as it requires attention to cosmesis, in addition to urethral patency. Different graft and flap based repairs have been described with variable success rates. However, the ideal management remains unclear. The feasibility and efficacy of a single stage ventral onlay buccal mucosa graft urethroplasty (VOBMGU) for navicular fossa strictures (NFS) was evaluated in the present study.

Subjects and Methods: All patients with NFS attending urology out-patient department from March, 2009 onward accepting VOBMGU were evaluated prospectively. Patients with minimum 1 year of follow-up were included for analysis. The technique involves opening the diseased stenosed meatus ventrally up to the corona. The diseased mucosa is excised leaving a midline strip of native urethral mucosa on the dorsal side. The buccal mucosal graft (BMG) is fixed on either side of this strip over a 24 Fr. silicone catheter. The glans wings are apposed in midline taking anchoring bites on the mucosal graft ventrally. Post-operatively patients were reviewed at 1, 3, 6 and 12 months and annually thereafter. Cosmetic acceptance and splaying of the urinary stream was assessed with individual questionnaires.

Results: A total of six patients underwent VOBMGU. Average flow rate at 3 months post-operatively was 12 ml/s. The end result was cosmetically highly acceptable. There was no fistula in any of the cases. With a median follow-up of 37 months, only one patient had a recurrence of stricture in a proximal site.

Conclusions: VOBMGU is a viable technique for reconstruction of NFS with promising short term results. However, long-term follow-up is necessary.

Key words: Buccal mucosa graft, navicular fossa stricture, ventral onlay

INTRODUCTION

Stricture of urethra involving navicular fossa and external meatus is a common occurrence in adult men as the distal urethra is susceptible to trauma, infection and inflammatory diseases like lichen sclerosus et atrophicus (LSA).^[1] Reconstruction of glanular urethra is particularly challenging as it entails not only achieving a functional urethral outlet, but also a cosmetically acceptable external meatus.^[1,2] Different

graft and flap based repairs have been described with variable success rates.^[1-9] However, the ideal management of navicular fossa strictures (NFS) remain unclear. The presence of LSA and the condition of the urethral plate are important factors influencing the choice of the reconstructive technique.^[1,10-12] These may necessitate excision of the strictured urethra and substitution with extragenital tissue grafts.^[1,13-16] This generally requires a multistage approach, which may not be desirable to most patients. We report our results with ventral onlay buccal mucosa graft urethroplasty (VOBMGU) in a single stage repair of NFS.

SUBJECTS AND METHODS

The data of all men with stricture urethra, confined exclusively to the navicular fossa, who underwent single stage urethroplasty using VOBMGU was collected prospectively from 2009 to 2012. The study was approved by our institutional review board. Patients with NFS were evaluated with a medical history, subjective assessment of voiding symptoms with American Urological Association (AUA) symptom score and uroflowmetry test with ultrasound

For correspondence: Dr. Puskar Shyam Chowdhury, SF-1, Maragatham Apartment, Ellaipillaichavadi, Puducherry - 605 005, India. E-mail: puskaridoc@yahoo.com

Access this article online	
Quick Response Code: 	Website: www.indianjurol.com
	DOI: 10.4103/0970-1591.124200

assessment of post-void residual urine volume. The extent of the stricture was assessed and coexisting proximal urethral strictures were ruled out by combined retrograde urethrography and voiding cystourethrography (VCUG) and urethroscopy using a 6.5 Fr. pediatric cystoscope pre-operatively [Figure 1]. All cases with stricture confined to the navicular fossa were included in the study. Patients with strictures extending beyond corona, with the history of prior surgeries (including extended meatotomy, attempts of repair with either flap or graft-based techniques) or with a follow-up of <12 months were excluded from the study. Full written informed consent was obtained from each patient after explanation of all the available techniques for male distal urethral reconstruction.

Surgical technique

Under general anesthesia, the patient was positioned supine on the operating table. Pre-operative cystoscopy with pediatric cystoscope was done to confirm that the stricture was limited exclusively to the navicular fossa. If the meatus was too tight to allow the pediatric scope, urethroscopy was performed after splitting the meatus ventrally. At first, the meatus was slit ventrally up to the corona [Figure 2a]. Stay sutures were placed on each of the glans flaps to aid in retraction. Glans wings were raised at the level of corona from the corporal bodies to get enough mobility for tension free apposition of the reconstructed glanular urethra. In all cases of non-LSA strictures, a dorsal strip of native urethral mucosa was preserved as far as available and remaining diseased mucosa resected. Among the LSA stricture cases, patients who had the navicular fossa entirely obliterated, the entire unhealthy mucosa was resected. However in the remaining LSA cases a relatively healthy dorsal mucosal strip of about 3 mm. was conserved. The fibrotic segments were resected up to about 5 mm of the proximal healthy urethra and then patency of the proximal urethra was confirmed with a 24 Fr. sound.

A rectangular BMG with an approximate length of 3 cm and width of 1.5-2.5 cm (depending upon the length of the defect) was harvested and defatted using standard technique with special care to avoid the oral commissure and the opening of Stensen's duct.^[17-20] The graft was transversely

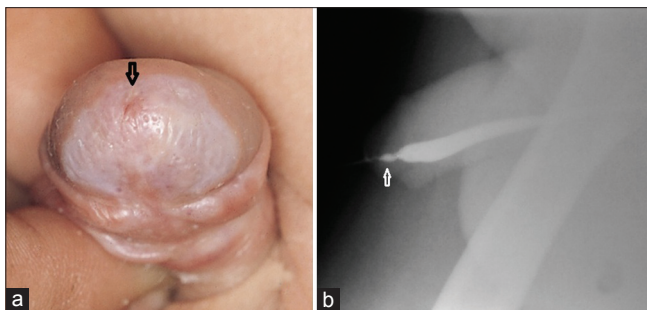


Figure 1: (a) Meatal stenosis due to lichen sclerosus et atrophicus (black arrow). (b) Micturating cystourethrogram urethrogram showing stricture of urethra limited exclusively to navicular fossa (white arrow)

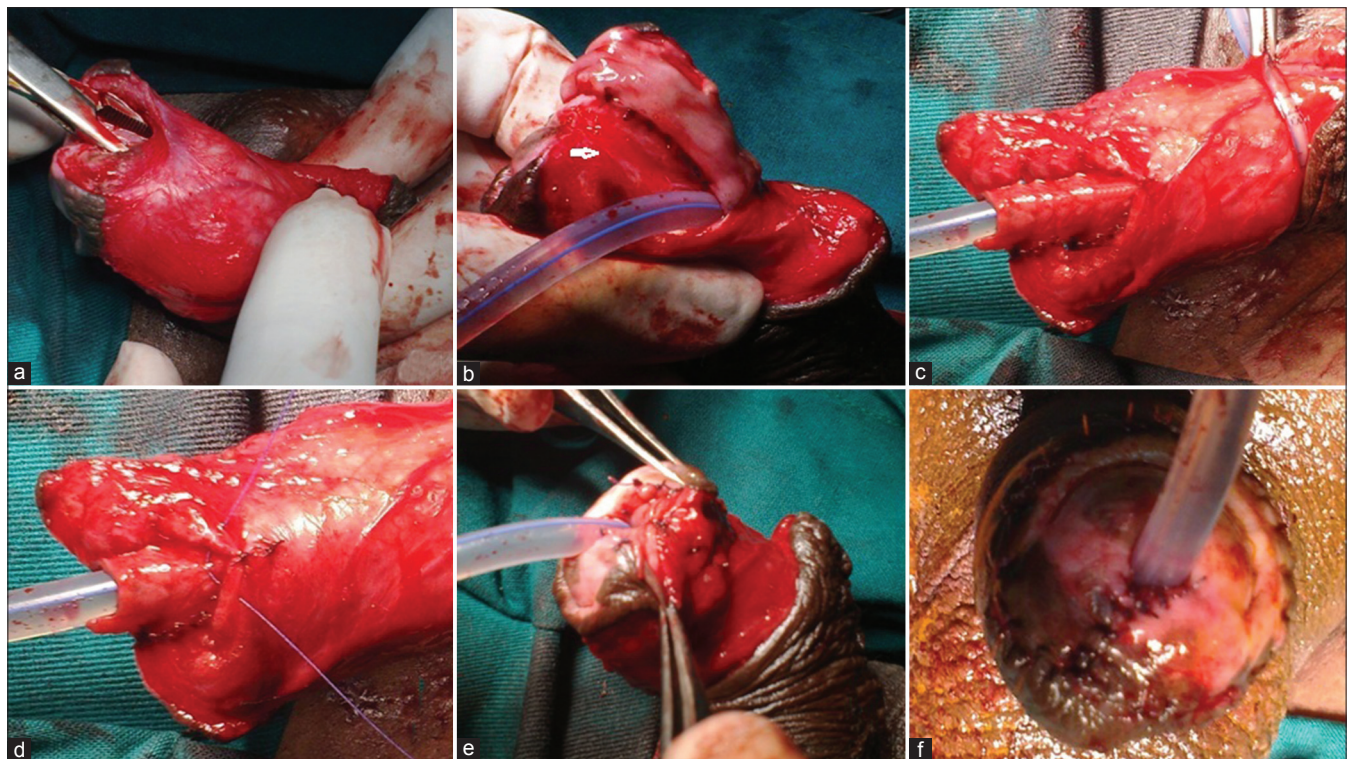


Figure 2: (a) The stenosed meatus is slit open ventrally up to corona. (b) Buccal mucosal graft (BMG) sutured to the lateral side of preserved dorsal mucosal strip (white arrow). (c) BMG rolled over 24 Fr. catheter and sutured to the other free edge of conserved mucosal strip. (d) First layer of glans wings being opposed with anchoring suture on the BMG ventrally. (e) Glans wings being closed in three layers. (f) Neomeatus reconstructed by suturing the distal end of graft along the initial ventral meatal slit allowing free movement of 24 Fr. catheter

oriented and one short free edge was then anastomosed to the lateral margin of the native mucosal strip along with the underlying glans tissue [Figure 2b]. The graft extends from the proximal healthy urethra to the site of the intended neomeatus. Then, the graft was rolled over a 24 Fr. silicone catheter with its mucosal surface facing inward [Figure 2c]. Its long edge was sutured circumferentially to the healthy proximal urethral mucosa using fine polyglactin sutures. Once the proximal anastomosis of the BMG was completed, the free edge of the graft was sutured to the free edge of the native mucosal strip dorsally in a proximal to distal fashion on the other side [Figure 2c]. Glans apposition was started proximally. During the first (innermost) layer of glans apposition, anchoring bites were taken on the graft in the midline, ventrally [Figure 2d]. This ensured a three point fixation of the graft thereby providing stability to the same. Then the glans wings were apposed ventrally in two more layers with horizontal mattress sutures [Figure 2e]. Neomeatus was reconstructed by suturing the distal edge of the BMG to the margins of the initial ventral slit made on the meatus, allowing the passage of the 24 Fr. catheter freely [Figure 2f]. 24 Fr. silicone catheter was replaced by a 20 or 22 Fr. silicone Foley catheter. Gauze soaked in antibiotic ointment was placed around the meatus and the Foley catheter was taped and fixed to the abdomen for 1 week to immobilize the VOBMG during graft take.

The Foley catheter was generally kept in place for 10 days. The urinary pattern was assessed after its removal by uroflowmetry. Post-operative data were prospectively recorded during an initial visit at 7 days after urethral catheter removal, at 1, 3 and 6 months and then annually thereafter. During each visit, patients underwent subjective assessment of voiding symptoms with AUA symptom score and objective calibration of the distal urethra with an 18 Fr. catheter as well as uroflowmetric studies with post-void residual determination.

All patients were followed for urinary pattern changes, lower urinary tract symptoms and reassessed with VCUG and urethroscopy in the case of recurrent symptoms. A successful outcome was defined as the subjective and objective improvement in urinary flow with maintenance of glanular shape and the absence of any need for further urethral instrumentation during follow-up [Figure 3]. Post-operative splaying of urine and cosmetic acceptance were assessed by simple individual questionnaires [Figure 4a-c]. The mean of pre-operative AUA symptom score and Q-max measurements were compared with post-operative values obtained at the last follow-up. All variables were categorical and percentage and proportions were calculated manually.

RESULTS

A total of 9 cases of exclusive NFS were operated in this study period. Of these, 2 patients opted for ventral meatotomy and

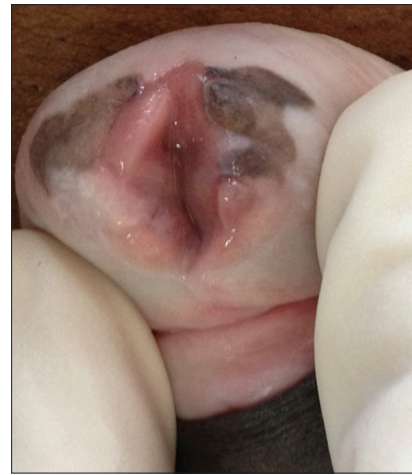

Figure 3: Final cosmetic appearance of the neomeatus one year after surgery

7 patients underwent VOBMGU. One was lost in follow-up after initial 3 months.

Among the remaining 6 patients, [median age 42.5 years, Table 1] LSA was the cause of stricture in three cases (50%) (as evidenced by pre-operative or intraoperative biopsy). Two cases had previous instrumentations for transurethral resection of prostate and ureterorenoscopy respectively and one case had a history of prolonged catheterization. With a median follow-up of 37 months (range 12-96 months), success was achieved in 5 (83%) patients. One patient with LSA developed stricture at the site of the proximal anastomosis and was managed with urethrotomy followed by intermittent urethral self-calibration. A cosmetic and functional distal urethra was obtained in all the remaining cases [Figure 3]. The mean substituted urethral defects after resection measured 1.5 cm (range 1-2.5 cm). At the last follow-up, the mean Q_{max} (ml/s) increased from 6.5 ± 2.3 pre-operatively to 24.3 ± 7.2 post-operatively and the mean AUA score decreased from 26.8 ± 3.4 pre-operatively to 10 ± 4 post-operatively. Three patients had no splaying of the urinary stream and out of the remaining, two had mild and only one had moderate splaying [Figure 4a and b]. Splaying subsided in all cases within 6 months. Three patients were very pleased, two were pleased and one was unhappy with the final cosmetic appearance [Figure 4c].

DISCUSSION

Strictures involving navicular fossa are particularly challenging because successful reconstruction requires the creation of a functional urethral conduit as well as maintaining a cosmetically appealing glans penis. Ventral meatotomy, onlay urethroplasty using transverse island ventral penile skin flap, two stage repair using BMG etc.,^[1-11] are the commonly used reconstructive options for the management of distal strictures. An ideal urethral substitute should have a dependable blood supply, absence of hair follicles, excellent applicability and immunity

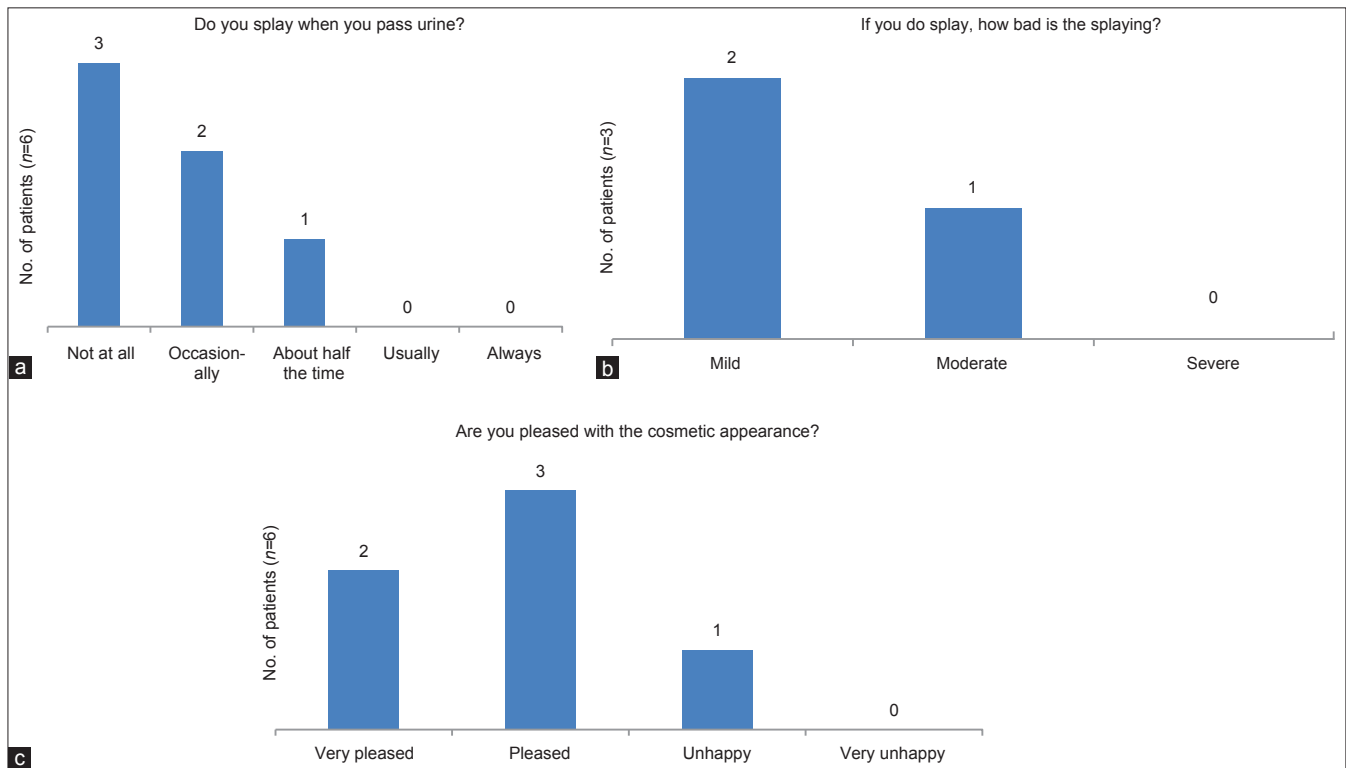


Figure 4: (a) Chart showing the number of patients having splaying of urine at 1 month of follow-up. (b) Degree of splaying of urine in patients who had splaying. (c) Cosmetic acceptance by patients at 1 month follow-up

Table 1: Patient characteristics (n=6)

Characteristic	Median	Range
Age (year)	42.5	27-62
Stricture length (cm)	1.5	1-2.5
Breadth of dorsal strip preserved (mm)	3	0-4
BMG length (cm) used for substitution	2	1.5-3
Pre-operative Qmax (ml/s)	6.5	4-10
Post-operative Qmax (ml/s)	24	14-34
Pre-operative AUA score	27	22-31
Post-operative AUA score	8	7-18
Follow-up (months)	37	12-96

Qmax=Peak urinary flow rate, AUA=American urological association, BMG=Buccal mucosal graft

from progression of the disease process.^[6,9] Urethral substitution for an obliterative process, mandates a more complex reconstructive procedure. Management of these strictures requires a customized approach, taking into account the length and etiology of the stricture, patient expectations and surgeon’s experience. For example, strictures associated with LSA may require excision of the diseased urethra and substitution with a multistage approach,^[10-13] which would not appeal to most adult men. The psychological distress of multiple procedures, loss of work and the inability to stand during voiding until the repair may outweigh the benefits of 2-stage repairs. Even the distorted hypospadiac meatal appearance following

a ventral meatotomy^[21] or Blandy’s urethroplasty^[22] may not be acceptable to most adult males.

Our results suggest that VOBMGU is a viable single-stage reconstructive alternative in the management of NFS confined to the glanular urethra. Half of our patients had LSA. LSA involvement of the urethra ranges from isolated meatal stenosis to panurethral disease. In most instances, the most severe inflammatory reaction in LSA is seen at the meatus and distal urethra, which compromises a successful stricture repair because of the recalcitrant nature of this disease.^[11,11,12] Therefore, excision of the diseased urethra and one or two stage urethroplasty using extragenital tissue grafts has been advocated in patients with LSA.^[11-13] In our present cohort, we excised the diseased urethra entirely in two cases of LSA because of severe stenosis. However, in one case of LSA-related stricture and all non-LSA strictures, a narrow 2-3 mm of native mucosal strip was preserved on the dorsal side. When the urethral plate is severely stenosed complete replacement of the diseased, fibrotic mucosa with BMG in a circular form still renders a 1-stage reconstruction possible in the case of glanular urethral strictures. The outcome is also cosmetically appealing. Nevertheless, VOBMGU reconstruction may not be suitable in longer strictures extending beyond corona, because of lack of ventral support proximally. However, in patients with a ventrally displaced external meatus because of previous operations (such as meatotomy and hypospadias repairs) this approach may still be possible if meatotomy is not extended

proximally beyond the corona. In the VOBMGU procedure, the anastomosis with the healthy proximal mucosa can be done under vision by the wide ventral meatotomy incision. The suture lines of the BMG with the native mucosal strip do not overlie the apposing ventral suture line of the glans wings. The robust buccal mucosa with its panlamina propria provides a continuous tissue layer, over which the glans wings are apposed ventrally. This may be hypothesized to be responsible for the excellent functional outcome without any post-operative fistula.

Traditionally, the use of BMG as a circumferential graft has been approached with caution in the literature because of its high overall failure rates compared with onlay or 2-stage techniques.^[14-16] However in recent times, reports have revealed an improved success rates with circular BMG for urethral substitution.^[23,24] The data presented by Barbagli *et al.* is encouraging and it suggests that circular BMG may be a feasible option in the management of bulbar urethral strictures because of good vascularity in this area.^[23] They treated five patients with bulbar strictures (2-4.5 cm in length) with circular BMG and reported no complications with a mean follow-up of 38 months. Likewise, we have successfully used VOBMGU for one-stage reconstruction of glanular urethral strictures because the glans penis has a good blood supply, providing an efficient circumferential graft take.^[24] The long-term result of graft take in glans penis is encouraging, as an evident from their frequent use in Hypospadias surgery.^[25-28] In a recent study, Gelman and Sohn presented their experience with 1-stage reconstruction of obliterative distal urethral strictures with combined BMG urethral plate reconstruction and onlay penile skin flap.^[8] They reported no urinary obstructions in 12 patients treated with this technique with a mean follow-up of 39 months. Despite presenting an attractive 1-stage alternative to tube flaps and grafts, these authors did not report on the incidence of LSA in their series. There is a quantum of evidence that LSA is prone to recur if local tissues are used for reconstruction.^[29-31] BMG is a robust graft which is most resistant to LSA.^[11-13,29-31] Onol *et al.* in their series of circular BMG for distal urethral strictures have reported impressive results in the short term follow-up.^[24] However, this technique employs a tubular BMG, which is only fixed at the proximal and distal anastomotic line without any fixation along its length. In our technique, the BMG is not only fixed proximally and distally, but also along the lateral margins on both sides with an anchoring midline suture ventrally. This provides stability to the graft and obliterates any free space between the graft and the bed, preventing any hematoma formation underneath, which would have made the graft take precarious. The 5-0 vicryl sutures apposing the superficial layer of ventral meatotomy leaves almost no appreciable scar at 1 year follow-up [Figure 3]. Thus, a highly acceptable cosmetic outcome may be achieved without compromising on the graft uptake as the entire graft placement and fixation is done under vision.

One of the drawbacks of our study is its limited size. A multi-institutional trial with greater numbers, comparing outcomes between VOBMGU, 1-stage combined flap-graft or 2-stage reconstructions will probably better address the advantages of our approach for specific causes of strictures (e.g., traumatic vs. LSA). Although all patients had at least 1 year follow-up, the median follow-up duration of 37 months may not be sufficient to evaluate the long-term outcomes of VOBMGU urethroplasty in this cohort composed partly of patients with LSA. Nevertheless, we decided to report our experience as there is a dearth of experience and information and a lack of consensus on the management of distal urethral strictures. The armamentarium of the reconstructive urethral surgeon is a continuously evolving process and requires familiarity with new concepts and concerns.

CONCLUSIONS

Our results suggest VOBMGU as a feasible alternative in one-stage reconstruction of NFS confined to the glanular urethra. It is easily replicable and has an impressive functional and cosmetic outcome. However, we do not advocate VOBMGU in longer strictures extending proximal to the corona, that may be best treated with other graft or flap-based techniques.^[11,13] Larger scale, long-term studies are necessary to determine the optimum reconstructive approach for the individual setting.

ACKNOWLEDGMENT

The authors would like to thank all faculty and staff of Urology, Anesthesiology, Pathology and Radiology Departments of MGMCRI.

REFERENCES

1. Singh SK, Agrawal SK, Mavuduru RS. Management of the stricture of fossa navicularis and pendulous urethral strictures. *Indian J Urol* 2011;27:371-7.
2. Tonkin JB, Jordan GH. Management of distal anterior urethral strictures. *Nat Rev Urol* 2009;6:533-8.
3. Meeks JJ, Barbagli G, Mehdiratta N, Granieri MA, Gonzalez CM. Distal urethroplasty for isolated fossa navicularis and meatal strictures. *BJU Int* 2012;109:616-9.
4. Jordan GH. Reconstruction of the fossa navicularis. *J Urol* 1987;138:102-4.
5. Armenakas NA, Morey AF, McAninch JW. Reconstruction of resistant strictures of the fossa navicularis and meatus. *J Urol* 1998;160:359-63.
6. Armenakas NA, McAninch JW. Management of fossa navicularis strictures. *Urol Clin North Am* 2002;29:477-84.
7. Goel A, Goel A, Dalela D, Sankhwar SN. Meatoplasty using double buccal mucosal graft technique. *Int Urol Nephrol* 2009;41:885-7.
8. Gelman J, Sohn W. 1-stage repair of obliterative distal urethral strictures with buccal graft urethral plate reconstruction and simultaneous onlay penile skin flap. *J Urol* 2011;186:935-8.
9. Onol SY, Onol FF, Onur S, Inal H, Akbaş A, Köse O. Reconstruction of strictures of the fossa navicularis and meatus with transverse island fasciocutaneous penile flap. *J Urol* 2008;179:1437-40.
10. Venn SN, Mundy AR. Urethroplasty for balanitis xerotica obliterans. *Br J Urol* 1998;81:735-7.

11. Dubey D, Sehgal A, Srivastava A, Mandhani A, Kapoor R, Kumar A. Buccal mucosal urethroplasty for balanitis xerotica obliterans related urethral strictures: The outcome of 1 and 2-stage techniques. *J Urol* 2005;173:463-6.
12. Levine LA, Strom KH, Lux MM. Buccal mucosa graft urethroplasty for anterior urethral stricture repair: Evaluation of the impact of stricture location and lichen sclerosus on surgical outcome. *J Urol* 2007;178:2011-5.
13. Kulkarni S, Barbagli G, Kirpekar D, Mirri F, Lazzeri M. Lichen sclerosus of the male genitalia and urethra: Surgical options and results in a multicenter international experience with 215 patients. *Eur Urol* 2009;55:945-54.
14. Patterson JM, Chapple CR. Surgical techniques in substitution urethroplasty using buccal mucosa for the treatment of anterior urethral strictures. *Eur Urol* 2008;53:1162-71.
15. Andrich DE, Mundy AR. Substitution urethroplasty with buccal mucosal-free grafts. *J Urol* 2001;165:1131-3.
16. Caldamone AA, Edstrom LE, Koyle MA, Rabinowitz R, Hulbert WC. Buccal mucosal grafts for urethral reconstruction. *Urology* 1998;51:15-9.
17. Eppley BL, Keating M, Rink R. A buccal mucosal harvesting technique for urethral reconstruction. *J Urol* 1997;157:1268-70.
18. Morey AF, McAninch JW. Technique of harvesting buccal mucosa for urethral reconstruction. *J Urol* 1996;155:1696-7.
19. Tolstunov L, Pogrel MA, McAninch JW. Intraoral morbidity following free buccal mucosal graft harvesting for urethroplasty. *Oral Surg Oral Med Oral Pathol Oral Radiol Endod* 1997;84:480-2.
20. Wood DN, Allen SE, Andrich DE, Greenwell TJ, Mundy AR. The morbidity of buccal mucosal graft harvest for urethroplasty and the effect of nonclosure of the graft harvest site on postoperative pain. *J Urol* 2004;172:580-3.
21. Morey AF, Lin HC, DeRosa CA, Griffith BC. Fossa navicularis reconstruction: Impact of stricture length on outcomes and assessment of extended meatotomy (first stage Johanson) maneuver. *J Urol* 2007;177:184-7.
22. Blandy JP, Tresidder GC. Meatoplasty. *Br J Urol* 1967;39:633.
23. Barbagli G, Palminteri E, Lazzeri M, Guazzoni G. One-stage circumferential buccal mucosa graft urethroplasty for bulbous stricture repair. *Urology* 2003;61:452-5.
24. Onol SY, Onol FF, Gümüş E, Topaktaş R, Erdem MR. Reconstruction of distal urethral strictures confined to the glans with circular buccal mucosa graft. *Urology* 2012;79:1158-62.
25. Leslie B, Lorenzo AJ, Figueroa V, Moore K, Farhat WA, Bağli DJ, *et al.* Critical outcome analysis of staged buccal mucosa graft urethroplasty for prior failed hypospadias repair in children. *J Urol* 2011;185:1077-82.
26. Fichtner J, Filipas D, Fisch M, Hohenfellner R, Thüroff JW. Long-term followup of buccal mucosa onlay graft for hypospadias repair: Analysis of complications. *J Urol* 2004;172:1970-2.
27. Dessanti A, Iannuccelli M, Ginesu G, Feo C. Reconstruction of hypospadias and epispadias with buccal mucosa free graft as primary surgery: More than 10 years of experience. *J Urol* 2003;170:1600-2.
28. Snodgrass W, Elmore J. Initial experience with staged buccal graft (Bracka) hypospadias reoperations. *J Urol* 2004;172:1720-4.
29. Bracka A. Re: Reconstruction of resistant strictures of the fossa navicularis and meatus. *J Urol* 1999;162:1389-90.
30. Pugliese JM, Morey AF, Peterson AC. Lichen sclerosus: Review of the literature and current recommendations for management. *J Urol* 2007;178:2268-76.
31. Depasquale I, Park AJ, Bracka A. The treatment of balanitis xerotica obliterans. *BJU Int* 2000;86:459-65.

How to cite this article: Chowdhury PS, Nayak P, Mallick S, Gurumurthy S, David D, Mossadeq A. Single stage ventral onlay buccal mucosal graft urethroplasty for navicular fossa strictures. *Indian J Urol* 2014;30:17-22.

Source of Support: Mahatma Gandhi Medical College & Research Institute,
Conflict of Interest: None declared.