



## Bankart versus Latarjet operation as a revision procedure after a failed arthroscopic Bankart repair

Sami Elamo, MD, MSc<sup>a,b,\*</sup>, Liisa Selänne, MD<sup>a</sup>, Kaisa Lehtimäki, MD<sup>a</sup>,  
Juha Kukkonen, MD, PhD<sup>b</sup>, Saija Hurme, MSc<sup>c</sup>, Tommi Kauko, MSc<sup>d</sup>,  
Ville Äärilä, MD, PhD<sup>a</sup>

<sup>a</sup> Division of Musculoskeletal Diseases, Department of Orthopaedics and Traumatology, Turku University Hospital and University of Turku, Turku, Finland

<sup>b</sup> Department of Orthopaedics and Traumatology, Satakunta Central Hospital, Pori, Finland

<sup>c</sup> Department of Biostatistics, University of Turku, Turku, Finland

<sup>d</sup> Auria Clinical Informatics, Hospital District of Southwest Finland, Turku, Finland

### ARTICLE INFO

#### Keywords:

Arthroscopic Bankart  
open Latarjet  
revision  
anterior shoulder instability  
shoulder dislocation  
patient reported outcome

Level of evidence: Level III; Retrospective  
Cohort Comparison; Treatment Study

**Background:** An arthroscopic Bankart operation is the most common operative procedure to treat shoulder instability. In case of recurrence, both Bankart and Latarjet procedures are used as revision procedures. The purpose of this study was to compare the re-recurrence rate of instability and clinical results after arthroscopic revision Bankart and open revision Latarjet procedures following failed primary arthroscopic Bankart operations.

**Methods:** Consecutive patients operatively treated for shoulder instability at Turku University Hospital between 2002 and 2013 were analyzed. Patients who underwent a primary arthroscopic Bankart operation followed by a recurrence of instability and underwent a subsequent arthroscopic Bankart or open Latarjet revision operation with a minimum of 1 year of follow-up were called in for a follow-up evaluation. The re-recurrence of instability, Subjective Shoulder Value, and Western Ontario Shoulder Instability index were assessed.

**Results:** Of 69 patients, 48 (dropout rate, 30%) were available for follow-up. Recurrent instability symptoms occurred in 13 patients (43%) after the revision Bankart procedure and none after the revision Latarjet procedure. A statistically and clinically significant difference in the Western Ontario Shoulder Instability index was found between the patients after the revision Bankart and revision Latarjet operations (68% and 88%, respectively;  $P = .0166$ ).

**Conclusions:** The redislocation rate after an arthroscopic revision Bankart operation is high. Furthermore, patient-reported outcomes remain poor after a revision Bankart procedure compared with a revision Latarjet operation. We propose that in cases of recurring instability after a failed primary Bankart operation, an open Latarjet revision should be considered.

© 2020 The Authors. Published by Elsevier Inc. on behalf of American Shoulder and Elbow Surgeons. This is an open access article under the CC BY-NC-ND license (<http://creativecommons.org/licenses/by-nc-nd/4.0/>).

Anterior-inferior shoulder instability is a frequent disorder among young adults.<sup>6</sup> It poses severe limitations on daily activities and quality of life. Moreover, it wears out the glenohumeral cartilage and predisposes to later osteoarthritis.<sup>20</sup> An arthroscopic Bankart procedure is the most common and widely used surgical intervention to treat this disorder.<sup>4</sup> In this operation, the torn labrum and inferior glenohumeral ligaments are anatomically reattached

to the glenoid rim with suture anchors<sup>5,24</sup> to re-establish the anatomy and stability of the joint.

Despite operative treatment, instability may recur in up to 40% of patients after a Bankart procedure.<sup>10,14</sup> In such cases, either a revision Bankart or an alternative procedure must be considered. In an open Latarjet operation, the coracoid process of the scapulae together with the conjoint tendon is non-anatomically transferred through the subscapularis muscle to the neck of the glenoid.<sup>8,17</sup> The Latarjet operation has been reported to yield high success rates as a primary operation, with rates of recurrence of instability ranging from 0% to 10%.<sup>2,15,19</sup> However, there are only 3 studies reporting the results of an open Latarjet operation as a revision surgical procedure after failed arthroscopic repair.<sup>7,11,21</sup> Moreover, no studies have

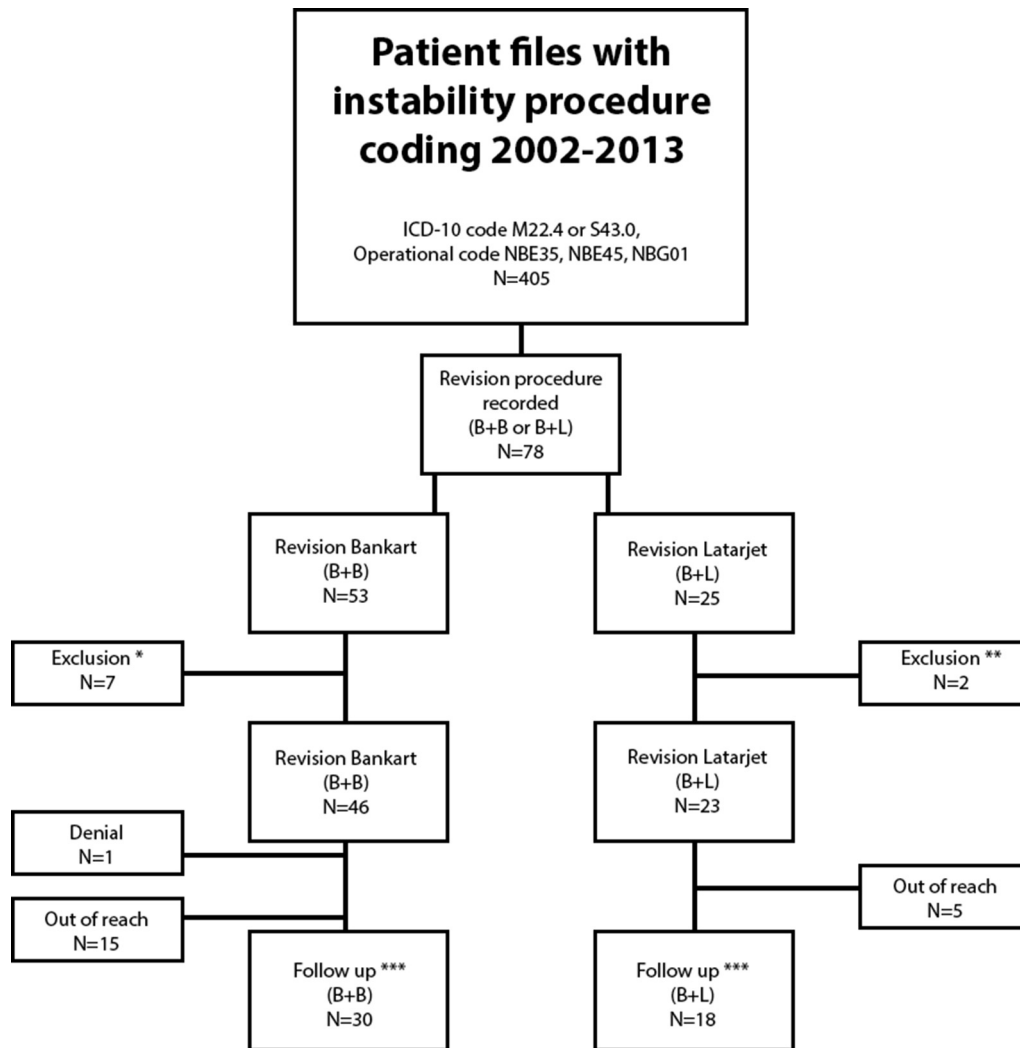
Institutional Review Board approval was received from Varsinais-Suomen sairaanhoitopiiri (Hospital District of Southwest Finland) (research number T145/2013)/Eettinen toimikunta (ETMK no. 27/1801/2013).

\* Corresponding author: Sami Elamo, MD, MSc, Department of Orthopedics and Traumatology, Satakunta Central Hospital, Sairaalan tie 3, FIN-28500 Pori, Finland.

E-mail address: [spelam@utu.fi](mailto:spelam@utu.fi) (S. Elamo).

<https://doi.org/10.1016/j.jseint.2020.01.004>

2666-6383/© 2020 The Authors. Published by Elsevier Inc. on behalf of American Shoulder and Elbow Surgeons. This is an open access article under the CC BY-NC-ND license (<http://creativecommons.org/licenses/by-nc-nd/4.0/>).



**Figure 1** Flowchart. \*Patients were excluded because the primary procedure was an open Bankart procedure ( $n = 3$ ), patients underwent an otherwise excluded procedure ( $n = 2$ ), or the shoulder had never dislocated ( $n = 2$ ). \*\*Nonrevision ( $n = 2$ ). \*\*\*Follow-up by either clinical assessment, patient-reported outcome measures, and radiographs or a phone call. ICD-10, *International Classification of Diseases, Tenth Revision*; B+B, revision Bankart procedure; B+L, revision Latarjet procedure.

compared the results of an arthroscopic Bankart revision and an open Latarjet revision after a primarily failed arthroscopic Bankart operation.

The aim of the study was to retrospectively assess and compare patient-reported outcomes and clinical results between an arthroscopic revision Bankart operation and an open revision Latarjet operation after failed arthroscopic primary Bankart stabilization. The hypothesis was that a revision Latarjet operation would yield better results in terms of clinical stability and subjective satisfaction than a revision Bankart procedure.

## Materials and methods

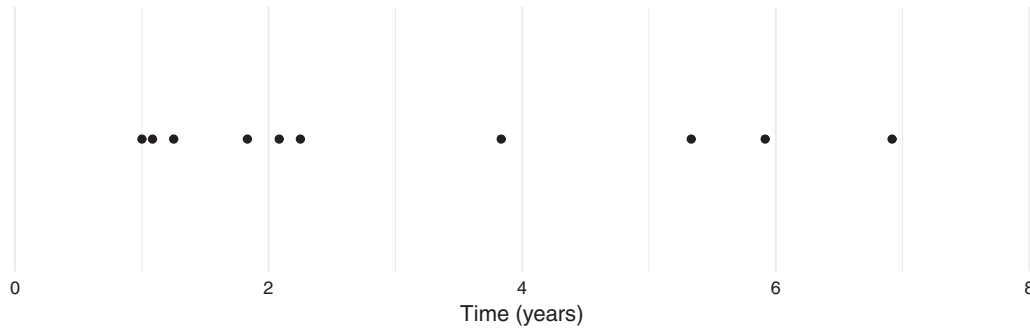
All patient files containing *International Classification of Diseases, Tenth Revision* codes for instability, subluxations, or dislocations of the shoulder and operational codes for arthroscopic Bankart and open Latarjet operations at Turku University Hospital during 2002 to 2013 were obtained. Patients with revision surgery for a failed arthroscopic Bankart operation, after anteroinferior shoulder instability, were identified. Data on patient age, sex, sports activities, initial Bankart operation, revision surgery, and recurrences of instability were obtained from the patient history and medical records. The patients were called in for a clinical follow-up, and plain

films of the operated shoulder were taken. The shoulders were clinically examined for anteroinferior stability (apprehension and relocation tests<sup>9,22</sup>) by an independent investigator (S.E.). The Subjective Shoulder Value (SSV)<sup>12</sup> and Western Ontario Shoulder Instability (WOSI) index<sup>16</sup> were recorded. Patients who declined the follow-up visit were interviewed by phone.

Plain films prior to and after the initial operation and at the follow-up were evaluated by 2 authors (S.E. and V.Å.). The degenerative changes in the glenohumeral joint were graded according to the Samilson-Prieto classification.<sup>20</sup>

**Table 1**  
Demographic characteristics

	Revision Bankart procedure	Revision Latarjet procedure
n	30	18
Available for clinical assessment, n	26	15
Male sex, n (%)	21 (81)	13 (87)
Age at primary operation, yr	27.9	26
Age at revision, yr	31.9	32.4
Contact sports, n (%)	12 (46)	9 (60)
Length of follow-up, yr	7.8	3.5



**Figure 2** Timeline of reoperations in revision Bankart group.

The primary outcome measure was treatment failure, defined as a recurrence of instability requiring surgical intervention or persisting subluxations and/or dislocations. Secondary measures included the SSV, WOSI index, and Samilson-Prieto grade. The patients were grouped according to the revision procedure as Bankart (group B) or Latarjet (group L). The data were analyzed using methods suitable for clinical trials regarding comparison of parallel treatment groups with repeated measurements. Repeated-measures analyses of variance together with generalized linear mixed models for longitudinal data and Cox regression models for survival data were used as the primary technique. The level of statistical significance was set at  $P = .05$ .

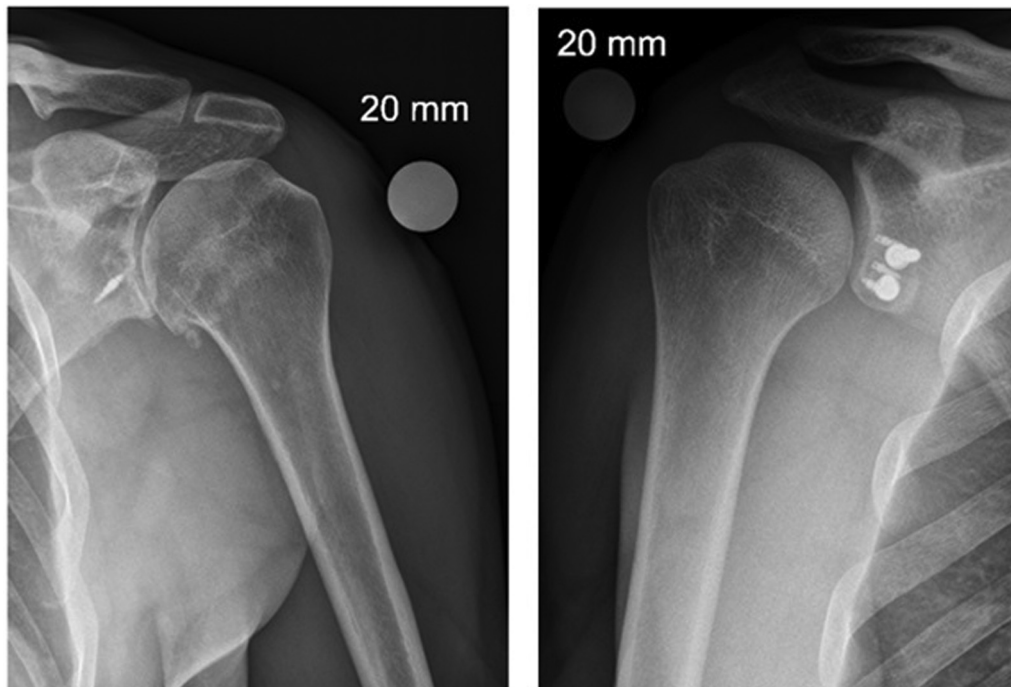
## Results

We identified 69 patients with revised primary Bankart procedures: 46 in group B and 23 in group L. Altogether, 41 patients were available for clinical follow-up (26 in group B and 15 in group

L). An additional 7 patients (4 in group B and 3 in group L) were contacted by phone. The total dropout rate was 30% (Fig. 1).

A total of 30 patients in group B and 18 in group L were available for follow-up, whereas 26 and 15, respectively, were available for clinical assessment. Of the patients, 84% were men (81% and 87% in groups B and L, respectively). The mean age of the patients at the time of primary surgery was 27.0 years (27.9 years in group B and 26.0 years in group L), and that at the time of revision surgery was 32.2 years (31.9 years in group B and 32.4 years in group L). There were 12 patients in group B (46%) and 9 in group L (60%) involved in contact sports. The mean follow-up period was 5.7 years (7.8 years in group B and 3.5 years in group L) (Table I).

A recurrence occurred in 13 patients in group B and none in group L. Nine patients in group B later underwent re-revision with an open Latarjet procedure. The mean age at the time of re-revision (ie, the third operation in group B) was 36.3 years. The time of the re-revision (third procedure, in years from the second procedure) is shown in Figure 2. No re-revisions were performed in group L. The shoulder was rated better than an SSV of 8 by 16



**Figure 3** Radiographs after arthroscopic revision Bankart and open revision Latarjet procedures.

**Table II**  
Results

	Revision Bankart procedure	Revision Latarjet procedure	P value
Recurrence, n (%) <sup>*</sup>	13 (43)	0 (0)	.0007
SSV	7.5	9.0	.0368
WOSI index, n (%)	678 (32.3)	245 (11.7)	.0166
Osteoarthritis at follow-up <sup>†</sup>	19	6	.0318

SSV, Subjective Shoulder Value; WOSI, Western Ontario Shoulder Instability.

<sup>\*</sup> Recurrence of instability requiring surgical intervention or persistent subluxations and/or dislocations.

<sup>†</sup> Samilson-Prieto grade of 1 or higher.

patients (62%) in group B and 14 (93%) in group L. The mean SSV was 7.5 in group B and 9.0 in group L ( $P = .0368$ ). The mean WOSI index at follow-up was statistically significantly higher in group B than in group L (678 in group B vs. 245 in group L,  $P = .0166$ ). Significantly more osteoarthritic changes were found in group B than in group L at follow-up (Fig. 3). A summary of clinical results is presented in Table II.

## Discussion

The main finding of our study was that treatment failure, that is, the recurrence of instability requiring surgical intervention, was statistically significantly more common after arthroscopic Bankart revision than after open Latarjet revision. This corroborates our hypothesis, and in the setting of a prior failed arthroscopic Bankart procedure, an open Latarjet procedure appears superior to revision arthroscopic Bankart surgery in preventing recurrence.

We also found a statistically significant difference in both the WOSI index and SSV score in favor of the revision Latarjet procedure. The WOSI index difference was well above the previously reported minimal clinically important change.<sup>13</sup> This finding is in line with reports advocating an open Latarjet procedure as a good option for revision after a failed arthroscopic Bankart repair.<sup>7,11,21</sup> Arthroscopic Bankart operations are reportedly associated with many treatment failures, despite the vast popularity of these procedures.<sup>3</sup>

A revision surgical procedure is always a challenge for the surgeon and adverse to clinical outcomes.<sup>18</sup> Hence, the first operation, in particular, but also the first revision, if needed, should be chosen wisely. In our cohort, arthroscopic Bankart revision was associated with a higher incidence of radiologic osteoarthritis at follow-up. It is interesting to note that nonanatomic open Latarjet revision was associated with fewer osteoarthritic changes. Therefore, it can be argued that persisting instability, rather than procedure type, is detrimental to the joint cartilage.

In a systematic review and meta-analysis by An et al,<sup>3</sup> the Latarjet procedure was considered a viable and possibly superior alternative to Bankart repair. However, their analysis covered only primary procedures, and to our knowledge, reliable comparative studies between these 2 methods in a revision setting do not exist. It may be that revision Bankart repair is associated with satisfactory results in a selected group of patients, as shown by Abouali et al<sup>1</sup> in a systematic review with a recurrent instability rate of only 14%. However, the patient populations may differ, and these results are not generalizable.

The main weakness of our study is the retrospective nature and relatively low number of patients. Second, the dropout rate was relatively high, which reflects the challenging and noncompliant patient population. Primary surgical procedures were also performed by several different surgeons in several different institutions, and we have no knowledge of the initial clinical or radiologic presentation of the patients or why the primary

operations failed. Potential initial bony defects of the glenohumeral joint and severity of instability may have affected the final patient outcomes in our study; however, no initial radiographic or clinical presentation data are available to us to investigate this.

Despite these obvious weaknesses, our study adds valuable information on a relatively rare but clinically challenging problem. The strength of this study is the consecutive series of patients with medium-term follow-up with both clinical and radiologic examinations. In a previous study, 96% of the failures after arthroscopic Bankart operations took place within 3 years, which is well within the range of our follow-up. We used a hard endpoint, that is treatment failure, as our primary outcome score. Our secondary outcome measure, the WOSI index is reportedly the most valid, reliable and responsive patient-reported outcome measure for assessing disease-specific quality of life among patients with shoulder instability.<sup>23</sup>

## Conclusion

An open Latarjet procedure yields better results than an arthroscopic Bankart procedure in a revision setting after a failed primary arthroscopic Bankart procedure. The redislocation rate is high and patient-reported outcome measures are poor after an arthroscopic revision Bankart operation compared with an open revision Latarjet procedure. Furthermore, later osteoarthritis is more common after an arthroscopic revision Bankart operation. Further good-quality studies are needed to thoroughly investigate the effectiveness of these 2 procedures, in both primary and revision settings.

## Disclaimer

The authors, their immediate families, and any research foundations with which they are affiliated have not received any financial payments or other benefits from any commercial entity related to the subject of this article.

## References

- Abouali JAK, Hatzantoni K, Holtby R, Veillette C, Theodoropoulos J. Revision arthroscopic Bankart repair. *Arthroscopy* 2013;29:1572–8. <https://doi.org/10.1016/j.arthro.2013.04.017>.
- Allain J, Goutallier D, Glorion C. Long-term results of the Latarjet procedure for the treatment of anterior instability of the shoulder. *J Bone Joint Surg Am* 1998;80:841–52.
- An VV, Sivakumar BS, Phan K, Trantalis J. A systematic review and meta-analysis of clinical and patient-reported outcomes following two procedures for recurrent traumatic anterior instability of the shoulder: Latarjet procedure vs. Bankart repair. *J Shoulder Elbow Surg* 2016;25:853–63. <https://doi.org/10.1016/j.jse.2015.11.001>.
- Bessière C, Trojani C, Carles M, Mehta SS, Boileau P. The open Latarjet procedure is more reliable in terms of shoulder stability than arthroscopic Bankart repair. *Clin Orthop Relat Res* 2014;472:2345–51. <https://doi.org/10.1007/s11999-014-3550-9>.
- Cole BJ, Romeo AA. Arthroscopic shoulder stabilization with suture anchors: technique, technology, and pitfalls. *Clin Orthop Relat Res* 2001;(390):17–30.
- Cutts S, Prempeh M, Drew S. Anterior shoulder dislocation. *Ann R Coll Surg Engl* 2009;91:2–7. <https://doi.org/10.1308/003588409X359123>.
- Dézaly C, Sirveaux F, Roche O, Wein-Remy F, Paris N, Molé D. Failure of arthroscopic treatment of anterior instability: patient outcome, results of revision for a coracoid block. *J Bone Joint Surg Br* 2011;93-B(Suppl IV):510.
- Edwards TB, Walch G. The Latarjet procedure for recurrent anterior shoulder instability: rationale and technique. *Oper Tech Sports Med* 2012;20:57–64. <https://doi.org/10.1053/otsm.2002.28776>.
- Farber AJ, Castillo R, Clough M, Bahk M, McFarland EG. Clinical assessment of three common tests for traumatic anterior shoulder instability. *J Bone Joint Surg Am* 2006;88:1467–74. <https://doi.org/10.2106/JBJS.E.00594>.
- Flinkkila T, Hyvonen P, Ohtonen P, Leppilähti J. Arthroscopic Bankart repair: results and risk factors of recurrence of instability. *Knee Surg Sports Traumatol Arthrosc* 2010;18:1752–8. <https://doi.org/10.1007/s00167-010-1105-5>.

11. Flinkkila T, Sirnio K. Open Latarjet procedure for failed arthroscopic Bankart repair. *Orthop Traumatol Surg Res* 2015;101:35–8. <https://doi.org/10.1016/j.otsr.2014.11.005>.
12. Gilbert M, Gerber C. Comparison of the Subjective Shoulder Value and the Constant score. *J Shoulder Elbow Surg* 2007;16:717–21. <https://doi.org/10.1016/j.jse.2007.02.123>.
13. Harris DJ, Jefferson CB, Mark PC, Faucett SC, Dhawan A. Research pearls: the significance of statistics and perils of pooling. Part 1: clinical versus statistical significance. *Arthroscopy* 2017;33:1102–12. <https://doi.org/10.1016/j.arthro.2017.01.053>.
14. Hobby J, Griffin D, Dunbar M, Boileau P. Is arthroscopic surgery for stabilisation of chronic shoulder instability as effective as open surgery? *J Bone Joint Surg Br* 2007;89-B:1188–96. <https://doi.org/10.1302/0301-620X.89B9.18467>.
15. Hovelius L, Sandström B, Sundgren K, Saebö M. One hundred eighteen Bristow-Latarjet repairs for recurrent anterior dislocation of the shoulder prospectively followed for fifteen years: study I—clinical results. *J Shoulder Elbow Surg* 2004;13:509–16. <https://doi.org/10.1016/j.jse.2004.02.013>.
16. Kirkley A, Griffin S, McLintock H, Ng L. The development and evaluation of a disease-specific quality of life measurement tool for shoulder instability. The Western Ontario Shoulder Instability Index (WOSI). *Am J Sports Med* 1998;26:764–72.
17. Latarjet M. A propos du traitement des luxations récidivantes de l'épaule [Treatment of recurrent dislocation of the shoulder]. *Lyon Chir* 1954;49:994–7 [in French].
18. Marquardt B, Garmann S, Schulte T, Witt K-A, Steinbeck J, Pötzl W. Outcome after failed traumatic anterior shoulder instability repair with and without surgical revision. *J Shoulder Elbow Surg* 2007;16:742–7. <https://doi.org/10.1016/j.jse.2007.02.132>.
19. Matthes G, Horvath V, Seifert J, Ptok H, Stengel D, Schmucker U, et al. Oldie but goldie: Bristow-Latarjet procedure for anterior shoulder instability. *J Orthop Surg* 2007;15:4–8. <https://doi.org/10.1177/230949900701500102>.
20. Samilson RL, Prieto V. Dislocation arthropathy of the shoulder. *J Bone Joint Surg Am* 1983;65:456–60.
21. Schmid SL, Farshad M, Catanzaro S, Gerber C. The Latarjet procedure for the treatment of recurrence of anterior instability of the shoulder after operative repair: a retrospective case series of forty-nine consecutive patients. *J Bone Joint Surg Am* 2012;94:e75. <https://doi.org/10.2106/JBJS.K.00380>.
22. Schneeberger AG, Hersche O, Gerber C. Die instabile Schulter. Klassifikation und therapie [The unstable shoulder. Classification and therapy]. *Unfallchirurg* 1998;101:226–31 [in German].
23. Whittle JH, Peters SE, Manzanero S, Duke PF. A systematic review of patient-reported outcome measures used in shoulder instability research. *J Shoulder Elbow Surg* 2020;29:381–91. <https://doi.org/10.1016/j.jse.2019.07.001>.
24. Wolf EM, Wilk RM, Richmond JC. Arthroscopic Bankart repair using suture anchors. *Oper Tech Orthop* 1991;1:184–91.