

Supernumerary Teeth: An Investigating Tool in Forensic Crime Investigation

Rupinder Kaur Multani¹, Kishore Kumar Sangeri², M Ramalakshmi³, S Pavithra⁴, M Rajesh⁵, Laiphrakpam Girindra Singh⁶

Contributors:

¹Senior Lecturer, Department of Oral & Maxillofacial Pathology, Rayat & Bahra Dental College & Hospital, Sahauran, Mohali, Punjab, India; ²Senior Lecturer, Department of Endodontics, Aditya Dental College, Beed, Maharashtra, India; ³Reader, Department of Oral Medicine & Radiology, Thai Moogambikai Dental College & Hospital, Chennai, Tamil Nadu, India; ⁴Reader, Department of Endodontics, Peoples College of Dental Sciences and Research, Bhopal, Madhya Pradesh, India; Associate Professor, Department of Forensic Medicine, Srinivasa Medical College, Mangalore, Karnataka, India; ⁶Senior Lecturer, Department of Oral & Maxillofacial Surgery, Apollo White, Chennai, Tamil Nadu, India.

Correspondence:

Dr. Multani RK. Department of Oral & Maxillofacial Pathology, Sahauran, Mohali, Punjab, India. Email: rupin 678@gmail.com

How to cite the article:

Multani RK, Sangeri KK, Ramalakshmi M, Pavithra S, Rajesh M, Singh LG. Supernumerary teeth: An investigating tool in forensic crime investigation. J Int Oral Health 2015;7(5):56-58.

Abstract:

Background: Supernumerary tooth is an additional entity to the normal series and is seen in all the quadrants of the jaw. The prevalence rates of supernumerary teeth in the permanent dentition, reported in the literature, vary between 0.1% and 6.9%. The presence of supernumerary teeth may be part of developmental disorders. As supernumerary tooth is a rare condition, it can be used as identification tool for crime investigation.

Material and Methods: A total of 30 volunteers with a supernumerary tooth were analyzed and casts were made after taking alginate impression. All the casts were coded and were given to five observers for correct identification of those volunteers with respective prepared cast.

Result: Personal identification and the cast identification of volunteers were done (cast of the volunteers). The matching identification is followed as below: Of five observers 1st observer able to detect 25 (83%), 2nd observer 27 (90%), 3rd observer 26 (87%), 4th observer 25 (83%) and 5th observer 28 (91%).

Conclusion: As positive matching identification was 87%, supernumerary tooth can be used for crime investigation and used as greatest weapon in criminal identification.

Key Words: Crime investigation, dental cast, positive identification, supernumerary teeth

Introduction

Supernumerary teeth are present in addition to the normal set of teeth. These were first described between 23 and 79 AD. A supernumerary tooth is defined as supplementary to the normal tooth series and can be observed in almost any region of the dental arch.¹ Hyperdontia is characterized by an excess number of teeth.²

The prevalence of supernumerary teeth vary between 0.1% and 3.8%, and it is more commonly seen in the permanent dentition.³

According to Brook, the incidence of supernumerary teeth in primary and permanent dentition were 0.8% and 2.1% respectively.⁴

Due to its normal shape and position in the primary dentition, the supernumerary teeth are usually overlooked by the parents.⁵

Numerous developmental disorders have been associated with the presence of supernumerary teeth such as cleft lip and palate, gardener's syndrome and cleidocranial dysostosis.⁶

Classification of supernumerary teeth

Supernumerary teeth can be classified based on various factors [Figure 1]. As per eruption sequence these are classified as pre-deciduous, similar to permanent teeth, and post permanent or complementary, according to shape they can be classified as conical, tuberculate, supplemental and odontome, as per their location in the dental arch they are classified as mesiodens, paramolar, distomolar and parapremolar, and according to orientation as vertical, inverted and transverse.⁵

Another basis of classification could be based on its association with developmental disorders.⁶

Etiology

The presence of supernumerary tooth is multifactorial. Both genetic and environmental factors play a significant role in its etiopathogenesis. Several theories have been suggested to explain their occurrence:

Atavism

The presence of supernumerary teeth was attributed to the phylogenetic reversion to extinct primates with three pairs of incisors. This theory has been largely discontinued.⁸

Dichotomy theory

According to this theory the tooth bud splits into two equal or unequal parts, which results in the formation of two teeth of equal size or one normal and one dysmorphic tooth, respectively. However, this theory has been discontinued.⁸

Dental lamina hyperactivity theory

It is based on the conditioned hyperactivity of the dental lamina. It is suggested that a supplemental form develops

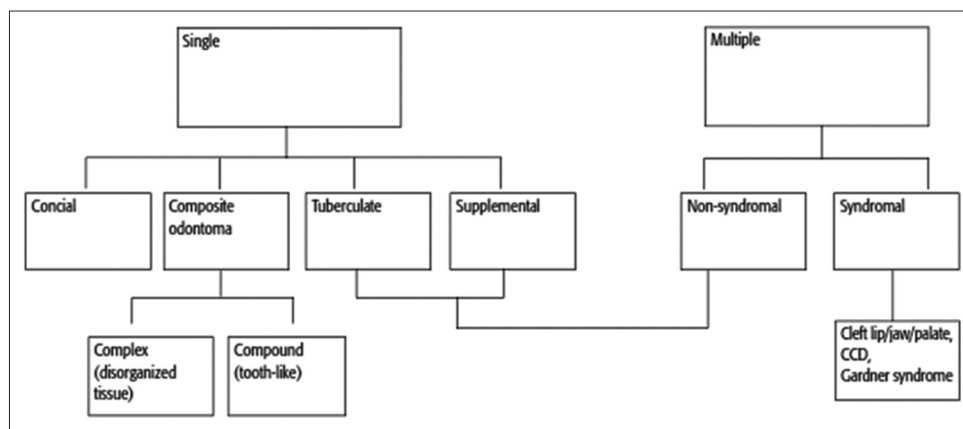


Figure 1: Classification of supernumerary teeth according to Garvey et al. 1999.⁷

from the lingual extension of an accessory tooth bud whereas a rudimentary form develops from the proliferation of epithelial remnants of the dental lamina. Most literature accepts the dental lamina hyperactivity theory.⁸

Genetic factors

Genetic factors play an important role in the incidence of supernumerary teeth. As more males are affected than females, a sex-linked inheritance has been suggested.⁸

Materials and Methods

Totally 30 volunteers with a supernumerary tooth were analyzed and casts were made after taking alginate impression. All the casts were coded and were given to five observers for correct identification of those volunteers with respective prepared cast.

Results

Personal identification and the cast identification of volunteers were done. The matching identification is followed as below in Table 1.

Out of five observers 1st observer was able to detect 25 (83%), 2nd observer 27 (90%), 3rd observer 26 (87%) 4th observer 25 (83%) and 5th observer 28 (91%).

Discussion

Supernumerary tooth is an additional entity to the normal series and is seen in all the quadrants of the jaw. Hyperdontia is a rare alteration of odontogenesis defined as the presence of any tooth or tooth substance in excess of the normal dental formula. Supernumerary tooth is a unique condition, its presence can be utilized as a useful tool in forensic science. If proper database is there its matching can be used as positive identification.

In the current study, 30 casts of the volunteers were analyzed by five observers. Out of five observers 1st observer was able to detect 25 (83%), 2nd observer 27 (90%), 3rd observer 26 (87%) 4th observer 25 (83%) and 5th observer 28 (91%). Overall cast identification from five observers was 87%. From five observers, average of 26 cast matching was obtained, which is a positive

Table 1: Matching by the observers.

Cast code	1 st observer	2 nd observer	3 rd observer	4 th observer	5 th observer
1	✓	✓	✓	✓	✓
2	✓	✓	✓	✓	✓
3	✓	✓	✓	✓	✓
4	✓	✓	✓	✓	✓
5	✓	✓	✓	✓	✓
6	✓	✓	✓	✓	✓
7	×	✓	✓	×	✓
8	✓	×	×	✓	✓
9	✓	✓	✓	✓	✓
10	✓	✓	×	✓	✓
11	×	×	✓	×	✓
12	✓	✓	✓	✓	✓
13	✓	✓	×	✓	✓
14	✓	✓	✓	×	✓
15	✓	×	✓	✓	✓
16	✓	✓	✓	×	×
17	×	✓	✓	×	✓
18	✓	✓	✓	✓	✓
19	✓	✓	✓	✓	✓
20	✓	✓	✓	✓	✓
21	×	✓	✓	✓	✓
22	✓	✓	✓	✓	✓
23	✓	✓	✓	✓	✓
24	✓	✓	✓	✓	✓
25	✓	✓	✓	✓	✓
26	✓	✓	✓	✓	×
27	✓	✓	✓	✓	✓
28	✓	✓	✓	×	×
29	✓	✓	✓	✓	✓
30	✓	✓	✓	✓	✓

identification. Hence, a high positive correlation was observed in this study, which clearly suggests that if proper database is maintained, supernumerary tooth can be utilized as personal identification in forensic crime investigation.

A very positive correlation was observed between supernumerary teeth and personal identification. The presence of supernumerary teeth can be utilized as strong evidence in forensic crime investigation. This gives the greatest tool for personal identification of individual in forensic crime investigation.

Conclusion

As positive matching identification was 87%, supernumerary tooth can be used for crime investigation and in criminal identification. Henceforth it can be concluded that supernumerary teeth can be included in forensic investigation even though the negative identification seen when the tooth is extracted and prerecords is not there in same individuals.

References

1. Amaral D, Muthu MS. Supernumerary teeth: review of literature and decision support system. *Indian J Dent Res* 2013;24 (1):117-22.
2. Krishnan B, Narasimhan B, Nirupama C. Nonsyndromic multiple supernumerary teeth: A case report of 11 supernumerary teeth. *J Indian Acad Oral Med Radiol* 2012;24 (4):296-9.
3. Parolia A, Kundabala M. Bilateral maxillary paramolars and endodontic therapy: a rare case report. *J Dent (Tehran)* 2010;7 (2):107-11.
4. Brook AH. Dental anomalies of number, form and size: their prevalence in British schoolchildren. *J Int Assoc Dent Child* 1974;5 (2):37-53.
5. Parolia A, Kundabala M, Dahal M, Mohan M, Thomas MS. Management of supernumerary teeth. *J Conserv Dent* 2011;14 (3):221-4.
6. Kumar A, Namdev R, Bakshi L, Dutta S. Supernumerary teeth: Report of four unusual cases. *Contemp Clin Dent* 2012;3 Suppl 1:S71-7.
7. Garvey MT, Barry HJ, Blake M. Supernumerary teeth – an overview of classification, diagnosis and management. *J Can Dent Assoc* 1999;65 (11):612-6.
8. Vinod Kumar P, Shruthi BS. Supernumerary teeth: An epitome of variability and unpredictability – A comprehensive review and five case reports. *Indian J Multidiscip Dent* 2013;4 (1):860-9.