

Eyelid ptosis following botulinum toxin injection treated with brimonidine 0.33% topical gel



Ghadah F. Alotaibi, MD, Sara F. Alsukait, MD, Hanan H. Als Salman, MD, and Mohammed G. Turkmani, MD
Riyadh, Saudi Arabia

Key words: botulinum toxin; brimonidine; eyelid ptosis.

INTRODUCTION

Botulinum toxin injection has become one of the most popular procedures in esthetics due to its effectiveness in softening dynamic wrinkles. Most of the complications associated with the esthetic use of botulinum toxin are rare and self-limited. The most common complication of treatment of the glabellar complex is ptosis of the upper portion of the eyelid. Ptosis can occur from 2 to 10 days after injection, at the same time as the esthetic effect is beginning to appear. It can persist for up to 2 to 4 weeks.¹ Eyelid ptosis can be treated with α -adrenergic eye drops. These eye drops cause contraction of the upper portion of the tarsal muscle, known as Müller's muscle, creating a 1- to 2-mm elevation of the upper portion of the eyelid, which is usually sufficient to make the eyelids more symmetric.²

One common treatment is an α_2 -adrenergic agonist ophthalmic eye drop, 0.5% apraclonidine. Another selective α_2 -adrenergic agent, brimonidine eye drop, is used as an alternative to apraclonidine to treat eyelid ptosis. Topical brimonidine has been used in dermatology to treat erythematous rosacea because of its potent peripheral vasoconstriction ability.

In this article, we report the treatment of a patient with unilateral eyelid ptosis following botulinum toxin type A (Botox; Allergan) injection for the management of dynamic lines of the upper third of the face with the use of 0.33% brimonidine topical gel.

CASE REPORT

A 35-year-old woman had received botulinum toxin type A for treatment of the dynamic lines on her glabella and forehead. After 4 days, she was

Abbreviation used:

MRD1: marginal reflex distance

presented to the clinic with right eyelid ptosis. She complained of fatigue and heaviness around her right eye. She did not know the dosage or the sites of injection of the botulinum toxin.

Upon examination, we noticed that the right iris was remarkably covered by the upper portion of the eyelid. Manual lifting of the eyebrow did not help, and frontalis activity was present. To evaluate the eyelid ptosis, we measured the palpebral fissure and the marginal reflex distance (MRD1). The palpebral fissure is the distance between the upper and lower portion of the eyelid margins while the patient is in primary gaze (the normal range can vary from 7-12 mm) (Fig 1). The patient's palpebral fissure was 6 mm in the affected right eye and 10 mm in the unaffected left eye. The MRD1 is the distance from the margin of the upper portion of the eyelid to the central aspect of the corneal reflex (the normal range is 4.0-4.5 mm) (Fig 1). The patient's MRD1 was 2 mm in the affected right eye and 4 mm in the unaffected left eye.

The diagnosis of eyelid ptosis was based on the clinical presentation as well as the palpebral fissure and MRD1 measurements. Usually, α_2 -adrenergic agonist ophthalmic eye drops, such as apraclonidine and brimonidine, improve eyelid ptosis. Using a fingertip, we applied 0.2 mg (pea-sized amount) of 0.33% topical brimonidine gel (Mirvaso Gel; Galderma Laboratories, LP) over the upper portion of the right eyelid. The patient then remained under observation in the clinic. One hour later, there was a

From the Derma Clinic, Riyadh.

Funding sources: None.

IRB approval status: Not applicable.

Correspondence to: Mohammed G. Turkmani, MD, Derma Clinic, Riyadh, Saudi Arabia. E-mail: mgtderma@yahoo.com.

JAAD Case Reports 2022;22:96-8.

2352-5126

© 2022 by the American Academy of Dermatology, Inc. Published by Elsevier, Inc. This is an open access article under the CC BY-NC-ND license (<http://creativecommons.org/licenses/by-nc-nd/4.0/>).

<https://doi.org/10.1016/j.jdc.2022.01.019>



Fig 1. Marginal reflex distance (*white lines*) and palpebral fissure (*black lines*).

significant elevation of the eyelid by 2 mm, and the noticeable elevation persisted for up to 2 hours. We did not repeat the procedure. We remeasured the palpebral fissure and MRD1 to confirm elevation of the droopy eyelid. Photographs were taken before application (Fig 2, A) and 1 hour after application (Fig 2, B). No side effects were observed.

DISCUSSION

The use of botulinum toxin injection has increased dramatically in cosmetic practice for rejuvenation of the aging face. Many of the complications associated with its esthetic use are limited and reversible. However, one of the most common complications of botulinum toxin injection is ptosis of upper portion of the eyelid. This is caused by diffusion of the toxin through the orbital septum, where it affects the upper portion of the eyelid levator muscle.³ The levator palpebrae superioris is the muscle in the orbit that elevates and retracts the upper portion of the eyelid. The levator palpebrae superioris originates on the lesser wing of the sphenoid bone, just above the optic foramen. It broadens and becomes the levator aponeurosis. This portion inserts on the skin of the upper portion of the eyelid, as well as the superior tarsal plate. The superior tarsal muscle is attached to the levator palpebrae superioris and also inserts on the superior tarsal plate.⁴

The main indication for α -adrenergic agonist eye drops such as apraclonidine and brimonidine is reduction of intraocular pressure in glaucoma. Although brimonidine is more selective than apraclonidine,⁵ both enhance aqueous humor uveoscleral outflow and decrease aqueous production by vasoconstriction. When these treatments are used for

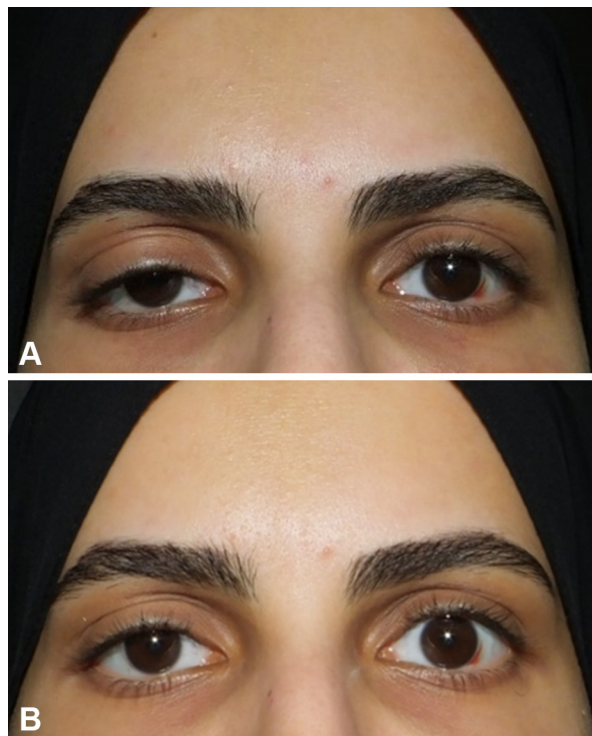


Fig 2. A, Before topical brimonidine application. **B,** One hour after application.

glaucoma, eyelid retraction appears as one of the side effects, especially with the use of apraclonidine.⁶ Apraclonidine elevates the eyelid by its effect on Müller's muscle, which is a smooth muscle innervated by sympathetic nerves.⁷ Brimonidine eye drops are used in clinical practice to elevate the eyelid if apraclonidine is not available. However, few studies have investigated the effect of brimonidine tartrate 0.15% ophthalmic solution on eyelid position in healthy patients, and those studies found no significant difference in eyelid position.^{6,8} To our knowledge, this is the first report describing the use of topical brimonidine gel for treatment of eyelid ptosis associated with cosmetic use of botulinum toxin.

Topical brimonidine gel has a direct potent peripheral vasoconstriction activity in the small arterioles, which makes it a good treatment for erythema associated with rosacea. Benkali et al⁹ studied the pharmacokinetics and bioavailability of brimonidine following ocular and dermal administration in patients with moderate-to-severe facial erythema associated with rosacea. They showed that the systemic exposure observed with the higher dose of brimonidine gel (0.5% once daily) was significantly lower than that observed with the ophthalmic solution (0.2%). This makes the systemic safety profile of topical brimonidine better than that of the marketed ophthalmic solution.⁹ Although this study compares

systemic absorption, to our knowledge there are no current studies comparing the effects of topical gel versus brimonidine eye drops on eyelid elevation.

In this case report, we demonstrate that topical application of 0.33% brimonidine gel over the eyelid elevates the eyelid with no observed side effects. We present brimonidine gel as an adequate option for symptomatic relief following botulinum toxin-induced eyelid ptosis. However, to our knowledge there are no current studies on the safety of this topical gel on the eyelids.

Conflicts of interest

None disclosed.

REFERENCES

1. Klein AW. Contraindications and complications with the use of botulinum toxin. *Clin Dermatol*. 2004;22:66-75.
2. Omoigui S, Irene S. Treatment of ptosis as a complication of botulinum toxin injection. *Pain Med*. 2005;6:149-151.
3. Klein AW. Complications, adverse reactions, and insights with the use of botulinum toxin. *Dermatol Surg*. 2003;29:549-556.
4. Abdelhady A. *Anatomy, head and neck, eye superior tarsal muscle (Muller's muscle)*. StatPearls Publishing; 2021.
5. Javier J, Robert C. Effects of common topical antiglaucoma medication on the ocular surface, eyelids and periorbital tissue. *Drugs Aging*. 2011;28(4):267-282.
6. Mendonça TB, Lummertz AP, Bocaccio FJ, Procianoy F. Effect of low-concentration, nonmydriatic selective alpha-adrenergic agonist eyedrops on upper eyelid position. *Dermatol Surg*. 2017;43:270-274.
7. Wijemanne S, Vijayakumar D, Jankovic J. Apraclonidine in the treatment of ptosis. *J Neurol Sci*. 2017;376:129-132.
8. Tuncer I, Bilgin S, Zengin MÖ, et al. Effect of brimonidine tartrate 0.15% on scotopic pupil size and upper eyelid position: controlled trial. *Eye (Lond)*. 2021;35:672-675.
9. Benkali K, Leoni M, Rony F, et al. Comparative pharmacokinetics and bioavailability of brimonidine following ocular and dermal administration of brimonidine tartrate ophthalmic solution and gel in patients with moderate-to-severe facial erythema associated with rosacea. *Br J Dermatol*. 2014;171(1):162-169.