

Atrial Fibrosis: Translational Considerations for the Management of AF Patients

Stylianos Tzeis¹, Dimitrios Asvestas¹ and Panos Vardas²

1. Cardiology Department, Mitera General Hospital, Hygeia Group, Athens, Greece; 2. Heart Sector, Hygeia Group Hospitals, Athens, Greece

Abstract

Fibrosis plays a fundamental role in the initiation and maintenance of AF, mainly due to enhanced automaticity and anisotropy-related re-entry. The identification and quantification of atrial fibrosis is achieved either preprocedurally by late gadolinium enhancement MRI or intraprocedurally using electroanatomic voltage mapping. The presence and extent of left atrial fibrosis among AF patients may influence relevant decision making regarding the need for anticoagulation, the adoption of rate versus rhythm control and mainly the type of ablation strategy that will be followed during interventional treatment. Several types of individualised substrate modifications targeting atrial fibrotic areas have been proposed, although their impact on patient outcome needs to be further investigated in adequately powered prospective randomised controlled clinical trials.

Keywords

Ablation, AF, atrial fibrosis, substrate modification

Disclosure: The authors have no conflicts of interest to declare.

Received: 14 December 2018 **Accepted:** 6 February 2019 **Citation:** *Arrhythmia & Electrophysiology Review* 2019;8(1):37–41. **DOI:** <https://doi.org/10.15420/aer.2018.79.3>

Correspondence: Stylianos Tzeis, 6, Erythrou Stavrou, Maroussi, Athens, PC 15123, Greece. E: stzeis@otenet.gr

Open Access: This work is open access under the CC-BY-NC 4.0 License which allows users to copy, redistribute and make derivative works for non-commercial purposes, provided the original work is cited correctly.

AF is the most common cardiac arrhythmia with a complex and multifactorial pathophysiological background. In their seminal publication, Haissaguerre et al. shed light on the role of rapidly firing pulmonary vein sources in the initiation of AF paroxysms.¹ Apart from the role of pulmonary vein-triggering foci, underlying electrical and structural remodelling also contributes to the onset and perpetuation of AF, especially in advanced stages of its natural course. The term ‘electrical remodelling’ mainly reflects the modification of the electrophysiological characteristics of atrial myocytes, while the hallmark of ‘structural remodelling’ is the underlying atrial fibrosis. Interestingly, these two components of atrial remodelling exhibit a substantial mechanistic interplay. The fundamental role of fibrosis in the pathogenesis of AF has attracted intense research interest with evident clinical implications for pertinent management strategies.

Fibrosis is characterised by the proliferation of fibroblasts, which subsequently differentiate into myofibroblasts secreting extracellular matrix proteins (collagen). The disorganised myocardial architecture and cellular content promotes arrhythmogenesis in multiple ways.² Fibroblasts and myofibroblasts may couple electrically to neighbouring cardiomyocytes, modifying their electrical properties and promoting automaticity and ectopic firing.³ In addition, the expanded extracellular matrix disrupts normal electrical cellular coupling, thus enhancing microstructural discontinuities and intensifying directionally dependent variation of conduction velocity. The latter augmentation of tissue anisotropy increases the susceptibility to unidirectional block and re-entry, and contributes to triggering and maintenance of AF.^{4,5} Experimental data further supported the key role of atrial fibrosis,

demonstrating that regions of fibrosis or scar may anchor fibrillatory rotors,⁶ while re-entrant drivers in persistent AF are confined to specific regions that constitute boundary zones between fibrotic and non-fibrotic tissue.⁷

Preprocedural Identification of Atrial Fibrotic Areas

A method that has been used in limited centres for the identification, localisation and quantification of atrial fibrosis is late gadolinium enhancement (LGE) MRI. The contrast agent accumulates in the extracellular space owing to altered washout kinetics compared with normal tissue, resulting in a higher signal intensity in fibrotic areas due to abundant extracellular space.⁸ Specific MRI protocols have been introduced and clinically tested for imaging of atrial fibrosis.^{9,10} The identified fibrotic areas are colour coded on the surface of the left atrial shell, allowing the quantification and subsequent staging of left atrial fibrosis based on the ratio of the volume of the fibrotic left atrial wall (delayed enhancement) to the total left atrial wall volume.^{9,11} The value of MRI for non-invasive assessment of underlying atrial fibrosis is also supported by data showing that histological findings of collagen content in surgical biopsy specimens correlate with respective tissue characterisation by LGE-MRI.¹⁰ Several studies have also shown a high level of agreement between regions of scar identified by LGE-MRI and low-voltage areas identified by electroanatomic voltage mapping.^{12–14} However, contradictory results have also been reported. In cohorts of patients subjected to AF ablation, the highest LGE coverage is located at the left pulmonary vein antral, left lateral and left posterior wall,¹⁵ while low-voltage zones are preferentially distributed in the anterior

wall, septum and posterior wall.¹⁶ Interestingly, the reported correlation between different techniques used for fibrosis delineation is influenced by the previous history of catheter ablation, since ablated atrial tissue is more easily identifiable by MRI, contrary to the non-iatrogenic diffuse interstitial atrial fibrosis.¹⁷ Despite recent progress in the reproducibility of left atrial fibrosis assessment,¹⁸ inherent caveats mainly stem from the reduced thickness of the atrial wall compared with the spatial resolution of the MRI. Additional limitations that may impair image quality and accuracy in LGE quantification include subjectivity in the definition of left atrial borders during segmentation, irregular rhythm and respiration pattern, increased body mass index and other types of technical faults.

Another tool that has been proposed for the assessment of underlying fibrosis is surface ECG. The more extensive the underlying atrial fibrosis, the slower the conduction within the left atrium, resulting in a prolonged duration of the sinus P wave. Jadidi et al. have reported a correlation between the extent of left atrial low-voltage substrate, which is indicative of underlying fibrosis, and the duration of amplified sinus P wave.¹⁹ They also proposed that a cut-off value of 150 msec identifies patients with fibrotic substrate who are also at increased risk of arrhythmia recurrence following catheter ablation of AF and offers high sensitivity and specificity. Thus, this widely available, non-invasive, low-cost tool could be used in everyday practice for the preprocedural assessment of underlying atrial fibrosis content, as well as improve the success rate of invasive arrhythmia management.

Impact on Patient Management

The evaluation of atrial fibrosis as the main indicator of underlying structural remodelling may affect decision making at several stages of the management plan of AF patients. The respective AF treatment domains that are influenced by the presence of underlying atrial fibrosis are assessment of stroke risk and need for anticoagulation; decision for rhythm control strategy; and modification of adopted strategy during catheter ablation.

Assessment of Stroke Risk and Need for Anticoagulation

Atrial fibrosis is associated with a worsened prognosis among AF patients. Patients with more severe left atrial LGE are more likely to have a history of stroke and to present with left atrial appendage thrombus or spontaneous echocardiographic contrast in transoesophageal echocardiography.^{20,21}

In an observational study, King et al. demonstrated that left atrial LGE severity, as a marker of fibrotic structural remodelling, is associated with increased risk of major adverse cardiovascular and cerebrovascular events, particularly stroke or transient ischaemic attack.²² Similarly, Müller et al. showed that a left atrial low-voltage area that was evaluated by intraprocedural mapping during AF catheter ablation (bipolar voltage <0.5 mV) was associated with history of stroke and silent cerebral ischaemia.²³

These findings support a potential role of atrial fibrosis in the stratification of ischaemic stroke risk among AF patients. The adopted risk-stratification schemes (CHA₂DS₂-VASc score) mainly aim to identify patients with a truly low risk score who do not require antithrombotic therapy. Therefore, the presence of atrial fibrosis, especially if severe, may influence decision making in favour of anticoagulation prescription in patients without clinical risk factors who would not otherwise be considered as suitable candidates for anticoagulation protection.²⁴

In the case presented in *Figure 1*, a young woman with homozygous thalassaemia and paroxysmal AF was prescribed anticoagulant treatment despite the absence of any clinical ischaemic risk factors, and solely based on the extensive atrial fibrosis identified during voltage mapping. However, despite similar anecdotal cases, adequately powered prospective studies are needed to validate the role of atrial fibrosis for guidance of antithrombotic treatment in AF patients.

Decision for Rhythm Control Strategy

The assessment of atrial fibrosis may aid in the selection of patients anticipated to gain benefit from rhythm control management.²⁵ Accumulating data support the notion that the higher the burden of atrial fibrosis, the more complex the underlying mechanism of AF, and thus the more challenging is sinus rhythm maintenance. Jadidi et al. demonstrated that the mean AF cycle length is inversely related to the extent of LGE on CMR.²⁶ Cochet et al. found that left atrial fibrosis, as assessed by LGE, is the only independent predictor of the number of re-entrant regions and the complexity of underlying re-entrant activity in the left atrium among persistent AF patients subjected to high-resolution electrocardiographic imaging.²⁷ These findings are consistent with evidence derived from experimental studies.^{28,29}

Furthermore, in the clinical context, the amount of preablation atrial fibrosis, as estimated by LGE-MRI, is independently associated with the likelihood of arrhythmia recurrence.^{9,27} The left atrial wall structural remodelling stage (Utah stage) is the strongest predictor of ablation outcome in multivariate analyses.¹⁰ Therefore, especially in the case of persistent and long-term persistent AF, a large volume of atrial fibrosis evidenced by LGE-MRI may serve as a gatekeeper to rule out patients from undergoing one or more demanding ablations in the challenging pursuit of sinus rhythm maintenance.

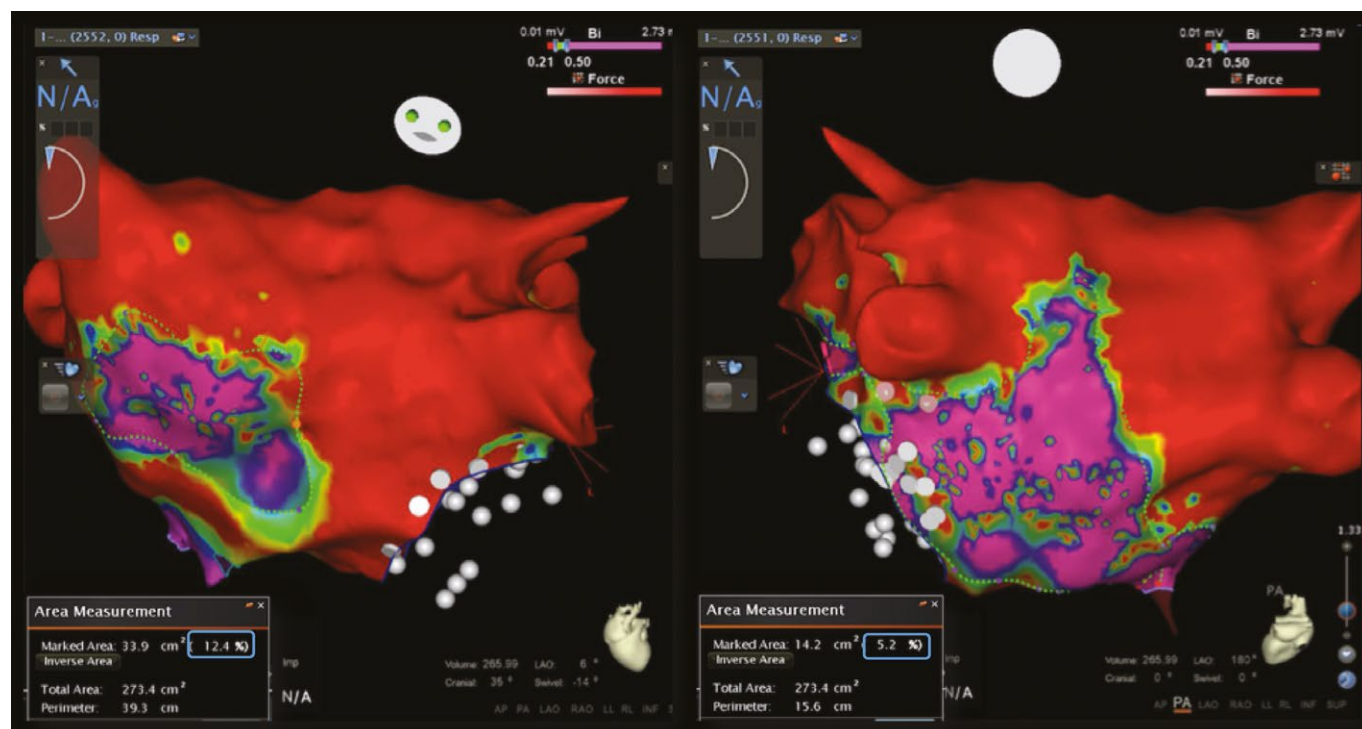
Impact on Ablation Strategy

A wide circumferential electrical isolation of pulmonary veins remains the cornerstone of AF ablation.³⁰ However, despite the need for an adjunctive ablation strategy in addition to pulmonary vein isolation to improve the low rates of sinus rhythm maintenance in patients with persistent and long-standing-persistent AF, randomised clinical trials have failed to show an additional benefit from linear lesions and ablation of complex fractionated electrograms.³¹

Atrial fibrosis is an attractive target for ablation among patients with AF, as it has been proposed to participate in the complex interplay of diverse pathophysiological mechanisms.³² Despite an existing contradiction on potential spatial correlation between re-entrant activity and underlying atrial fibrosis in AF,^{27,33} several computational, experimental and human studies have supported the role of atrial fibrosis in anchoring re-entry during AF.^{34,35} The evident link between fibrotic substrate and re-entrant drivers perpetuating AF has rendered these late gadolinium enhanced areas as potential ablation targets, lending support to the development of an adjunctive ablation strategy to be implemented in addition to pulmonary vein isolation.

The first step in the incorporation of atrial fibrosis as an ablation target during invasive management of AF is the accurate identification of atrial fibrotic areas during voltage mapping. Several studies have shown a spatial correlation between low-voltage areas detected by intraprocedural voltage mapping and fibrotic areas identified by delayed enhancement cardiac MRI.³⁶ The evolution of 3D electroanatomic mapping tools and high-density voltage mapping improved the

Figure 1: 3D Electroanatomical Mapping During Scheduled Catheter Ablation in a Woman with Thalassaemia and AF



Electroanatomical mapping was performed during scheduled catheter ablation for this woman with thalassaemia major (beta thalassaemia homozygous state) and early persistent AF. She had no clinical thromboembolic risk factors and a CHA₂DS₂-VASc score of 1 due to her gender. The voltage map was performed in sinus rhythm and demonstrated extensive fibrosis using strict voltage criteria for identification of 'scar' (≤ 0.2 mV). Viable tissue was identified only in 17.6% of the left atrial surface. Based on these procedural findings, no ablation lesions were deployed, a rate-control strategy was adopted, and anticoagulant therapy was recommended in contradiction to the current guidelines.

identification of pathological tissue.³⁷ However, voltage mapping during AF tends to overestimate the extent of underlying atrial fibrosis due to significant differences in electrogram voltage amplitude between sinus rhythm and AF at the same sites among persistent AF patients.³⁸ The optimal cut-off value for accurate demarcation of left atrial scar displays regional variation, and a bipolar voltage of 0.27 mV best identified atrial scar compared with delayed enhancement cardiac MRI.³⁹

The optimal ablation method of atrial fibrotic areas in the context of AF ablation has not been clarified. Several ablation strategies targeting atrial fibrotic areas have been proposed in the context of persistent AF ablation.

Box Isolation of the Fibrotic Area

The isolated fibrotic areas should also be connected to neighbouring anchoring lines, such as the circumferential pulmonary vein isolation lines or other empirical lines, including the roof line, mitral isthmus line or anterior line.^{40,41} The deployed connection lesions aim to prevent micro or macro re-entrant arrhythmias through iatrogenically formed conduction channels around the isolated fibrotic areas. This strategy of individualised substrate modification has been reported to improve the ablation success rate when applied in addition to pulmonary vein isolation during ablation of paroxysmal and non-paroxysmal AF (Figure 2).⁴²

Homogenisation of the Low-voltage Area

Another ablation approach for the management of underlying atrial fibrosis is the homogenisation of low-voltage areas. This method aims to eliminate all detectable electrograms within the borders of the low-voltage area. In contradiction to the clear procedural endpoint of the BIFA strategy, the homogenisation method aims to reduce the

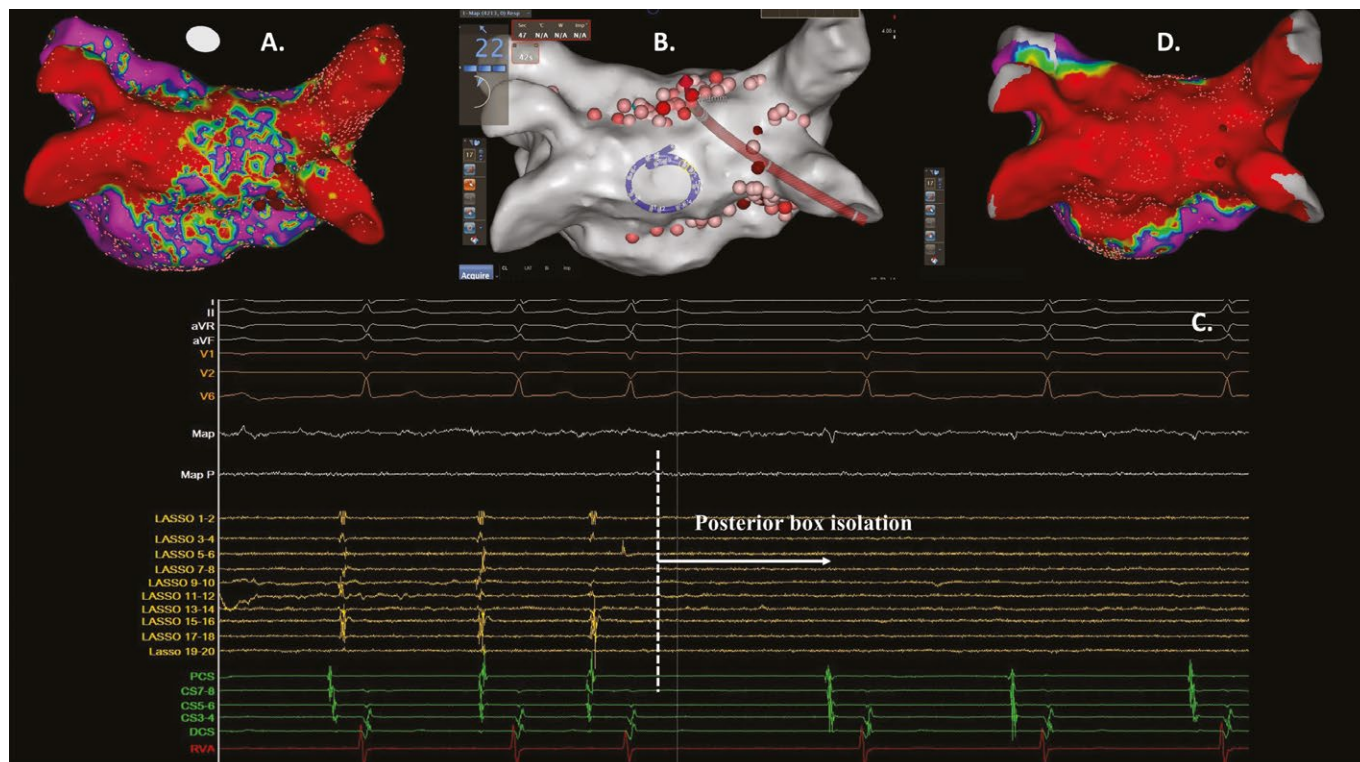
amplitude of the recorded bipolar electrograms with diverse criteria (less than 0.1 mV, or more than 50% compared with baseline).^{43,44} The homogenisation lesions within the fibrotic area are complemented by deployment of linear lesions to eliminate conduction channels that increase the likelihood of iatrogenic re-entrant arrhythmias. Yamaguchi et al. reported that implementation of the homogenisation strategy in addition to pulmonary vein isolation in patients with persistent AF and underlying atrial fibrosis significantly increases the likelihood of sinus rhythm maintenance compared with pulmonary vein isolation alone.⁴⁴

Selective Ablation of Atrial Low-voltage Sites

A caveat of targeting all atrial fibrotic areas during substrate modification in persistent AF is the lack of specificity in identifying underlying driver re-entrant circuits or rotors.²⁷ In other words, the majority of pathophysiological culprit re-entrant regions are located within atrial fibrotic areas. However, several fibrotic areas do not home re-entrant circuits, and thus their ablation would not be expected to have an impact on AF organisation or termination.²⁷ Therefore, it seems intriguing to select the low-voltage areas to be targeted during ablation based on the presence of certain electrogram criteria suggestive of a critical role in arrhythmia perpetuation. In this concept, the combined implementation of selection criteria based on both indices of electrical remodelling (specific activation patterns) and structural remodelling (low-voltage areas suggestive of fibrosis) aim to increase the specificity of localising target sites for ablation.

Several groups have proposed similar strategies of selective ablation of low-voltage atrial regions. Jadidi et al. identified low-voltage areas of interest for subsequent ablation based on specific regional activation patterns including repetitive presence of prolonged fractionation

Figure 2: Patient with Persistent AF Subjected to Redo Ablation



A: After isolation of the reconnected right inferior pulmonary vein with spot lesions, detailed voltage mapping in sinus rhythm demonstrated patchy fibrosis mainly located at the posterior wall. B: In the context of an individualised invasive management, a posterior box lesion was performed. The figure shows the ablation catheter deploying the roof line with the circular catheter situated at the posterior wall. C: After completion of the posterior box, the elimination of electrical activity on the circular catheter validates the electrical isolation of the posterior wall. D: Final voltage map showing an absence of electrical activity at the posterior wall.

(>70% of AF cycle length), repetitive rotational activity or discrete rapid activity.⁴⁵ The same group demonstrated that the ablation of those sites in addition to pulmonary vein isolation was associated with significantly reduced recurrence of atrial tachyarrhythmias compared with pulmonary vein isolation only.⁴⁵ Furthermore, targeted ablation of specific electrograms in low-voltage areas in addition to wide antral circumferential ablation in patients with persistent AF has been reported to improve patient outcome.⁴⁶

Other Ablation Strategies Targeting Low-Voltage Areas

A personalised substrate-modification method targeting left atrial low-voltage areas combining several of the elements described in the aforementioned strategies has been reported. Rolf et al. targeted low-voltage areas for substrate modification by homogenisation of the respective area, or deployment of strategic linear lesions either to encircle and electrically isolate large low-voltage areas or to connect these areas with non-conducting structures.⁴⁷ The combined application of this individualised substrate modification with pulmonary vein isolation significantly increased AF-free survival compared with pulmonary vein isolation alone.

In the same context, the multicentre, randomised Electrophysiological Substrate Ablation in the Left Atrium During Sinus Rhythm (STABLE-SR) trial evaluated the safety and efficacy of a substrate-modification strategy targeting the fibrotic areas in patients with non-paroxysmal AF, with a procedural aim of total tissue homogenisation in low-voltage zones (0.1–0.4 mV), complex electrogram elimination in the transitional zones and de-channelling if considered necessary.⁴⁸ This strategy resulted in similar rates of arrhythmia-free survival compared with the

typical stepwise ablation approach, without, however, implementing any additional substrate ablation in addition to pulmonary vein isolation in more than 50% of patients. These findings further support the concept of an individualised substrate-modification approach tailored to the specific left atrial tissue characteristics of each patient, avoiding potential unnecessary ablation and enhancing procedural safety.

Conclusion

The role of atrial fibrosis in the maintenance of persistent AF is well established. Despite our progress in accurately identifying the presence, location and extent of atrial fibrosis, there are gaps in understanding the optimal way of targeting those fibrotic areas of interest during catheter ablation. Diverse existing ablation strategies aiming to modify the arrhythmogenic substrate and to improve the outcome of patients with persistent AF subjected to catheter ablation need to be tested in adequately powered prospective, multicentre studies. These findings are expected to pave the way towards more effective invasive management of AF. ■

Clinical Perspective

- Left atrial fibrosis is independently associated with history of stroke and is a risk factor for future thromboembolic events. Evaluation of atrial fibrosis might improve thromboembolic risk stratification.
- Substrate-modification strategies targeting low-voltage areas in the left atrium may improve the long-term outcome of AF ablation.

- Haissaguerre M, Jais P, Shah DC, et al. Spontaneous initiation of atrial fibrillation by ectopic beats originating in the pulmonary veins. *N Engl J Med* 1998;339:659–66. <https://doi.org/10.1056/NEJM199809033391003>; PMID: 9725923.
- Nattel S. Molecular and cellular mechanisms of atrial fibrillation in atrial fibrillation. *JACC Clin Electrophysiol* 2017;3:425–35. <https://doi.org/10.1016/j.jacep.2017.03.002>; PMID: 29759598.
- Miragoli M, Salvarani N, Rohr S. Myofibroblasts induce ectopic activity in cardiac tissue. *Circ Res* 2007;101:755–8. <https://doi.org/10.1161/CIRCRESAHA.107.160549>; PMID: 17872460.
- de Bakker JM, Stein M, van Rijen HV. Three-dimensional anatomic structure as substrate for ventricular tachycardia/ventricular fibrillation. *Heart Rhythm* 2005;2:777–9. <https://doi.org/10.1016/j.hrthm.2005.03.022>; PMID: 15992738.
- Spach MS, Dolber PC. Relating extracellular potentials and their derivatives to anisotropic propagation at a microscopic level in human cardiac muscle: evidence for electrical uncoupling of side to side fiber connections with increasing age. *Circ Res* 1986;56:356–71. <https://doi.org/10.1161/01.RES.58.3.356>; PMID: 3719925.
- Gonzales MJ, Vincent KP, Rappel WJ, et al. Structural contributions to fibrillatory rotors in a patient-derived computational model of the atria. *Europace* 2014;16(Suppl 4):iv3–10. <https://doi.org/10.1093/europace/euu251>; PMID: 25362167.
- Zahid, Cochet H, Boyle PM, et al. Patient-derived models link re-entrant driver localization in atrial fibrillation to fibrosis spatial pattern. *Cardiovasc Res* 2016;110:443–54. <https://doi.org/10.1093/cvr/cwv073>; PMID: 27056895.
- Kim RJ, Chen EL, Lima JA, Judd RM. Myocardial Gd-DTPA kinetics determine MRI contrast enhancement and reflect the extent and severity of myocardial injury after acute reperfusion infarction. *Circulation* 1996;94:3318–26. <https://doi.org/10.1161/01.CIR.94.12.3318>; PMID: 8989146.
- Marrouche NF, Wilber D, Hindricks G, et al. Association of atrial tissue fibrosis identified by delayed enhancement MRI and atrial fibrillation catheter ablation: the DECAAF study. *JAMA* 2014;311:498–506. <https://doi.org/10.1001/jama.2014.3>; PMID: 24496537.
- McGann C, Akoum N, Patel A, et al. Atrial fibrillation ablation outcome is predicted by left atrial remodeling on MRI. *Circ Arrhythm Electrophysiol* 2014;7:23–30. <https://doi.org/10.1161/CIRCEP.113.000689>; PMID: 24363354.
- Spragg DD, Khurram I, Nazarian S. Role of magnetic resonance imaging of atrial fibrosis in atrial fibrillation ablation. *Arrhythm Electrophysiol Rev* 2013;2:124–7. <https://doi.org/10.15420/aer.2013.2.2.124>; PMID: 26835053.
- Spragg DD, Khurram I, Zimmerman SL, et al. Initial experience with magnetic resonance imaging of atrial scar and co-registration with electroanatomic voltage mapping during atrial fibrillation: success and limitations. *Heart Rhythm* 2012;9:2003–9. <https://doi.org/10.1016/j.hrthm.2012.08.039>; PMID: 23000671.
- Malcolm-Lawes LC, Juli C, Karim R, et al. Automated analysis of atrial late gadolinium enhancement imaging that correlates with endocardial voltage and clinical outcomes: a 2-center study. *Heart Rhythm* 2013;10:1184–91. <https://doi.org/10.1016/j.hrthm.2013.04.030>; PMID: 23685170.
- Badger TJ, Daccarett M, Akoum NW, et al. Evaluation of left atrial lesions after initial and repeat atrial fibrillation ablation: lessons learned from delayed-enhancement MRI in repeat ablation procedures. *Circ Arrhythm Electrophysiol* 2010;3:249–59. <https://doi.org/10.1161/CIRCEP.109.868356>; PMID: 20335558.
- Higuchi K, Cates J, Gardner G, et al. The spatial distribution of late gadolinium enhancement of left atrial magnetic resonance imaging in patients with atrial fibrillation. *JACC Clin Electrophysiol* 2018;4:49–58. <https://doi.org/10.1016/j.jacep.2017.07.016>; PMID: 29600786.
- Huo Y, Gaspar T, Pohl M, et al. Prevalence and predictors of low voltage zones in the left atrium in patients with atrial fibrillation. *Europace* 2018;20:956–62. <https://doi.org/10.1093/europace/eux082>; PMID: 28605524.
- Zghaib T, Keramati A, Chrispin J, et al. Multimodal examination of atrial fibrillation substrate: correlation of left atrial bipolar voltage using multi-electrode fast automated mapping, point-by-point mapping, and magnetic resonance image intensity ratio. *JACC Clin Electrophysiol* 2018;4:59–68. <https://doi.org/10.1016/j.jacep.2017.10.010>; PMID: 29520376.
- Cochet H, Mouriés A, Nivet H, et al. Age, atrial fibrillation, and structural heart disease are the main determinants of left atrial fibrosis detected by delayed-enhanced magnetic resonance imaging in a general cardiologic population. *J Cardiovasc Electrophysiol* 2015;26:484–92. <https://doi.org/10.1111/jce.12651>; PMID: 25727248.
- Jacidi A, Müller-Edenborn B, Chen J, et al. The duration of the amplified sinus-P-wave identifies presence of left atrial low voltage substrate and predicts outcome after pulmonary vein isolation in patients with persistent atrial fibrillation. *JACC Clin Electrophysiol* 2018;4:531–43. <https://doi.org/10.1016/j.jacep.2017.12.001>; PMID: 30067494.
- Daccarett M, Badger TJ, Akoum N, et al. Association of left atrial fibrosis detected by delayed-enhancement magnetic resonance imaging and the risk of stroke in patients with atrial fibrillation. *J Am Coll Cardiol* 2011;57:831–8. <https://doi.org/10.1016/j.jacc.2010.09.049>; PMID: 21310320.
- Akoum N, Fernandez G, Wilson B, et al. Association of atrial fibrosis quantified using LGE-MRI with atrial appendage thrombus and spontaneous contrast on transesophageal echocardiography in patients with atrial fibrillation. *J Cardiovasc Electrophysiol* 2013;24:1104–9. <https://doi.org/10.1111/jce.12199>; PMID: 23844972.
- King JB, Azadani PN, Suksaranjit P, et al. Left atrial fibrosis and risk of cerebrovascular and cardiovascular events in patients with atrial fibrillation. *J Am Coll Cardiol* 2017;70:1311–21. <https://doi.org/10.1016/j.jacc.2017.07.758>; PMID: 28882227.
- Müller P, Makimoto H, Dietrich JW, et al. Association of left atrial low-voltage area and thromboembolic risk in patients with atrial fibrillation. *Europace* 2018;20(F1_3):f359–65. <https://doi.org/10.1093/europace/eux172>; PMID: 29016757.
- Kirchhof P, Benussi S, Kotecha D, et al. 2016 ESC Guidelines for the management of atrial fibrillation developed in collaboration with EACTS. *Europace* 2016;18:1609–78. <https://doi.org/10.1016/j.rec.2016.11.033>; PMID: 28038729.
- Akoum N, Daccarett M, McGann C, et al. Atrial fibrosis helps select the appropriate patient and strategy in catheter ablation of atrial fibrillation: a DE-MRI guided approach. *J Cardiovasc Electrophysiol* 2011;22:16–22. <https://doi.org/10.1111/j.1540-8167.2010.01876.x>; PMID: 20807271.
- Jacidi AS, Cochet H, Shah AJ, et al. Inverse relationship between fractionated electrograms and atrial fibrosis in persistent atrial fibrillation: combined magnetic resonance imaging and high-density mapping. *J Am Coll Cardiol* 2013;62:802–12. <https://doi.org/10.1016/j.jacc.2013.03.081>; PMID: 23727084.
- Cochet H, Dubois R, Yamashita S, et al. Relationship between fibrosis detected on late gadolinium-enhanced CMR and re-entrant activity assessed with ECGI in human persistent atrial fibrillation. *JACC Clin Electrophysiol* 2018;4:17–29. <https://doi.org/10.1016/j.jacep.2017.07.019>; PMID: 29479568.
- Zlochiver S, Muñoz V, Vikstrom KL, et al. Electrotonic myofibroblast-to-myocyte coupling increases propensity to reentrant arrhythmias in two-dimensional cardiac monolayers. *Biophys J* 2008;95:4469–80. <https://doi.org/10.1529/biophysj.108.136473>; PMID: 18658226.
- Tanaka K, Zlochiver S, Vikstrom KL, et al. Spatial distribution of fibrosis governs fibrillation wave dynamics in the posterior left atrium during heart failure. *Circ Res* 2007;101:839–47. <https://doi.org/10.1161/CIRCRESAHA.107.153858>; PMID: 17704207.
- Calkins H, Hindricks G, Cappato R, et al. 2017 HRS/EHRA/ECAS/APHRS/SOLAECE expert consensus statement on catheter and surgical ablation of atrial fibrillation: Executive summary. *Europace* 2018;20:157–208. <https://doi.org/10.1093/europace/eux275>; PMID: 29016841.
- Verma A, Jiang CY, Betts TR, et al. Approaches to catheter ablation for persistent atrial fibrillation. *N Engl J Med* 2015;372:1812–22. <https://doi.org/10.1056/NEJMoa1408288>; PMID: 25946280.
- Hansen BJ, Zhao J, Fedorov VV. Fibrosis and atrial fibrillation: computerized and optical mapping: a view into the human atria at submillimeter resolution. *JACC Clin Electrophysiol* 2017;3:531–46. <https://doi.org/10.1016/j.jacep.2017.05.002>; PMID: 29159313.
- Chrispin J, Gucuk Ipek E, Zahid S, et al. Lack of regional association between atrial late gadolinium enhancement on cardiac magnetic resonance and atrial fibrillation rotors. *Heart Rhythm* 2016;13:654–60. <https://doi.org/10.1016/j.hrthm.2015.11.011>; PMID: 26569460.
- Gonzales MJ, Vincent KP, Rappel WJ, et al. Structural contributions to fibrillatory rotors in a patient-derived computational model of the atria. *Europace* 2014;16(Suppl 4):iv3–10. <https://doi.org/10.1093/europace/euu251>; PMID: 25362167.
- Hansen BJ, Zhao J, Csepe TA, et al. Atrial fibrillation driven by micro-anatomic intramural re-entry revealed by simultaneous sub-epicardial and sub-endocardial optical mapping in explanted human hearts. *Eur Heart J* 2015;36:2390–401. <https://doi.org/10.1093/eurheartj/ehv233>; PMID: 26059724.
- Oakes RS, Badger TJ, Kholmovski EG, et al. Detection and quantification of left atrial structural remodeling with delayed-enhancement magnetic resonance imaging in patients with atrial fibrillation. *Circulation* 2009;119:1758–67. <https://doi.org/10.1161/CIRCULATIONAHA.108.811877>; PMID: 19307477.
- Asvestas D, Vlachos K, Bazoukis G. Left atrial voltage mapping using a new impedance-based algorithm in patients with paroxysmal atrial fibrillation. *Pacing Clin Electrophysiol* 2018;41:1447–53. <https://doi.org/10.1111/pace.13501>; PMID: 30225845.
- Masuda M, Fujita M, Iida O, et al. Comparison of left atrial voltage between sinus rhythm and atrial fibrillation in association with electrogram waveform. *Pacing Clin Electrophysiol* 2017;40:559–67. <https://doi.org/10.1111/pace.13051>; PMID: 28211132.
- Kapa S, Desjardins B, Callans DJ, et al. Contact electroanatomic mapping derived voltage criteria for characterizing left atrial scar in patients undergoing ablation for atrial fibrillation. *J Cardiovasc Electrophysiol* 2014;25:1044–52. <https://doi.org/10.1111/jce.12452>; PMID: 24832482.
- Kottkamp H, Bender R, Berg J. Catheter ablation of atrial fibrillation: how to modify the substrate? *J Am Coll Cardiol* 2015;65:196–206. <https://doi.org/10.1016/j.jacc.2014.10.034>; PMID: 25593061.
- Tzeis S, Luik A, Jilek C, et al. The modified anterior line: an alternative linear lesion in perimitral flutter. *J Cardiovasc Electrophysiol* 2010;21:665–70. <https://doi.org/10.1111/j.1540-8167.2009.01681.x>; PMID: 20050958.
- Kottkamp H, Berg J, Bender R, et al. Box isolation of fibrotic areas (BIFA): a patient-tailored substrate modification approach for ablation of atrial fibrillation. *J Cardiovasc Electrophysiol* 2016;27:22–30. <https://doi.org/10.1111/jce.12870>; PMID: 26511713.
- Yang G, Yang B, Wei Y, et al. Catheter ablation of nonparoxysmal atrial fibrillation using electrophysiologically guided substrate modification during sinus rhythm after pulmonary vein isolation. *Circ Arrhythm Electrophysiol* 2016;9:e003382. <https://doi.org/10.1161/CIRCEP.115.003382>; PMID: 26857907.
- Yamaguchi T, Tsuchiya T, Nakahara S, et al. Efficacy of left atrial voltage-based catheter ablation of persistent atrial fibrillation. *J Cardiovasc Electrophysiol* 2016;27:1055–63. <https://doi.org/10.1111/jce.13019>; PMID: 27235000.
- Jacidi AS, Lehmann H, Keyl C, et al. Ablation of persistent atrial fibrillation targeting low-voltage areas with selective activation characteristics. *Circ Arrhythm Electrophysiol* 2016;9:p002962. <https://doi.org/10.1161/CIRCEP.115.002962>; PMID: 26966286.
- Efremidis M, Vlachos K, Letsas KP, et al. Targeted ablation of specific electrogram patterns in low-voltage areas after pulmonary vein atrial isolation in persistent atrial fibrillation: termination to an organized rhythm reduces atrial fibrillation recurrence. *J Cardiovasc Electrophysiol* 2019;30:47–57. <https://doi.org/10.1111/jce.13763>; PMID: 30288830.
- Rolf S, Kircher S, Arya A, et al. Tailored atrial substrate modification based on low-voltage areas in catheter ablation of atrial fibrillation. *Circ Arrhythm Electrophysiol* 2014;7:825–33. <https://doi.org/10.1161/CIRCEP.113.001251>; PMID: 25151631.
- Yang B, Jiang C, Lin Y, et al. STABLE-SR (Electrophysiological Substrate Ablation in the Left Atrium During Sinus Rhythm) for the treatment of nonparoxysmal atrial fibrillation: a prospective, multicenter randomized clinical trial. *Circ Arrhythm Electrophysiol* 2017;10. <https://doi.org/10.1161/CIRCEP.117.005405>; PMID: 29141843.