


Comparison of Unipedicular and Bipedicular Percutaneous Kyphoplasty for Kummell's Disease

Geriatric Orthopaedic Surgery
& Rehabilitation
Volume 13: 1–8
© The Author(s) 2022
Article reuse guidelines:
sagepub.com/journals-permissions
DOI: 10.1177/21514593221099264
journals.sagepub.com/home/gos


Dan Pan, MBBS¹  and Dayong Chen, MBBS¹

Abstract

Objective: To compare the clinical efficacy of unipedicular and bipedicular percutaneous kyphoplasty (PKP) for Kummell's disease. **Methods:** A retrospective study was performed to review 40 patients with stage I and II Kummell's disease who underwent PKP in our hospital from January 2015 to June 2018. Based on the transpedicular approach of PKP, those patients were randomly divided into unipedicular group (n = 19) and bipedicular group (n = 21). Operative time, bone cement injection volume and cement leakage rate were compared in the two groups. Pre- and post-operative visual analogue score (VAS), local kyphotic angle and average vertebral height were also evaluated. **Results:** All patients underwent surgery successfully. Compared with preoperative condition, VAS was significantly decreased at 1 day after operation and the last follow-up in both groups ($P < .05$), and local kyphotic angle and average vertebral height were restored markedly ($P < .05$). Operative time of both groups had no significant difference ($P > .05$). Bone cement injection volume was larger in bipedicular group ($P < .05$). At 1 day after operation and the last follow-up, the local kyphotic angle and average vertebral height in bipedicular group were restored better than those in unipedicular group ($P < .05$). There were 4 cases of cement leakage in both groups, with leakage rates of 21.1% and 19.0%, respectively, and the difference was not significant ($P > .05$). **Conclusion:** Both unipedicular and bipedicular PKP are effective for treating patients with stage I and II Kummell's disease, while postoperative pain relief and imaging results in bipedicular group were better than those in unipedicular group.

Keywords

Kummell's disease, percutaneous kyphoplasty, unipedicular approach, bipedicular approach, background

Submitted 30 December 2021. Revised 18 April 2022. Accepted 19 April 2022

Kummell's disease was first proposed in 1895, known as post-traumatic delayed vertebral collapse, with the main features of avascular vertebral necrosis (AVN) and intra-vertebral cleft (IVF). Kummell's disease occurred in a delayed fusion after minor trauma and present with kyphotic deformity, even with neurological symptoms.¹ Li et al. classified Kummell's disease into three stages: vertebral compression $<20\%$, with or without adjacent disc degeneration (stage I); vertebral compression $>20\%$, with adjacent disc degeneration (stage II); posterior wall rupture of vertebral body with spinal nerve compression (stage III).² For patients with no obvious relief of pain after

conservative treatments, surgery is needed to relieve pain, stabilize the spine and relieve nerve compression. Patients with stage I and II Kummell's disease are recommended to receive percutaneous vertebroplasty (PVP) or

¹Department of Spinal Surgery, The Affiliated Zhuzhou Hospital of Xiangya Medical College, Central South University, Zhuzhou, China

Corresponding Author:

Dan Pan, Department of Spinal Surgery, The Affiliated Zhuzhou Hospital of Xiangya Medical College, Central South University, Tianyuan District, Zhuzhou, Hunan 412000, China.
Email: pandan81@163.com



Creative Commons Non Commercial CC BY-NC: This article is distributed under the terms of the Creative Commons Attribution-NonCommercial 4.0 License (<https://creativecommons.org/licenses/by-nc/4.0/>) which permits non-commercial use, reproduction and distribution of the work without further permission provided the original work is attributed as specified on the

SAGE and Open Access pages (<https://us.sagepub.com/en-us/nam/open-access-at-sage>).

percutaneous kyphoplasty (PKP) because there are no neurological deficits. Both PVP and PKP are effective for the treatment of Kummell's disease, while PKP has advantage to correct kyphotic deformity.^{3,4} Controversy remains regarding whether a unipedicular or bipedicular PKP is superior.⁵⁻⁷ Some scholars concluded that the operative time, intra-operative fluoroscopy time and volume of bone cement injection were lower but could achieve similar clinical and radiographic outcomes in the unipedicular group, while some other scholars believed that the bipedicular PKP is more efficacious in height restoration and pain relief. From January 2015 to June 2018, 40 patients with stage I and II Kummell's disease were admitted in our hospital and underwent unipedicular or bipedicular PKP with satisfactory efficacy. The clinical effects are analyzed as follows.

Material and Methods

Case Selection

Inclusion criteria: (1) patients who were unresponsive to conservative treatment and underwent unipedicular or bipedicular PKP; (2) stage I and II Kummell's disease; (3) single vertebral lesion of thoracolumbar spine (T11-L2); (4) follow-up time ≥ 24 months. Exclusion criteria: patients with acute fracture, primary and secondary bone tumors, spinal infection or tuberculosis. Each patient underwent magnetic resonance imaging (MRI) to confirm the diagnosis of Kummell's disease. A total of 40 patients with Kummell's disease was enrolled in this study. Patients were randomly divided into unipedicular group ($n = 19$) and bipedicular group ($n = 21$). In both groups, patients' gender, age, fractured vertebra, course of disease, follow-up time, preoperative visual analogue score (VAS) were recorded and preoperative standing local kyphotic angle (angle between the upper and lower endplates of the fractured vertebral body) and average vertebral height (mean value of anterior and midline height of fractured vertebral body) were measured. Details were shown in Tables 1, 3, and 4.

Operation and Post-Operative Treatment

All operations were performed by the same group of surgeons. All patients were treated in a prone position under local anaesthesia using biplanar C-arm imaging guidance. In unipedicular group, the working channel was established through unilateral pedicle puncture, and in bipedicular group, two surgeons simultaneously established the working channel through bilateral pedicle puncture. PKP was performed using minimally invasive instruments and special balloons produced by Shanghai Kinetic Co., Ltd. Conditions related with balloon dilatation and fracture reduction were closely monitored during operation. The balloons are inflated using pressure control to create a cavity within the vertebra and to reduce the fracture deformity. Once this has been achieved, the balloons are deflated and removed, and mixed bone cement (polymethyl methacrylate, PMMA, Tecres, Italy) was prepared. PMMA cement was injected into the cavity. The injection stopped when the cement reached the posterior margin of the vertebral body. The patients walked on the ground 24 hours after operation and were given conventional drugs for anti-osteoporosis treatment after operation, such as calcium and calcitriol.

Outcomes Evaluation

Operative time, bone cement injection volume, patients' pain relief at preoperation, post operation and the last follow-up assessed by VAS were recorded. Two researchers especially trained in the measurement of radiological spinal parameters independently evaluated the standing local kyphotic angle and average vertebral height of the fractured vertebra on pre- and post-operative plain X-rays for all patients. CT scan of fractured vertebra was performed in postoperative reexamination for observing bone cement dispersion and cement leakage. Image analysis was carried out using Centricity Enterprise Web[®] (GE Healthcare, Buckinghamshire, UK). The mean values from both measurements were used for statistical analysis to minimize the risk of systematic bias.

Table 1. General Information of Patients With Kummell's Disease.

Groups	Cases	Gender		Age (year, $\bar{x} \pm s$)	Fractured vertebra				Course of disease (week, $\bar{x} \pm s$)	Follow-up (month, $\bar{x} \pm s$)
		M	F		T ₁₁	T ₁₂	L ₁	L ₂		
Unipedicular	19	7	12	73.21 \pm 7.64	2	7	5	5	8.63 \pm 4.59	27.58 \pm 3.69
Bipedicular	21	8	13	71.62 \pm 8.11	7	7	4	3	7.71 \pm 2.99	28.67 \pm 3.61
χ^2/t		.007		.637	3.297				.107	-.942
P		.935		.528	.348				.454	.352

Statistic Analysis

Statistic analysis was performed by using SPSS 17.0 (Chicago, USA). Measurement data were expressed as $\bar{x} \pm s$, paired sample *t*-test was used for comparison within group, and two independent sample *t*-test was used for comparison between groups. Enumeration data were analyzed by χ^2 test, and the α value of the test level was taken as .05.

Results

Comparisons of General Information in the Two Groups

The differences of gender, age, fractured vertebra, course of disease, follow-up time, preoperative VAS, preoperative local kyphotic angle and preoperative average vertebral height in the two groups were not significant ($P > .05$, Tables 1, 3, and 4) and comparable.

Perioperative Condition

All patients underwent surgery successfully. No injury of spinal cord, nerve root and bursa and rupture of balloon occurred during operation. The difference of operative time in the two groups was not significant ($P > .05$). Bone cement injection volume in bipedicular group was more than that in unipedicular group ($P < .05$, Table 2). There were 4 cases of asymptomatic cement leakage (leakage along lateral vertebral body) in both groups, with leakage rates of 21.1% and 19.0%, respectively. The difference between the two groups was not significant ($\chi^2 = .006$, $P > .05$).

VAS and Imaging Evaluation

Compared with preoperative condition, VAS was significantly decreased at 1 day after operation and the last follow-up in both groups ($P < .05$, Table 3). VAS in bipedicular group decreased more significantly than that in

Table 2. Comparison of Perioperative Condition of Patients With Kummell's Disease ($\bar{x} \pm s$).

Groups	Cases	Operative time (min)	Bone cement injection volume (mL)
Unipedicular	19	47.32 ± 7.22	3.73 ± .59
Bipedicular	21	52.52 ± 10.38	5.28 ± 1.17
<i>t</i>		-1.824	-5.321
<i>P</i>		.072	.000

Table 3. Comparison of Pre- and Post-Operative VAS of Patients With Kummell's Disease ($\bar{x} \pm s$).

Groups	Cases	VAS		
		Preoperation	1 day post operation	Last follow-up
Unipedicular	19	6.42 ± 1.61*	3.63 ± 1.61	3.21 ± 1.44
Bipedicular	21	6.48 ± 1.57*	2.28 ± .87	2.33 ± .73
<i>t</i>		-.110	2.786	2.396
<i>P</i>		.913	.010	.024

Note. VAS = visual analogue score, * means compared with other time points in the same group, $P < .05$.

Table 4. Comparisons of Pre- and Post-Operative Local Kyphotic Angle and Average Vertebral Height of Patients With Kummell's Disease ($\bar{x} \pm s$).

Groups	Cases	Local kyphotic angle (°)				Average vertebral height (mm)			
		Preoperation	1 day post operation	<i>t</i>	<i>P</i>	Preoperation	1 day post operation	<i>t</i>	<i>P</i>
Unipedicular	19	19.95 ± 3.49	12.89 ± 2.36	24.087	.000	15.63 ± 2.79	18.95 ± 3.06	-16.833	.000
Bipedicular	21	19.29 ± 3.45	10.71 ± 2.78	17.609	.000	17.24 ± 4.18	21.57 ± 4.39	-25.453	.000
<i>t</i>		.602	2.663			-1.441	-2.170		
<i>P</i>		.551	.011			.159	.036		

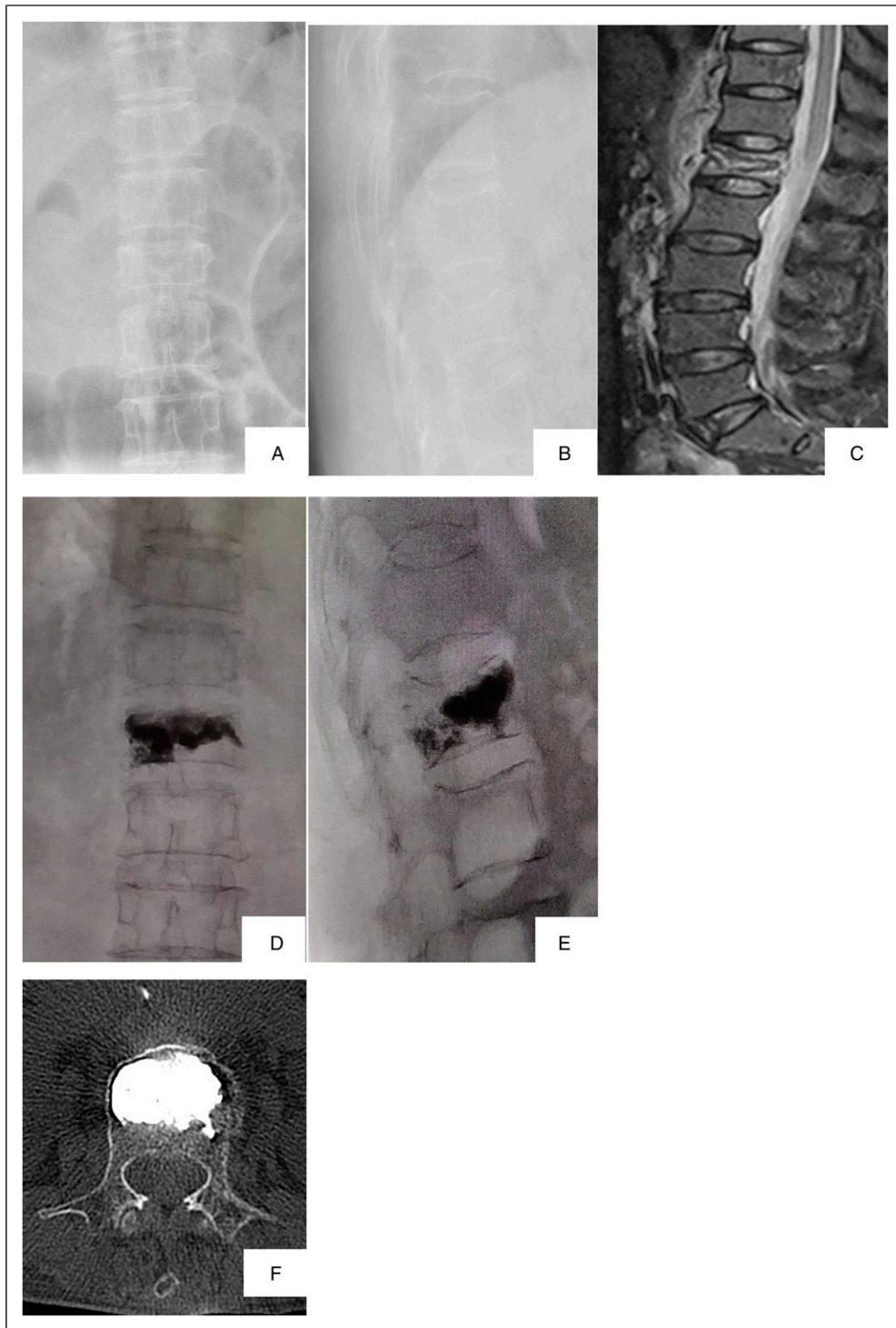


Figure 1. Typical case in unipedicular group (female, 70 years). (A-B): Pre-operative X-ray images. in (A) frontal and (B) lateral view showed L1 vertebral compression fracture; (C): Fat-suppressed MRI images showed hyperintense signal of vertebral body and clear boundary with the surrounding vertebral bodies signal. (D-E): X-ray images in (D) frontal and (E) lateral view in post operation reexamination showed reduction of L1 vertebral fracture and bone cement dispersion over the midline of vertebral body. (F): Postoperative CT scan of fractured vertebra showed no cement leakage.

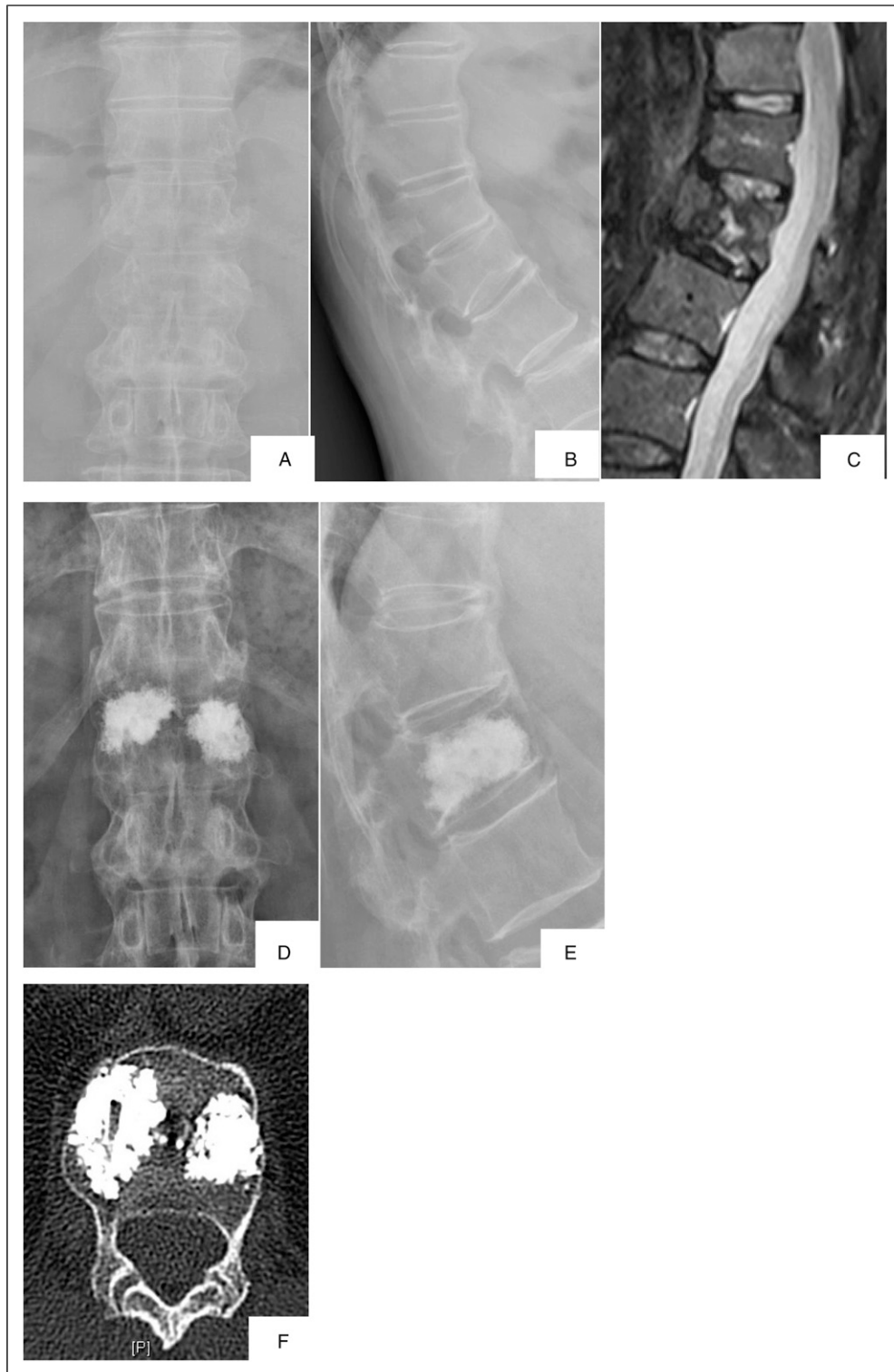


Figure 2. Typical case in bipedicular group (male, 65 years). A-B: Pre-operative X-ray images. in (A) frontal and (B) lateral view showed L1 vertebral compression fracture; (C): T2-weighted MRI image showed hyperintense signal of vertebra and clear boundary with the surrounding vertebral bodies signal. (D-E): X-ray images in (D) frontal and (E) lateral view in post-operative reexamination showed obvious reduction of L1 vertebral fracture, good restoration of average vertebral height and bilateral distribution of bone cement. (F): Postoperative CT scan of fractured vertebral body showed no cement leakage and bone cement with spongy distribution pattern.

unipedicular group ($P < .05$, Table 3). Local kyphotic angle and average vertebral height were restored markedly at 1 day after operation as compared with preoperative condition, and the improvement in bipedicular group was more obvious than that in unipedicular group ($P < .05$, Table 4). No middle/long term complications (such as bone cement dislocation and new vertebral fracture) were found in the follow-up of the both groups. Typical cases of the two groups were shown in Figure 1 and Figure 2.

Discussion

The incidence of Kummell's disease is relatively low and nonsurgical treatments have usually been less effective. Hence, many surgeons have advised that Kummell's disease should be treated by operative intervention.⁸ For the posterior vertebral wall rupture, combined with severe kyphotic deformity and neurological symptoms at stage III of Kummell's disease, open surgery is recommended.⁹ Patients with stage I and II Kummell's disease have no neurological symptoms, and the main goal of surgery is to eliminate fractured vertebral micromotion and reconstruct spinal stability, therefore, PVP or PKP is recommended.¹⁰ Both PVP or PKP can achieve satisfactory clinical efficacy. Compared with PVP, PKP has advantage in terms of correcting kyphosis.⁴ In this study, the clinical symptoms of patients in the two groups were improved significantly with satisfactory efficacy.

Controversy remains regarding whether a unipedicular or bipedicular PKP is superior.⁵⁻⁷ Researchers who supported unipedicular PKP considered that unipedicular PKP is comparable to bipedicular approach in clinical efficacy, while given the advantages of short operative time, low radiation exposure and incidence of complications, unipedicular approach should be recommended.¹¹ In this study, two surgeons simultaneously established the working channel through bilateral pedicle puncture in bipedicular group. The scan times of X-Ray in bipedicular group and surgery duration were comparable to that in unipedicular group. Bone cement leakage is a common complication of PKP. In order to decrease the leakage rate, intraoperative lateral C-arm fluoroscopy was used to observe the diffusion of bone cement discontinuously. We stopped injection when bone cement diffused to the posterior wall of the vertebral body. There were 4 cases of cement leakage in both groups, with leakage rates of 21.1% and 19.0%, respectively. There was no spinal canal involved by the bone cement leakage, all the leaky cement were along lateral vertebral body and the difference between the two groups was not significant.

The optimal bone cement injection volume for vertebroplasty remains controversial. Molly et al. reported that restoration of stiffness in the thoracic region required fill

volumes of 2 mL cement in the thoracic region, 4 mL in the thoracolumbar region, 8 mL in the lumbar region, while restoration of strength in vertebral body required 4 mL of cement.¹² Kim et al. revealed that stiffness was restored when bone cement filling volume reached 30% of the volume of a vertebral body.¹³ Liebschner et al. found that bone cement fill with unipedicular injection resulted in asymmetric distribution of the cement and further led to unstable conditions and deformation of vertebral body due to the single-sided load.¹⁴ Chevalier et al. proved that compliant cement distribution touching the inferior and the superior endplate in vertebroplasty was helpful to prevent future recollapse or fracture.¹⁵ Hence, proper bone cement fill volume and uniform distribution are essential for vertebral reconstruction. Unilateral puncture achieves the expected amount of cement perfusion and satisfactory distribution required the cement distribution across the midline,¹⁶ so that during puncture, the needle insertion point should be outward, or directly from the transverse-pedicle junction, while the abduction angle needs to be increased with the risk of intraoperative rupture of the medial wall of the pedicle, cement leakage, and nerve injury.

Kummell's disease is a rare type of osteoporotic vertebral compression fracture with obvious cleft and cavity in the fractured vertebral body in which cavity was filled by gas or liquid, or mixed gas and liquid, and changed with body position.¹⁷ Elimination of mechanical instability plays a key role in reducing pain, however, volume of cement injected as well as the correction of the kyphosis are also important for Kummel's disease. The efficacy of vertebral augmentation techniques on height restoration and kyphotic deformity correction were more remarkable in vertebrae with intravertebral cleft than in those without intravertebral cleft. Unrelieved or recurrent pain was reported to be related to incomplete filling of the cleft or interface failure between bone and cement.¹⁸⁻²⁰ For pain relief and functional recovery, the spongy group was superior to the blocky group. Therefore, the spongy distribution pattern should be formed during the injection of bone cement to obtain better therapeutic effect.²¹ Yu et al. concluded that due to the presence of fibroperichondrium on the inner wall of the cleft and sclerosis of the surrounding bone, bone cement is difficult to diffuse into the surrounding cancellous bone and form effective adhesion, only form solid lump in the cleft.²² The limited bone cement mass cannot be connected with the upper and lower adjacent endplates and cannot strengthen cancellous bone of vertebrae, which is more prone to stress shielding leading to recollapse, and cannot support the normal physiological stress from the body resulting in the continued existence of pain symptoms caused by osteoporosis.²³ Hence, bone cement injection should fill both the cleft in the vertebral body and the bone tissue around the

cleft to increase the stability and prevent later loss of average vertebral height.

In this study, to ensure better homogeneity of baseline characteristics, we included patients with Kummell's disease of a single vertebra in the thoracolumbar region. The bone cement injection volume in unipedicular group was less than 4 mL and bone cement failed to diffuse to the midline in some patients. It might be from the obstruction of fibroperichondrium on the inner wall of the cleft and sclerosis of the surrounding bone. Due to the advanced age of most patients, blood pressure and intraoperative pain increased significantly after unilateral procedure, contralateral puncture was no longer performed in one stage.

In our patients, individualized techniques of PKP were performed to make the cement sufficiently fill the cleft and anchor the peri-cleft bones, especially in the bipedicular group, which could avoid two percutaneous working canals enter the cleft simultaneously. Meanwhile, kyphoplasty curette tool is helpful to break up the walls of the cleft so cement can interdigitate "fluffy", and decrease the incidence of cement leakage. The bone cement volume and direction in bipedicular group could flexibly adjusted as needed with asymmetric distribution of the cement and easy to form spongy distribution pattern. The bone cement volume was higher in bipedicular group than that in unipedicular group. For postoperative pain relief and imaging results, VAS, local kyphotic angle and average vertebral height at 1 day after operation and the last follow-up improved more obviously in bipedicular group than in unipedicular group, which suggested that bipedicular group achieved better efficacy.

This study also has limitations. Firstly, some patients did not take X-ray examination at 2 years follow up, we could not collect all patients' imaging data, the comparative study could not be carried out. Secondly, Measurement on a single fractured vertebra was not enough, and sometimes might be flawed, because the fractured endplate was irregular and/or covered by cement after operation, which made the superior or inferior endplate was not legible enough. Overall sagittal spinal X-rays play a good complementary role in further studies. Thirdly, this study is a single-center retrospective study with limited cases and short follow-up time, so the long-term randomized controlled study with large sample are needed to further verify the clinical efficacy of bipedicular PKP in the treatment of Kummell's disease.

Conclusion

In summary, both unipedicular and bipedicular PKP are effective for treating patients with stage I and II Kummell's disease, while postoperative pain relief and imaging results in bipedicular group were better than unipedicular group.

Declaration of conflicting interests

The author(s) declared no potential conflicts of interest with respect to the research, authorship, and/or publication of this article.

Funding

The author(s) received no financial support for the research, authorship, and/or publication of this article.

Abbreviations

PKP: bipedicular percutaneous kyphoplasty; PVP: percutaneous vertebroplasty; AVN: avascular vertebral necrosis; IVF: intra-vertebral cleft; MRI: magnetic resonance imaging; VAS: visual analogue score; PMMA: polymethyl methacrylate.

Ethics approval and consent to participate

Ethical approval was obtained from the Affiliated Zhuzhou Hospital of Xiangya Medical College, Central South University, Zhuzhou, Hunan, China. All patients provided written informed consent prior to their inclusion within the study.

Availability of data and material

All data used or analyzed during this study are included in this published article.

ORCID iD

Dan Pan  <https://orcid.org/0000-0003-2071-6324>

References

1. Kummell H. Die rarefizierende ostitis der Wirbelkörper[J]. *Dtsch Med.* 1895;21(1):180-181.
2. Li K, Wong T, Kung F, Li A, Hsieh CH. Staging of Kümmell's disease[J]. *J Musculoskelet Res.* 2004;8:43-55.
3. Huang Y, Peng M, He S, Tang X, Dai M, Tang C. Clinical efficacy of percutaneous kyphoplasty at the hyperextension position for the treatment of osteoporotic Kümmell Disease[J]. *Clin Spine Surg.* 2016;29(4):161-166.
4. Kong LD, Wang P, Wang LF, Shen Y, Shang ZK, Meng LC. Comparison of vertebroplasty and kyphoplasty in the treatment of osteoporotic vertebral compression fractures with intravertebral clefts[J]. *Eur J Orthop Surg Traumatol.* 2014;24(suppl 1):S201-S208.
5. Xiong XM, Sun YL, Song SM, et al. Efficacy of unilateral transverse process-pedicle and bilateral puncture techniques in percutaneous kyphoplasty for Kummell disease[J]. *Exp Ther Med.* 2019;18(5):3615-3621.
6. Chen C, Chen L, Gu Y, et al. Kyphoplasty for chronic painful osteoporotic vertebral compression fractures via unipedicular versus bipedicular approachment: a comparative study in early stage[J]. *Injury.* 2010;41(4):356-359.

7. Jiang J, Gu FL, Li ZW, et al. The clinical efficacy and experience of bipedicular percutaneous vertebroplasty combined with postural reduction in the treatment of Kümmell's disease[J]. *BMC Musculoskel Disord*. 2020;21(1):82.
8. Huang YS, Ge CY, Feng H, et al. Bone cement-augmented short-segment pedicle screw fixation for Kümmell disease with spinal canal stenosis[J]. *Med Sci Monit*. 2018;24:928-935.
9. Lee GW, Yeom JS, Kim HJ, Suh BG. A therapeutic efficacy of the transpedicular intracorporeal bone graft with short-segmental posterior instrumentation in osteonecrosis of vertebral body: a minimum 5-year follow-up study[J]. *Spine (Phila Pa 1976)*. 2013;38(4):E244-E250.
10. Iida K, Harimaya K, Tarukado K, Tono O, Matsumoto Y, Nakashima Y. Kyphosis progression after balloon kyphoplasty compared with conservative treatment[J]. *Asian Spine J*. 2019;7(9):928-935.
11. Steinmann J, Tingey CT, Cruz G, et al. Biomechanical comparison of unipedicular versus bipedicular kyphoplasty[J]. *Spine*. 2005;30(2):201-205.
12. Molly S, Mathis JM, Belkoff SM. The effect of vertebral body percentage fill on mechanical behavior during percutaneous vertebroplasty[J]. *Spine*. 2003;28(14):1549-1554.
13. Kim JM, Shin DA, Byun DH, Kim HS, Kim S, Kim HI. Effect of bone cement volume and stiffness on occurrences of adjacent vertebral fractures after vertebroplasty[J]. *J Korean Neurosurg Soc*. 2012;52(5):435-440.
14. Liebschner MA, Rosenberg WS, Keaveny TM. Effects of bone cement volume and distribution on vertebral stiffness after vertebroplasty [J]. *Spine*. 2001;26(14):1547-1554.
15. Chevalier Y, Pahr D, Charlebois M, Heini P, Schneider E, Zysset P. Cement distribution, volume, and compliance in vertebroplasty: some answers from an anatomy-based nonlinear finite element study [J]. *Spine*. 2008;33(16):1722-1730.
16. Lin J, Qian L, Jiang C, et al. Bone cement distribution is a potential predictor to the reconstructive effects of unilateral percutaneous kyphoplasty in OVCFs: a retrospective study [J]. *J Orthop Surg Res*. 2018;13(1):140.
17. Theodorou DJ. The intravertebral vacuum cleft sign[J]. *Radiology*. 2001;221(3):787-788.
18. Sun G, Jin P, Li M, Liu XW, Li FD. Height restoration and wedge angle correction effects of percutaneous vertebroplasty: association with intraosseous clefts. *Eur Radiol*. 2011;21:2597-2603.
19. Krauss M, Hirschfelder H, Tomandl B, Lichti G, Bar I. Kyphosis reduction and the rate of cement leaks after vertebroplasty of intravertebral clefts. *Eur Radiol*. 2006;16:1015-1021.
20. Ha KY, Lee JS, Kim KW, Chon JS. Percutaneous vertebroplasty for vertebral compression fractures with and without intravertebral clefts. *J Bone Joint Surg Br*. 2006;88:629-633.
21. Chen J, Xiao Y, Chen D, Chang JZ, Li T. Clinical observation of two bone cement distribution modes of percutaneous vertebroplasty in the treatment of thoracolumbar Kümmell's disease[J]. *J Orthop Surg Res*. 2020;15(1):250.
22. Yu W, Liang D, Jiang X, Yao Z, Qiu T, Ye L. Efficacy and safety of the target puncture technique for treatment of osteoporotic vertebral compression fractures with intravertebral clefts [J]. *J Neurointerv Surg*. 2017;9(11):1113-1117.
23. Niu J, Song D, Zhou H, et al. Percutaneous kyphoplasty for the treatment of osteoporotic vertebral fractures with intravertebral fluid or air: a comparative study[J]. *Clin Spine Surg*. 2017;30(8):367-373.