

Received: 2021.10.09

Accepted: 2022.04.26

Available online: 2022.05.31

Published: 2022.06.09

Case Report of an Elderly Woman Who Presented with Hypothermia and an Electrocardiographic Finding of a J Wave

Authors' Contribution:

Study Design A
Data Collection B
Statistical Analysis C
Data Interpretation D
Manuscript Preparation E
Literature Search F
Funds Collection G

BDEF 1 **Bandar A. Alyami**
CDF 2 **Matthew M. Shotwell**
E 1 **Tyler C. Miller**
EF 2 **Yasmin S. Hamirani**

1 Department of Medicine, West Virginia University School of Medicine, Morgantown, WV, USA
2 Department of Cardiology, West Virginia University Heart and Vascular Institute, Morgantown, WV, USA

Corresponding Author: Yasmin S. Hamirani, e-mail: Yasmin.hamirani@wvumedicine.org

Financial support: None declared

Conflict of interest: None declared

Patient: Female, 92-year-old
Final Diagnosis: ECG abnormalities associated with hypothermia • sepsis
Symptoms: Confusion
Medication: —
Clinical Procedure: —
Specialty: Cardiology • General and Internal Medicine

Objective: Rare disease

Background: This report is of a 92-year-old woman who presented with hypothermia and an electrocardiogram (ECG) finding of a J wave, or Osborn wave. On ECG, the J wave had an elevation of the J point at the junction of the QRS complex and ST segment, which usually appears at a body temperature below 32°C.

Case Report: A 92-year-old woman presented to our hospital with an altered mental status. On evaluation, the vital signs were significant for low temperature (34.7°C), and she looked dehydrated. An ECG was performed as a part of the initial assessment and displayed normal sinus rhythm with an elevation of the J point (Osborn wave). Empiric antibiotic coverage was initiated for possible sepsis, in addition to supportive measures including hydration and passive external warming. By the next day, the patient's hypothermia was resolved, with improvement in her mental status, and a repeated ECG showed disappearance of the Osborn waves after appropriate warming.

Conclusions: This case highlights the importance of recognizing the J wave, or Osborn wave, and distinguishing it from ST-segment elevation seen in ischemic cardiac injury. Identification of the J wave is neither a specific finding nor predictive of patient outcome from hypothermia; however, an ECG should be performed in all patients with hypothermia as it serves a pivotal role in preventing progression to ventricular arrhythmia by prompt intervention and management.

Keywords: Arrhythmias, Cardiac • Electrocardiography • Electrolytes • Hypothermia • Sepsis

Full-text PDF: <https://www.amjcaserep.com/abstract/index/idArt/935076>



1010



—



3



16



Background

The Osborn wave is an electrocardiogram (ECG) abnormality that can precede other arrhythmia associated with hypothermia [1,2] and is defined as a deflection between the end of the QRS complex and the beginning of the ST segment (Figure 1) [3,4]. This clinical vignette highlights the valuable diagnostic and prognostic use of an ECG in hypothermia [5]. This report is of a 92-year-old woman who presented with hypothermia and an ECG finding of a J wave, or Osborn wave.

Case Report

We present an interesting case of a 92-year-old woman who was transferred to our hospital with an altered mental status.

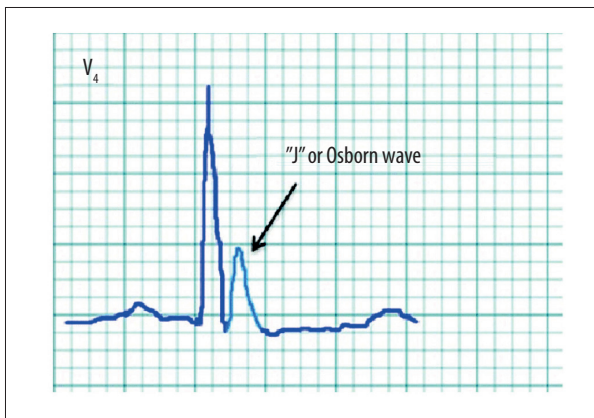


Figure 1. Osborn wave. Source: Chavez LO, Leon M, Einav S, Varon J, Editor's Choice – Inside the cold heart: A review of therapeutic hypothermia cardioprotection. *Eur Heart J Acute Cardiovasc Care.* 2017;6(2):130-41, used with permission from Oxford University Press for the European Society of Cardiology.

The patient's past medical history included hypertension, hypothyroidism, and chronic kidney disease. Her temperature was 34.7°C, oxygen saturation was 99% on room air, pulse rate was 89 beats/min with a regular rhythm, and blood pressure was 158/88 mm Hg. Initially, there was no clear reason for her low temperature. The patient was not alert or oriented. She looked dehydrated based on skin turgor, secondary to decreased oral intake a couple of days before her presentation. An ECG was performed as a part of the initial assessment and showed Osborn waves after the QRS complex (Figure 2). Laboratory testing revealed mild leukocytosis, acute kidney injury with an anion gap metabolic acidosis, and mildly elevated level of the cardiac enzyme troponin (60 ng/L; institutional reference range, 0-30 ng/L). Electrolytes were within the reference range. The brain computed tomography scan was unremarkable. The patient was admitted under medicine service for further management. Blood and urine cultures had no growth after monitoring for 72 h, which may have been due to the patient being given an antibiotic at an outside facility before she was transferred. The chest X-ray was unremarkable. A second ECG was performed, and it showed no change, with persistence of camel-hump waves between the QRS complex and T wave. The echocardiogram showed an ejection fraction of 55% without wall motion abnormalities, which lowered concern for takotsubo cardiomyopathy. She was placed on telemetry for cardiac monitoring, and it did not reveal any other abnormalities. Empiric antibiotic coverage was started for possible sepsis, in addition to supportive measures including hydration, passive external warming, and continuous monitoring. By the next day, the patient's hypothermia was resolved and her mental status was improved. The troponin level peaked at 230 ng/L then trended down to 104 ng/L, and a repeated ECG showed the disappearance of the Osborn waves after appropriate warming (Figure 3). The troponin elevation could have been related to non-ST-elevation myocardial infarction type 2, secondary to the possible ongoing sepsis, especially since the

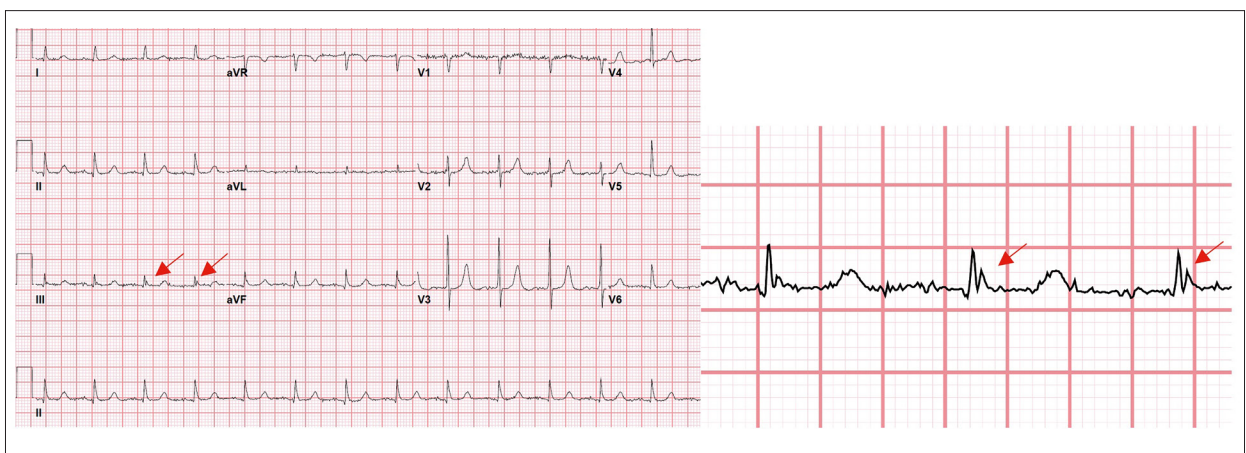


Figure 2. A 12-lead electrocardiogram obtained at core temperature of 34.7°C. Sinus rhythm with Osborn wave, an extra deflection at end of QRS complex on the lead III (arrow).

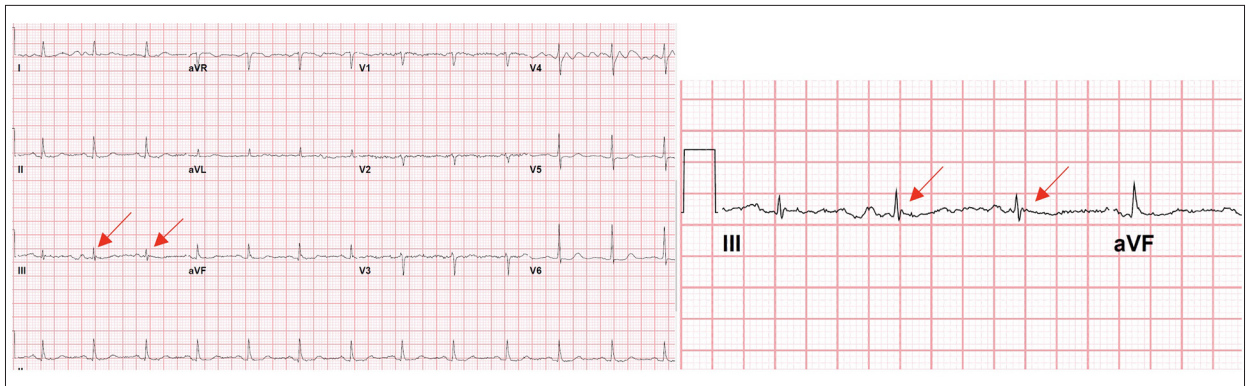


Figure 3. A 12-lead electrocardiogram obtained later, after the patient's temperature improved to 36.6°C, with disappearance of the extra deflection at the end of the QRS (Osborn wave).

patient's clinical picture and ECG abnormality improved after the initiation of a broad spectrum antibiotic. This patient's hypothermia was also most likely related to ongoing sepsis. She was discharged to a skilled nursing facility after returning to her regular baseline.

Discussion

This case highlights the importance of recognizing the J wave, or Osborn wave, and distinguishing it from the ST-segment elevation seen in ischemic cardiac injury. Hypothermia is defined as a core temperature below 35°C [1]. The ECG findings in the setting of hypothermia includes sinus bradycardia, QT prolongation "prolonged repolarization", QRS widening, and Osborn waves, which are also known as J waves, camel-hump waves, and hypothermic waves [2]. Our patient had no other EKG findings than J waves. Osborn waves can be seen diffusely on the ECG but are more commonly recognized in the inferior limb leads and precordial leads [3]. The incidence of Osborn waves in hypothermia is reported to be 80% [4]. Our patient had the classic Osborn wave, which is a deflection between the end of the QRS complex and the beginning of the ST segment [5]. Other cases associated with Osborn waves include acute myocardial ischemia [6], hypercalcemia [7], takotsubo cardiomyopathy [8], left ventricular hypertrophy due to hypertension [9], and Brugada syndrome [10]. One study on acute coronary syndrome showed that the presence of Osborn waves in the patients was correlated with a higher incidence of ventricular fibrillation and cardiac arrest [11]. Our patient's finding was not significant for any of the conditions reported in the cases above. It is hypothesized that the hypothermia-induced J wave is secondary to a prominent action potential notch in the epicardium because the epicardium has a large outward potassium current [12]. Hypothermia can cause renal tubular dysfunction and intracellular shift, which can lead to electrolyte abnormalities [13].

Treatment of hypothermia ranges from noninvasive passive external warming to advanced active warming techniques, such as extracorporeal life support, which has been shown to reduce mortality in severe hypothermia with circulatory instability [14-16]. Clinicians should be aware of the rare but fatal ECG findings in hypothermia, and our clinical vignette highlights the importance and significance of the ECG in hypothermia. ECG is a quick, noninvasive preliminary test that should be performed in all patients with hypothermia, and it serves a pivotal role in preventing progression to ventricular arrhythmia. Continuous monitoring of the patient's ECG and electrolytes while treating secondary causes of hypothermia is required. Our patient's case was managed, and she was discharged to a skilled nursing facility in a stable condition. Her ECG abnormality was resolved at the time of discharge.

Conclusions

The Osborn wave is an ECG abnormality that can precede other arrhythmia associated with hypothermia. This case highlights the importance of recognizing the J wave, or Osborn wave, and distinguishing it from ST elevation seen in ischemic cardiac injury. Identification of the J wave is neither a specific finding nor a prediction of patient outcome from hypothermia. Continuous monitoring of the patient's ECG and electrolytes while treating secondary causes of hypothermia is required.

Acknowledgements

We sincerely thank all the staff involved in patient care.

Institution Where Work Was Performed

Heart and Vascular Institute, West Virginia University School of Medicine, Morgantown, WV, USA.

Declaration of Figures' Authenticity

Figure 1 from Eur Heart J Acute Cardiovasc Care. 2017;6(2):130-41. Figures 2 and 3 submitted have been created by the authors who confirm that the images are original with no duplication and have not been previously published in whole or in part.

References:

1. Dietrichs ES, Tveita T, Smith G. Hypothermia and cardiac electrophysiology: A systematic review of clinical and experimental data. *Cardiovasc Res*. 2019;115(3):501-9
2. Slovis C, Jenkins R. ABC of clinical electrocardiography: Conditions not primarily affecting the heart. *BMJ*. 2002;324(7349):1320-23
3. Omar HR. The Osborn wave: What have we learned? *Herz*. 2016;41(1):48-56
4. Alhaddad IA, Khalil M, Brown EJ Jr. Osborn waves of hypothermia. *Circulation*. 2000;101(25):E233-44
5. Graham CA, McNaughton GW, Wyatt JP. The electrocardiogram in hypothermia. *Wilderness Environ Med*. 2001;12(4):232-35
6. Maruyama M, Atarashi H, Ino T, et al. Osborn waves associated with ventricular fibrillation in a patient with vasospastic angina. *J Cardiovasc Electrophysiol*. 2002;13(5):486-89
7. Otero J, Lenihan DJ. The "normothermic" Osborn wave induced by severe hypercalcemia. *Tex Heart Inst J*. 2000;27(3):316-17
8. Zorzi A, Migliore F, Perazzolo Marra M. Electrocardiographic J waves as a hyperacute sign of Takotsubo syndrome. *J Electrocardiol*. 2012;45(4):353-56
9. Patel A, Getsos JP, Moussa G, et al. The Osborn wave of hypothermia in normothermic patients. *Clin Cardiol*. 1994;17(5):273-76
10. Rudusky BM. The Osborn J wave revisited with reference to the Brugada syndrome. *Angiology*. 2013;64(2):161-62
11. Jastrzebski M, Kukla P. Ischemic J wave: Novel risk marker for ventricular fibrillation? *Heart Rhythm*. 2009;6(6):829-35
12. Yan GX, Antzelevitch C. Cellular basis for the electrocardiographic J wave. *Circulation*. 1996;93(2):372-79
13. Moore EM, Nichol AD, Bernard SA, et al. Therapeutic hypothermia: Benefits, mechanisms, and potential clinical applications in neurological, cardiac and kidney injury. *Injury*. 2011;42(9):843-54
14. Sessler DI. Complications and treatment of mild hypothermia. *Anesthesiology*. 2001;95(2):531-43
15. Paal P, Gordon L, Strapazzon G, et al. Accidental hypothermia-an update: The content of this review is endorsed by the International Commission for Mountain Emergency Medicine (ICAR MEDCOM). *Scand J Trauma Resusc Emerg Med*. 2016;24(1):111
16. Austin MA, Maynes EJ, O'Malley TJ, et al. Outcomes of extracorporeal life support use in accidental hypothermia: A systematic review. *Ann Thorac Surg*. 2020;110(6):1926-32