

## Original article

## Systemic sclerosis sine scleroderma in children

Francesco Zulian <sup>1</sup>, Gloria Lanzoni<sup>1</sup>, Biagio Castaldi<sup>1</sup>,  
Alessandra Meneghel<sup>1</sup>, Francesca Tirelli<sup>1</sup>, Elisabetta Zanatta<sup>2</sup> and  
Giorgia Martini <sup>1</sup>

## Abstract

**Objective.** Juvenile systemic sclerosis (JSSc) is a rare condition in childhood and its variety with no skin involvement, sine scleroderma (ssJSSc), is anecdotal. We report the first case series of patients with ssJSSc.

**Methods.** Demographic, clinical and laboratory data of patients with JSSc followed at our centre were retrospectively collected. Patients with no skin involvement but with all of the features RP, positive ANA, intestinal dysmotility and/or interstitial lung disease (ILD) or pulmonary arterial hypertension (PAH) and/or cardiac or renal involvement typical of scleroderma were defined as having ssJSSc and compared with those with classic JSSc (cJSSc).

**Results.** Among 52 JSSc patients seen in 20 years, five (9.6%) presented with ssJSSc. Their clinical features and those of the only two patients reported in the literature so far were compared with classic JSSc with available complete data. Six patients had cardiac involvement as presenting feature, three primary cardiomyopathy, three secondary to PAH. Two patients died after a brief disease course and one rapidly underwent heart transplantation. In comparison with cJSSc, ssJSSc showed a significantly longer diagnostic delay (20.1 vs 8.3 months,  $P=0.017$ ), higher frequency of cardiac involvement (85.7 vs 15.6%,  $P=0.001$ ) and worse outcome, intended as mortality or end-stage organ failure rates (42.9% vs 6.2%,  $P<0.001$ ).

**Conclusion.** Cardiac involvement represents the most important characteristic of ssJSSc and carries a high morbidity and mortality rate. The longer delay in diagnosis underlines the need for a comprehensive rheumatological work-up in patients with isolated cardiomyopathy or PAH/ILD.

**Key words:** scleroderma, juvenile systemic sclerosis, heart, pulmonary arterial hypertension, cardiomyopathy

## Rheumatology key messages

- Systemic Sclerosis is rare in childhood and its variety, sine scleroderma (ssJSSc) is anecdotal.
- We report clinical features, autoantibody profile and outcome of the first series of patients with ssJSSc.
- SsJSSc carries longer delay in diagnosis, significant cardiac involvement and worse outcome than classic JSSc.

## Introduction

Juvenile systemic sclerosis (JSSc) is a multisystem connective tissue disease characterized by hardening skin changes and widespread abnormalities of the viscera. The PRES/ACR/EULAR 2007 classification criteria require the presence of skin induration proximal to

metacarpal-phalangeal (MCP) joints and at least two of 20 minor criteria [1]. Even the recent classification criteria for systemic sclerosis in adults require the presence of skin thickening of the fingers extending proximal to the MCP joints as sufficient to classify the patient as having SSc [2]. In the absence of this finding, seven alternative criteria such as skin thickening of the fingers, fingertip lesions, telangiectasias, abnormal nailfold capillaries, interstitial lung disease or pulmonary arterial hypertension, RP, and SSc-related autoantibodies are to be considered indicative for the diagnosis [2].

Nevertheless, up to 10% of adult patients in whom a diagnosis of SSc is eventually made do not have clinically evident skin induration, and hence the definition 'sine scleroderma' [3–6]. The diagnosis of SSc in these patients

<sup>1</sup>Department of Woman and Child Health, University of Padua, Padua, Italy and <sup>2</sup>Rheumatology Division, Department of Medicine-DIMED, University of Padua, Padua, Italy

Submitted 22 July 2021; accepted 17 September 2021

Correspondence to: Francesco Zulian, Department of Woman's and Child's Health, University of Padua, Via Giustiniani 3, 35128 Padua, Italy. E-mail: francescozulian58@gmail.com

rests upon the presence of other characteristic clinical features such as RP, oesophageal hypomotility, nailfold capillary changes, digital tip pitting, evidence of pulmonary and/or renal involvement and specific serum autoantibodies [3]. JSSc is a very rare condition in childhood and its variety with no skin involvement, systemic sclerosis sine scleroderma (ssJSSc), is anecdotal as only two cases have been reported to date [7, 8].

Since little is known about its clinical presentation, disease progression and outcome, our objective was to describe the peculiar baseline characteristics of our own cases of ssJSSc and to review the data of the literature in order identify possible clues for a prompt diagnosis and proper treatment.

## Methods

### Study population

Unselected patients with juvenile systemic sclerosis (JSSc), diagnosed according to the PRES/ACR/EULAR criteria [1] and followed at our Centre since the year 2000 were retrospectively considered. Patients who did not satisfy the PRES/ACR/EULAR classification criteria [1] nor the 2013 ACR/EULAR SSc classification criteria [2] were considered as having ssJSSc if they satisfied all the following criteria: (i) RP or a peripheral vascular equivalent such as digital pitting scars, digital-tip ulcers or abnormal nailfold capillaries, (ii) positive ANA, (iii) any one of the following: distal oesophageal hypomotility, pulmonary interstitial fibrosis, pulmonary arterial hypertension, cardiac involvement typical of scleroderma or renal failure consistent with scleroderma renal crisis, and (iv) no other defined connective tissue diseases [3].

We collected demographic, clinical and laboratory data and autoantibody profile at the time of diagnosis of all the patients. The Juvenile Systemic Sclerosis Severity Score (J4S) was calculated to quantify the overall disease severity [9]. As part of J4S, the following clinical-instrumental parameters were considered: skin involvement evaluated by the modified Rodnan Skin Score, RP and/or digital lesions, chest X-ray, high-resolution CT (HRCT), diffusing capacity for carbon monoxide (DLCO), forced vital capacity (FVC), musculoskeletal involvement, oesophageal scinti-scan or 24-h pH-metry, malabsorption test and glomerular filtration rate (GFR). Cardiac investigations included at rest electrocardiography (EKG), standard transthoracic echocardiography (TTE) and speckle tracking echocardiography (STE) with assessment of left ventricular (LV) global longitudinal strain (GLS), a technique able to identify ventricular dysfunctions in JSSc in early stages [10]. A written informed consent was obtained from patients or legal representatives. According to the Padua University Hospital policy, approval from the Ethics Committee was not needed because all information was anonymously collected.

### Statistical analysis

The association between categorical variables was investigated with the  $\chi^2$  test or Fisher's exact test. The Mann-Whitney test was used to evaluate differences between the two groups, after verification of the non-normality distribution of variables considered in the analysis. *P*-values <0.05 were considered statistically significant. Statistical analyses were performed using SPSS version 18.0 (SPSS Inc., Chicago, IL, USA).

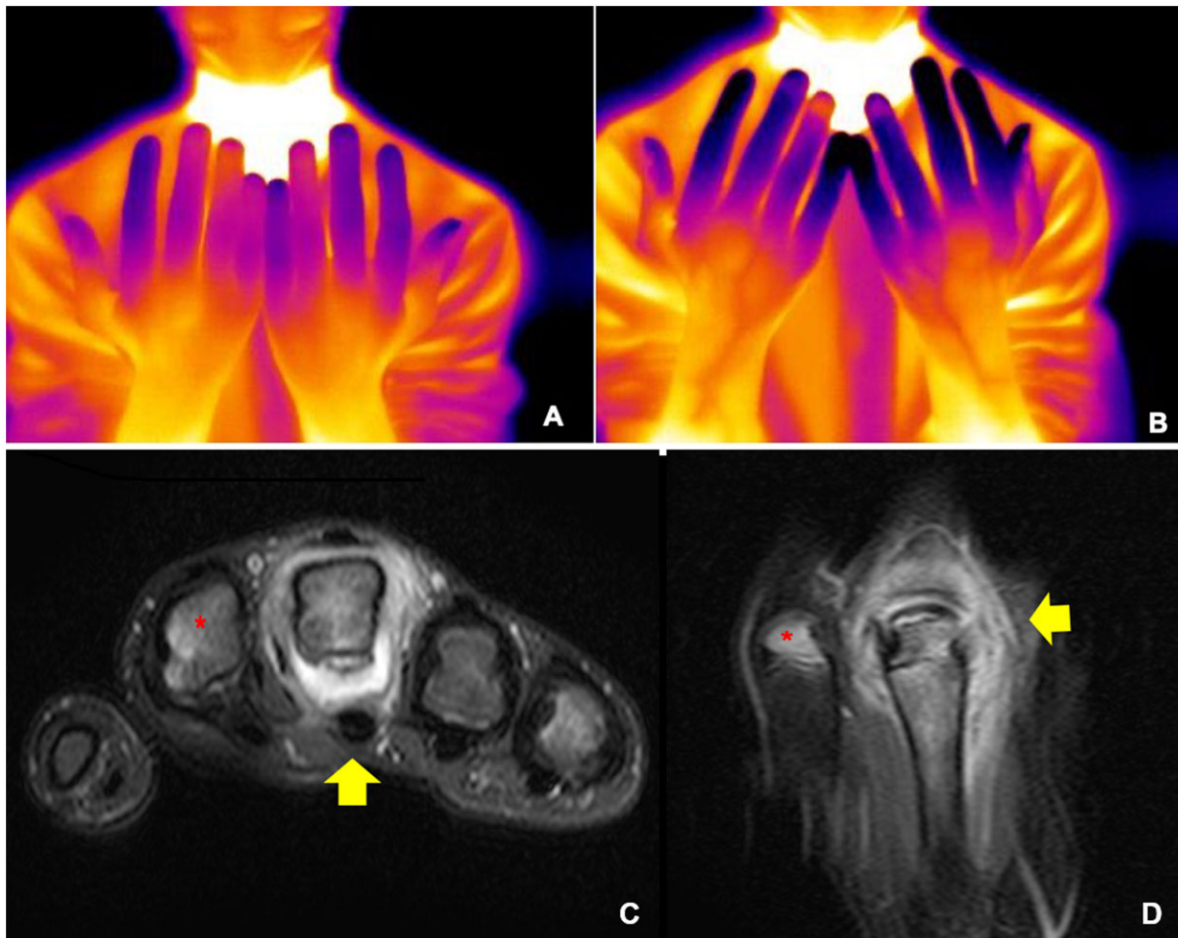
## Case histories

As instructive examples, we briefly report the clinical histories of two patients diagnosed with ssJSSc at our centre.

### Patient 1

A previously healthy 15-year-old male teenager was referred for episodes of alternating pallor-cyanosis of the second to third finger of the right hand, for about 1 year. As a football goalkeeper, he reported occasional short episodes of unexplained 'air hunger', not always associated with physical exertion. Three months before our observation, he presented arthritis at the third right finger. Physical examination revealed frank arthritis at the right third metacarpophalangeal (MCP) joint, no digital ulcers, sclerodactyly or skin changes. Capillaroscopy was abnormal with many dilated capillary loops but no clear scleroderma pattern. A cold-challenged thermography showed a prolonged rewarming time at second, third and fifth fingers of both hands, a pattern suggestive for RP (Fig. 1A and B) [11]. MRI of the right hand showed intense bone oedema involving the third metacarpus and the proximal third phalanx, and joint effusion with synovial thickening of the third MCP joint (Fig. 1C and D). The immunological laboratory results were positive for ANA at titre levels 1:160, homogeneous pattern, positive anti-topoisomerase I (anti-Scl-70), anti-55 Ro/SSA and anti-La/SSB antibodies. Other tested autoantibodies (anti-dsDNA, anti-RNP, anti-Sm, anti-histone, anti-centromere, anti-RNA polymerase, RF and anti-phospholipid antibodies) were all negative.

Oesophageal scintigraphy showed normal oesophageal transit. Pulmonary function tests revealed normal FVC but decreased DLCO that was 70% of the predicted value for age and body mass index. The pulmonary HRCT did not show any significant abnormality. EKG showed ventricular ectopic beats, confirmed by Holter-EKG. The TTE revealed a mild mitral valve prolapse with normal biventricular function while the STE showed a moderate myocardial dysfunction (GLS -13%, normal range between -20 and -25). This was confirmed by cardiac MRI (GLS -15%), which also showed a few small areas of hyperintense sub-endocardial signals in T2-weighted images at the lower postero-lateral LV wall. The J4S was 7/40. Since both paediatric and adult criteria for SSc were not satisfied, a diagnosis of ssJSSc was then established [3] and treatment with mycophenolate mofetil and calcium channel blockers was started.

**Fig. 1** Thermography showing RP

MRI showing active arthritis of the third metacarpophalangeal joint. (A, B) Thermography images showing the finger temperature at baseline (A) and 10 min after cold challenge (B). At second, third and fifth fingers of both hands is evident a markedly slowed rewarming, suggestive for RP. (C, D) Axial (C) and coronal (D) T2w fat saturated MR images showing synovial thickening of the third metacarpophalangeal joint with joint fluid (yellow arrow). Bone marrow oedema of the distal epiphysis of the second metacarpal bone is also evident (red asterisk).

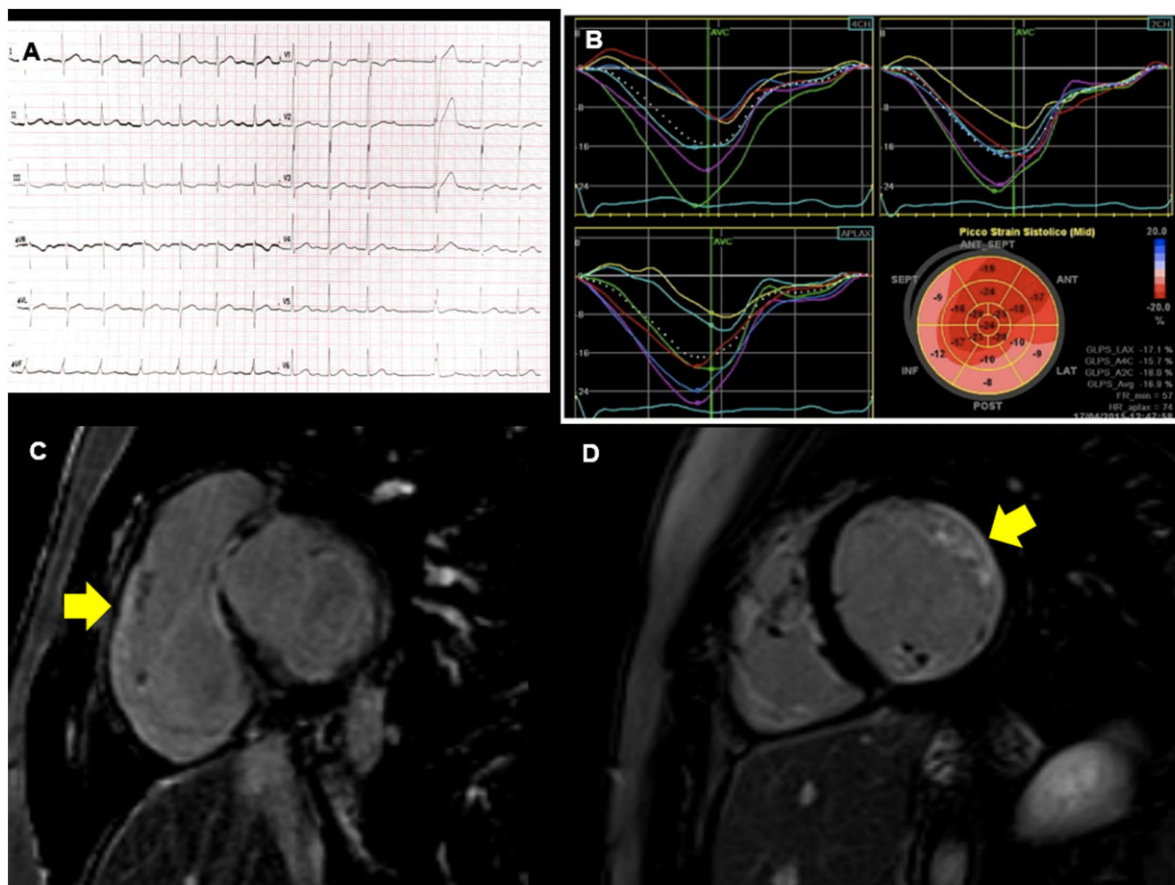
### Patient 2

A 16-year-old boy presented at our unit for suspected RP. Two years earlier, during a routine sports medicine check in his native country, an EKG showed ventricular ectopic beats and a TTE showed a moderate LV dilation with reduction of global kinetics (EF 46%). Nonetheless, he continued non-competitive physical activity during which he reported episodes of dyspnoea due to moderate-severe exertion (New York Heart Association class II). Two months later, cMRI showed a 'diffuse chronic myocarditis with signs of an active inflammatory process' so beta-blocker and antiarrhythmic agents were started.

Nine months later the family moved to Italy and soon after the patient was admitted to the emergency room because of cardiac arrest that needed cardiopulmonary resuscitation. After the patient's stabilization, EKG showed first-degree atrio-ventricular block with supraventricular and ventricular

ectopic beats, confirmed by Holter-EKG (Fig. 2A). TTE was suggestive of dilated cardiomyopathy (EF 30%) and STE showed a severe myocardial dysfunction involving both ventricles (Fig. 2B). A new cMRI confirmed the LV dilation with hypokinesia of the postero-lateral wall, positive late gadolinium enhancement images of the lower postero-lateral LV (Fig. 2C) and right ventricular (Fig. 2D) free walls, suggestive of myocardial fibrosis. An endomyocardial biopsy showed diffuse fibrous changes with lymphocytic infiltration (CD3<sup>+</sup>) and some macrophages (CD68<sup>+</sup>). A diagnosis of dilated cardiomyopathy was made, and an implantable cardioverter defibrillator was applied for secondary prevention. Because of the onset of RP, the patient was referred to our paediatric rheumatology unit. Physical examination showed no skin induration, and a cold digital fingertip with pitting scars at three fingers on the left hand and another two on the right. Nailfold video-capillaroscopy showed an early scleroderma

**Fig. 2** Arrhythmia (EKG), reduced LV global longitudinal strain (echocardiography), and myocardial fibrosis of the postero-lateral LV and RV walls (cMRI)



(A) First degree atrio-ventricular block with supraventricular ectopic beats. (B) Speckle tracking echocardiography curves showing LV reduced global longitudinal strain (pink segments). (C, D) Positive late gadolinium enhancement of the lower postero-lateral LV (C) and RV (D) free walls (arrow), suggestive of myocardial fibrosis. EKG: electrocardiography; LV: left ventricular; RV: right ventricular.

pattern. Autoantibody profile showed positive ANA (titre >1:1280, speckled pattern) and anti-RNA polymerase III (titre 1:640). All the other SSc-specific or associated autoantibodies resulted negative. Pulmonary HRTC and function tests were normal. Oesophageal scintigraphy showed dysmotility of the medium oesophagus and J4S was 12/40. A diagnosis of ssJSSc was made and therapy with rituximab (RTX) i.v. pulses, low dose oral prednisone and mycophenolate mofetil was started.

After an initial stabilization and mild improvement of the cardiac function for 1 year, the patient presented incoming episodes of ventricular tachycardia with progressive cardiac failure, and therefore he underwent urgent cardiac transplantation.

## Results

Up to 31 December 2020, among 52 patients with JSSc followed in our centre, we identified five patients (9.6%)

with clinical features that satisfied the criteria for ssSSc [3]. Their characteristics and those of the only two patients reported so far in the literature [7, 8] are summarized in Table 1.

The ssJSSc cohort consists of four females and three males, with an average age at diagnosis of 9.7 years (range 3–16 years). Interestingly, the age at diagnosis of females was lower than that of males [6(2.4) vs 14.7(1.5),  $P=0.002$ ]. All patients were positive for ANA and four for SSc-specific autoantibodies. Two patients tested positive for extractable nuclear antigen autoantibodies with no specificity and one was not tested at all [7]. RP was the presenting symptom in six patients while capillaroscopy abnormalities were present in all. This resulted in an early scleroderma pattern in two patients, active in two and pathological but non-specific in the remaining three. Six patients showed cardiac involvement at disease diagnosis. In three, it consisted in primary cardiomyopathy associated with arrhythmia and heart failure in two; in the other three, the cardiac



**TABLE 1** Clinical characteristics of patients with juvenile systemic sclerosis sine scleroderma

	Sex	Age at diagnosis (years)	ANA	SSc-specific autoantibodies	Capillaroscopy SSc pattern	Organ involvement				Outcome
						Cardiac	Vascular	Respiratory	Other	
Patient 1	M	15	1:640	Topo isomerase I (Scl70)	Abnormal non-specific	Primitive myocardiopathy (arrhythmia)	RP		Arthritis	Arrhythmia, Raynaud
Patient 2	M	16	1:1280	RNA polymerase III	Abnormal early	Primitive myocardiopathy (arrhythmia, CHF)	RP, DPS		Oesophageal dysmotility	Cardiac transplantation
Patient 3	F	9	1:640	Non-specific band	Abnormal active	Primitive myocardiopathy (arrhythmia, CHF)	RP		Oesophageal dysmotility	Cardiac arrest (deceased)
Patient 4	F	6	1:320	Non-specific band	Abnormal non-specific	None	RP	ILD	Oesophageal dysmotility	Moderate respiratory insufficiency
Patient 5	M	13	1:640	Centromere (ACA)	Abnormal non-specific	Secondary myocardiopathy (PAH)		PAH		Mild respiratory insufficiency
Reference no. 7	F	6	1:80	N/A	Abnormal active	Secondary myocardiopathy (PAH)	RP	ILD-PAH	Oesophageal dysmotility	Cardiorespiratory failure (deceased)
Reference no. 8	F	3	1:320	Topo isomerase I (Scl70)	Abnormal early	Secondary myocardiopathy (PAH)	RP	ILD-PAH		Moderate respiratory insufficiency

ACA: anti-centromeric antigens ; CHF: congestive heart failure; DPS: digital pitting scars; ILD: interstitial lung disease; PAH: pulmonary artery hypertension.

involvement was secondary to the presence of pulmonary artery hypertension (PAH). As for involvement of other internal organs, one patient presented with respiratory abnormalities [interstitial lung disease (ILD)], four had oesophageal involvement and one hand arthritis. Cardiac involvement substantially affected the outcome of these patients as two patients died from cardiac arrest, and one underwent an urgent heart transplantation. The other patients had various degrees of respiratory insufficiency (patient no. 3) or arrhythmia and RP (patient no. 1) (Table 1).

We compared the clinical characteristics of the patients with ssJSSc with those of 32 patients with classical presentation (cJSSc) and with complete data. As shown in Table 2, gender, age at onset of the first non-Raynaud symptom, disease severity at diagnosis, as assessed by J4S score, and disease duration at the last evaluation were comparable in the two groups. As for organ involvement, we observed a significantly higher prevalence of cardiac involvement in the ssJSSc group ( $P=0.0001$ ) while there were no significant differences

between the two groups. This has certainly influenced the long-term outcome of these patients. In fact, considering both mortality rate and end-stage organ failure globally, ssJSSc presented a worse prognosis in 43% of patients as compared with 6% in the control group. This worse outcome may have been also related to the prolonged delay in diagnosis, which was 20.1 months in comparison with only 8.3 months in the cJSSc group ( $P=0.017$ ).

As for capillaroscopy, it was abnormal in all ssJSSc patients, but a defined scleroderma pattern was significantly less frequent than in the cJSSc group ( $P=0.038$ ). ANA and SSc-specific autoantibodies were present in most patients, although their frequency did not differ in the two groups.

### Discussion

JSSc is a multisystem connective tissue disorder, characterized by fibrotic skin changes and abnormalities of

**TABLE 2** Comparison between patients with juvenile systemic sclerosis sine scleroderma (ssJSSc) and those with classic presentation (cJSSc)

	ssJSSc (n = 7)	cJSSc (n = 32)	P-value
Sex (female), n (%)	4 (57)	24 (75)	0.40
Age at onset of first non-RF, mean (s.d.), years months	9 y 3 m (4 y 5 m)	10 y 2 m (3 y 3 m)	0.59
Disease duration at last evaluation (five living patients), mean (s.d.), years months	7 y 6 m (5 y 0 m)	10 y 0 m (5 y 9 m)	0.38
Delay in diagnosis, mean (s.d.), months	20.1 (17.0)	8.3 (5.3)	<b>0.017</b>
Disease severity at diagnosis (J4S), mean (s.d.)	7.1 (2.7)	6.4 (2.4)	0.31
Organ involvement, n (%)			
Vascular	6 (86)	27 (84)	1.00
Respiratory	3 (43)	19 (59)	0.67
Renal	0 (0.0)	2 (6)	1.00
Cardiac	6.0 (86)	5 (16)	<b>0.001</b>
Gastrointestinal	4 (57)	19 (59)	1.00
Musculoskeletal	1 (14)	16 (50)	0.11
Outcome (mortality/end-stage organ failure), n (%)	3 (43)	2 (6)	<b>0.032</b>
SSc-specific capillaroscopy pattern, n (%)	4 (57)	30 (94)	<b>0.038</b>
Early	2 (29)	4 (13)	
Active	2 (29)	24 (75)	
Late	0 0	2 (6)	
Non-specific	3 (43)	2 (6)	
ANA, n (%)	6 (86)	30 (94)	0.38
SSc-specific autoantibodies, n (%)	4/6 (67)	18 (56)	0.55
Anti-tipoisomerase I (SCL-70)	2/6 (33)	16 (50)	0.66
Anti-centromere (ACA)	1/6 (17)	2 (6)	0.54
Rare SSc-specific autoantibodies, n (%)	1/6 (17)	2/24 (8)	0.78

P-values in bold indicate statistical significance. ACA: anti-centromeric antigens ; m: months; y: years.

internal organs. It rarely occurs in paediatric age, with a reported annual incidence of 0.45–1.9 cases per 100 000 persons [12]. In the largest series of patients with JSSc, characteristic skin induration was the most common reported feature, followed by RP and musculoskeletal symptoms [13]. JSSc has a variety of clinical manifestations but, despite this, it differs from the adult form in many aspects [14]; the peculiar finding for the diagnosis in both categories is the presence of skin involvement [1, 2].

The initial report of an adult SSc patient with visceral scleroderma without skin involvement was published in 1954 [15] and the first case series of ssSSc in adults in 1962 [16]. Only 40 years later, Poormoghim *et al.* published the first comprehensive description of a large series of 48 patients with ssSSc and proposed a set of criteria to guide the diagnosis [3]. According to these criteria, once other defined connective tissue diseases are excluded, a patient should be considered as having ssJSSc if RP or a peripheral vascular equivalent or abnormal nailfold capillaries, positive ANA and internal organ involvement typical of scleroderma are simultaneously present [3].

In this study, we describe the first case series of paediatric patients with JSSc without skin involvement, named juvenile systemic sclerosis sine scleroderma. Previously, only two case reports have been reported, which underlined the particularly aggressive clinical picture at disease onset, leading to death in one case and to respiratory insufficiency in the other [7, 8]. The cohort of patients with ssJSSc herein reported presented a particularly severe clinical picture at the time of diagnosis, with cardiac involvement in almost all of them. Other peculiar features of ssJSSc, in comparison with the classic subtype, were the prolonged delay in diagnosis (mean 20 vs 8 months), the higher mortality rate (43% vs 6%) and the less frequent SSc-specific capillaroscopy pattern (57% vs 94%). The prevalent cardiac involvement, the delay in diagnosis and the greater disease severity than in classical JSSc can easily explain the poor outcome reported in this condition.

Due to the lack of 'paediatric' criteria for the diagnosis of ssJSSc, we adopted the adult criteria to select the individual patients with ssJSSc among the cohort of JSSc patients followed at our centre during the two last decades. We were surprised to find that about 10% of patients presented this subtype of scleroderma, similarly to what was reported also in adults [3, 6]. One can argue that these patients might represent a subset in which the clinical manifestations of classic JSSc, including the skin induration, have yet to fully manifest, as possible incomplete forms. In reality, as shown in Table 2, no patients changed their clinical features during the follow-up and the disease duration at the last evaluation was comparable in the two groups. This confirms that ssJSSc represents an entity in its own right that does not change clinical characteristics over time.

The paediatric form of ssJSSc seems to differ from the adult form of ssSSc as the latter is more prevalent in

the female sex and often the extracutaneous clinical features and laboratory findings are most similar to that seen in the limited cutaneous SSc (lcSSc) subset [3–6]. Nevertheless, also in adult patients, it has been suggested that ssSSc should be considered as a specific subset of scleroderma that would require further specific clinical studies [17]. In our cohort, there was no net female prevalence (57%) and the lcSSc subset was very small and did not significantly differ from the classic JSSc subtype. As for the other main difference from reported data on adult ssSSc, primary cardiac involvement was the only one reported with higher frequency (43%) in our patients than in adults (11%) while oesophageal involvement, ILD and PAH were much more frequent in the adult forms [6]. All these aspects underline that ssJSSc represents a peculiar form of systemic sclerosis of childhood whose characteristics are unique in comparison with both classic JSSc and adult ssSSc.

In order to find a pathogenetic explanation for the significant myocardial involvement with skin sparing in patients with ssJSSc, the hypothesis of a 'vascular phenotype', raised by some authors for a subtype of SSc in adults, might be reasonable [18]. Apart from RP, also present in cJSSc, the higher prevalence of primary myocardial involvement and PAH in ssJSSc would indicate a more 'vascular phenotype' as compared with cJSSc. It is known that in primary cardiac involvement the microvascular damage is prevalent and the same has been reported in PAH, present in 3/7 of our patients [19]. On the other hand, skin involvement and musculoskeletal manifestations, absent or rare in our patients, are generally characterized by an initial greater inflammatory component that drives the subsequent fibrotic process [20]. This hypothesis could also be justified by the relative resistance to the aggressive immunosuppressive treatment that failed to arrest the clinical worsening in most of our ssJSSc patients.

A further element of interest is the difficulty in diagnosing ssJSSc as, in the absence of skin involvement, there was a delay in many cases. Our data clearly indicate that it is important to suspect ssJSSc in patients with unclassified cardiomyopathy or idiopathic pulmonary arterial hypertension associated or not with RP. In these cases, the search for ANA, and in particular for specific SSc-specific autoantibodies, associated with a nailfold capillaroscopy is crucial to speed up the diagnosis and address the proper treatment.

We acknowledge some limitations of our study, which was retrospective and heterogeneous in that patients were drawn from different sources. However, the method of data extraction was uniform and cases with incomplete clinical data at diagnosis were excluded from the analysis.

In conclusion, the cardiac involvement represents the most important clinical feature of ssJSSc at presentation and carries a high morbidity and mortality rate. These preliminary findings and, in particular, the longer delay in diagnosis in comparison with classical JSSc, underline the need for a comprehensive rheumatological work-up,

including the search for autoantibodies and nailfold capillaroscopy, in paediatric patients presenting with isolated cardiomyopathy and/or ILD or PAH, especially when associated with RP.

## Acknowledgements

The authors thank our statistician, Fabio Vittadello, for the careful data analysis. F.Z. and G.M. are the senior authors. F.Z. and G.L. designed the study. G.L., A.M. and F.T. performed the systematic literature review. A.M., G.M. and E.Z. contributed with patients to the study. F.Z. wrote the first draft of manuscript and all the other co-authors revised and approved the final version of the manuscript.

**Funding:** This study was financially supported by IL VOLO, Onlus, Association for childhood rheumatic diseases.

**Disclosure statement:** The authors have declared no conflicts of interest.

## Data availability statement

Additional unpublished data from the study are available by sending an E-mail to the corresponding author (F.Z.).

## References

- Zulian F, Woo P, Athreya BH *et al.* The Pediatric Rheumatology European Society/American College of Rheumatology/European League against Rheumatism provisional classification criteria for juvenile systemic sclerosis. *Arthritis Rheum* 2007;57:203–12.
- Van den Hoogen F, Khanna D, Fransen J *et al.* 2013 classification criteria for systemic sclerosis: an American College of Rheumatology/European League against Rheumatism collaborative initiative. *Arthritis Rheum* 2013;65:2737–47.
- Poormoghim H, Lucas M, Fertig N *et al.* Systemic sclerosis sine scleroderma: demographic, clinical, and serologic features and survival in forty-eight patients. *Arthritis Rheum* 2000;43:444–51.
- Diab S, Dostrovsky N, Hudson M *et al.*; Canadian Scleroderma Research Group. Systemic sclerosis sine scleroderma: a multicenter study of 1417 subjects. *J Rheumatol* 2014;41:2179–85.
- Simeon-Aznar CP, Fonollosa-Pla V, Tolosa-Vilella C *et al.* Registry of the Spanish Network for Systemic Sclerosis: clinical pattern according to cutaneous subsets and immunological status. *Semin Arthritis Rheum* 2012;41:789–800.
- Marangoni RG, Rocha LF, Del Rio APT *et al.* Systemic sclerosis sine scleroderma: distinct features in a large Brazilian cohort. *Rheumatology (Oxford)* 2013;52:1520–4.
- Navon P, Halevi A, Brand A *et al.* Progressive systemic sclerosis sine scleroderma in a child presenting as nocturnal seizures and Raynaud's phenomenon. *Acta Paediatr* 1993;82:122–3.
- Zloof Y, Schonfeld T, Dagan T *et al.* Systemic sclerosis sine scleroderma with pulmonary arterial hypertension in a 3-year-old girl. *Pediatrics* 2020;145:e20192504.
- La Torre F, Martini G, Russo R *et al.* A preliminary disease severity score for juvenile systemic sclerosis. *Arthritis Rheum* 2012;64:4143–50.
- Civieri G, Castaldi B, Martini G *et al.* Early detection of ventricular dysfunction in juvenile systemic sclerosis by speckle tracking echocardiography. *Rheumatology (Oxford)* 2021;60:103–7.
- Martini G, Cappella M, Culpo R *et al.* Infrared thermography in children: a reliable tool for differential diagnosis of peripheral microvascular dysfunction and Raynaud's phenomenon. *Pediatr Rheumatol Online J* 2019;17:68.
- Herrick AL, Ennis H, Bhushan M *et al.* Incidence of childhood linear scleroderma and systemic sclerosis in the UK and Ireland. *Arthritis Care Res (Hoboken)* 2010;62:213–8.
- Martini G, Foeldvari I, Russo R *et al.*; Juvenile Scleroderma Working Group of the Pediatric Rheumatology European Society. Systemic sclerosis in childhood: clinical and immunologic features of 153 patients in an international database. *Arthritis Rheum* 2006;54:3971–8.
- Zulian F, Martini G. Childhood systemic sclerosis. *Curr Opin Rheumatol* 2007;19:592–7.
- Abrams HL, Carnes WH, Eaton J. Alimentary tract in disseminated scleroderma with emphasis on small bowel. *Arch Intern Med* 1954;94:61–81.
- Rodnan GP, Fennell RH. Progressive systemic sclerosis sine scleroderma. *JAMA* 1962;180:665–70.
- Allanore Y. Limited cutaneous systemic sclerosis: the unfairly neglected subset. *J Sclerod Rel Dis* 2016;1:241–6.
- Allanore Y, Distler O, Matucci-Cerinic M, Denton CP. Defining a unified vascular phenotype in systemic sclerosis. *Arthritis Rheum* 2018;70:162–70.
- Asano Y, Sato S. Vasculopathy in scleroderma. *Semin Immunopathol* 2015;37:489–500.
- Denton CP, Khanna D. Systemic sclerosis. *Lancet* 2017;390:1685–99.