

# Vitamin K deficiency-induced spontaneous haemopericardium and cardiac tamponade in an infant with alpha-1 antitrypsin deficiency: a case report

Christoph Bauer <sup>1,2</sup>, Désirée Furthner <sup>2,3</sup>, Eva Grohmann <sup>1,\*</sup>, and Gerald Tulzer <sup>1,2</sup>

<sup>1</sup>Department of Paediatric Cardiology, Kepler University Hospital GmbH, Krankenhausstrasse 26-30, 4020 Linz, Austria; <sup>2</sup>Faculty of Medicine, Johannes Kepler University Linz, Altenbergerstrasse 68, 4040 Linz, Austria; and <sup>3</sup>Department of Paediatrics and Adolescent Medicine, Kepler University Hospital GmbH, Krankenhausstrasse 26-30, 4020 Linz, Austria

Received 22 May 2020; first decision 16 June 2020; accepted 12 November 2020

## Background

Vitamin K deficiency bleeding is a life-threatening complication in early infancy. Exclusive breastfeeding and neonatal cholestasis syndromes, most notable  $\alpha$ -1-antitrypsin deficiency, have been reported to be risk factors. Intracranial haemorrhage is most common. No association to haemopericardium has been reported before.

## Case summary

We report on an 11 weeks old at term-born infant, who presented with severe anaemia and signs of cardiogenic shock. Immediately echocardiography was done and depicted cardiac tamponade. Pericardiocentesis was performed and a significant amount of haemorrhagic fluid was removed. Further workup revealed deranged coagulation parameters, cholestatic liver disease, and reduced  $\alpha$ -1-antitrypsin levels. Despite normal brain sonography, a small cerebral haemorrhage was detected on magnetic resonance imaging. A genetic test finally proofed homozygotic mutation of the SERPINA1-gene and confirmed the diagnosis of  $\alpha$ -1-antitrypsin deficiency as the underlying cause. After initial replacement of coagulation factors, erythrocytes and vitamin K, the infant recovered. Eighteen weeks after discharge, the infant is still on vitamin K supplementation. She did not have any further bleedings and no neurologic or developmental impairment.

## Discussion

Alpha-1-antitrypsin deficiency can lead to vitamin K deficiency in young infants even with adequate prophylaxis. Spontaneous haemorrhagic pericardial effusion was a new manifestation of vitamin K deficiency bleeding in our patient and should be considered and ruled out in young infants who present with acute anaemia and poor clinical condition.

## Keywords

Vitamin K deficiency bleeding • Haemopericardium • Cardiac tamponade • Alpha-1-antitrypsin deficiency • Infant • Case report

## Learning points

- Spontaneous haemopericardium complicated by cardiac tamponade should be considered and ruled out in young infants who present in poor clinical condition and with acute anaemia.
- Coagulation disorders should be ruled out in infants with unclear pericardial effusion.

\* Corresponding author. Tel: 00435768084/24815, Email: [desiree.furthner@kepleruniklinikum.at](mailto:desiree.furthner@kepleruniklinikum.at)

Handling Editor: Inga Voges

Peer-reviewers: Sylvia Krupickova, Daniele Giacompo and Arvind Singh

Compliance Editor: Abdelrahman Ibrahim Abushouk

Supplementary Material Editor: Ross Thomson

© The Author(s) 2020. Published by Oxford University Press on behalf of the European Society of Cardiology.

This is an Open Access article distributed under the terms of the Creative Commons Attribution Non-Commercial License (<http://creativecommons.org/licenses/by-nc/4.0/>), which permits non-commercial re-use, distribution, and reproduction in any medium, provided the original work is properly cited. For commercial re-use, please contact [journals.permissions@oup.com](mailto:journals.permissions@oup.com)

## Introduction

Vitamin K deficiency is a common cause for neonatal bleeding and can be life-threatening.<sup>1,2</sup> Vitamin K prophylaxis is aimed to prevent coagulation disorders but may not be sufficient in all infants, particularly with unrecognized neonatal cholestasis causing malabsorption.<sup>3</sup> Intracranial haemorrhage is typical but other organs may be affected too.<sup>4,5</sup> Biliary atresia and  $\alpha$ -1-antitrypsin deficiency are two of the most common causes of cholestasis in infants and can lead to malabsorption of fat-soluble vitamins resulting in vitamin K deficiency.<sup>6</sup> We report on an infant, who showed haemopericardium and cardiac tamponade as a new manifestation of vitamin K deficiency bleeding due to  $\alpha$ -1-antitrypsin deficiency.

## Timeline

Age:	Events:
Past medical history: healthy at term-born girl, breast and partially formula fed, received 2 mg of vitamin K p.o. after birth, during the 1st week and after 7 weeks.	
10 + 4 weeks	Weakness, vomiting, sucking weakness
10 + 6 weeks	Admission to local hospital due to aggravating symptoms
11 + 0 weeks	Sudden drop in haemoglobin level (6.3 g/dL, normal 9.2–15.0 g/dL), administration of erythrocytes, new onset of pericardial effusion Transfer to our intensive care unit, signs of cardiogenic shock, emergency pericardiocentesis (drainage of 150 ml blood), milrinone i.v., replacement of deranged coagulation parameters, administration of 1 mg vitamin K i.v. Diagnosis of cholestatic liver disease, reduced $\alpha$ -1-antitrypsin level (37 mg/dL, normal 90–120 mg/dL), white matter lesion (cerebral-magnetic resonance imaging)
11 + 2 weeks	removal of pericardial tubes, exclusion of biliary atresia (liver biopsy), exclusion of viral hepatitis (serology) initiation of vitamin deficiency replacement therapy: cholecalciferol, tocopherol, retinol and vitamin K
12 + 3 weeks	Genetic testing: homozygotic mutation of the SERPINA1-gene (c.1096G>A), PiZZ-type confirmed $\alpha$ -1-antitrypsin deficiency Discharge: without any neurologic deficits
35 + 4 weeks	Latest outpatient visit: appropriate weight gain, no developmental delay or neurologic deficits, continuation of the vitamin deficiency replacement therapy

## Case presentation

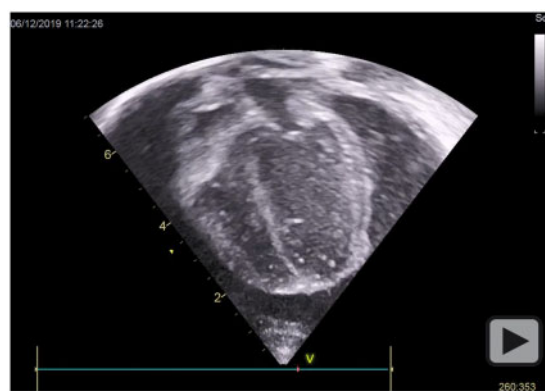
A previously healthy at term-born 11-week-old girl was transferred from a local hospital to our intensive care unit with a history of new-

onset pericardial effusion and a sudden drop in haemoglobin levels (6.3 g/dL, normal 9.2–15.0 g/dL), which was treated with erythrocyte transfusion. Symptoms started 3 days prior to admission with weakness, vomiting, and refusal to drink and aggravated during the last night. The patient was the first child of non-consanguineous parents with no family history of liver disease or bleeding disorders. There was no history of trauma.

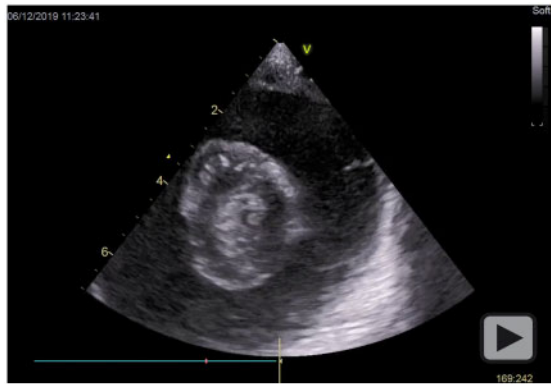
On admission to our centre, the infant was in a poor clinical condition. Physical examination revealed normal heart sounds which could be heard well, a heart rate of 134–155 b.p.m. with different heights of amplitude, a blood pressure of 76/57 mmHg, and an extended capillary refill time. The saturation was good, but the venous blood gas analysis showed lactate acidosis with pH 7.18 and blood lactate concentration of 8.5 mmol/L (normal 0.5–1.6 mmol/L). The infant was pale, tachypnoeic, tachycardic, and showed a slight icterus and moderate hepatosplenomegaly that was confirmed by ultrasound.

Emergency echocardiography was performed and depicted a significant amount of pericardial effusion leading to haemodynamic compromise. Two-dimensional echocardiography demonstrated collapse of the right atrium and right ventricle (*Video 1*) as well as inspiratory bouncing of the interventricular septum towards the left ventricle (*Video 2*). Pulsed wave Doppler of mitral valve inflow was marked reduced on inspiration (*Figure 1*) and M-Mode showed the paradoxical movement of the interventricular septum in early diastole (*Figure 2*). Cardiac tamponade was immediately treated with pericardiocentesis and tube placement. One hundred and fifty millilitres of haemorrhagic fluid was drained from the pericardial space and the patient improved. In addition, milrinone was started to improve cardiac function.

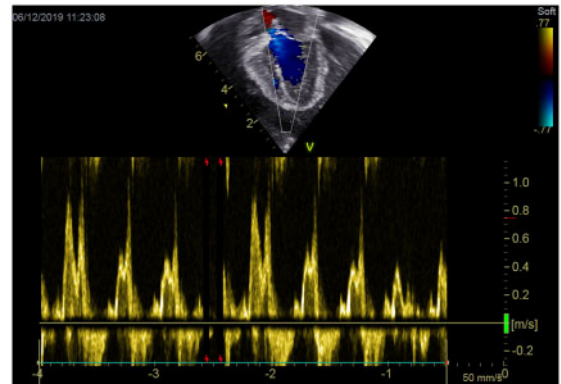
Coagulation parameters were severely deranged with extended prothrombin time (14 s, normal < 11 s), reduced factor II activity (27%, normal 70–120%) and factor X activity (52%, normal 70–120%), and slight extended aPTT (30.4 s, normal 21.6–28.7 s), and had to be replaced with 1 mg vitamin K intravenously and human coagulation factor II, VII, IX, and X with following fast regression of the coagulation profile. Laboratory tests further revealed cholestatic liver disease [elevated total bilirubin (3.52 mg/dL, normal 0–1.2 mg/dL),



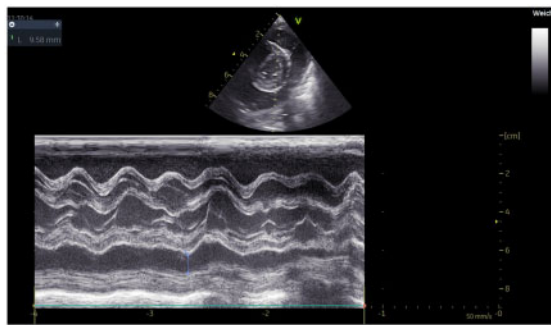
**Video 1** Echocardiography (apical four-chamber view) in our patient with cardiogenic shock showing significant amount of pericardial effusion compressing the right atrium and right ventricle in diastole. Note the presence of fibrin strains.



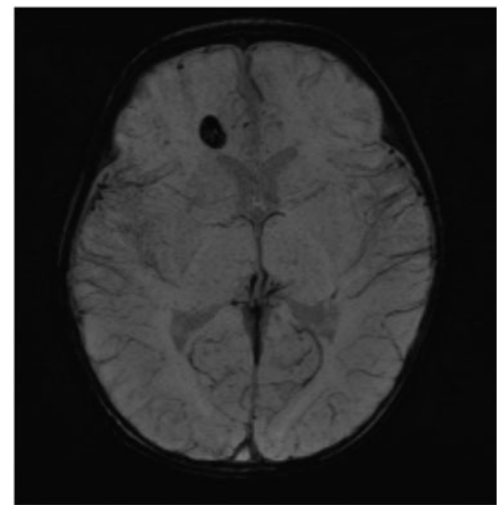
**Video 2** Echocardiography (parasternal short axis): note inspiratory bouncing of the interventricular septum towards the left ventricle.



**Figure 2** Echocardiography (apical four-chamber view): mitral valve inflow pattern demonstrating a reduction in mitral peak E-wave velocity during inspiration.



**Figure 1** Echocardiography (parasternal short axis): M-mode showing the paradoxical movement of the interventricular septum in early diastole.



**Figure 3** Brain-magnetic resonance imaging (maximal intensity projection) of the patient showing a white matter lesion of 10 × 6 mm in the right frontal lobe.

gamma GT (253 U/L, normal 27–134 U/L), and a reduction of total protein (52.9 g/L, normal 64–87 g/L), and  $\alpha$ -1-antitrypsin levels (37 mg/dL, normal 90–200 mg/dL)]. Thrombocytes were within normal limits.

Vitamin K deficiency bleeding due to  $\alpha$ -1-antitrypsin deficiency was suspected. In addition, cholecalciferol (4000 IU), tocopherol (0.35 mg/kg), and retinol (4000 IU) were started to replace fat-soluble vitamins.

During workup, biliary atresia and viral hepatitis were excluded with liver biopsy and serology. To rule out cerebral bleeding, magnetic resonance imaging was performed and despite normal brain sonography a small haemorrhage (10 × 6 mm) in the right frontal lobe was detected (Figure 3). However, no signs of neurologic deficits were evident. A genetic test finally proved homozygous mutation of the SERPINA1-gene (c.1096G>A), PiZZ-type and confirmed the diagnosis of  $\alpha$ -1-antitrypsin deficiency.

Pericardial tubes could be removed 2 days after placement and the infant recovered. The patient was discharged 10 days after admission

with vitamin K, cholecalciferol, tocopherol, and retinol as long-term medication. The first follow-up 1 month after discharge showed a normal echocardiography and liver sonography. Also 23 weeks after discharge, the patient still presented without any neurologic deficits or signs of pericardial effusion as well as good cardiac function. The laboratory test showed sufficient blood levels of supplemented vitamins in addition to normal coagulation profile.

## Discussion

Pericardial bleeding is a rare disorder that is often complicated by life-threatening cardiac tamponade. In the paediatric population, it was

reported in trauma, endocarditis, cardiac malformations, and tumours but no association to coagulation disorders have been described.<sup>7–9</sup> In adults, spontaneous haemopericardium has previously been reported in a small number of patients with haemophilia and vitamin K-antagonist therapy (e.g. warfarin),<sup>10–13</sup> conditions similar to vitamin K deficiency bleeding.

Vitamin K deficiency is a common cause of haemorrhage in neonates and young infants. The predominant manifestation of bleeding is intracranial, followed by gastrointestinal and umbilical affection.<sup>2,5</sup> To prevent complications, routine administration of vitamin K has been introduced widely. However, vitamin K deficiency bleeding still occurs in infants with unknown cholestasis on the basis of poor intestinal absorption, especially in those who are exclusively breastfed.<sup>3</sup>

The most common hereditary cause of neonatal cholestasis syndrome is  $\alpha$ -1-antitrypsin deficiency.<sup>6</sup> It has been associated with vitamin K deficiency bleeding in 75% of breastfed infants in a small study. Interestingly, the risk of vitamin K-dependent bleeding did not correlate with the degree of cholestasis in that cohort and no vitamin K deficiency bleeding was seen in partially formula-fed infants.<sup>4</sup>

Our patient was partially formula fed and received 2 mg vitamin K orally after birth, during the 1st week and after 7 weeks. However, despite prophylaxis and adequate nutrition, vitamin K deficiency bleeding developed due to  $\alpha$ -1-antitrypsin deficiency.

Spontaneous haemopericardium complicated by cardiac tamponade was a new and severe complication in this young infant that could successfully be managed with pericardiocentesis and replacement of coagulation factors and should therefore be considered and ruled out in young infants who present in poor clinical condition and acute anaemia.

## Lead author biography



Dr Christoph Bauer graduated from medical university of Graz, Austria in 2010. He completed his residency in Pediatric and Adolescent Medicine at the Kepler University Hospital. Currently, he is following his residency in Pediatric Cardiology at the Kepler University Hospital. His main research theme is Fontan failure in single ventricle patients.

## Supplementary material

Supplementary material is available at *European Heart Journal - Case Reports* online.

**Slide sets:** A fully edited slide set detailing this case and suitable for local presentation is available online as [Supplementary data](#).

**Consent:** The authors confirm that written consent for submission and publication of this case report including images and associated text has been obtained from the parents of the patient in line with COPE guidance.

**Conflict of interest:** none declared.

**Funding:** none declared.

## References

1. Shearer MJ. Vitamin K deficiency bleeding (VKDB) in early infancy. *Blood Rev* 2009;**23**:49–59.
2. Kries R, Göbel U. Vitamin K prophylaxis and vitamin K deficiency bleeding (VKDB) in early infancy. *Acta Paediatr* 1992;**81**:655–657.
3. Sankar MJ, Chandrasekaran A, Kumar P, Thukral A, Agarwal R, Paul VK. Vitamin K prophylaxis for prevention of vitamin K deficiency bleeding: a systematic review. *J Perinatol* 2016;**36**:S29–S35.
4. van Hasselt PM, Kok K, Vorselaars ADM, van Vlerken L, Nieuwenhuys E, de Koning TJ et al. Vitamin K deficiency bleeding in cholestatic infants with alpha-1-antitrypsin deficiency. *Arch Dis Child Fetal Neonatal Ed* 2009;**94**:F456–F460.
5. Sutor AH, Dagres N, Niederhoff H. Late form of vitamin K deficiency bleeding in Germany. *Klin Padiatr* 1995;**207**:89–97.
6. Fischler B, Lamireau T. Cholestasis in the newborn and infant. *Clin Res Hepatol Gastroenterol* 2014;**38**:263–267.
7. Çil E, Senkaya I, Tarım Ö. Delayed hemopericardium due to trivial chest trauma. *Cardiol Young* 1998;**8**:390–392.
8. Sugunan S, Krishnan ASA, Devakumar VK, Arif AK. Safety-pin induced hemopericardium and cardiac tamponade in an infant. *Indian Pediatr* 2018;**55**:521–522.
9. Pettersson G, Bergström T. A case of ruptured diverticulum of the left ventricle with hemopericardium in a neonate, treated successfully by surgery. *Scand J Thorac Cardiovasc Surg* 1969;**3**:203–206.
10. Jelani Q-U-A, Gordon R, Schussheim A. Dabigatran-induced spontaneous hemopericardium and cardiac tamponade. *Tex Heart Inst J* 2017;**44**:370–372.
11. Kızılırmak F, Gunes HM, Guler E, Demir GG, Karaca O, Canpolat HG. Hemopericardium and cardiac tamponade in a patient treated with dabigatran etexilate. *Korean Circ J* 2016;**46**:99–101.
12. Sajawal Ali M, Mba BI, Ciftci FD, Ali AS. Bleeding heart: a case of spontaneous hemopericardium and tamponade in a hyperthyroid patient on warfarin. *BMJ Case Rep* 2016;**2016**:bcr2016215731.
13. Ghosh N, Teefy P, Laudenbach L, Rivard G-E. Cardiac tamponade in a patient with moderate hemophilia A and factor VIII inhibitors. *Can J Cardiol* 2006;**22**:73–75.