

Lethal Malaria: Marchiafava and Bignami Were Right

Nicholas J. White,^{1,2} Gareth D. H. Turner,^{1,2} Nicholas P. J. Day,^{1,2} and Arjen M. Dondorp^{1,2}

¹Mahidol-Oxford Tropical Medicine Research Unit, Faculty of Tropical Medicine, Mahidol University, Bangkok, Thailand; and ²Centre for Tropical Medicine, Churchill Hospital, Oxford University, Oxford, United Kingdom

One hundred and twenty years ago, the Italian malariologists Marchiafava and Bignami proposed that the fundamental pathological process underlying lethal falciparum malaria was microvascular obstruction. Since then, several alternative hypotheses have been proposed. These formed the basis for adjunctive interventions, which have either been ineffective or harmful. Recent evidence strongly suggests that Marchiafava and Bignami were right.

Keywords. *P. falciparum*; malaria; cerebral malaria; pathology.

Now it seems to us that no other explanation of these facts can be given, except that which is based on the mechanical alterations in the circulation, of which we have spoken.

E. Marchiafava and A. Bignami [1]

Within a decade of Alphonse Laveran's discovery of the malaria parasite, the great malariologists and pathologists Ettore Marchiafava and Amico Bignami (Figure 1) and their Italian colleagues had observed the key pathological features of lethal malaria and deduced the pathophysiological processes that caused death. Marchiafava and Bignami published their classic monograph "*On Summer-Autumnal Fevers*" in 1892, and it was translated into English in 1894 [1]. Malaria was a major cause of illness and death in many parts of Italy at that time. The fatal cases they examined in the Ospedale Santo Spirito in Rome were often young "hale and

hearty" shepherds who had come down from the malaria-free Appenini high pastures and contracted the dangerous aestivo-autumnal fever in the malarious lowlands during the Transumanza. Malaria transmission then in the Campagna Romana was so intense that it was said that a stay of only 1 night was sufficient to guarantee malaria infection.


Marchiafava and Bignami conducted autopsies on fatal cases and examined the pathological material they obtained. Bolstered by the cellular definition provided by the newly discovered Romanowsky stains, their findings differed with Laveran on several important points. The Italian malariologists concluded that the malaria parasites were spherical in nature (rather than filamentous), mainly intraerythrocytic (rather than free living), that the liberation of "spores" at segmentation (schizont rupture) caused fever, and that there were different species of malaria parasites (each with its own different characteristics, notably fever periodicity). They observed that malignant malaria was caused only by the parasite species causing aestivo-autumnal malaria (which we now call *Plasmodium falciparum*). On pathological processes they disagreed with Laveran's suggestion that pigmented bodies caused thrombosis and with Frerich's earlier proposition that pigment accumulation and also "white coagula" caused microvascular blockage. Marchiafava and Bignami wrote that "their recent researches allow a different view to be taken of the mechanical theory of the cerebral symptoms in malignant infections"; they were of the opinion that the "endoglobular" shape of the accumulated

Received 17 September 2012; accepted 23 October 2012; electronically published 12 April 2013.

Correspondence: Professor Nicholas J. White FRS, Mahidol-Oxford Research Unit, Faculty of Tropical Medicine, Mahidol University, Bangkok 10400, Thailand (nickw@tropmedres.ac).

The Journal of Infectious Diseases 2013;208:192–8

© The Author 2013. Published by Oxford University Press on behalf of the Infectious Disease Society of America. This is an Open Access article distributed under the terms of the Creative Commons Attribution-NonCommercial-NoDerivs licence (<http://creativecommons.org/licenses/by-nc-nd/3.0/>), which permits non-commercial reproduction and distribution of the work, in any medium, provided the original work is not altered or transformed in any way, and that the work properly cited. For commercial re-use, please contact journals.permissions@oup.com. DOI: 10.1093/infdis/jit116



Ettore Marchiafava 1847-1935



Amico Bignami 1862-1929

Figure 1. Ettore Marchiafava (1847–1935) (left) and Amico Bignami (1862–1929) (right).

parasitized erythrocytes packing the small blood vessels provided a physical obstruction to the microcirculation. In 1900, Patrick Manson, based on his own pathological observations, wrote, “This crowding of the vessels of the brain with parasites affords ample explanation of many of the phenomena of that type of malaria known as pernicious cerebral malaria.” Manson P. Manual of the Diseases of Warm Climates. Cassell, London, 1900.

Marchiafava and Bignami had described the key pathological feature of sequestration. Malignant malaria was associated with extensive parasitized erythrocyte sequestration, an “exceptionally abundant quantity of parasitic forms, a quantity much more abundant—where the cases terminate fatally—in the blood of the viscera than in the blood of the finger.” [1] They noted that whereas the parasites that circulated were usually young unpigmented (ring) forms, the parasites that accumulated in the small blood vessels were mature, often pigmented, and located at the peripheries of the larger vessels (although they did not actually specify the cause of this margination as cytoadhesion to the vascular endothelium). In contrast, when blood vessels did break, the red cells that extravasated were mainly unparasitized, which suggested that the sequestered intravascular parasitized red cells were static and, therefore, retained. Marchiafava, Bignami, and their colleague Giuseppe Bastianelli observed that punctuate hemorrhages in fatal cerebral malaria were predominantly in the white matter of the brain, whereas sequestration was most noticeable in the cerebral gray matter. They also noted that retinal hemorrhages could occur in fatal falciparum malaria. Finding mature pigmented parasites in the peripheral blood smear was considered an ominous sign and, in patients who presented with uncomplicated infections, was a harbinger of clinical deterioration. The pathological consequence of parasitized erythrocyte sequestration in the brain was a rise in intracranial tension, with intense hyperemia, which resulted from “the accumulation in the cerebral vessels of red blood corpuscles loaded with amoebae.” [1] Critically, they noted that the degree of

sequestration varied considerably between different organs, was often marked in the brain, particularly in cerebral malaria, and was a particular feature of small as compared with large blood vessels: “From the point of view of the frequency of the forms of sporulation (the schizonts) the brain contains the largest number, then comes in order the lungs, the spleen, the osseous marrow, the liver, and the intestines; but in some cases the intestines have a greater quantity than the organs last mentioned.” [1] By contrast the crescent-shaped forms (the *P. falciparum* gametocytes) were more abundant in the spleen and bone marrow than the viscera.

The only effective specific antimalarial treatments available in the nineteenth century were the Cinchona alkaloids—in particular, quinine. Marchiafava and Bignami noted the varying resistance to quinine of the Italian aestivo-autumnal (*P. falciparum*) parasites, and they confirmed the work of Camillo Golgi, Guido Bacelli, and others that indicated that quinine acted predominantly on the mature trophozoites that were sequestered, but had relatively little effect on mature schizonts, young rings, or *P. falciparum* gametocytes. They were aware of the importance of the timing of their observations in relation to the evolving pathological processes, both with regard to the stage of the parasites’ development and microvascular obstruction and the hazards of considering together patients who died in the acute phase of the infection (cerebral microvasculature packed with erythrocytes containing mature forms of the parasites) versus those who died after several days of quinine treatment (residual intravascular pigment, which we now know is retained through cytoadherent membrane remnants, and few or no recognizable parasites). With regard to circulating soluble products (which today we might regard as proinflammatory cytokines) and toxic manifestations (from a malaria “toxin”) in cerebral malaria, they considered the evidence insufficient that these caused the disease manifestations and therefore that “the chemical theory of the cerebral symptoms cannot be maintained.” [1] Severe malaria was caused by “mechanical alterations in the circulation” [1] (ie, microvascular blockage or, literally, a traffic jam).

That research took just over 10 years. In the subsequent 120 years, there have been few further advances of substance in our understanding of malaria pathophysiology. The relatively small number of pathology studies that have been conducted have generally confirmed the histopathological observations described by the Italian school (Figure 2) [2–5].

Nevertheless malaria pathophysiology has been rich ground for the generation of hypotheses, although these have not led to improvements in the management of severe malaria. Malaria researchers have often been distracted by epiphenomena, and they have failed to falsify the hypotheses of Marchiafava and Bignami. Investigations into the roles of cerebral edema, disseminated intravascular coagulation, immunopathogenesis, hypovolemia, and systemic cytokine activation have all shown

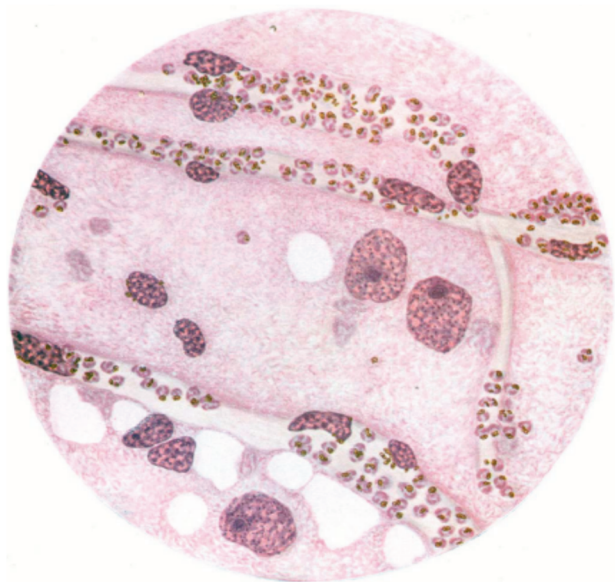


Figure 2. Drawing by Yap Loy Fong from Field’s classic text illustrating the cerebral microvasculature in a Chinese woman who died of cerebral malaria near Kuala Lumpur [31]. The blood vessels are packed with red cells containing mature stages of *Plasmodium falciparum*. Field stated that “it was not illogical to assume that anoxia from arrest of the capillary circulation may have been the cause of death.”

abnormalities but provided no convincing evidence that any of these phenomena are consistently and causally lethal, and they have not provided effective treatments. Numerous adjunctive treatments have been evaluated, often based on the fashionable hypotheses of the time, but none have proved effective; indeed the majority have proved harmful (Table 1). Pathology research on severe malaria has been dominated in recent years by studies of a murine model of cerebral malaria (*Plasmodium berghei* ANKA strain in CB57BL/6 or CBA mice), which has a fundamentally different pathology [6]. Of 34 adjuvant interventions assessed in the murine model, 31 proved very effective, whereas none of the adjuvant interventions assessed in human malaria have proved effective (Table 1) [6]. Meanwhile evidence supporting Marchiafava and Bignami’s original hypothesis explaining the lethal pathophysiology of severe falciparum malaria has steadily built.

Pathology studies in lethal malaria have confirmed that there is intense sequestration of parasitized erythrocytes in vital organs—notably the brain—and that sequestration varies between organs. Sequestration is also very uneven within an organ, with some vessels completely blocked while others close by remain patent [1–5, 7–11] (Figure 3). Ultrastructural studies show parasitized red cells adhering tightly via knob-like protrusions on their surface to the adjacent vascular endothelium (Figure 4), which immunohistochemical studies show is clearly activated [7–10]. The parasite-derived ligands (principally the variant red cell surface-expressed PfEMP1) and their vascular

Table 1. Interventions Evaluated in Severe Falciparum Malaria

Intervention	Result
Urea	No benefit
Aspirin	Harm
Heparin	Harm
Mannitol	Harm
Prostacyclin	No benefit
Corticosteroids	Harm
Plasmapheresis	No benefit
Pentoxifylline	No benefit (? ↑ mortality)
Desferrioxamine	Harm
Low-dose quinine	Harm
Anti-TNF antibody	Harm
Hyperimmune globulin	No benefit
High-dose phenobarbitone	Harm
Exchange blood transfusion	No benefit
Fluid loading	Harm
Albumin	Harm
Erythropoietin	Ongoing
Activated charcoal	Ongoing
L-arginine	Ongoing
Sevuparin	Ongoing
Levamisole	Ongoing
Artesunate	Reduced mortality by 35%

? Denotes uncertainty in the effect

Abbreviation: TNF, tumor necrosis factor.

receptors (CD36, ICAM1, CSA, etc) have been identified and characterized [12], and the adhesive forces that bind parasitized red cells to vascular endothelium (cytoadherence), uninfected red cells (rosetting), and infected red cells (agglutination) have been measured. In the brain, sequestered parasites in different vessels are found in groups at similar stages of their life cycle, suggesting asynchronous upregulation of the vascular adhesins (notably ICAM1) (Figure 5). Unparasitized red cell deformability is also reduced, further contributing to impaired microvascular perfusion and reducing red cell survival [13]. In fatal cases with premortem coma, there is more intense sequestration in the cerebral microvasculature than that observed in patients who remained conscious before death with other manifestations of severe malaria. Greater congestion within the cerebral microvessels is associated significantly with deeper levels of premortem coma and shorter times to death [14]. These findings argue strongly that microvascular obstruction is a key process in the genesis of coma and a cause of death from cerebral malaria.

Individual organ blood flows have been measured in severe malaria for the brain, liver, kidneys, and skeletal muscle and generally found to be either normal or relatively reduced in comparison with the high cardiac index and the low arterial oxygen content [15–18]. But whole-organ flows reflect a

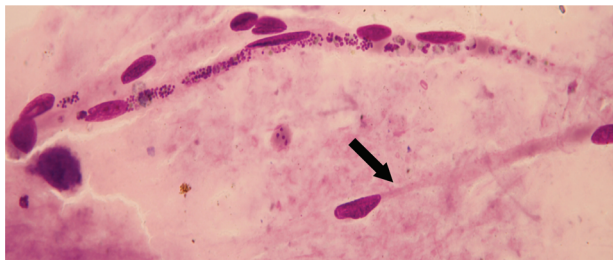


Figure 3. Post-mortem brain smear taken from a patient who died from cerebral malaria. Three capillaries are seen traversing the figure. There is 1 schizont in the upper capillary. The middle capillary shows intense sequestration and packing with schizonts on the left and mature trophozoites on the right. The lower capillary (arrow) contains no parasitized erythrocytes.

vascular summary and thus do not provide an accurate picture of microvascular flows, particularly if they are heterogeneous, because there may be low or no flow in blocked vessels and very high flow in unblocked vessels (Figure 3). Measures of systemic or organ-specific anaerobic glycolysis, such as lactate production, are more informative. Metabolic studies clearly demonstrate evidence of anaerobic glycolysis (lactate production, elevated lactate/pyruvate ratios) in direct proportion to the severity of illness (which is a different profile to the hypermetabolism observed in sepsis) [15–19]. These findings suggest extensive microvascular obstruction and consequently impaired perfusion [19].

Proof has come recently with techniques that allow visualization of the microcirculation *in vivo*. Reversible heterogeneous microvascular obstruction has been observed directly in the retinal, buccal, and rectal circulations in severe falciparum malaria [20–23]. The pattern observed *in vivo* mirrors exactly the process seen in the tissues examined from fatal cases. The degree of microvascular obstruction parallels clinical severity and known prognostic measures, such as plasma lactate and base deficit.

This is not to say that microvascular obstruction explains everything in severe malaria. Beyond ischemia, we do not know exactly how parasitized erythrocyte sequestration and the consequent microvascular obstruction lead to vital organ dysfunction and death. The pathogenesis of alterations in vascular permeability and transport functions remains unclear [24–26]. The pathology of sudden noncardiogenic pulmonary edema, acute renal failure, and anemia (both bone marrow dyserythropoiesis and accelerated unparasitized red cell destruction), all of which may cause death, is not explained satisfactorily by microvascular obstruction only. The continued activation of cerebral vascular endothelium by residual membranes and pigment (residual intravascular pigment was noted by Marchiafava and Bignami) and the discovery of interrupted axoplasmic transport

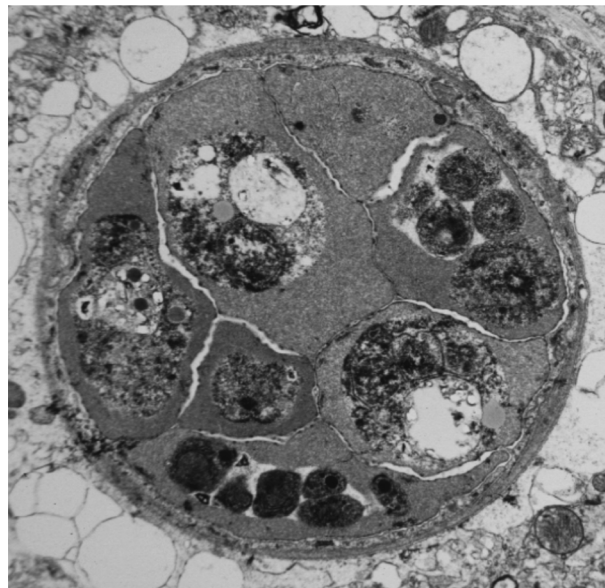


Figure 4. Cross-section electron micrograph showing a cerebral venule packed with erythrocytes containing mature stages of *Plasmodium falciparum* from a Thai patient who died from cerebral malaria [10]. Courtesy of E. Pongponratn.

provide plausible explanations for continued coma after clearance of the microvascular obstruction [27, 28]. Nevertheless the cellular pathogenesis underlying the rapidly reversible coma in cerebral malaria remains unknown, and the secondary consequences of cytoadhesion and microvascular obstruction on an active vascular endothelium and the underlying signaling to neurons and glial cells remain to be elucidated. It is also unclear how diffuse microvascular obstruction predisposes to residual neurological sequelae such as stroke and epilepsy [29, 30]. As regards “the chemical theory of the cerebral symptoms,” [1] no convincing toxin has been demonstrated, and, although concentrations of nearly every cytokine or mediator measured in severe malaria have either been high or low, there is no evidence that any of these are directly lethal.

Assessment of the sequestered parasite biomass *in vivo* in falciparum malaria has proved difficult, but here there has been some progress. The widely used peripheral blood malaria parasite count quantitates the relatively nonpathogenic circulating parasites in falciparum malaria, not the pathological sequestered forms [31, 32]. As a result, the predictive value of the total parasite count as a measure of disease severity is poor. It is common to see African children with uncomplicated malaria in endemic areas with high parasite densities similar to those in patients with severe malaria. Augmented splenic clearance in these semi-immune children may reduce the proportion of these parasites that sequester in vital organs. The prognostic value of the peripheral blood film in hospitalized patients can be improved by assessing the stage of parasite development. A predominance of

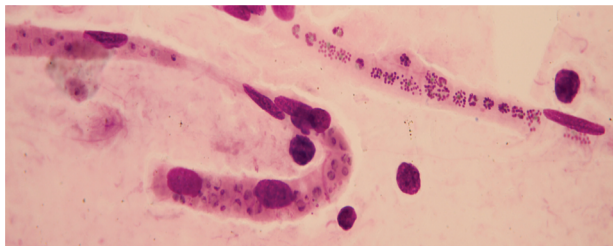


Figure 5. In fatal cerebral malaria, sequestered *Plasmodium falciparum* parasites are usually of similar stage of development within a vessel segment but differ in stage between vessels, indicating temporal differences between vessels in the upregulation of the vascular ligands. The upper vessel is packed with late schizonts, whereas the lower venule is packed with mature trophozoites. Courtesy of K. Silamut.

very young parasites makes a greater number of sequestered forms from the preceding asexual parasite cycle very unlikely, whereas if many peripheral parasites are mature and already contain visible malaria pigment, then it is increasingly likely that they represent the tip of a much larger iceberg of already sequestered parasites from the same asexual cycle [32]. Recently, parasite biomass has been estimated from in vivo models based on measurement of plasma concentrations of PfHRP2 [33–35]. This parasite protein is produced during the asexual life cycle, and then the majority is liberated at schizont rupture, but it is cleared from the circulation relatively slowly. Parasitized biomass estimates provided by the model are plausible and correlate much better than parasitemia with subsequent prognosis [33–34]. These data suggest that the lethal parasite biomass on average in a 60-kg adult is approximately 270 mL ($=3.4 \times 10^{12} \times 80$ fL) of parasitized red cells (Figure 6). This has direct effects on organ pathology. In the brain, for instance, where 10%–20% of the total biomass may be sequestered at death from cerebral malaria, this would represent an approximate intravascular volume of 50 mL, which is certainly enough to cause significant cerebral swelling independently of any vasogenic oedema [9–11, 13, 14, 36].

Recent very large randomized controlled trials that compared artesunate with quinine in adults and children with severe falciparum malaria [37, 38] also provide evidence supportive of a direct relationship between the sequestered parasite biomass and outcome. The main pharmacodynamic benefit of artesunate over quinine is that it kills young ring-stage parasites, whereas, as Marchiafava and Bignami correctly noted [1], quinine does not. Both antimalarial drugs have similar effects on sequestered trophozoites. As a result, artesunate prevents sequestration, whereas quinine does not [39]. In the SEAQUAMAT study conducted in 1461 Asian patients (mainly adults) [37], artesunate reduced the mortality of severe malaria by 35% compared with quinine. In the subsequent AQUAMAT study [38] conducted in 5425 African children, artesunate reduced mortality by 22.5%. Further analysis of the factors contributing to

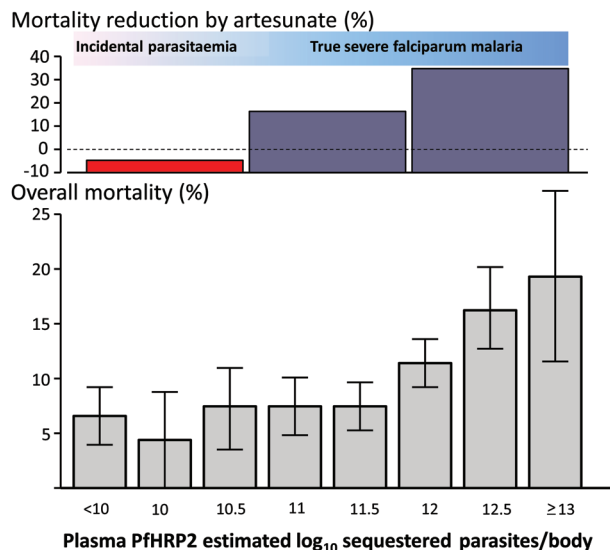


Figure 6. The AQUAMAT trial was an open randomized comparison between parenteral artesunate and quinine in 5425 African children with severe malaria [38]. The lower panel shows the relationship between mortality (%) in the AQUAMAT trial and the estimated number of malaria parasites sequestered, derived from a model based upon measurement of PfHRP2 in plasma [34]. The error bars are the 95% confidence intervals for the mortality proportion. The upper panel shows the treatment effect (mortality difference: %) in the lower, middle, and upper tertiles of plasma PfHRP2 concentrations. These data show that deaths in patients with low numbers of sequestered parasites are not prevented by artesunate, which suggests that these fatalities were probably caused partly by a disease process other than malaria (most likely sepsis).

the life-saving effect of artesunate in the Asian study showed that the therapeutic benefit derived mainly from lives saved in patients with high parasitemias with a predominance of young ring stages [37]. This was interpreted as showing that, by preventing further sequestration, artesunate saved one-third of the patients with severe malaria who would have died had sequestration continued.

But why then was the life-saving effect of artesunate in African children not the same as that in Asian adults and children? There are certainly differences in the pattern of vital organ dysfunction between adults and children with severe malaria. Children are more likely to present with severe anemia, whereas acute renal failure is more common in adults. Although parasitized red cell sequestration is the key autopsy finding in fatal cerebral malaria in African children and Asian adults, there are some differences between the two groups in the amounts of leukocyte and platelet accumulation [7, 9–13, 25, 28]. It has also been suggested that there are major pathophysiological differences between severe malaria in African children and in nonimmune children and adults that could affect therapeutic responses [40]. But there is another more prosaic

possibility, and that is misdiagnosis. In contrast with low-transmission settings, such as the majority of Asia, the diagnosis of severe malaria in African children is difficult. Transmission is higher, so the prevalence of parasitemia in the community is often high. As a consequence, many children with sepsis or other severe febrile illnesses present with an incidental positive parasitemia on blood slide or rapid test, and they are misdiagnosed as having severe malaria [41–45]. This has weakened clinical studies, confounded comparisons with adult severe malaria, and confused pathological and pathophysiological assessments. Furthermore, concomitant bacterial septicemia in “true” severe malaria, particularly with enteric organisms, is definitely more common in children in high-transmission settings than in children and adults in lower-transmission settings [41–44]. Although recent neuropathology studies do show some differences in microvascular pathology between Thai and Vietnamese adults and Malawian children who died of cerebral malaria, these differences are overshadowed by the pathological similarities, notably the unique process of extensive microvascular parasitized erythrocyte sequestration in patients who died in the acute phase of the disease [7, 9–13, 25, 28, 45]. Skilled ophthalmological assessments and PfHRP2 model estimates of the parasite biomass now allow better distinction of “true” severe malaria from severe febrile illness with incidental malaria [20–23]. In those African children who had the highest tertile of plasma PfHRP2 concentrations in the AQUAMAT study, and thus were most likely to represent “true” severe malaria, artesunate reduced mortality by 35% [34], which is exactly the same amount as in adults and children in the SEAQUAMAT study [38]. In contrast, in the lowest tertile of plasma PfHRP2 concentrations, in which children were more likely to have a “nonmalaria” cause of severe illness, there was no difference in outcomes between artesunate and quinine recipients [34] (Figure 6). The one-third lower overall survival benefit in the AQUAMAT study in Africa [38] compared with the SEAQUAMAT study in Asia is therefore probably explained in part by dilution of patients who died from severe malaria in Africa with patients with incidental parasitemia who died from another cause (such as sepsis). This argues that the quantitative relationship between lethal pathological processes and parasitized erythrocyte sequestration is similar in Asian adults and African children.

There is still much to learn about the pathophysiology of lethal malaria, but the cumulative weight of pathological data and these consistent recent *in vivo* observations in adults and children lead us to an inescapable conclusion: Marchiafava and Bignami were right.

Notes

Acknowledgments. We are very grateful to our many colleagues in Asia and Africa who have contributed to these studies and particularly to Ilse

Hendriksen for the PfHRP2 data and to Kamolrat Silamut for the brain smears.

Financial support. We are supported by the Wellcome Trust as part of the Wellcome Trust–Mahidol University–Oxford Tropical Medicine Research Programme.

Potential conflicts of interest. All authors: No reported conflicts.

All authors have submitted the ICMJE Form for Disclosure of Potential Conflicts of Interest. Conflicts that the editors consider relevant to the content of the manuscript have been disclosed.

References

1. Marchiafava E, Bignami A. On summer-autumn malarial fevers. In: Marchiafava E, ed. Two monographs on malaria and the parasites of malarial fevers (translated from the first Italian edition by JH Thompson). London: New Sydenham Society, 1894:1–232.
2. Dudgeon LS, Clarke C. An investigation on fatal cases of pernicious malaria caused by *Plasmodium falciparum* in Macedonia. *Q J Med* 1918; 12:372–90.
3. Gaskell JF, Millar WL. Studies on malignant malaria in Macedonia. *Q J Med* 1920; 13:381–426.
4. Kean BH, Smith JA. Death due to aestivo-autumnal malaria. A resume of one hundred autopsy cases 1925–1942. *Am J Trop Med Hyg* 1944; 24:317–22.
5. Spitz S. Pathology of acute falciparum malaria. *Milit Med* 1946; 99:555–72.
6. White NJ, Turner GD, Medana IM, Dondorp AM, Day NP. The murine cerebral malaria phenomenon. *Trends Parasitol* 2010; 26:11–5.
7. MacPherson GG, Warrell MJ, White NJ, Looareesuwan S, Warrell DA. Human cerebral malaria. A quantitative ultrastructural analysis of parasitized erythrocyte sequestration. *Am J Pathol* 1985; 119:385–401.
8. Nguansangiam S, Day NPJ, Hien TT, et al. A quantitative ultrastructural study of renal pathology in fatal *P. falciparum* malaria. *Trop Med Int Health* 2007; 12:1037–50.
9. Pongponratn E, Riganti M, Punpoowong B, Aikawa M. Microvascular sequestration of parasitized erythrocytes in human falciparum malaria—a pathological study. *Am J Trop Med Hyg* 1991; 44:168–75.
10. Pongponratn E, Turner GDH, Day NPJ, et al. An ultrastructural study of the brain in fatal falciparum malaria. *Am J Trop Med Hyg* 2003; 69:345–59.
11. Silamut K, Phu NH, Whitty C, et al. A quantitative analysis of the microvascular sequestration of malaria parasites in the human brain. *Am J Pathol* 1999; 155:395–410.
12. Milner DA Jr. Rethinking cerebral malaria pathology. *Curr Opin Infect Dis* 2010; 23:456–63.
13. Dondorp AM, Pongponratn E, White NJ. Reduced microcirculatory flow in severe falciparum malaria: pathophysiology and electron-microscopic pathology. *Acta Trop* 2004; 89:309–17.
14. Ponsford MJ, Medana IM, Prapansilp P, et al. Sequestration and microvascular congestion are associated with coma in human cerebral malaria. *J Infect Dis* 2012; 205:663–71.
15. Warrell DA, White NJ, Veall N, et al. Cerebral anaerobic glycolysis and reduced cerebral oxygen transport in human cerebral malaria. *Lancet* 1988; 2:534–8.
16. Pukrittayakamee S, White NJ, Davis TME, et al. Hepatic blood flow and metabolism in severe falciparum malaria: clearance of intravenously administered galactose. *Clin Sci* 1992; 82:63–70.
17. Krishna S, Supanaranond W, Pukrittayakamee S, et al. Dichloroacetate for lactic acidosis in severe malaria: a pharmacokinetic and pharmacodynamic assessment. *Metabolism* 1994; 43:974–81.
18. Day NP, Phu NH, Mai NT, et al. Effects of dopamine and epinephrine infusions on renal hemodynamics in severe malaria and severe sepsis. *Crit Care Med* 2000; 28:1353–62.
19. Day NP, Phu NH, Mai NT, et al. The pathophysiologic and prognostic significance of acidosis in severe adult malaria. *Crit Care Med* 2000; 28:1833–40.

20. Beare NA, Taylor TE, Harding SP, Lewallen S, Molyneux ME. Malarial retinopathy: a newly established diagnostic sign in severe malaria. *Am J Trop Med Hyg* **2006**; 75:790–7.
21. Dondorp AM, Ince C, Charunwatthana P, et al. Direct in vivo assessment of microcirculatory dysfunction in severe falciparum malaria. *J Infect Dis* **2008**; 197:79–84.
22. Beare NA, Harding SP, Taylor TE, Lewallen S, Molyneux ME. Perfusion abnormalities in children with cerebral malaria and malarial retinopathy. *J Infect Dis* **2009**; 199:263–71.
23. Abu Sayeed A, Maude RJ, Hasan MU, et al. Malarial retinopathy in Bangladeshi adults. *Am J Trop Med Hyg* **2011**; 84:141–7.
24. Potchen MJ, Kampondeni SD, Seydel KB, et al. Acute brain MRI findings in 120 Malawian children with cerebral malaria: new insights into an ancient disease. *Am J Neuroradiol* **2012**; 33:1740–6.
25. Grau GE, Craig AG. Cerebral malaria pathogenesis: revisiting parasite and host contributions. *Future Microbiol* **2012**; 7:291–302.
26. Medana IM, Turner GD. *Plasmodium falciparum* and the blood-brain barrier—contacts and consequences. *J Infect Dis* **2007**; 195:921–3.
27. Medana IM, Day NP, Hien TT, et al. Axonal injury in cerebral malaria. *Am J Pathol* **2002**; 160:655–66.
28. Dorovini-Zis K, Schmidt K, Huynh H, et al. The neuropathology of fatal cerebral malaria in Malawian children. *Am J Pathol* **2011**; 178:2146–58.
29. Brewster DR, Kwiatkowski D, White NJ. Neurological sequelae of cerebral malaria in children. *Lancet* **1990**; 336:1039–43.
30. Birbeck GL, Molyneux ME, Kaplan PW, et al. Blantyre Malaria Project Epilepsy Study (BMPES) of neurological outcomes in retinopathy-positive paediatric cerebral malaria survivors: a prospective cohort study. *Lancet Neurol* **2010**; 9:1173–81.
31. Field JW, Shute PG. The microscopic diagnosis of human malaria. II. A morphological study of the erythrocytic parasites. Studies from the Institute for Medical Research. No. 24 Federation of Malaya, Kuala Lumpur, 1956.
32. Silamut K, White NJ. Relation of the stage of parasite development in the peripheral blood to prognosis in severe falciparum malaria. *Trans R Soc Trop Med Hyg* **1993**; 87:436–43.
33. Dondorp AM, Desakorn V, Pongtavornpinyo W, et al. Estimation of the total parasite biomass in acute falciparum malaria from plasma PfHRP2. *PLoS Med* **2005**; 2:e204.
34. Hendriksen ICE, Mwanga-Amumpaire J, von Seidlein L, et al. Diagnosing severe falciparum malaria in parasitaemic African children; a prospective evaluation of plasma PfHRP2 measurement. *PLoS Med* **2012**; 9:e1001297.
35. Seydel KB, Fox LL, Glover SJ, et al. Plasma concentrations of parasite histidine-rich protein 2 distinguish between retinopathy-positive and retinopathy-negative cerebral malaria in Malawian children. *J Infect Dis* **2012**; 206:309–18.
36. Medana IM, Day NPJ, Sachanonta N, et al. Cerebral oedema in fatal adult human malaria is not associated with coma. *Malaria J* **2011**; 10:e267.
37. Dondorp A, Nosten F, Stepniewska K, Day N, White NJ; for the South East Asian Quinine Artesunate Malaria Trial (SEAQUAMAT) group. Artesunate versus quinine for treatment of severe falciparum malaria: a randomised trial. *Lancet* **2005**; 366:717–25.
38. Dondorp AM, Fanello CI, Hendriksen IC, et al. Artesunate versus quinine in the treatment of severe falciparum malaria in African children (AQUAMAT): an open-label, randomised trial. *Lancet* **2010**; 376:1647–57.
39. Udomsangpetch R, Pipitaporn B, Krishna S, et al. Antimalarial drugs reduce cytoadherence and rosetting *Plasmodium falciparum*. *J Infect Dis* **1996**; 173:691–8.
40. Mackintosh CL, Beeson JG, Marsh K. Clinical features and pathogenesis of severe malaria. *Trends Parasitol* **2004**; 20:597–603.
41. Mabey DC, Brown A, Greenwood BM. *Plasmodium falciparum* malaria and Salmonella infections in Gambian children. *J Infect Dis* **1987**; 155:1319–21.
42. Berkley JA, Lowe BS, Mwangi I, et al. Bacteraemia among children admitted to a rural hospital in Kenya. *N Engl J Med* **2005**; 352:39–47.
43. Were T, Davenport GC, Hittner JB, et al. Bacteremia in Kenyan children presenting with malaria. *J Clin Microbiol* **2011**; 49:671–6.
44. Mtove G, Amos B, Nadjm B, et al. Decreasing incidence of severe malaria and community-acquired bacteraemia among hospitalized children in Muheza, north-eastern Tanzania, 2006–2010. *Malar J* **2011**; 10:e320.
45. Taylor TE, Fu WJ, Carr RA, et al. Differentiating the pathologies of cerebral malaria by postmortem parasite counts. *Nat Med* **2004**; 10:143–5.