



Case report

A case of pneumococcal tricuspid endocarditis: An oslerian diagnosis



Francisco Machiavello Roman

Jacobi Medical Center, 1400 Pelham Parkway South, Bronx, NY, United States

ARTICLE INFO

Article history:

Received 13 April 2021

Received in revised form 7 May 2021

Accepted 7 May 2021

Keywords:

Streptococcus pneumoniae

Infective endocarditis

ABSTRACT

Streptococcal infections present in a variety of clinical syndromes. Invasive disease, such as infective endocarditis, was common in the pre-antibiotic era but is now seldom encountered. The author reports the case of an elderly man with pneumococcal tricuspid endocarditis presenting with fever and syncope, and reviews current literature regarding the epidemiology, clinical features and treatment of this condition.

© 2021 The Author(s). Published by Elsevier Ltd. This is an open access article under the CC BY-NC-ND license (<http://creativecommons.org/licenses/by-nc-nd/4.0/>).

Introduction

Streptococcus pneumoniae is one of the most common pathogens encountered in daily practice, usually as the etiologic agent of pneumonia, sinusitis, and otitis media [1]. Its spectrum of pathogenicity, however, is much broader. Clinical manifestations of pneumococcal invasive disease, such as bacteremia with endocarditis, were common before the advent of antimicrobial therapy and immunization but are now mostly limited to patients in the extremes of age or with comorbidities [2]. Although rare, these can be associated with significant morbidity. The following case describes the occurrence of pneumococcal endocarditis in an elderly patient and highlights the potential for invasive disease in pneumococcal infections.

Case

A 64-year-old man was admitted following a syncopal episode with associated cough and fever of 3-day duration. He was an active smoker and intranasal cocaine user with a remote history of pulmonary tuberculosis, hepatitis C virus (HCV) infection, and intravenous drug use. He had completed antituberculous therapy, and his HCV infection had remitted without evidence of chronic liver disease. His immunization status was unknown. His physical exam was positive for fever and a left parasternal systolic murmur without radiation. Auxiliary tests were remarkable for mild leukocytosis, azotemia and negative HIV serology. His chest X-ray was unremarkable, and ECG showed normal sinus rhythm. *Streptococcus pneumoniae* was isolated from 6/6 blood cultures drawn on admission and one day thereafter, with very low minimum inhibitory

concentration (MIC) for penicillin (E-test 0.023 µg/mL, AB Biodisk). A transthoracic echocardiogram (TTE) demonstrated a thickened and redundant septal leaflet of the tricuspid valve suggestive of vegetation (Fig. 1) along with moderate tricuspid regurgitation, hence fulfilling modified Duke criteria for the diagnosis of infective endocarditis (IE). A single right middle lobe paracardiac infiltrate demonstrated on chest CT was deemed the possible primary infection source. Ceftriaxone 2 g IV daily was started with the ensuing resolution of fever and bacteremia within 24 h of treatment. No embolic or immunologic phenomena were noted throughout his admission. Repeat ECGs continued to show normal sinus rhythm and a follow-up TTE after seven days of antimicrobial treatment revealed a decreased size of the vegetation without signs of intracardiac complications. The patient completed 28 days of IV ceftriaxone treatment and was discharged home; he was lost to follow-up.

Discussion

Streptococcus pneumoniae was a common etiologic agent of IE in the pre-antimicrobial era, with an estimated prevalence of 10–15% of all IE cases [3]. William Osler provided one of the earliest descriptions of pneumococcal IE in 1881 through post-mortem histological identification of “micrococci” in patients with the triad of pneumonia, meningitis, and endocarditis (then called “ulcerative endocarditis”). In 1957, Robert Austrian demonstrated that Osler’s micrococci were *Streptococcus pneumoniae*, and henceforth the Osler triad was renamed Austrian syndrome [3].

In the antimicrobial and immunization era, the prevalence of pneumococcal IE decreased to <3% of all cases. It is now a rare manifestation of invasive pneumococcal disease compared to pneumonia, bacteremia, or meningitis [3,4]. Multiple case series of pneumococcal IE have consistently reported that this entity is most common in middle-aged men without traditional risk

E-mail address: machiavf@nychhc.org (F. Machiavello Roman).

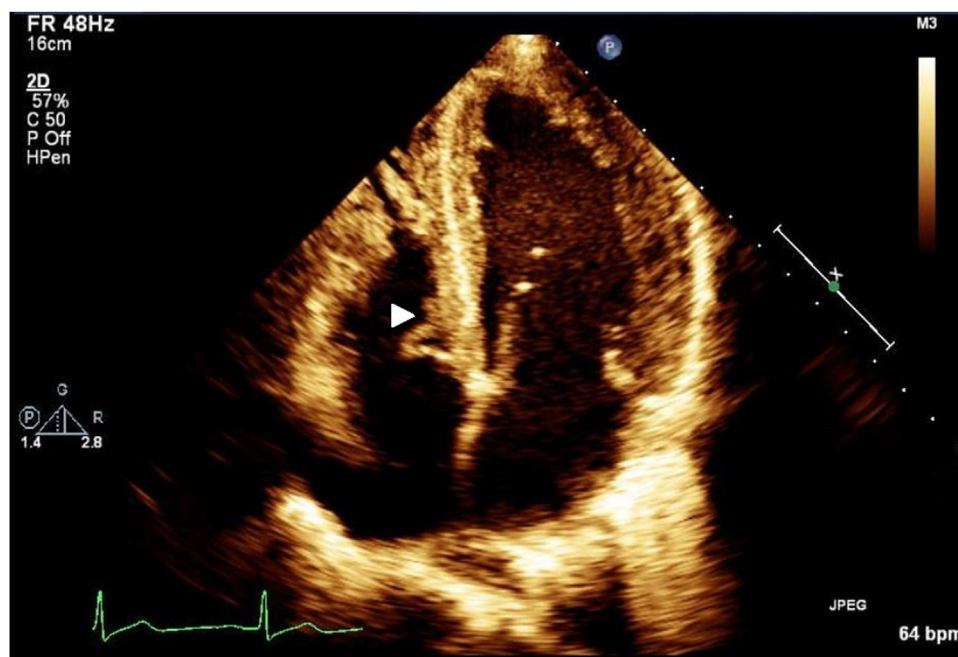


Fig. 1. Transthoracic echocardiogram, apical 4-chamber view. White arrow points to vegetation on the septal leaflet of the tricuspid valve.

factors for IE; alcoholism and smoking seem to be frequent comorbidities in this population [5,6]. The primary infection source is usually concomitant pneumonia, although a definite source is seldom identified [6]. The most frequent clinical manifestations are fever and a new murmur, as was this case. Unlike our patient, however, left-sided valves are predominantly affected, and there is a high risk for complications such as heart failure, shock, or septic emboli [5,7]. Intracardiac complications are common, usually requiring valvular surgery. Penicillin MICs are usually very low, which allows for treatment with penicillin or ceftriaxone, while some authors advocate for the synergistic combination with gentamicin [5].

The isolation of *S. pneumoniae* as the etiologic agent of IE was most unusual in this patient. He had no established risk factors for endocarditis other than remote IV drug use, as is the case in most patients with pneumococcal endocarditis. He responded adequately to single-drug antimicrobial therapy. The tricuspid valve compromise and lack of complications requiring surgical intervention set him apart from what has been described in the medical literature. This case underscores the pathogenicity of *S. pneumoniae* and its potential to re-emerge as a pathogen responsible for severe invasive disease.

Conflicts of interest

None.

Sources of funding

None.

Consent

Written informed consent was obtained from the patient for publication of this case report and accompanying images. A copy of the written consent is available for review by the Editor-in-Chief of this journal on request

Ethical approval

None.

Author contribution

Francisco Machiavello Roman: data collection, review of literature, manuscript redaction

CRediT authorship contribution statement

Francisco Machiavello Roman: Conceptualization, Investigation, Writing - original draft, Writing - review & editing.

Acknowledgments

The author would like to thank Gabriela Cedepa De Jesus, MD, and Rossana Roman Vargas, MD, for their invaluable support in preparing this manuscript.

References

- [1] Taylor SN, Sanders CV. Unusual manifestations of invasive pneumococcal infection. *Am J Med* 1999;107(July (1A)):125–275.
- [2] Backhaus E, Berg S, Andersson R, et al. Epidemiology of invasive pneumococcal infections: manifestations, incidence and case fatality rate correlated to age, gender and risk factors. *BMC Infect Dis* 2016;16(August):367.
- [3] Mandal AK, Mohamad B, Missouri CG. Lessons of the month 3: gone but not forgotten – osler – a reminder of the syndrome not bearing his name. *Clin Med (Lond)* 2019;19(6):523–5.
- [4] Marrie TJ, Tyrrell GJ, Majumdar SR, Eurich DT. Risk factors for pneumococcal endocarditis. *Eur J Clin Microbiol Infect Dis* 2018;37(2):277–80.
- [5] Daudin M, Tattlevin P, Lelong B, et al. Characteristics and prognosis of pneumococcal endocarditis: a case-control study. *Clin Microbiol Infect* 2016;22(572):e5–8.
- [6] Périer A, Puyade M, Revest M, et al. Prognosis of *Streptococcus pneumoniae* endocarditis in France, a multicenter observational study (2000–2015). *Int J Cardiol* 2019;288:102–6.
- [7] De Egea V, Muñoz P, Valerio M, et al. Characteristics and outcome of *Streptococcus pneumoniae* endocarditis in the XXI century. *Medicine (Baltimore)* 2015;94(39):e1562.