

# Use of Mobile Application as an Auxiliary Tool in the Preoperative Marking of Nipple-areola Complex Positioning in Mammoplasty

Gustavo Augusto Matos Saliba,  
MD\*†‡  
José Carlos Ribeiro Resende  
Alves, MD, PhD§¶

**Background:** Smartphones have the ability to benefit plastic surgeons in many ways. The aim of the study is to demonstrate that the use of a mobile application is a useful auxiliary tool for checking and eventual correction/adjustment of preoperative markings by plastic surgeons in mammoplasty.

**Methods:** The retrospective study was performed in a consecutive series of cases from July 2016 to October 2019. After preoperative marking, photographs were taken using the laser-level application (inclinometer, a leveling instrument), produced by Examobile, with an objective of verifying alignment deviations in preoperative marking. Some marking asymmetry related to the vertical height of the areolas was immediately corrected and a new photograph using the application was made for alignment checking.

**Results:** Ninety-three patients were included in the study. Comparatively, there was an increase in symmetry index around 28.6% of patients. The application of the Fisher and Chi-square tests evidenced statistical significance between the groups demonstrating the application as an auxiliary preoperative marking tool in relation to the symmetrical vertical positioning of the areolas.

**Conclusions:** The use of technology has become an important component of the way plastic surgeons train and practice. Today, there is a big gap between the desire for digital resources and awareness of the resources that are already available. By aggregating and evaluating current mobile applications available, surgeons, residents, and medical students will have more efficient ways to connect to the information that drives education and tactical surgery development. (*Plast Reconstr Surg Glob Open* 2021;9:e3942; doi: [10.1097/GOX.0000000000003942](https://doi.org/10.1097/GOX.0000000000003942); Published online 30 November 2021.)

## INTRODUCTION

The plastic surgeon, at some point during training, has heard the saying, “measure twice, cut once.” This wisdom emphasizes the importance of careful and accurate

preoperative planning. Surgical markings are a critical stage of a procedure, even when they occur outside the operating room.<sup>1</sup>

Masters of their art have modified and enhanced changes to produce consistent and reliable results. While there is often a systematic method to markings, experienced surgeons know how to make nuanced modifications to accommodate variations in patient anatomy and goals.<sup>1</sup>

There is no consensus on the best method for preoperative marking. Some authors defend freehand marking, which requires experience and practice to avoid postoperative asymmetries. Others use rulers and molds to assist in the preoperative markings.<sup>2</sup>

In 1955, Sir Harold Gillies, father of modern plastic surgery, claimed that photography was among one of the main advances in the specialty. The importance of photographic standardization has been valued in numerous publications.<sup>3</sup> Smartphones have immense capacity to

From the \*Hospital Semper, Plastic Surgery, Belo Horizonte, Minas Gerais, Brazil; †Hospitals Unimed Belo Horizonte e Betim, Plastic Surgery, Belo Horizonte, Minas Gerais, Brazil; ‡IMOP—Institute of Mastology, Dentistry and Plastic Surgery, Belo Horizonte, Minas Gerais, Brazil; §Felício Rocho Hospital, Plastic Surgery, Belo Horizonte, Minas Gerais, Brazil; and ¶Institute of Advanced Plastic Surgery, Plastic Surgery, Belo Horizonte, Minas Gerais, Brazil.

Received for publication June 15, 2021; accepted September 29, 2021.

Copyright © 2021 The Authors. Published by Wolters Kluwer Health, Inc. on behalf of The American Society of Plastic Surgeons. This is an open-access article distributed under the terms of the [Creative Commons Attribution-Non Commercial-No Derivatives License 4.0 \(CCBY-NC-ND\)](https://creativecommons.org/licenses/by-nc-nd/4.0/), where it is permissible to download and share the work provided it is properly cited. The work cannot be changed in any way or used commercially without permission from the journal.

DOI: [10.1097/GOX.0000000000003942](https://doi.org/10.1097/GOX.0000000000003942)

**Disclosure:** The authors have no financial interest to declare in relation to the content of this article.

benefit plastic surgeons. The large number of applications available, with more being created daily, contribute to the existing tools with great relevance and should not be overlooked.<sup>4,5</sup>

An inclinometer is a device used to measure the inclination of an angle. It has applicability in geological, civil, naval, aeronautical, and automobile engineering.

There is no description in the literature of the method used in the present study. Technology-savvy plastic surgeons can make the most of these applications to their advantage. Despite being used daily, smartphones and their applications are not exploited to their full potential.<sup>5</sup>

### OBJECTIVE

The objective is to demonstrate the use of the inclinometer as a useful auxiliary tool for the conference and eventual correction/adjustment of the preoperative marking in mammoplasty. This application is specific to assess

the vertical height of the areolas and the consequent pre and postoperative symmetry.

### METHODS

The retrospective study was carried out in a consecutive series of cases, from July 2016 to October 2019, at Vera Cruz hospital, with CEP approval and application of the informed consent term to all participants, respecting the principles of the Declaration of Helsinki.

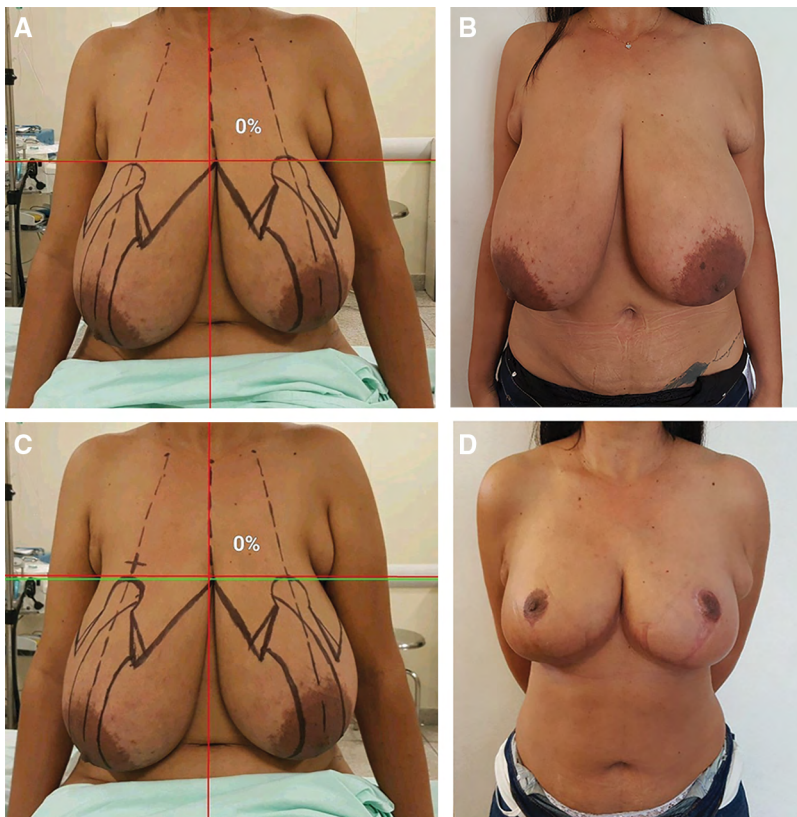
The patients included in the study were all those who underwent reduction mammoplasty and mastopexy with or without an implant. Group 1 (n = 68) did not use the digital inclinometer for preoperative marking. Group 2 (n = 25) was submitted to the application in the preoperative appointment.

Preoperative photographic documentation was performed in the office using a single digital camera (Samsung note 5, 16 megapixel, 4640 × 3480 resolution with digital stabilization) with standard distance. Surgical markings were made in the surgical theater, using a ruler and template described by Wise, in a seated position.

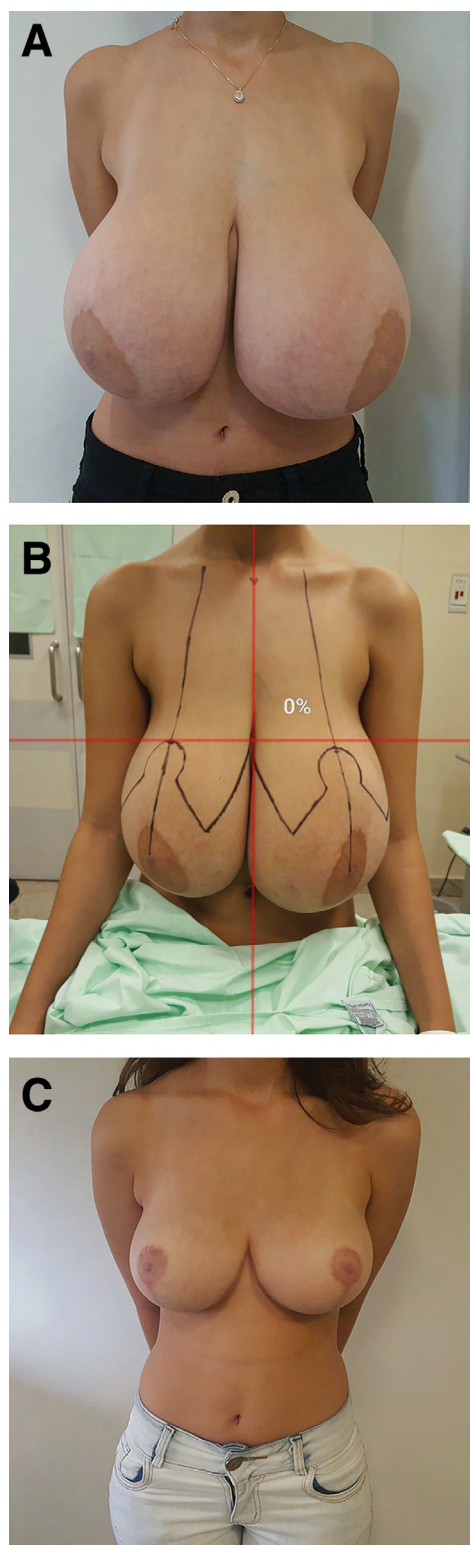
After preoperative marking, photographs were taken using the application “Laser Level” (inclinometer, an leveling instrument), produced by Examobile (Version 1.4.03.238), duly calibrated, with the objective of verifying alignment deviations in the preoperative markings. Evidence of some unevenness in the marking related to the vertical height of the areolas was immediately corrected and a new photograph using the application was taken to check the alignment correction (Figs. 1–4). The adjustment of the nipple-areola complex (NAC) in the operating room followed preoperative markings, without additional modifications. The app is not used in the operative room during the surgery.

Upon return of the patients, photographic documentation was carried out regularly, between 3 and 12 months. The mean duration of follow-up was 12 months.

The photographic results were evaluated by the main author to qualify them in terms of areolar unevenness. The unevenness or asymmetry was defined by a transverse line tangent to the upper pole of the areolas. Any deviation of this alignment was considered asymmetry and the opposite of this statement was defined as a symmetrical result. The Fisher and Chi-square tests were



**Fig. 1.** A 24-year-old patient with asymmetric bilateral gigantomastia, submitted to reduction mammoplasty through bipediculated areolar flap. A, Application showing asymmetric marking on the right side of the patient, at a lower level on the left. B, Asymmetric vertical height of the areolas in the preoperative period. C, Immediate correction with elevation of the mark on the right. D, Sixth postoperative month with satisfactory vertical areolar symmetry.



**Fig. 2.** A 15-year-old patient with asymmetric gigantomastia submitted to a reduction mammoplasty with supero-medial areolar flap. A, Preoperative photograph. B, Preoperative marking, using the application showing a marking error, submitted to immediate correction on the left side with elevation of the pre-operative marking. C, Photograph at 12 months postoperative showing satisfactory vertical areolar symmetry.

performed to verify the association of postoperative areolar symmetry with the use of the application in the preoperative period. The statistical analysis of the collected data was performed using IBM SPSS Statistics Version 2.0.

## RESULTS

The average age was 38 years (15–65 years). The mean body mass index was 25.59 (20–32.9). Reduction mammoplasty was performed in 25 patients, mastopexy with implant in 54, and mastopexy without implant in 14 patients.

Of the total number of patients,  $n = 75$  had asymmetrical areolar height in the preoperative period, that is, 80.6% of the patients. The mean distance between the sternal notch-NAC was 24.5 cm (19–33).

In group 2, 20 patients (80%) had symmetry of the areolar height and five patients (20%) had unevenness in the 3- to 12-month postoperative period. In group 1, 35 patients (51.40%) obtained adequate symmetry, whereas 33 (48.52%) showed unevenness.

Comparing the symmetric groups, the symmetry was higher in 28.6% of the cases in which the application was used. The application of the Fisher test and the chi-square test showed statistical significance between the groups, demonstrating the application as an auxiliary preoperative marking tool in relation to the symmetrical vertical positioning of the areolas (Table 1).

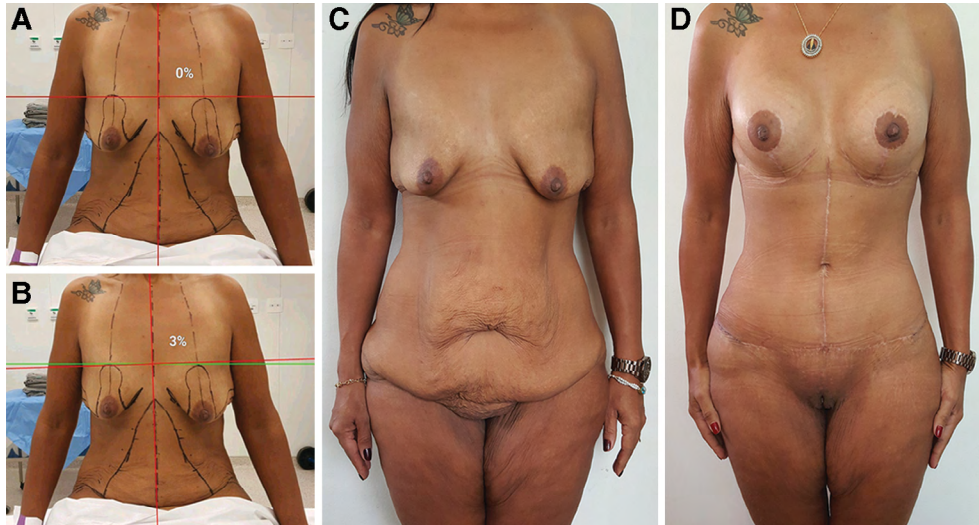
## DISCUSSION

The location of the NAC is of great importance, even if other breast characteristics such as size and shape are different.<sup>6–8</sup> The positioning of the NAC has a significant effect on the overall appearance of the female breast.<sup>9</sup> Recent studies using eye tracking technology show that the point of fixation of the initial look is the NAC. In addition, the greater time of capturing attention remains in this area of the breast when compared to other areas.<sup>10</sup>

An understanding of the most important variables in the perception of symmetry serves to improve postoperative results. Changes in the areolar diameter are detected more commonly than changes in the position and color of the NAC. A displacement of the NAC of 0.5–1.5 cm in the vertical direction is considered less aesthetic compared to a similar displacement in the horizontal direction.<sup>11,12</sup>

Although patients may not be aware of preoperative asymmetries, any postoperative asymmetry can be misinterpreted as a surgical error.<sup>13</sup> It must be emphasized that the absolute symmetry of the NAC may not be as important as the harmonious placement of the NAC within the limits of each breast at the point of maximum projection. The nipple should ideally accentuate the apical projection of the breast.<sup>7</sup> Although the previous statement is true, some patients persist with complaints of areolar asymmetry in the postoperative period, since visually the vertical symmetry of the areolas at the same





**Fig. 3.** A 40-year-old patient with breast asymmetry and unevenness in the vertical height of the areolas, submitted for mastopexy with a subglandular implant (270 cc, ultra-high profile). A, Preoperative marking using the application showing asymmetric marking on the left side of the patient is evident. B, Unevenness of approximately 3%. C–D, Photographs at preoperative and 12 months postoperative period showing satisfactory vertical NAC leveling.

level potentially harmonizes the self-image in addition to allowing the plastic surgeon to attempt a more accurate allocation of the NAC.

Smartphones are becoming ubiquitous in all aspects of our daily lives. With the potential to develop applications to meet any need, it is natural that they will find increasing use in the medical field. The increase in the number of articles on the subject in recent times proves their potential usefulness.<sup>5</sup>

Preoperative surgical marking has been reported since the beginning of plastic surgery, beginning with Sushruta Samhita's description of the use of plant leaves for the marking of nasal flaps, progressing over the centuries with the use of leather molds and wax, and reaching the most widespread use of incision designs made with paints and dyes from the 19th century onward.<sup>14</sup>

Although there may not be a single way to mark all patients, a tool with the potential to assist preoperative marking in mammoplasties was found in the present study, stimulating learning and discussion about how to improve surgical markings and, finally, results for patients (Board 1).

### BOARD 1: REGARDING THE APPLICATION AND THE SOCIAL IMPACT OF USING THIS APPLICATION

1. Prevention of inappropriate NAC height markings.
2. Fewer instruments used.
3. Shorter dismissal time in the pre and intraoperative period.

4. Facilitator in teaching surgical procedure in mammoplasty in accredited medical residency services.

It is the responsibility of the surgeon to ensure that any tool is used to promote progress and not for harmful purposes. This study highlights the benefits that the mobile application offers in overcoming potential risks.<sup>5</sup>

In short, smartphones and their applications can and will revolutionize the healthcare industry. Adopting the use of technology in a responsible manner can increase the efficiency of the surgeon, assist in teaching residents, reduce material costs and, ultimately, lead to a better outcome/result for the patient, which is the main source of happiness for the plastic surgeon.<sup>5</sup>

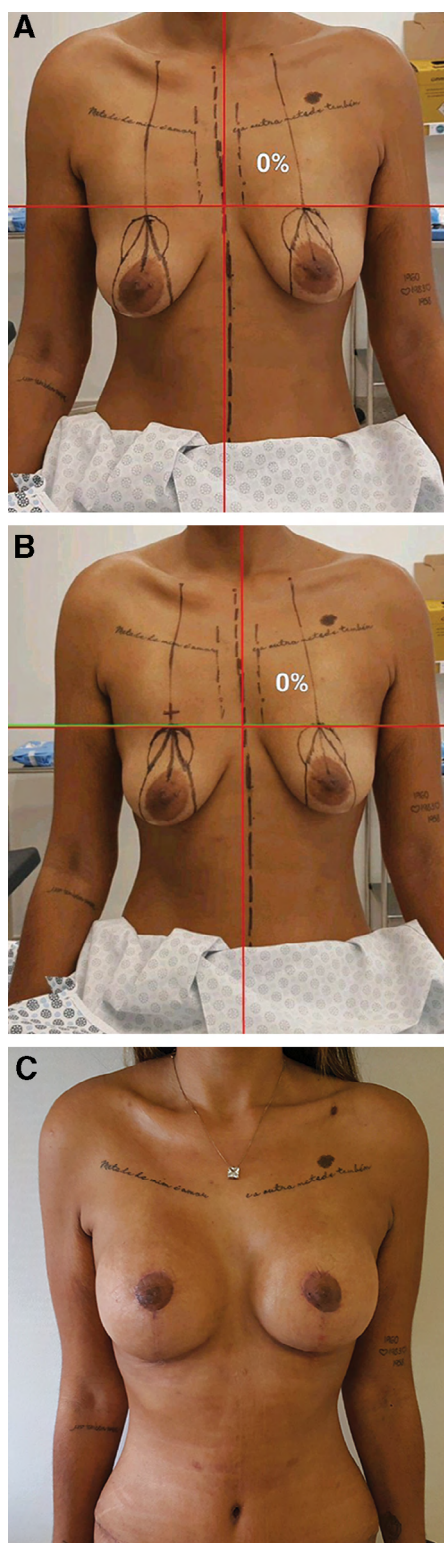
The use of technology has become an essential component of the way plastic surgeons train and practice. Currently, there is a big gap between the desire for digital resources and the awareness of the resources that are already available.

The data presented in the article point to the possibility of predicting results based on the definition of the future location of the areola, minimizing marking mistakes to which the human eye and brain are subjugated.

### CONCLUSION

The Examobile digital inclinometer proved to be a useful tool to correct asymmetries in preoperative marking, related to the height of the NAC in mammoplasty.

*Gustavo Augusto Matos Saliba*  
Hospital Semper, Plastic Surgery  
Belo Horizonte



**Fig. 4.** A 24-year-old patient with asymmetric breast and unevenness in the vertical height of the areolas submitted to subglandular mastopexy with implant (300 cc, ultra-high profile). A, Preoperative marking using the application. Asymmetry of marking on the right side of the patient is evident. B, Immediate correction with elevation of the mark on the right. C, Third postoperative month with satisfactory vertical areolar symmetry.

**Table 1. Distribution of Groups with and without the Use of Laser versus Groups with Postoperative Symmetry and Asymmetry**

	Results		
	Laser Level	No Laser Level	Total
Symmetry	20	35	55
Asymmetry	5	33	38
Total	25	68	93 (Grand Total)

Groups with postoperative symmetry and asymmetry. The chi-square statistic is 6,157. The *P* value is 0.013089. The Chi-square test with significance level lower than 0.05 ( $P < 0.05$ ). The Fisher exact test statistic value is 0.017. The Fisher test with level significance less than 0.05 ( $P < 0.05$ ).

Minas Gerais, Brazil

E-mail: [gustavo.saliba@cplastica.org.br](mailto:gustavo.saliba@cplastica.org.br); [salibagustavo@yahoo.com.br](mailto:salibagustavo@yahoo.com.br)

## REFERENCES

1. Qureshi AA. Surgical markings: measure twice, cut once. *Aesthetic Surg J*. Available at: <https://academic.oup.com/asj/pages/surgical-markings-measure-twice-cut-once>. Accessed November 26, 2019.
2. Barbosa MV, Nahas FX, Neto MA, et al. Keyhole pattern for preoperative marking for reduction mammoplasty. *Can J Plast Surg*. 2010;18:130–134.
3. Denadai R, Suguimoto A, Ghizoni E, et al. Formal training in standardized two-dimensional photographic documentation during residency in plastic surgery. *Rev Bras Cir Plást*. 2018;33:609–618.
4. Grow JN, Vargo J, Nazir N, et al. Smartphone applications in plastic surgery: a cross-sectional survey of 577 plastic surgeons, fellows, residents, and medical students. *Aesthet Surg J*. 2019;39:NP530–NP537.
5. Venkataram A, Ellur S, Kujur AR, et al. Smart apps for the smart plastic surgeon. *Indian J Plast Surg*. 2015;48:66–74.
6. Raveendran SS, El-ali K, Shibu M. Precision and symmetry in aesthetic plastic surgery “What Immortal hand or eye could frame thy fearful symmetry” (William Blake). *Aesth Plast Surg*. 2008;32:920–922.
7. Bishara A, Fadel C. Metrics of the aesthetically perfect breast. *Aesthetic Plast Surg*. 2018;42:1187–1194.
8. Brown MH, Semple JL, Neligan PC. Variables affecting symmetry of the nipple-areola complex. *Plast Reconstr Surg*. 1995;96:846–851.
9. Lewin R, Amoroso M, Plate N, et al. The aesthetically ideal position of the nipple – areola complex on the breast. *Aesthet Plast Surg*. 2016;40:724–732.
10. Pietruski P, Paskal W, Paskal AM, et al. Analysis of the visual perception of female breast aesthetics and symmetry: an eye-tracking study. *Plast Reconstr Surg*. 2019;144:1257–1266.
11. Brown MH, Semple JL, Neligan PC. Variables affecting symmetry of the nipple-areola complex. *Plast Reconstr Surg*. 1995;96:846–851.
12. Rohrich RJ, Hartley W, Brown S. Incidence of breast and chest wall asymmetry in breast augmentation: a retrospective analysis of 100 patients. *Plast Reconstr Surg*. 2006;118(7 Suppl):7S–13S; discussion 14S, 15S.
13. Cheema MH, Singh S. Modified pitanguy technique for intraoperative symmetrical localization of nipple – areola complex. *Aesth Plast Surg*. 2008;32:920–922.
14. Paiva SAA, Gomes HC, Nicodemo D, et al. Abdominoplasty marking instrument. *Rev Bras Cir Plást*. 2018;33:484–492.