


CASE REPORT

Scintigraphy false-positive results for cardiac amyloidosis in a patient with Danon disease

Dmitry Antukh¹  | Dmitry Shchekochikhin^{1,2} | Teona Rosina^{2,3} | Elena Mershina³ | Olga Larina³ | Sergey Pasha² | Elena Zaklyazminskaya^{2,3} | Valentin Sinitsyn³ | Sergey Moiseev^{2,3}

¹Pirogov Russian National Research Medical University, Moscow, Russia

²Sechenov University, Moscow, Russia

³Lomonosov Moscow State University, Moscow, Russia

Correspondence

Dmitry Antukh, Pirogov Russian National Research Medical University, Moscow, Russia.

Email: dimst@list.ru

Funding information

None

Abstract

Common diagnostic approach in patients with suspected cardiac amyloidosis includes cardiac magnetic resonance imaging and scintigraphy. We report the first clinical case of false-positive results of scintigraphy in a patient with Danon disease.

KEY WORDS

cardiac amyloidosis, Danon disease, hypertrophic cardiomyopathy

1 | INTRODUCTION

We report a clinical case of a patient who had a hypertrophic cardiomyopathy of unknown etiology. We used variety of tests among that were cardiac magnetic resonance imaging (CMR) and scintigraphy. CMR showed dubious results but scintigraphy was false-positive. As we know, there were no reports of scintigraphy false positive results indicating cardiac amyloidosis.

2 | CASE REPORT

A 23-year-old man presented with leg edema, ascites, shortness of breath, history of intermittent palpitations and syncope, mild proximal muscle weakness, and cognitive deficit. The patient reported that his mother died suddenly at the age of 22 years. Heart failure symptoms progressively worsened

from the age of 16 years. He was earlier diagnosed with asymmetric non-obstructive hypertrophic cardiomyopathy, WPW-syndrome, and complete left bundle-branch block. He used metoprolol 25 mg a day and irregularly torasemide without medical monitoring.

Laboratory tests revealed increased levels of creatine kinase, lactate dehydrogenase, aspartate aminotransferase, alanine aminotransferase, which was believed to be caused by myopathy. Other common laboratory tests were normal. Moreover, electromyography of the deltoid muscle showed the typical myopathic pattern.

Cardiac magnetic resonance imaging showed left and right ventricle hypertrophy (interventricular septum thickness of 24 mm), interventricular asynchrony, and dilation of the pulmonary arteries and the inferior vena cava (Figure 1). Late gadolinium enhancement (LGE) imaging showed early subendocardial LGE throughout all LV segments that is not typical for HCM and amyloidosis (Figure 2).

This is an open access article under the terms of the Creative Commons Attribution-NonCommercial-NoDerivs License, which permits use and distribution in any medium, provided the original work is properly cited, the use is non-commercial and no modifications or adaptations are made.

© 2021 The Authors. *Clinical Case Reports* published by John Wiley & Sons Ltd.

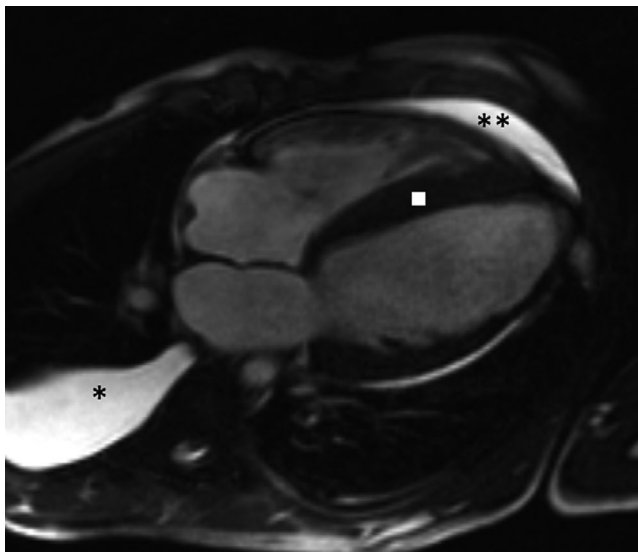


FIGURE 1 Cardiac magnetic resonance imaging four chamber view reveals myocardial hypertrophy up to 24 mm mostly in the interventricular segments (square), right side hydrothorax (asterisk), and mild pericardial effusion (two asterisks)

The definitive diagnosis was established after genetic tests. We found a frameshifting mutation in *LAMP2* gene which means that patient had Danon disease.

Unfortunately, there is no specific treatment available for this disorder. The patient received implantable cardioverter defibrillator considering the high risk of sudden cardiac death. Symptomatic treatment included furosemide and spironolactone.

3 | DISCUSSION

Genetic disorders including metabolic diseases are reported to account for up to 10% of all causes of hypertrophic cardiomyopathy.¹ It is easy to suspect one in cases like ours; however, definitive diagnosis may be difficult to establish.

Our patient had features of metabolic disease: young age, family history, proximal muscle involvement, and cognitive deficit. Interestingly, our patient had WPW-syndrome—another common feature of a storage disease.¹ Particularly, the

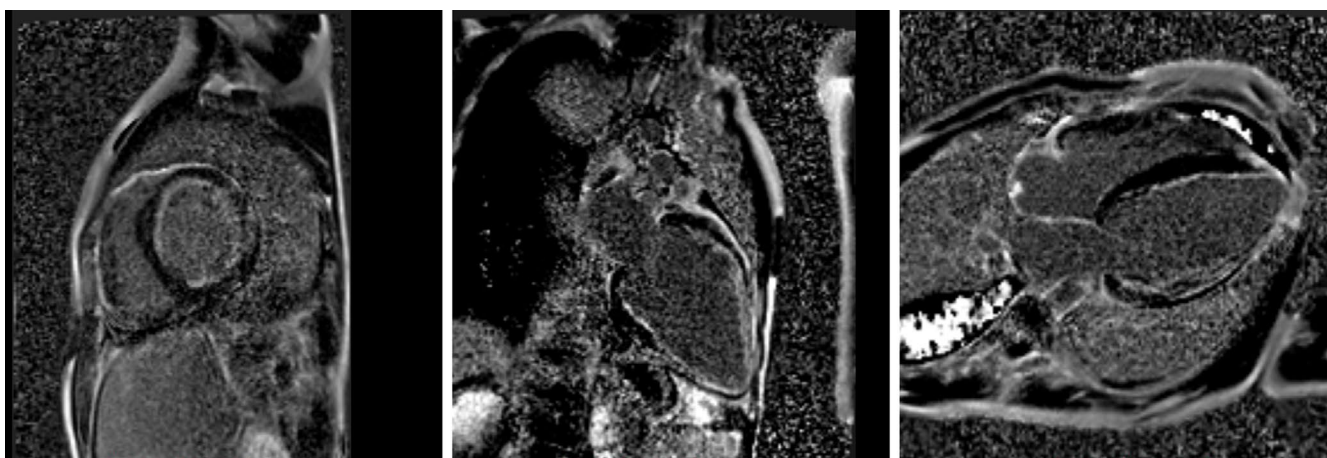


FIGURE 2 Post-contrast images demonstrate subendocardial LGE in all LV segments. This pattern of LGE is not typical for HCM and amyloidosis

Considering patient's young age, family history, and the absence of kidney involvement and polyneuropathy, the most probable diagnosis seemed to be a glycogen storage disease. ATTR amyloidosis was included in differential diagnosis.

Further, we performed scintigraphy and rectal mucosal biopsy. Bone tracer cardiac scintigraphy using ^{99m}Tc-labeled pyrophosphate showed cardiac uptake consistent with ATTR amyloidosis. However, amyloid deposits were not found in biopsy specimens. Heart muscle biopsy was not performed due to high perioperative risks.

whole picture was rather typical for a Danon disease. Danon disease is an X-linked dominant form of lysosome-associated membrane protein 2 (*LAMP2*) deficiency characterized by severe cardiomyopathy, mild skeletal myopathy, ophthalmic abnormalities, and variable intellectual disability.²

Interesting part of our case is that after dubious results of contrast enhance MRI, cardiac scintigraphy showed false-positive results indicating cardiac amyloidosis. It is important to note that these modalities are a part of a common diagnostic algorithm.³ To our knowledge, there were no reports of a case like ours. These modalities are believed to be highly

specific but one should remember of rare conditions which could mimic cardiac amyloidosis.

ACKNOWLEDGEMENTS

None.

CONFLICT OF INTEREST

None declared.

AUTHOR CONTRIBUTIONS

DA: wrote and revised manuscript. DS: wrote and revised manuscript. TR: revised manuscript. EM: revised manuscript and figure acquisition. OL revised manuscript and figure acquisition. SP: revised manuscript. EZ: revised manuscript. VS: revised manuscript. SM: revised manuscript.

ETHICAL APPROVAL

Written informed consent was obtained from the patient for the publication of this case report.

DATA AVAILABILITY STATEMENT

Authors confirm that all relevant data are included in the article and are available via open access platform of this journal.

ORCID

Dmitry Antukh  <https://orcid.org/0000-0002-1439-267X>

REFERENCES

1. Task A, Elliott PM, Uk C, et al. 2014 ESC guidelines on diagnosis and management of hypertrophic cardiomyopathy: the task force for the diagnosis and management of hypertrophic cardiomyopathy of the European society of cardiology (ESC). *Eur Heart J*. 2014;35(39):2733-2779. <https://doi.org/10.1093/eurheartj/ehu284>
2. Arad M, Maron BJ, Gorham JM, et al. Glycogen storage diseases presenting as hypertrophic cardiomyopathy. *N Engl J Med*. 2005;352(4):362-372. <https://doi.org/10.1056/NEJMoa033349>
3. Dorbala S, Ando Y, Bokhari S, et al. Expert consensus recommendations. *J Nucl Cardiol*. 2020;27:659-673. <https://doi.org/10.1007/s12350-019-01761-5>

How to cite this article: Antukh D, Shchekochikhin D, Rosina T, et al. Scintigraphy false-positive results for cardiac amyloidosis in a patient with Danon disease. *Clin Case Rep*. 2021;9:e04652. <https://doi.org/10.1002/ccr3.4652>