



## Intravitreal anti-vascular endothelial growth factor injections to treat post-trabeculectomy Swan syndrome

Silvia Feu-Basilio<sup>a,\*</sup>, Barbara Romero-Nuñez<sup>a</sup>, Néstor Ventura-Abreu<sup>a,b,1</sup>, Josep Torras-Sanvicens<sup>a,c</sup>, Marc Figueras-Roca<sup>a,c</sup>, Marta Pazos<sup>a,c</sup>

<sup>a</sup> Ophthalmology Institute, Hospital Clínic de Barcelona, Barcelona University (UB), Barcelona, Spain

<sup>b</sup> PhD Program, Instituto de Investigaciones Oftalmológicas Ramón Castroviejo, Department of Immunology, Ophthalmology and ORL, Faculty of Medicine, Complutense University of Madrid (UCM), Madrid, Spain

<sup>c</sup> Institut d'Investigacions Mèdiques August Pi i Sunyer (IDIBAPS), Barcelona, Spain

### ARTICLE INFO

#### Keywords:

Swan syndrome  
Trabeculectomy  
Wound neovascularization  
Anti-vascular endothelial growth factors

### ABSTRACT

**Purpose:** To report a case of wound neovascularization (Swan syndrome) one year after trabeculectomy favorably treated with two intravitreal ranibizumab injections.

**Observations:** A 79-year-old woman under coumadin treatment for atrial fibrillation experienced relapsing decreased vision in her left eye due to vitreous hemorrhage. She had had a past history of ocular hypertension corneal decompensation after phacoemulsification that required a Descemet Membrane Endothelial Keratoplasty and a subsequent trabeculectomy. After clearance of the hemorrhage, examination showed neovascularization not in the retina but surrounding the sclerostomy wound of the trabeculectomy, being diagnosed as a Swan syndrome. After two intravitreal injections of ranibizumab, gonioscopy showed complete resolution of the new vessels. No further recurrences have been reported and IOP has remained controlled without glaucomatous changes 7 months after the last injection. Clinical features and patient characteristics are described.

**Conclusion and importance:** Anti-vascular endothelial growth factor intravitreal injections may be a good and safe alternative to manage vitreous hemorrhage secondary to wound neovascularization of the trabeculectomy site.

### 1. Introduction

Intraocular hemorrhage, either affecting the anterior chamber or the vitreous cavity, is a late-onset complication of limbal or scleral incisions. First described by Swan,<sup>1</sup> it consists of recurrent intraocular bleeding months to years after an uncomplicated anterior segment surgery, due to abnormal wound neovascularization, visible under gonioscopy. The incidence of Swan syndrome has markedly decreased due to less extracapsular cataract extraction in favor of small-incision, clear cornea cataract surgeries,<sup>1–8</sup> although there have been some cases reported after glaucoma filtering procedures.<sup>8–10</sup>

Previous publications have described argon laser photocoagulation of the angle neovascularization as an effective treatment. However, in some patients recurrent bleeding can occur that can lead to angle closure and refractory glaucoma.<sup>8,11,12</sup> Moreover, the laser associated inflammation may potentially induce fibrosis and failure of the filtering bleb.

We describe a post-trabeculectomy Swan syndrome and its complete

remission without complications after two intravitreal injections of anti-vascular endothelial growth factor.

### 2. Case report

A 79-year-old woman with prior ocular history of phacoemulsification and Descemet membrane endothelial keratoplasty (DMEK) due to bullous keratopathy was followed in our Glaucoma Department due to steroid-induced secondary ocular hypertension which required further IOP control with an uneventful trabeculectomy performed 11 months later. One year after this last filtering procedure, she went to our Ophthalmology emergency department because of blurry vision in her left eye (OS). A month before, in another institution, she had been diagnosed with a vitreous hemorrhage that had resolved spontaneously in this same eye. She had a medical history of hypertension, dyslipidemia and rosacea and she was under treatment with acenocoumarin for atrial fibrillation. The patient did not suffer from diabetes or any other

\* Corresponding author. Institute of Ophthalmology. Hospital Clínic Barcelona. Sabino Arana s/n, Barcelona, Spain.

E-mail address: [SFEU@clinic.cat](mailto:SFEU@clinic.cat) (S. Feu-Basilio).

<sup>1</sup> Silvia Feu-Basilio & Néstor Ventura-Abreu equally contributed to the final version of this manuscript.

metabolic disease.

Her best corrected visual acuity (BCVA) was 20/50 in the OS. Slit lamp examination showed a diffuse, functioning filtering bleb, no corneal opacities, a nasally located, 2.5mm previous clear corneal incision, correct pseudophakia with in-the-bag intraocular lens and anterior chamber cells. Intraocular pressure (IOP) was 32 mmHg in the OS. Fundus examination of the OS showed an inferior vitreous hemorrhage. After complete clearance of the hemorrhage eleven days later, no retinal tears, wet age-related macular degeneration, diabetic retinopathy, retinal vein occlusion or any other vascular etiologies were found. The central corneal thickness was 479  $\mu\text{m}$ . The optic disc had a 0.5 cup to disc ratio with a subtle notch in the superior rim, and an average peripapillary retinal nerve fiber layer thickness (pRNFL) of 76  $\mu\text{m}$  in the Optical Coherence Tomography (OCT). When we further examined the anterior segment, gonioscopy revealed neovascularization in the rim of the sclerectomy (Swan sign) (Fig. 1A).

Considering the aforementioned signs, the patient was diagnosed with Swan Syndrome. A minimally invasive approach was preferred, and we opted for 0.5mg in 0.05 ml ranibizumab intravitreal injection (IVI) and topical antihypertensive medications (fixed combination brimonidine/timolol) in OS.

The patient was re-examined one month after the ranibizumab injection; at that time, angle neovascularization was absent (Fig. 1B), BCVA of the OS had improved to 20/32 and IOP had decreased to 18 mmHg, so glaucoma medication burden was reduced to brimonidine monotherapy in the left eye.

However, six days after this visit, the patient re-consulted the emergency department for sudden visual loss in the OS. BCVA had decreased to 20/40 and IOP was 21 mmHg in OS, after voluntary cessation of brimonidine tartrate. Anterior segment examination revealed new red blood cells in the anterior chamber. Similarly to the first episode, fundoscopic examination showed an attached retina without further details visualization due to the vitreous hemorrhage. Based on the previous diagnosis, re-examination of the iridocorneal angle showed remaining neovascularization now surrounding the iridectomy (Fig. 2A).

A second ranibizumab IVI in the OS was performed four days later – that is forty days after the first injection-without complications. Brimonidine tartrate was restarted in the OS due to IOP increase up to 21 mmHg. Due to the COVID-19 pandemic situation, the patient was followed telephonically for 4 months without new visual symptoms or complaints. On the successive face-to-face follow-up visits at our Glaucoma department, she was visually stable without changes in her optic disc appearance. Brimonidine tartrate was changed to latanoprost due to allergic conjunctivitis associated with the former treatment. The last visit was, to this date, 7 months after the last ranibizumab IVI. The patient maintained BCVA of 20/32, her IOP was 18 mmHg with latanoprost and there was no neovascularization in the gonioscopy (Fig. 2B).

### 3. Discussion

Swan syndrome is a rare, late-onset surgical complication that was first described by Kenneth C. Swan in 1973.<sup>1</sup> Frequently overlooked, it consists of recurrent intraocular bleeding months to years after an uncomplicated anterior segment surgery, due to abnormal vessels growth through the incisions.

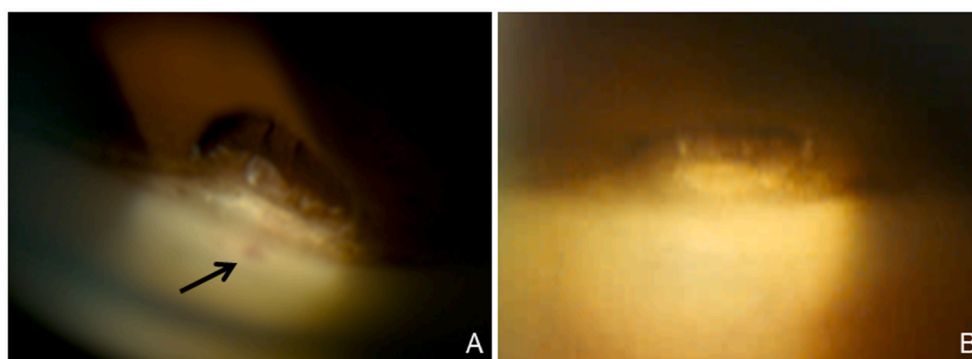
It should be considered in either pediatric or adult patients complaining of episodes of painless blurred vision who have a history of anterior segment surgery. Indeed, although it has mostly been reported after either intracapsular or extracapsular cataract surgery,<sup>1–8</sup> cases following glaucoma filtering procedures have also been described.<sup>8–10</sup>

Despite the fact that it typically presents within the first few years after surgery, a remote surgery should not exclude it. In fact, Watzke et al. described a patient with Swan syndrome that occurred 34 years after surgery.<sup>5</sup>

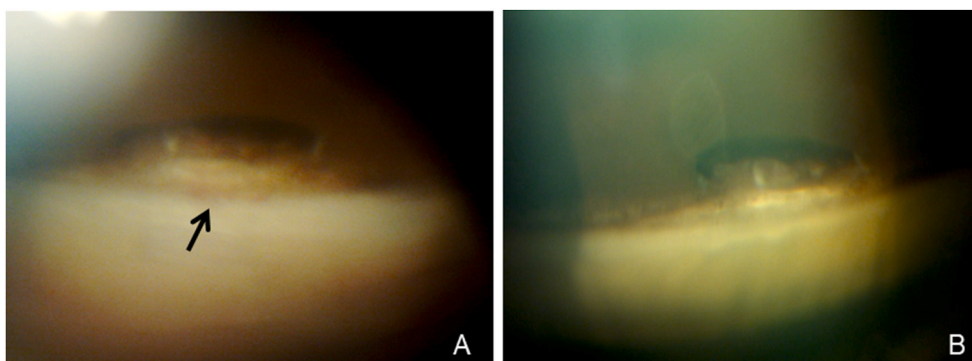
It is unclear what predisposes to Swan syndrome. Although there are only some case series published, several authors have suggested that the faulty wound closure and gaping of the inner edges of the wound may be contributing factors.<sup>1,6,8,11,13</sup> Additionally, it has been demonstrated that the limbal wounds healing process is associated with ingrowth of episcleral tissue and vessels,<sup>8</sup> likely due to poor wound apposition.<sup>1,3,7,8</sup> In fact, postmortem studies suggest that focal abnormal wound vascularization is not rare after a surgery involving scleral incisions.<sup>7</sup> These abnormal capillaries are exposed to the anterior chamber, and minor trauma or fluctuations of intravascular pressure may lead to episodes of bleeding that may take place more likely if the patient is anticoagulated, like in our case.<sup>8,12</sup> On the other hand, known systemic risk factors for other kinds of angle neovascularization like diabetes or arterial hypertension<sup>14,15</sup> may also play a role in this entity but have not been fully elucidated due to the rarity of this condition.

A careful dilated ophthalmoscopy examination should be performed to exclude other causes of vitreous hemorrhage, such as retinal tears, retinal neovascularization, trauma or Uveitis-Glaucoma-Hyphema syndrome. Gonioscopy ultimately provides diagnosis by revealing wound neovascularization, and rocking or manipulation of the gonioscopy lens may aid in the diagnosis by provoking bleeding.<sup>2</sup> Imaging techniques such as gonioscopy fluorescein angiography<sup>5</sup> or ultrabiomicroscopy 50–80 MHz<sup>10</sup> may be of help when visualization of neovascularization is not evident. In our case, gonioscopic visualization clearly showed neovascularization in the sclerostomy once the vitreous hemorrhage was fully reabsorbed.

Swan syndrome can present as a self-limited disease,<sup>10</sup> but there are also reported cases of recurrences after minimal trauma. In those cases, if left untreated, Swan syndrome can result in extensive synechiae, angle closure and refractory glaucoma.<sup>8,11,12</sup> In our case, none of these signs were found, although the patient showed an increased IOP in spite of an apparently normally functioning filtering bleb, probably due to partial blood cells blockage in the remaining trabecular meshwork and at the



**Fig. 1.** Results after one anti-VEGF IVI. Sclerectomy neovascularization (arrow) visible with gonioscopy (A) and their regression after a first ranibizumab IVI (B). VEGF: vascular endothelial growth factor; IVI: intravitreal injection.



**Fig. 2.** Results after a second anti-VEGF IVI. New neovascularization (arrow) surrounding the iridectomy (A) and their regression after a second ranibizumab IVI (B). VEGF: vascular endothelial growth factor; IVI: intravitreal injection.

subconjunctival area. Additionally, our patient was under treatment with acenocoumarin, which is known to facilitate bleeding in all organs, including the eye. Although the INR level of our patient was 2.14–2.52 at the time of the bleeding and recurrences (normal range 0.9–1.3 and in anticoagulated patients 2–3), cases of intraocular bleeding linked to warfarin therapy in eyes with predisposing abnormalities have been reported.<sup>16</sup>

There is no consensus regarding the best treatment for Swan syndrome. Although observation may be a reasonable option in self-limited intraocular bleeding, focal argon laser photocoagulation through a gonioscopy lens using retrobulbar anesthesia has been proposed as the treatment of choice in case of recurrent hemorrhages. Generally, short pulses with high intensity are used to blanch the abnormal blood vessels.<sup>3,5,11</sup> However, this treatment is only temporarily effective since episcleral vessels often regrow.<sup>5,8</sup> Furthermore, potential inflammation of the trabeculectomy site may lead to fibrosis and subsequent filtering bleb failure. Other treatment options include cryotherapy to the limbus at the neovascular site – although cystoid macular edema has been reported as a complication<sup>4,5,8</sup> –, or surgical reopening of the wound followed by diathermy or surgical excision of the blood vessels.<sup>1</sup>

In our case, the patient had already presented two episodes of vitreous hemorrhage in less than one month, so we decided to treat. Due to focal argon laser photocoagulation high recurrence rate and potential complications and the sight-threatening side effects of cryotherapy, these treatment options were dismissed as first-line therapy. A surgical approach was also discarded at this stage.

Lately, vascular endothelial growth factors (VEGF) inhibitors have been found to be clinically efficient in several conditions in which angle angiogenesis is involved, such as neovascular glaucoma.<sup>17</sup> They can be administered by direct anterior chamber injection (ACI) but also via IVI. Indeed, anti-VEGF have proven to reach the trabecular meshwork in less than 48 hours following IVI<sup>18</sup> and remission of neovascularization has been described for both administration routes.<sup>17,19–21</sup> Although Bhagat et al.<sup>21</sup> found the intracameral route of injection to be most effective in terms of IOP control in a subgroup of NVG patients, concerns about its safety have been raised. In fact, Akal et al.<sup>22</sup> showed that ACI may have local toxic effects in the corneal tissue. Moreover, ocular decompression retinopathy following intracameral bevacizumab injection has also been reported.<sup>23</sup>

Having all this in mind and considering their excellent safety profile and our center's large experience with intravitreal anti-VEGF, we decided to treat with a ranibizumab intravitreal injection. However, we believe that ACI may also have been a valid option, although further studies are needed to compare its efficiency and safety to that of IVI.

We opted for a different approach in the management of Swan syndrome with ranibizumab injections due to several reasons. First, anti-VEGF injections are a relatively safe, minimally invasive, and a very frequently used intraocular treatment that is available in nearly all ophthalmologic centers, and theoretically they may not preclude a

subsequent laser treatment if needed. Second, in contrast to laser photocoagulation, anti-VEGF injections do not seem potentially harming to the filtering bleb, as they have been widely used even intraoperatively in filtering surgeries, with a similar safety profile compared to antimetabolites.<sup>17,24</sup> Finally, as previously discussed, the use of anti-VEGF injections has proved to be effective in the management of other etiologies with anterior segment neovascularization, such as neovascular glaucoma.

After a first ranibizumab IVI, complete neovascular regression was observed and vision was stable for one month; however, another episode of vitreous hemorrhage occurred, and vascularization regrowth was observed but in a different area of the sclerostomy site. To address the recurrence of the bleeding, a second intravitreal injection was administered forty days after the first dose, without any further relapse throughout a follow-up period of seven months; however, the frequency and the total amount of intravitreal injections needed to avoid the recurrences completely is yet to be elucidated. Based on our early experience, we hypothesize that anti-VEGF IVI may be a good and less invasive alternative to successfully manage Swan syndrome after trabeculectomy, but that more than one intravitreal injection may be necessary.

#### 4. Conclusions

Although less frequent in the advent of micro-incisional surgeries, Swan syndrome should be suspected in recurrent anterior chamber or vitreous body bleeding in patients with prior history of anterior segment surgery, including trabeculectomy. Anti-VEGF intravitreal ranibizumab injections may be a safe and less-invasive treatment option that could prevent bleeding relapse and further major complications, such as angle closure or refractory glaucoma. Although further investigation is required, this case report shows promising results of antiangiogenic intravitreal injections as a favorable treatment for Swan syndrome with recurrent bleedings.

#### Patient consent

The patient consented to publication of the case in writing.

#### Funding

No funding was received for this work.

#### Intellectual property

We confirm that we have given due consideration to the protection of intellectual property associated with this work and that there are no impediments to publication, including the timing of publication, with respect to intellectual property. In so doing we confirm that we have

followed the regulations of our institutions concerning intellectual property.

### Research ethics

We further confirm that any aspect of the work covered in this manuscript that has involved human patients has been conducted with the ethical approval of all relevant bodies and that such approvals are acknowledged within the manuscript.

Written consent to publish potentially identifying information, such as details or the case and photographs, was obtained from the patient(s) or their legal guardian(s).

### Authorship

All authors attest that they meet the current ICMJE criteria for Authorship. The International Committee of Medical Journal Editors (ICMJE) recommends that authorship be based on the following four criteria:

1. Substantial contributions to the conception or design of the work; or the acquisition, analysis, or interpretation of data for the work; AND
2. Drafting the work or revising it critically for important intellectual content; AND
3. Final approval of the version to be published; AND
4. Agreement to be accountable for all aspects of the work in ensuring that questions related to the accuracy or integrity of any part of the work are appropriately investigated and resolved.

### Declaration of competing interest

We wish to confirm that there are no known conflicts of interest associated with this publication and there has been no significant financial support for this work that could have influenced its outcome.

### References

1. Swan KC. Hyphema due to wound vascularization after cataract extraction. *Arch Ophthalmol*. 1973;89(2):87–90.
2. Banitt MR, Rand A, Vann RR, Gedde SJ. Bilateral intraocular hemorrhage from vascularization of cataract wounds. *J Cataract Refract Surg*. 2009;35(9):1637–1639.
3. Bene C, Hutchins R, Kranias G. Cataract wound neovascularization: an often overlooked cause of vitreous hemorrhage. *Ophthalmology*. 1989;96(1):50–53.
4. Watzke RC. Intraocular hemorrhage from vascularization of the cataract incision. *Ophthalmology*. 1980;87(1):19–23.
5. Watzke RC. Intraocular hemorrhage from wound vascularization following cataract surgery. *Trans Am Ophthalmol Soc*. 1974;72:242–252.
6. Benson WE, Karp LA, Nichols CW, Crandall AS, Frayer WC. Late hyphema due to vascularization of the cataract wound. *Ann Ophthalmol*. 1978;10(8), 1109–1012.
7. Jarstad JS, Hardwig PW. Intraocular hemorrhage from wound neovascularization years after anterior segment surgery (Swan syndrome). *Can J Ophthalmol*. 1987;22(5):271–275.
8. Carrasquillo AM, Gupta BK, Wilensky JT. Recurrent hyphema in an aphakic child: Swan syndrome. *J AAPOS*. 2001;5(1):55–57.
9. Wilensky JT. Late hyphema after filtering surgery for glaucoma. *Ophthalmic Surg*. 1983;14(3):227–228.
10. Mannino G, Verrilli S, Calafiore S, et al. Evaluation of recurrent hyphema after trabeculectomy with ultrabiomicroscopy 50–80 MHz: a case report. *BMC Res Notes*. 2012;5(1):549.
11. Sharpe ED, Simmons RJ. Argon laser therapy of occult recurrent hyphema from anterior segment wound neovascularization. *Ophthalmic Surg*. 1986;17(5):283–285.
12. Swan KC. Late hyphema due to wound vascularization. *Trans Sect Ophthalmol Am Acad Ophthalmol Otolaryngol*. 1976;81(1):138–144.
13. Speakman JS. Recurrent hyphema after surgery. *Can J Ophthalmol*. 1975;10(3):299–304.
14. Rong AJ, Swaminathan SS, Vanner EA, et al. Predictors of neovascular glaucoma in central retinal vein occlusion. *Am J Ophthalmol*. 2019;204:62–69.
15. Rodrigues GB, Abe RY, Zangalli C, et al. Neovascular glaucoma: a review. *Int J Retin Vit*. 2016;2(1):26.
16. Greenfield DS, Liebmann JM, Ritch R. Hyphema associated with pupillary dilation in a patient with exfoliation glaucoma and warfarin therapy. *Am J Ophthalmol*. 1999;128(1):98–100.
17. Andrés-Guerrero V, Perucho-González L, García-Feijoo J, et al. Current perspectives on the use of anti-VEGF drugs as adjuvant therapy in glaucoma. *Adv Ther*. 2017;34(2):378–395.
18. Gal-Or O, Dotan A, Dachbash M, et al. Bevacizumab clearance through the iridocorneal angle following intravitreal injection in a rat model. *Exp Eye Res*. 2016;145:412–416.
19. Ungureanu E, Geamanu A, Popescu V, Dinu I, Grecescu M, Gradinaru S. Comparison between the efficacy and side effects of intravitreal versus anterior chamber Bevacizumab injection in neovascular glaucoma patients. *J Med Life*. 2014;7(4):68–70.
20. Lim TH, Bae SH, Cho YJ, Lee JH, Kim HK, Sohn YH. Concentration of vascular endothelial growth factor after intracameral bevacizumab injection in eyes with neovascular glaucoma. *Kor J Ophthalmol*. 2009;23(3):188–192.
21. Bhagat PR, Agrawal KU, Tandel D. Study of the effect of injection bevacizumab through various routes in neovascular glaucoma. *J Curr Glaucoma Pract*. 2016;10(2):39–48.
22. Akal A, Ulas T, Goncu T, et al. Evaluating the safety of intracameral bevacizumab application using oxidative stress and apoptotic parameters in corneal tissue. *Int J Ophthalmol*. 2015;8(4):697–702.
23. Reddy S, Doshi S, Pathengay A, Panchal B. Ocular decompression retinopathy following intracameral bevacizumab injection in a case of proliferative diabetic retinopathy with neovascular glaucoma. *Indian J Ophthalmol*. 2020;68(6):1206–1209.
24. Xiong Q, Li Z, Li Z, et al. Anti-VEGF agents with or without antimetabolites in trabeculectomy for glaucoma: a meta-analysis. *PLoS One*. 2014;9(2).