



# Thyroid Artery Embolization for Tracheostomy Site Bleeding: A Report of Three Cases

기관절개 부위 출혈에 대한 갑상선 동맥 색전술:  
3개 증례 보고

Suyoung Park, MD<sup>1</sup>, Jeong Ho Kim, MD<sup>1\*</sup>,  
Jung Han Hwang, MD<sup>1</sup>, Woo Sung Choi, MD<sup>2</sup>

Departments of <sup>1</sup>Radiology and <sup>2</sup>Emergency Medicine, Gil Medical Center, Gachon University College of Medicine, Incheon, Korea

Received December 29, 2023  
Revised March 15, 2024  
Accepted June 12, 2024  
Published Online September 25, 2024

**\*Corresponding author**

Jeong Ho Kim, MD  
Department of Radiology,  
Gil Medical Center,  
Gachon University College of Medicine,  
21 Namdong-daero 774beon-gil,  
Namdong-gu, Incheon 21565, Korea.

Tel 82-32-460-3063

Fax 82-32-460-3065

E-mail ho7ok7@gilhospital.com

This is an Open Access article distributed under the terms of the Creative Commons Attribution Non-Commercial License (<https://creativecommons.org/licenses/by-nc/4.0>) which permits unrestricted non-commercial use, distribution, and reproduction in any medium, provided the original work is properly cited.

In this case report, the authors present three cases of post-tracheostomy site bleeding successfully treated using embolization, supplemented by CT and angiography images. This report highlights that embolization can be a viable alternative when surgical or endoscopic interventions fail or are not applicable in cases of post-tracheostomy bleeding.

**Index terms** Embolization; Tracheostomy; Complications

## INTRODUCTION

Tracheostomy is a life-saving procedure often performed in patients with upper airway obstruction. Although uncommon, bleeding complications after tracheostomy can lead to significant hemorrhage and require close medical attention (1). Embolization can be performed for persistent or recurrent bleeding after conservative or surgical management. This report presents three cases of bleeding from tracheostomy sites treated with embolization.

## CASE REPORT

### CASE 1

A 72-year-old male in a semicomatose state due to cerebellar infarction had undergone a tracheostomy 1 month prior. Bleeding was observed at the oral and tra-

cheostomy sites, and the patient was transferred to the emergency department. A contrast-enhanced CT (CECT) was performed to find the bleeding focus, which revealed a small pseudoaneurysm on the right side of the tracheostomy site (Fig. 1A). Angiography of the right innominate and external carotid arteries was performed. No evidence of bleeding was observed (Fig. 1B). However, selective angiography of the right superior thyroid artery using a microcatheter revealed a small pseudoaneurysm that matched the CECT image (Fig. 1B; inset). Embolization was performed using 25% N-butyl-2-cyanoacrylate (NBCA) mixture. The patient was discharged 6 days after embolization without any clinical evidence of bleeding.

## CASE 2

A 45-year-old male who was bedridden due to an intracranial hemorrhage had undergone a tracheostomy 9 months prior. The patient was admitted because of frequent dyspnea. Stoma revision was performed, and circumferential granulation tissue originating from the inner wall of the tracheal lumen and bleeding was observed, necessitating the removal of the granulation tissue. Despite the procedure, intermittent oozing bleeding persisted. Cauterization could not be performed because of tracheal necrosis, and endoscopic examination failed to identify the specific bleeding focus. A CECT (Fig. 2A) revealed soft tissue, presumed to be granulation tissue, combined with a pseudoaneurysm on the left side of the trachea. Angiography of the left external carotid artery revealed no definitive evidence of bleeding. However, bleeding foci corresponding to the CECT findings were identified on selective angiography of the left superior thyroid artery (Fig. 2B). Embolization was performed using 25% NBCA mixture. The patient was discharged 2 weeks after the embolization without any clinical evidence of bleeding.

## CASE 3

A 57-year-old female who had undergone tracheostomy 8 years earlier for chronic subglottic stenosis was referred to the emergency department for worsening tracheostomy site

**Fig. 1.** Representative CT and angiography images for case 1.

**A.** A contrast-enhanced CT scan shows a small pseudoaneurysm around the tracheostomy site (arrow).

**B.** Right external carotid arteriography is negative for bleeding, but superselective right superior thyroid arteriography reveals a pseudoaneurysm (arrow in inset).

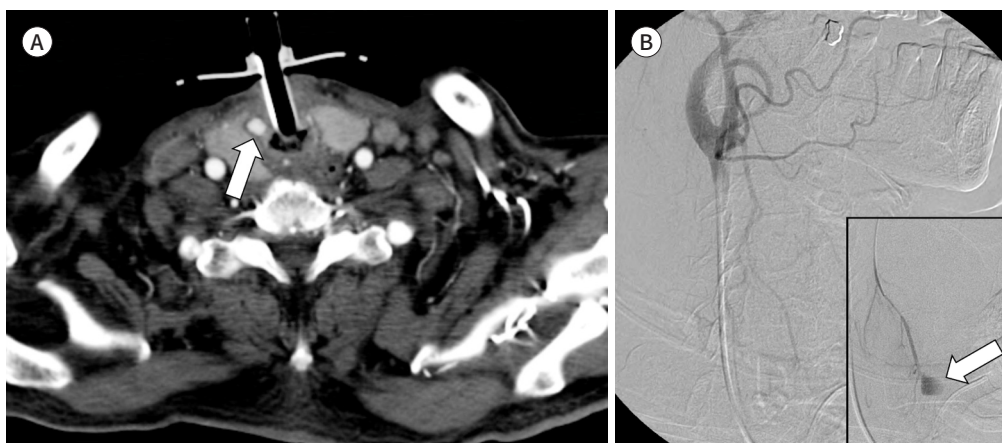
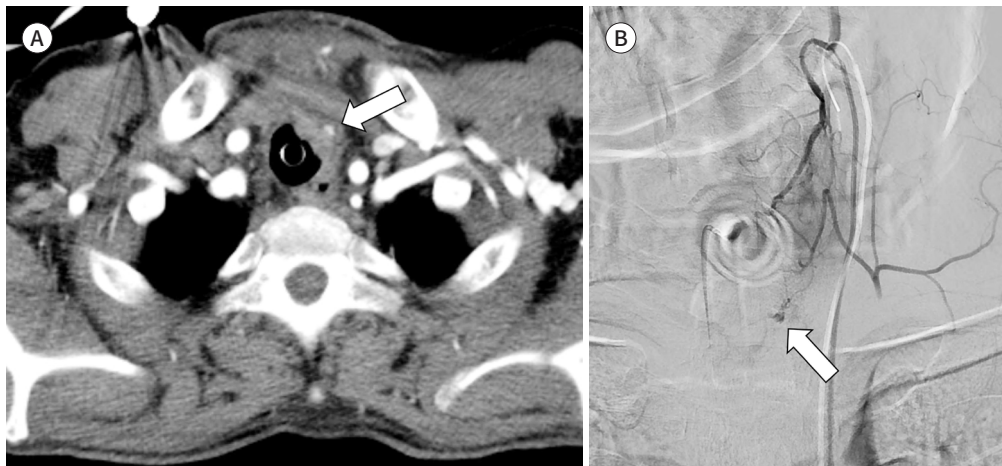


Fig. 2. Representative CT and angiography images for case 2.

A. A contrast-enhanced CT scan shows a tiny pseudoaneurysm around the tracheostomy site (arrow).

B. Left superior thyroid arteriography reveals a pseudoaneurysm (arrow).



bleeding that had started a week prior. There was no evidence of bleeding on CECT. Bronchoscopy revealed an ulcerative lesion in the anterior wall of the trachea without active bleeding. Bleeding persisted for a day, and an angiographic examination was planned. Angiography of the right innominate, external carotid, and superior thyroid arteries, as well as thyrocervical trunks revealed no active bleeding. Empirical embolization was performed using gelatin sponge particles (Cali-Gel 350–560  $\mu\text{m}$ , Alicon, Hangzhou, China) on the right superior thyroid artery and right thyrocervical trunk. Oozing bleeding decreased and completely stopped 2 days later. The patient was discharged 10 days after embolization without any clinical evidence of bleeding.

This study, consisting of three case presentations, was approved by the Institutional Review Board (IRB No. GDIRB2023-343).

## DISCUSSION

The underlying causes of bleeding complications after tracheostomy may differ depending on the timing of onset. Early-onset bleeding within 48 hours of tracheostomy is highly likely to be procedure-related, whereas delayed-onset bleeding may be caused by tracheal erosion due to direct pressure (1, 2). Although the overall bleeding complication rate has been reported to be up to 5% (1), it can serve as a sentinel for fatal bleeding complications, such as tracheo-innominate fistula (3). Therefore, in cases where hemostasis cannot be effectively achieved with manual compression alone or when the bleeding site cannot be identified, a diagnostic workup is necessary.

CECT can reveal the area around the tracheostomy site and mediastinal areas, including the innominate arteries. Although a surgical method may be considered in cases where a tracheostomy has been performed for a long time, it may be difficult to dissect the tissues, potentially compromising the surgical field. Moreover, the surgical difficulty may increase if the bleeding focus is deep, leading to a larger surgical wound. In addition, general anesthesia

is required. In contrast, embolization can selectively target the bleeding focus and has the advantage of allowing empirical embolization to be performed safely, even when the bleeding focus is not clearly identified. Furthermore, it can serve as an alternative in cases where general anesthesia is challenging, as it does not require general anesthesia and thus may be advantageous in situations where cardiopulmonary function is compromised. However, in cases where airway compression is caused by the mass effect of a large hematoma, combined surgical evacuation of the hematoma may be beneficial. If the bleeding site is localized, superselective embolization can be performed to treat bleeding lesions.

Tracheostomy is typically performed in the region around the thyroid gland, and the arteries supplying it are potential bleeders. The superior thyroid artery branches from the external carotid artery and runs to the superior anterior of the thyroid gland. In contrast, the inferior thyroid artery branches from the thyrocervical trunk and runs to the inferior part of the thyroid gland. Occasionally, the thyroidea ima artery may branch from various arteries, such as the innominate artery, and supply the isthmus or the inferior parts of the thyroid gland, trachea, and parathyroid glands. The superior thyroid artery may be the first choice for catheterization (4). Furthermore, empirical embolization can be safely performed to prevent rebleeding even if bleeding is not observed on CECT or selective angiography.

Possible complications associated with thyroid artery embolization may include thyroid parenchymal infarction; however, thyroid artery embolization is a widely used and safe method for the treatment of goiter and thyroid storm (5, 6). Because of the presence of multiple collateral branches supplying the thyroid gland, the risk of ischemia or infarction is low.

In summary, we successfully treated three patients with tracheostomy site bleeding and thyroid artery embolization without major complications. Empirical embolization also has a positive effect on the clinical course.

### Author Contributions

Conceptualization, K.J.H.; data curation, P.S.; resources, H.J.H., C.W.S.; writing—original draft, P.S.; and writing—review & editing, K.J.H.

### Conflicts of Interest

The authors have no potential conflicts of interest to disclose.

### ORCID iDs

Suyoung Park  <https://orcid.org/0000-0001-9688-3239>

Jeong Ho Kim  <https://orcid.org/0000-0002-1404-2821>

Jung Han Hwang  <https://orcid.org/0000-0002-0872-0956>

Woo Sung Choi  <https://orcid.org/0000-0002-0011-0985>

### Funding

None

## REFERENCES

1. Bontempo LJ, Manning SL. Tracheostomy emergencies. *Emerg Med Clin North Am* 2019;37:109-119
2. Fernandez-Bussy S, Mahajan B, Folch E, Cavedes I, Guerrero J, Majid A. Tracheostomy tube placement: early and late complications. *J Bronchology Interv Pulmonol* 2015;22:357-364
3. Laswi M, Vega J, Jones K, Lottenberg L. Tracheoinnominate artery fistula treated with endovascular stent

graft at a level I trauma center. *Cureus* 2020;12:e9710

4. Lin HW, Reilly BK. Pseudoaneurysm of the superior thyroid artery following revision tracheostomy. *Laryngoscope* 2012;122:1641-1643
5. Kaminski G, Jaroszuk A, Zybek A, Brzozowski K, Piasecki P, Ziecina P, et al. The calcium-phosphate balance, modulation of thyroid autoimmune processes and other adverse effects connected with thyroid arterial embolization. *Endocrine* 2014;46:292-299
6. Yilmaz S, Habibi HA, Yildiz A, Altunbas H. Thyroid embolization for nonsurgical treatment of nodular goiter: a single-center experience in 56 consecutive patients. *J Vasc Interv Radiol* 2021;32:1449-1456

## 기관절개 부위 출혈에 대한 갑상선 동맥 색전술: 3개 증례 보고

박수영<sup>1</sup> · 김정호<sup>1\*</sup> · 황정한<sup>1</sup> · 최우성<sup>2</sup>

기관절개술 후 출혈에 대해 색전술로 치료한 3개의 증례를 CT와 혈관조영술 사진과 함께 보고한다. 이 증례 보고를 통해 수술적/내시경적 치료가 불가능하거나 실패한 경우 색전술이 좋은 대안이 될 수 있음을 강조하고자 한다.

가천대학교 의과대학 길병원 <sup>1</sup>영상의학과, <sup>2</sup>응급의학과