International Journal of Surgery Case Reports 93 (2022) 106993

Contents lists available at ScienceDirect

International Journal of Surgery Case Reports

journal homepage: www.elsevier.com/locate/ijscr

Case report

An unusual presentation of thoracic diffuse idiopathic skeletal hyperostosis (DISH) and video-assisted thoracoscopic surgery (VATS)

Suthipas Pongmanee, Borvornsake Rojdumrongrattana, Noparoot Kritworakarn, Peem Sarasombath, Wongthawat Liawrungrueang *

Department of Orthopaedics, Faculty of Medicine, Chiang Mai University, Chiang Mai 50200, Thailand

ARTICLE INFO

Keywords:
Anterior thoracic osteophytectomy
Diffuse idiopathic skeletal hyperostosis
DISH
Dyspepsia
Video-assisted thoracoscopic surgery

ABSTRACT

Introduction and importance: Diffuse idiopathic skeletal hyperostosis (DISH), also known as Forestier's disease and Forestier and Rotes-Querol disease, is a systemic condition characterized by calcification and ossification of ligaments and entheses which often mainly affects the thoracic spine. Anterior osteophyte compression of the esophagus resulting in dysphagia and dyspepsia is extremely rare in symptomatic thoracic DISH.

Case presentation: A 72-year-old male presented with dyspepsia and dysphagia for 10 months. A large beak-like anterior osteophyte, detected by a radiographic study and by a Barium esophagogram test at the T9-T10 level of the thoracic spine, was established by gastrointestinal medicine specialists to be the cause of the symptoms. The large anterior osteophyte was removed using video-assisted thoracoscopic surgery (VATS). At the one-year follow-up, the patient's symptoms had significantly improved and there was no recurrence of the osteophyte or the dyspepsia and dysphagia.

Clinical discussion: Thoracic DISH rarely presents with dysphagia and dyspepsia due to the greater mobility of the esophagus in the area of the thoracic spine than in the area of the cervical spine. This is the first reported case of symptomatic thoracic DISH treated by anterior thoracic osteophytectomy with VATS. The treatment was effective with no post-operative complications.

Conclusion: Anterior thoracic osteophytectomy with VATS is an effective surgical treatment option for this condition.

1. Introduction and importance

Diffuse idiopathic skeletal hyperostosis (DISH), also known as Forestier's disease and Forestier and Rotes-Querol disease, is a systemic condition characterized by calcification and ossification of ligaments and entheses [1]. The etiology of DISH, which is associated with older age, male gender, obesity, metabolic syndrome, smoking and alcohol intake, is still unclear [2]. DISH often occurs at the right anterolateral thoracic spine, with ossification occurring more often at the T8-T10 level [3]. Patients with DISH are usually asymptomatic, although some report low back discomfort and other symptoms such as spinal motion stiffness. Dysphagia, hoarseness, stridor, and aspirated pneumonia are unusual manifestations of DISH at the cervical or thoracic spine which can occur when an anterior osteophyte compresses the esophagus or upper airway. Surgical treatment is an option for symptomatic DISH for cases where conservative treatment has been unsuccessful [2].

We describe the results of surgical treatment of a patient with symptomatic thoracic DISH who presented with dysphagia and dyspepsia, an unusual presentation. We describe the successful outcome of video-assisted thoracoscopic surgery (VATS) to remove an anterior osteophyte at the T9-T10 level which was compressing the esophagus. This case report has been prepared in accordance with SCARE criteria [4].

2. Case presentation

A 72-year-old male with the underlying diseases hypertension and dyslipidemia presented with dyspepsia and dysphagia for 10 months. He also complained of bloating and of significant weight loss (from 54 kg to 46 kg in 3 months). He had had no previous surgery and had no history of spine injury. The patient did not smoke, consume alcohol, or use

* Corresponding author.
E-mail address: mint11871@hotmail.com (W. Liawrungrueang).

https://doi.org/10.1016/j.ijscr.2022.106993
Received 28 February 2022; Accepted 26 March 2022
Available online 30 March 2022

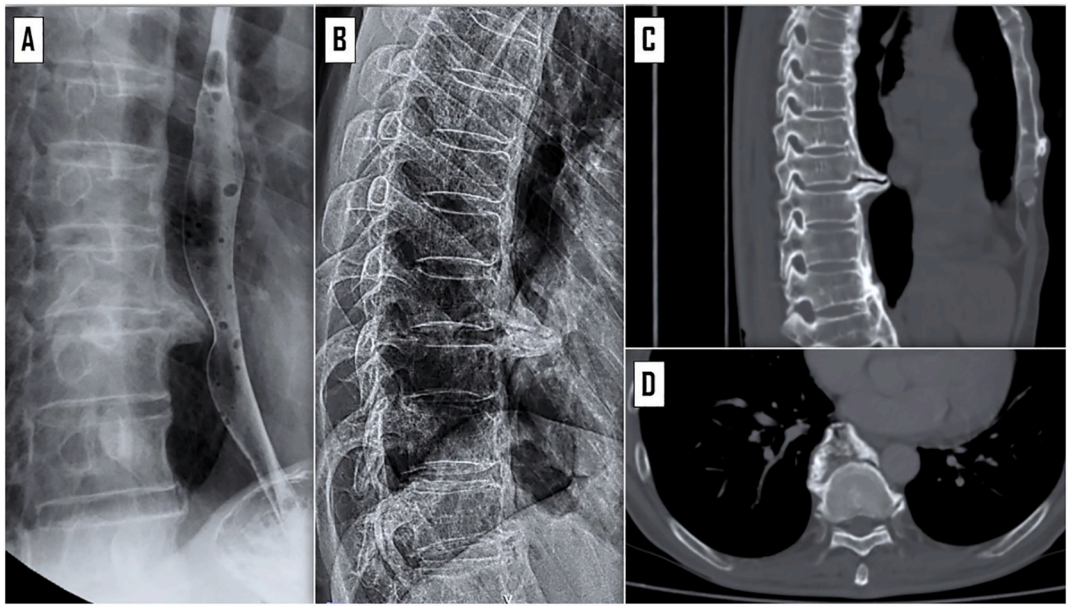

Fig. 1. Barium esophagogram study. (A) Plain radiograph of the thoracic spine (B), axial (C) and midsagittal (D) computerized topography views showing a large anterior osteophyte compressing the posterior esophageal wall at the T9-T10 level.

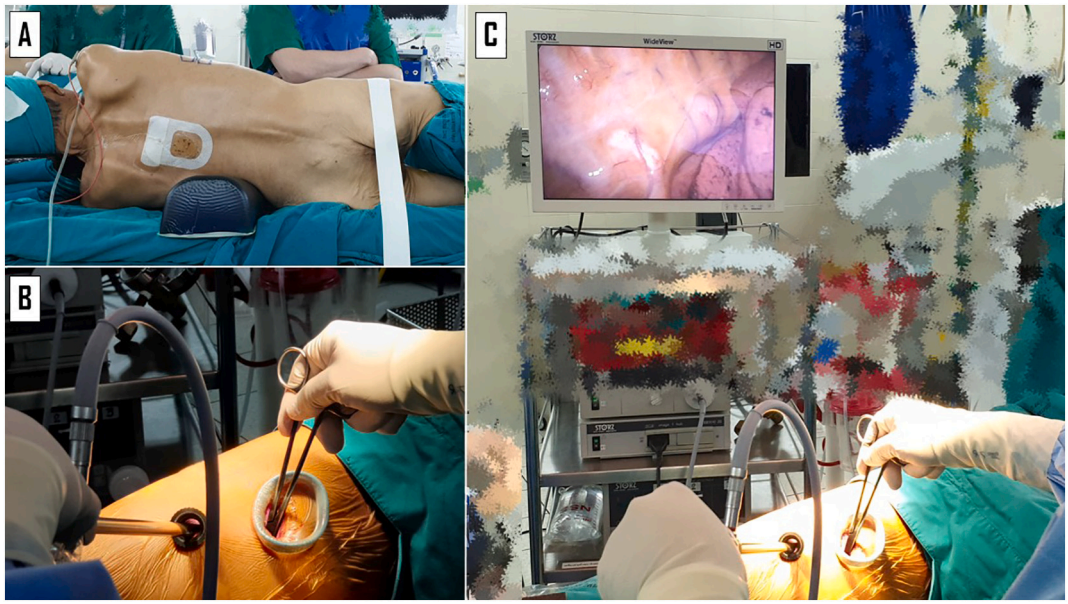

Fig. 2. Patient in the left lateral decubitus position (A), incision and portal for VAT assisted system (B), the large anterior osteophyte of thoracic identified using the VATS system (C).

recreational drugs. Physical examination found his vital signs and neurological status to be normal and there was no back pain. Results of the swallowing test were abnormal. A barium esophagogram showed posterior indentation of the esophagus by an anterior osteophyte at the T9-T10 vertebra (Fig. 1A). A plain X-ray showed a giant beak-like anterior osteophyte at the T9-T10 level of the thoracic spine (Fig. 1B). A computerized tomography (CT) scan showed features of DISH along the spine including a 2 cm osteophyte at the T9-T10 spine and a bulging posterior esophageal wall (Fig. 1C–D).

The cause of the dysphagia and dyspepsia was investigated and confirmed by gastrointestinal medicine specialists to be the large anterior osteophyte at the T9-T10 level. Surgical removal of the osteophyte was advised and the patient underwent VATS to remove the osteophyte at the T9-T10 level. Intraoperatively, the patient was placed in the left lateral decubitus position under general anesthesia (Fig. 2A). The level of the osteophyte was confirmed by fluoroscopic examination. The transthoracic approach was used for VATS. Mini-open skin incision was performed at anterior axillary line of the 9th intercostal space and the 6th intercostal space (Fig. 2B). The osteophyte was identified during VATS (Fig. 2C) and was removed using Rongeur forceps and a high-speed burr (Fig. 3A–F).

Dysphagia and dyspepsia improved without post-operative complications following surgery. At the 1-year follow-up, the clinical condition had significantly improved with no return of dysphagia or dyspepsia symptoms. The patient was highly satisfied with the treatment.

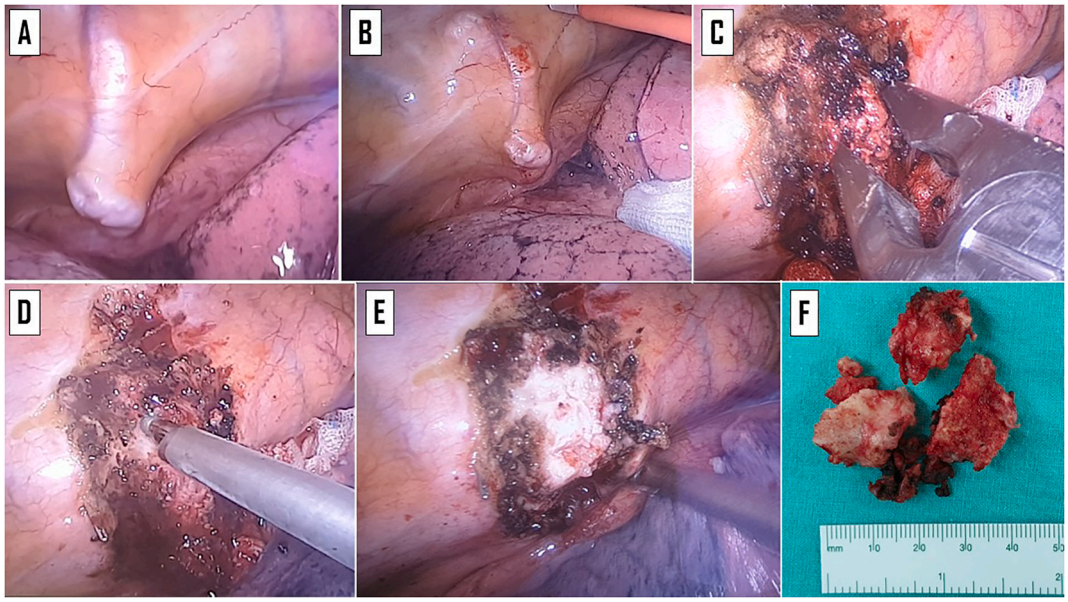

Fig. 3. The large anterior thoracic osteophyte identified during VATS (A, B). The osteophyte was removed using Rongeur forceps (C) and a high-speed burr (D). The resected osteophyte (F).

Table 1
Reports on dysphagia from diffuse idiopathic skeletal hyperostosis of thoracic spine published in the English language.

Author	Year	Diagnosis	Number of cases	Preoperative symptoms	Levels of anterior osteophyte	Treatment	Final clinical outcome
S. Underberg-Davis and M.S. Levine [8]	1991	DISH	1	Dysphagia	T9-T10	Close follow-up and spontaneous relief	Significant improvement; recurrence of symptoms not reported
S.B. Patel and A.V. Patel [12]	2021	DISH	1	Dysphagia	T2-T3	Diet modification and swallowing rehabilitation	Clinical improvement
This case	2022	DISH	1	Dysphagia, dyspepsia and weight loss	T9-T10	Anterior thoracic osteophytectomy with VATS	Significant improvement of dysphagia and dyspepsia without recurrence

Abbreviations: VATS - video-assisted thoracoscopic surgery; DISH - diffuse idiopathic skeletal hyperostosis.

3. Clinical discussion

DISH is a systemic disease characterized by excessive calcification of the anterior spinal body, primarily at the T8-T10 level [3]. The etiology is still unclear; the prevalence of DISH in the Asian population ranges between 10 and 25% [5]. The majority of patients are asymptomatic, although compression of the anterior component of the cervical spine can cause dysphagia, recurrent pneumonia, and airway obstruction [2,6,7]. Thoracic DISH, however, is extremely uncommon [8]. When nonoperative treatments, including diet modification and medication, have failed, surgical resection can be considered [9]. Reformation of an osteophyte has been found to occur at a rate of 1 mm/year; however, recurrence of symptoms after surgical resection occurs slowly and in very few patients [10]. Apart from surgical resection, additional fusion, NSAIDs, bisphosphonate, indomethacin and radiotherapy have been used to reduce the risk of recurrence, but there are no precise guidelines for prophylaxis to prevent recurrence [5,11].

A review of the literature on thoracic spine osteophytes causing dysphagia found few cases with only limited treatment data (Table 1). Thoracic anterior osteophytes are rare, causing symptoms related to the ability the esophagus at the thoracic level to move anteriorly and laterally. Additionally, the esophagus at the cervical level is fixed to the neck by the cricothyroid cartilage making it easier to become compressed [8,12]. VATS is a minimally invasive surgery used to access anterior pathologies of thoracic and thoracolumbar spine. VATS also results in fewer perioperative complications and results in a faster recovery than the standard anterior approach. The VATS procedure does, however, involve a learning curve for surgeons to become familiar with the technique. This procedure has been used for decompression corpectomy, stabilization and reconstruction [13,14]. There have been no published reports of VATS being used in the removal of an anterior osteophyte in DISH patients.

4. Conclusion

Anterior osteophyte compression of the esophagus with dysphagia and dyspepsia is extremely rare in symptomatic thoracic DISH. VATS to remove an osteophyte is a treatment of choice in DISH patients with dysphagia and dyspepsia caused by an anterior thoracic osteophyte.

Provenance and peer review

Not commissioned, externally peer-reviewed.

Consent

Written informed consent was obtained from the patient for publication of this case report and accompanying images. A copy of the written consent is available for review from the Editor-in Chief of this journal upon request.

Ethical approval

This case report was approved by the Institutional Review Board, Faculty of Medicine, Chiang Mai University.

Funding

Funding for this research was provided by the Faculty of Medicine, Chiang Mai University, Chiang Mai, Thailand. The funders had no role in the study design, data collection and analysis, decision to publish or preparation of the manuscript.

Guarantor

Wongthawat Liawrungrueang, MD.

Research registration number

None.

CRediT authorship contribution statement

Suthipas Pongmanee (SP): Data curation, review and editing.
Borvornsake Rojdumrongrattana (BR): Writing original draft, review of literature, artwork design visualization and data analysis.
Noparoot Kritworakarn (NK): Review of literature and data curation.
Peem Sarasombath (PS): Review of literature and data curation.
Wongthawat Liawrungrueang (WL): Review of literature, conceptualization, methodology, artwork design, writing-original draft, editing and revision the final version for publication.

Declaration of competing interest

The authors declare that they have no competing interests.

Acknowledgments

The authors would like to express their sincere thanks to Dr. G. Lamar Robert, Ph.D., and Assoc. Prof. Dr. Chongchit Sripun Robert, Ph.D., for editing the English manuscript. We would also like to express our thanks to Department of Orthopaedics, Faculty of Medicine, Chiang Mai University for their support.

References

[1] D. Resnick, S.R. Shaul, J.M. Robins, Diffuse idiopathic skeletal hyperostosis (DISH): Forestier's disease with extraspinal manifestations, Radiology 115 (1975) 513–524, https://doi.org/10.1148/15.3.513.
[2] J.S. Kuperus, F.A.A. Mohamed Hoesein, P.A. de Jong, J.J. Verlaan, Diffuse idiopathic skeletal hyperostosis: etiology and clinical relevance, Best Pract. Res. Clin. Rheumatol. 34 (2020), 101527, https://doi.org/10.1016/j.berh.2020.101527.
[3] A. Hiyama, H. Katoh, D. Sakai, M. Sato, M. Tanaka, M. Watanabe, Prevalence of diffuse idiopathic skeletal hyperostosis (DISH) assessed with whole-spine computed tomography in 1479 subjects, BMC Musculoskelet. Disord. 19 (2018) 178, https://doi.org/10.1186/s12891-018-2108-5.
[4] R.A. Agha, T. Franchi, C. Sohrabi, G. Mathew, A. Kerwan, SCARE Group, The SCARE 2020 guideline: updating consensus Surgical CAse REport (SCARE) guidelines, Int. J. Surg. 84 (2020) 226–230, https://doi.org/10.1016/j.ijsu.2020.10.034.
[5] W. Liawrungrueang, P. Sarasombath, T. Maihom, W. Tantivorawit, N. Sugandhavesa, T. Bunmaprasert, Anterior cervical spine surgery for treatment of secondary dysphagia associated with cervical myelopathy in patient with Forestier's disease, Ann. Med. Surg. 72 (2021), 103120, https://doi.org/10.1016/j.amsu.2021.103120.
[6] J.J. Lee, J.Y. Hong, J.H. Jung, J.H. Yang, J.-Y. Sohn, Recurrent aspiration pneumonia due to anterior cervical osteophyte, Korean J. Crit. Care Med. 32 (2017) 74–78, https://doi.org/10.4266/kjccm.2016.00409.
[7] J.-J. Verlaan, P.F.E. Boswijk, J.A. de Ru, W.J.A. Dhert, F.C. Oner, Diffuse idiopathic skeletal hyperostosis of the cervical spine: an underestimated cause of dysphagia and airway obstruction, Spine J. 11 (2011) 1058–1067, https://doi.org/10.1016/j.spinee.2011.09.014.
[8] S. Underberg-Davis, M.S. Levine, Giant thoracic osteophyte causing esophageal food impaction, AJR Am. J. Roentgenol. 157 (1991) 319–320, https://doi.org/10.2214/ajr.157.2.1853815.
[9] J. Urrutia, C.M. Bono, Long-term results of surgical treatment of dysphagia secondary to cervical diffuse idiopathic skeletal hyperostosis, Spine J. 9 (2009) e13–e17, https://doi.org/10.1016/j.spinee.2009.04.006.
[10] K. Miyamoto, S. Sugiyama, H. Hosoe, N. Iinuma, Y. Suzuki, K. Shimizu, Postsurgical recurrence of osteophytes causing dysphagia in patients with diffuse idiopathic skeletal hyperostosis, Eur. Spine J. 18 (2009) 1652–1658, https://doi.org/10.1007/s00586-009-1133-3.
[11] S. Ruetten, X. Baraliakos, G. Godolias, M. Komp, Surgical treatment of anterior cervical osteophytes causing dysphagia, J. Orthop. Surg. (Hong Kong) 27 (2019), https://doi.org/10.1177/2309499019837424, 2309499019837424.
[12] S.B. Patel, A.V. Patel, S2167 rare cause of dysphagia due to thoracic vertebral osteophytes, Off. J. Am. Coll. Gastroenterol. 116 (2021), S930, https://doi.org/10.14309/01.ajg.0000782200.43208.5f.
[13] R. Levin, D. Matusz, A. Hasharoni, C. Scharf, B. Lonner, T. Errico, Mini-open thoracoscopically assisted thoracotomy versus video-assisted thoracoscopic surgery for anterior release in thoracic scoliosis and kyphosis: a comparison of operative and radiographic results, Spine J. 5 (2005) 632–638, https://doi.org/10.1016/j.spinee.2005.03.013.
[14] S.J. Kim, M.-J. Sohn, J.-Y. Ryoo, Y.-S. Kim, C.J. Whang, Clinical analysis of video-assisted thoracoscopic spinal surgery in the thoracic or thoracolumbar spinal pathologies, J. Korean Neurosurg. Soc. 42 (2007) 293–299, https://doi.org/10.3340/jkns.2007.42.4.293.