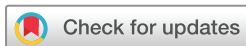

Comparison of age-related vascular changes in the optic disc of patients with diabetes, with glaucomatous and non-glaucomatous features

Manuel Gonzalez de la Rosa ,¹ Santiago de-la-Huerga-Moreno,² Francisco Alfonso-Lopez,² Francisco Cabrera-Lopez,³ Alicia Pareja-Rios,⁴ Daniel Gonzalez-Hernandez,⁵ Marta Gonzalez-Hernandez⁶

To cite: Gonzalez de la Rosa M, de-la-Huerga-Moreno S, Alfonso-Lopez F, *et al.* Comparison of age-related vascular changes in the optic disc of patients with diabetes, with glaucomatous and non-glaucomatous features. *BMJ Open Ophthalmology* 2022;**7**:e001100. doi:10.1136/bmjophth-2022-001100

Received 22 June 2022
Accepted 5 August 2022



© Author(s) (or their employer(s)) 2022. Re-use permitted under CC BY-NC. No commercial re-use. See rights and permissions. Published by BMJ.

¹Ophthalmology, University of La Laguna Faculty of Health Sciences, San Cristobal de La Laguna, Spain

²Retisalud, Servicio Canario de Salud, Santa Cruz de Tenerife, Spain

³Ophthalmology, Hospital Universitario Insular de Gran Canaria, Las Palmas de Gran Canaria, Spain

⁴Ophthalmology, Hospital Universitario de Canarias, La Laguna, Spain

⁵Instrumentacion y Oftalmologia INSOFTE SL, Santa Cruz de Tenerife, Spain

⁶Ophthalmology, Hospital Universitario de Canarias, University of La Laguna, Spain, La Laguna, Spain

Correspondence to

Dr Manuel Gonzalez de la Rosa; mgdelarosa1950@gmail.com

ABSTRACT:

Objective To identify age-related vascular changes in the optic discs of patients with diabetes with and without signs of glaucoma.

Methods and analysis A total of 2153 eyes of 1797 patients with diabetes without significant retinopathy were monitored with 10 Topcon-NW400 images obtained over 10.27 ± 1.58 years. 571 non-diabetics eyes were selected as controls. Laguna ONhE uses convolutional neural networks to identify optic disc edges, vessels, cup and rim, and provides a glaucoma assessment index—Globin Distribution Function (GDF).

Results In the first image, vessel pixels accounted for 33.88% of the disc area (SD=3.72) in non-glaucoma (DN) and 31.35% (SD=4.05; $p < 0.0001$) in glaucoma cases (DG). This number of pixels was reduced by -0.55% each year (SD=0.77) in the DN and -0.76% (SD=0.86; $p = 0.0014$) in the DG. In the first image, 76.55% of the disc pixels (SD=11.13) belonged to the rim in the DN and 62.05% (SD=11.00; $p = 0.0014$) in the DG, decreasing annually by -0.33% (SD=0.99) in the DN and -0.68% (SD=1.08; $p < 0.0001$) in the DG groups. All rim sectors were reduced over time in the DG group, particularly superotemporal (41° – 80°) and inferotemporal (271° – 310°). The reduction was smaller in DN, presenting as progressive thickening of the temporal sector (311° – 40°). No changes in age were observed in healthy controls.

Conclusion Patients with diabetes show progressive reduction of vessels and neuroretinal rim at the optic disc, which is more intense in association with glaucoma. In the absence of glaucoma, the temporal sector of the diabetic rim was not reduced but thickened, displacing the cup nasally.

INTRODUCTION

Vascular and perfusion alterations have been related to the progression of glaucoma in various ways.^{1–7} Particularly since the introduction of angiography using optical coherence topography,⁸ numerous studies have observed a reduction in microvascularisation across the ocular tissue in glaucomatous disease, peripapillary vessels,⁹ optic disc,¹⁰ whole-image vessel density¹¹ or in the macular region.^{12 13}

WHAT IS ALREADY KNOWN ON THIS TOPIC

⇒ There is conflicting evidence about the reduction in the number of vessels of the normal optic disc with age and the higher incidence of glaucoma in diabetics. A reduction in vascular pixels in different areas of the fundus was observed in patients with diabetes.

WHAT THIS STUDY ADDS

⇒ Vascular pixels and rim width are reduced over time at the optic disc in most patients with diabetes, except in the temporal sector. This reduction is greater and more generalised in the presence of glaucomatous signs.

HOW THIS STUDY MIGHT AFFECT RESEARCH, PRACTICE OR POLICY

⇒ This study will account for the contribution of the vascular impairment of the diabetic optic nerve to glaucomatous damage.

In addition, this technique also provides information of great interest on other diseases that affect the retinal vascularisation, such as diabetes.¹⁴

The Laguna ONhE application, developed in 2013, evaluates the topographic distribution of haemoglobin in the optic disc by analysing conventional colour photographs.¹⁵ The application has demonstrated, in several publications, its ability to identify the usual features of glaucoma in fundus images and distinguish them from normal physiology, with high sensitivity and specificity.^{16–19} In recent years, the method has achieved absolute automation due to the application of convolutional neural networks. Its results are enhanced when associated with perimetry, especially with homogeneity or harmony of the visual field.²⁰

The Health Services of the Canary Islands have a large database of retinographies

obtained over the years with the aim of monitoring and controlling the progression of disease in the diabetic population of this region of Spain. Specifically, the Retisalud health unit has more than 60 fundus cameras located in different centres, which facilitated the inclusion of patients that were scattered over several islands, as controls in this study. Only patients without obvious retinopathy were included in the database, while patients with significant diabetic involvement were referred to hospital centres for further treatment and were excluded from the study.

We retrospectively analysed the patient images to observe and detect possible vascular changes within the optic disc. Therefore, we selected a series of patients with relatively equivalent information, to facilitate the differentiation of patients with signs of glaucoma from those without.

The intention of this study was to identify, in a longitudinal way, the existence of vascular and perfusion changes in the optic disc of patients with diabetes. We assessed the constancy and morphological modifications that could occur during the evolution of non-advanced diabetic disease in patients, with and without signs of glaucoma.

MATERIALS AND METHODS

In a retrospective screening for glaucoma in patients with diabetes using the Laguna ONhE application, the vast majority of the population with diabetes in the Canary Islands was evaluated. Specifically, 1124885 fundus images obtained from 203115 patients between 18 May 2006 and 31 March 2021 were analysed. Among them, the cases where 10 useful images were obtained with the Topcon NW400 fundus camera (Tokyo Optical, Japan) were selected as consecutive checks. Patients with significant retinopathy were excluded from this study. Retisalud general doctors attended to the patients without any significant retinopathy recorded in their database. Those requiring strict control (moderate non-proliferative retinopathies) or specific treatment (severe non-proliferative retinopathies, proliferative retinopathies and macular oedema) were monitored by ophthalmologists in their respective areas and hospitals. A group of 571 eyes (315 healthy and 256 glaucoma eyes) from 312 non diabetic participants was used as the control.

Given the nature of this retrospective study and respect for the anonymity of the patients, no written consent was obtained from them. Given the population of the Canary Islands, it can be stated that the vast majority of the participants belonged to Caucasian ethnicities, although individual identification of this aspect was not performed.

The Laguna ONhE application was used to analyse the images using an automated process.²⁰ The method uses several convolutional neural networks to identify the optic nerve and its boundaries, locate the inner edge of the Elschnig scleral ring, recognise the image quality, identify the laterality of the eye, segment the vessels and obtain a haemoglobin distribution map using the colour

of the vessels as a pattern. The deep learning neural network that analyses the image quality is programmed to exclude the abnormal optic discs, such as myelin fibres inside the optic disc, myopic gyrate atrophies, optic disc oedema and colobomas. It also identifies the cup and rim sectors, and provides an index called the globin distribution function (GDF), in which a glaucoma discriminator based on deep learning plays an important role. This index identifies glaucoma when the value is below -15 with a specificity of 99%.

Thus, the percentage of pixels corresponding to the vessels and the percentage of pixels corresponding to the tissue can be calculated. In addition, this method estimates the shape and dimensions of the excavation (cup) and sectors of the rim. The changes observed in the morphological and vascular data over time were analysed in this study.

Statistical analyses were performed using the Microsoft Excel 2016 program (Excel. Microsoft, Redmond, Wash, USA), and MedCalc (V.18.9–64 bits; MedCalc software bvba, Mariakerke, Belgium).

RESULTS

The study included 2153 eyes from 1797 patients with diabetes (356 bilateral and 1441 monocular, 941 men and 856 women, 1213 left eyes and 940 right eyes). The average age of the patients at the beginning of the study was 57.23 ± 9.39 years and the duration of follow-up was 10.27 ± 1.58 years. The non-diabetic group consisted of 571 eyes from 312 participants (315 healthy eyes and 256 eyes affected with glaucoma, 248 men and 323 women, 266 left eyes and 305 right eyes). The average age of non-diabetic participants at the time of examination was 57.21 ± 12.99 years ($p=0.486$ compared with the diabetic group).

At the beginning of the follow-up, the pixels corresponding to the vessels were assessed for $33.88\% \pm 3.72\%$ of the disc area in the 1990 diabetic non-glaucoma subjects (DN) and $31.35\% \pm 4.05\%$ ($p<0.00001$) in the 163 glaucoma patients (DG). The number of pixels was reduced from the initial value by $-0.55\% \pm 0.77\%$ every year in DN and $-0.76\% \pm 0.86\%$ ($p=0.0014$) in DG (figure 1). In the DN group, 79.68% of the cases presented a negative slope in the number of vascular pixels, while in the DG group 82.96% of the cases presented with this slope ($p=0.0015$).

Although women from the DN group were slightly older (57.43 years ± 9.56) than their male counterparts (56.37 ± 9.33 ; $p=0.0213$), the percentage of vessels involved was slightly higher ($34.11\% \pm 3.64\%$ vs $33.68\% \pm 3.77\%$; $p=0.0003$) at the beginning of the follow-up. However, the slope of the annual loss was similar in both the cases.

Patients included in the DN group had an initial vertical cup-to-disc ratio of 0.4073 ± 0.1322 , while those in the DG group had a ratio of 0.5670 ± 0.1080 ($p<0.00001$). The annual increments in the DN group were 0.0032 ± 0.0078 , while those in the DG group were 0.0039 ± 0.0057 ($p=0.0824$).

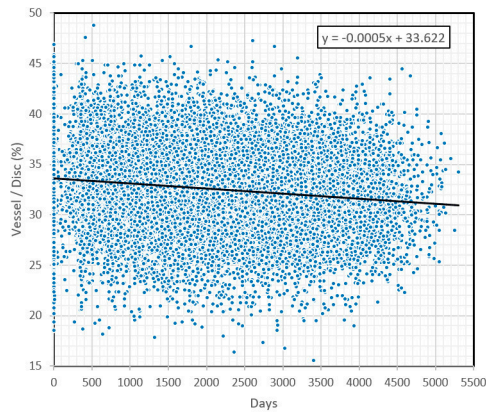


Figure 1 Percentual evolution of the disc area occupied by vessels. The scatter plot shows the regression line defined by the data for all eyes over the period studied. ($r=-0.1561$, $p<0.0001$). The high dispersion of the data is essentially due to the large interindividual variability in size and morphology of the optic disc.

At the beginning of the series, the rim occupied $76.55\% \pm 11.13\%$ of the disc area in the DN group and $62.05\% \pm 11.00\%$ ($p<0.00001$) of the disc area in the DG group. This figure decreased annually from the initial value by $-0.33\% \pm 0.86\%$ in the DN group and $-0.68\% \pm 1.08\%$ ($p<0.0001$) in the DG group.

All sectors of the rim reduced over time in the DG group, particularly in the superotemporal ($41^\circ-80^\circ$) and inferotemporal ($271^\circ-310^\circ$) zones. In the DN group, the reduction was smaller in all sectors; however, progressive thickening of the temporal sector ($311^\circ-40^\circ$) was observed (table 1 and figures 2 and 3). The percentage area of the rim was reduced in 63.90% of the DN cases and 69.26% of the DG cases ($p<0.0001$).

At the time of initial examination, the 1990 diabetic eyes without glaucoma had a correlation coefficient of $r=-0.2815$ between age and the percentage of vascular pixels ($p<0.0001$), with a reduction of 0.289% from the initial value per year. In the 315 healthy, non-diabetic eyes, the correlation coefficient was $r=0.0557$ ($p<0.323$), showing no vascular reduction with age. The difference

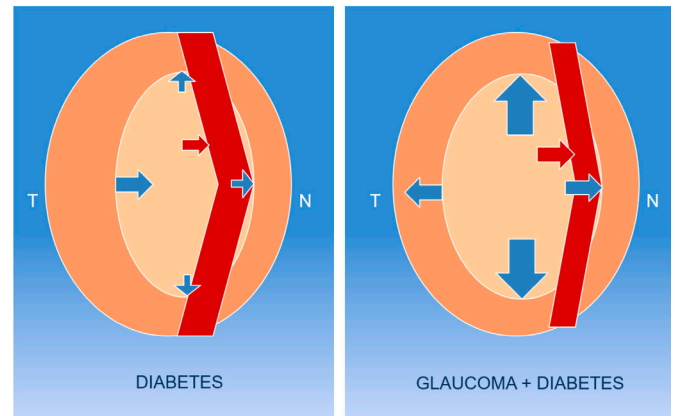


Figure 2 Diagram of vascular and rim changes. In the absence of glaucoma in the diabetic (left image) patients, there is vascular reduction and growth of the cup, with widening of the rim in the temporal (T) sector. On average, in diabetic glaucoma (right image), the vessels are reduced more significantly (red arrows) and the cup widens in all directions, although preferentially in the vertical direction (blue arrows).

in ‘r’ between the normal and diabetic groups was significant ($p<0.0001$) (figure 4A).

At the time of the initial examination, 163 diabetic eyes with signs of glaucoma had a correlation coefficient of $r=-0.2157$ between age and the percentage of vascular pixels ($p=0.0057$), with a reduction of 0.319% from the initial value per year. In 256 non-diabetic glaucoma cases, the correlation coefficient was $r=-0.110$ ($p<0.0001$), with a reduction of 0.156% per year (figure 4B).

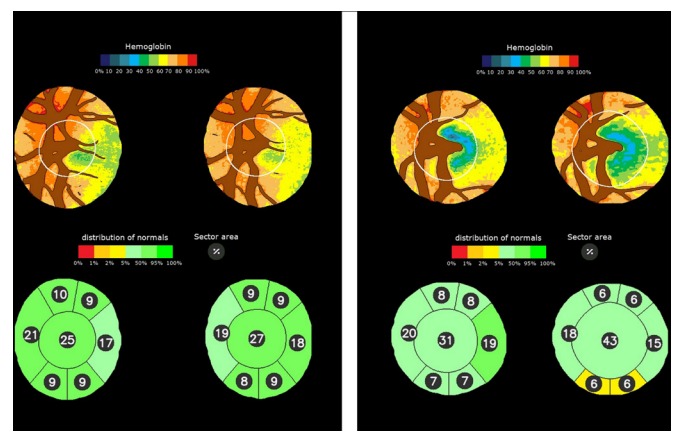


Figure 3 Examples of changes in haemoglobin distribution. The upper images represent the distribution of haemoglobin across the optic disc and the lower images represent the percentage area of the cup and rim sectors. Left: initial and final images of a non-glaucomatous diabetic patient controlled for 7.5 years. Vascular pixels decreased from 30.8% to 29.3%. Right: initial and final images of a glaucomatous diabetic patient controlled for 7.8 years. Vascular pixels decreased from 35.8% to 31.9%.

Table 1 Annual percentage reduction of rim sector areas (average and SD) in diabetic non-glaucoma subjects (DN) and glaucoma cases (DG) along with the degree of significance (p)

Rim sector	DN	DG	P value
% sector $311^\circ-40^\circ$ (T)	$+0.15 \pm 1.37$	-0.19 ± 1.31	0.0009
% sector $41^\circ-80^\circ$	-0.20 ± 0.91	-0.44 ± 1.39	0.0161
% sector $81^\circ-120^\circ$	-0.45 ± 0.89	-0.81 ± 1.35	0.0006
% sector $121^\circ-230^\circ$ (N)	-0.63 ± 1.12	-1.02 ± 1.55	0.0010
% sector $231^\circ-270^\circ$	-0.46 ± 1.16	-0.87 ± 1.6	0.0010
% sector $271^\circ-310^\circ$	-0.19 ± 1.18	-0.53 ± 1.32	0.0010

DG, glaucoma group; DN, non-glaucoma group.

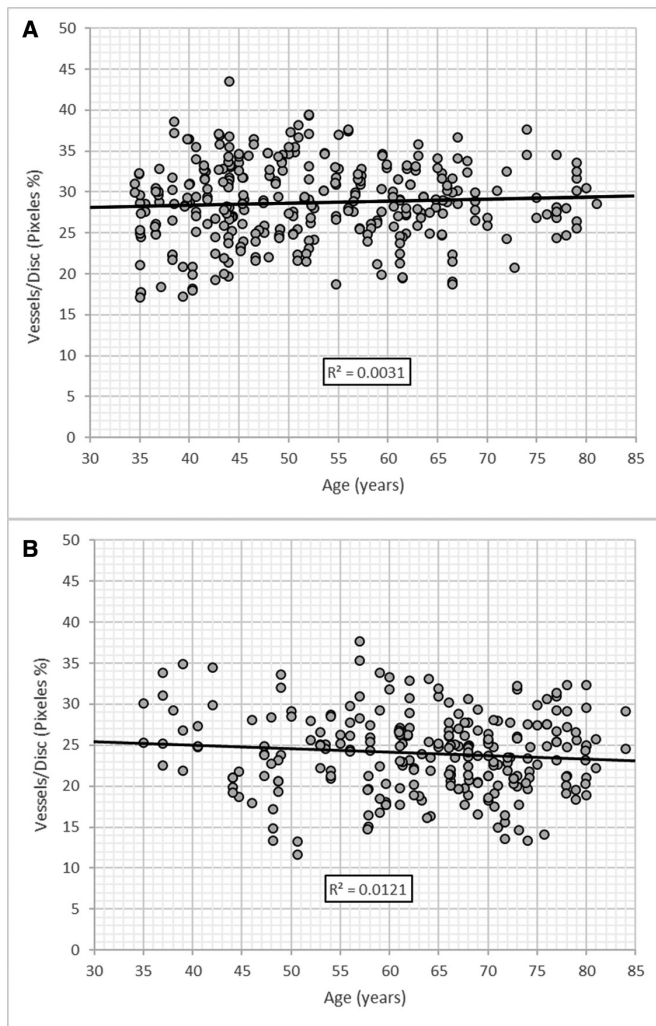


Figure 4 Changes in the percentage of vascular pixels at the optic disc with age. Scatter plots of the percentages of vascular pixels in 315 normal non-diabetic eyes with respect to their age (A) and in 256 glaucomatous non-diabetic eyes (B).

DISCUSSION

A reduction in optic disc vessels in the glaucomatous subjects when compared with normal subjects has been previously observed using angio-optical coherence tomography (OCT).^{10 21} A recent review elucidated the need for comprehensive longitudinal studies in this regard.²²

The present paper is oriented towards the previous mentioned goal, focusing on longitudinal changes in optic disc vessels in patients with diabetes with and without signs of glaucoma. Vascular reduction in peripapillary vessels has been previously reported in patients with diabetes and is related to the degree of retinopathy.²³

We have not been able to observe the vascular reduction with age in our control group, as has been recently described in normal subjects using angio-OCT,²⁴ and is a controversial topic in the literature.²⁵ Our present results seem to corroborate those we have found in a previous

study in which no decrease in papillary haemoglobin with age was found in normal subjects.¹⁶

The cup of the optic nerve head is one of the most widely used parameters for assessing glaucoma. In particular, its elongation in the vertical direction, usually measured by the vertical cup/disc ratio, has been generalised because an increasing number of objective procedures have emerged, such as stereoscopic photography,²⁶ confocal tomography²⁷ and OCT.²⁸

However, our results showed that this increase is not exclusive to glaucoma. Diabetes also causes a significant increase in excavation with disease progression, probably as a consequence of the vascular defects associated with it. However, this increase has specific characteristics that differentiate it from glaucomatous damage. These differences are manifested mainly by a smaller reduction in the temporal and nasal sectors of the rim, and even by an increase in the thickness of the temporal sector, with a tendency to produce a displacement of the excavation toward the nasal side.

On the other hand, it is also possible that both processes are associated with or potentiate each other. It has been speculated that the higher incidence of glaucoma in the diabetic population could be related to more frequent eye examinations in these patients, and the relationship between both diseases has been suggested in the Blue Mountains study²⁹ and few other studies.^{30 31}

Our results seem to point to the latter direction. Patients with diabetes show a progressive reduction of the vascular calibre at the optic disc throughout their evolution, which is more intense in the case of diabetes associated with glaucoma. Reduction of the neuroretinal rim is also greater in the presence of glaucoma. Thus, the reduction in the calibre of the vessels, which mainly occupy the nasal sector, produces a displacement of the cup towards this side, facilitating the expansion of the temporal sector if diabetes does not concur with glaucoma.

The progression of the vertical cup/disc ratio is similar in both cases; however, it must be considered that the growth possibilities are limited because the residual rim becomes increasingly smaller.

A recent study has shown that the application of Laguna ONhE provides results comparable to those of angio-OCT in relation to glaucomatous optic nerve vascularisation.³² The current study also suggests that the information provided by Laguna ONhE may be useful in the follow-up of other vascular processes such as diabetes.

The main limitation of this study is that the diagnosis of patients with diabetes with signs of glaucoma has not been confirmed in practice. Although previous experiences suggests that a large majority of patients with GDF values below -15 are glaucomatous, this finding should be confirmed in this particular series. Therefore, a prospective study should be conducted to understand the degree of sensitivity and specificity of Laguna ONhE in the near future.

Another limitation is the ethnicity of the population studied. The results of this study may not be fully comparable to other ethnic groups where optic disc morphology, among other factors, may present particularities that need to be evaluated.

Although we did not have the opportunity to make a comparison in a longitudinal series, the two series were analysed at a specific date in subjects with an equivalent age range; it was observed that diabetics showed vascular reduction with age, whereas this could not be observed in non-diabetic subjects without glaucoma. In glaucomatous subjects, this reduction would be smaller in non-diabetic subjects; this data is in line with that obtained using angio-OCT.²³

In conclusion, our results suggest that, in diabetes, there is progressive deterioration of the optic disc vessels, as in other parts of the eye. The importance of the vascular component in glaucoma aetiopathogenesis is now being recognised. In the case of patients with diabetes, their own vascular defects converge with glaucomatous defects, favouring optic nerve damage.

Acknowledgements The authors are grateful to Unidad Retisalud del Servicio Canario de Salud (Islas Canarias) who provided the infrastructure, database, and images.

Collaborators Manuel Gonzalez de la Rosa 1 Daniel Gonzalez-Hernandez 1 Santiago de-la-Huerta-Moreno 2 Francisco Afonso 2 Francisco Cabrera 3 Alicia Pareja-Rios 4 Marta Gonzalez-Hernandez 1-4 Groups: 1 INSOFT S.L., 2 Retisalud. Servicio Canario de Salud. 3 Hospital Insular de Gran Canaria. 4 Hospital Universitario de Canarias, Spain.

Contributors MGdIR, DG-H, S-d-I-H-M, FA-L, FC-L, AP-R and MG-H contributed to planning the study, analysed the data, provided critical comments and contributed to the final manuscript. In particular, S-d-I-H-M and FA-L organised and provided the images used, and MGdIR and MG-H managed the project. MGdIR is the guarantor.

Funding This study was carried out in part with INSOFT S.L.'s own funds and was partially financed with the European Union FEDER funds. 'A way of doing Europe'. Red.es Project 2020/0720/00098137.

Competing interests DG-H, MG-H and MGdIR participated in the patent rights of the Laguna ONHe method and its partners. The rest of the authors have no conflicts of interest to declare.

Patient and public involvement Patients and/or the public were not involved in the design, or conduct, or reporting, or dissemination plans of this research.

Patient consent for publication Not applicable.

Ethics approval The study protocol adhered to the principles of the 1975 Declaration of Helsinki revised in 2013. This study was approved by the Research Ethics Committee of Hospital Universitario de Canarias (CHUC_2018_09 (V4)).

Provenance and peer review Not commissioned; externally peer reviewed.

Data availability statement Data are available on reasonable request.

Open access This is an open access article distributed in accordance with the Creative Commons Attribution Non Commercial (CC BY-NC 4.0) license, which permits others to distribute, remix, adapt, build upon this work non-commercially, and license their derivative works on different terms, provided the original work is properly cited, appropriate credit is given, any changes made indicated, and the use is non-commercial. See: <http://creativecommons.org/licenses/by-nc/4.0/>.

ORCID iD

Manuel Gonzalez de la Rosa <http://orcid.org/0000-0002-7543-0211>

REFERENCES

- Flammer J, Haefliger IO, Orgül S, *et al.* Vascular dysregulation: a principal risk factor for glaucomatous damage? *J Glaucoma* 1999;8:212–9.
- Piltz-seymour JR, Grunwald JE, Hariprasad SM, *et al.* Optic nerve blood flow is diminished in eyes of primary open-angle glaucoma suspects. *Am J Ophthalmol* 2001;132:63–9.
- Flammer J, Orgül S, Costa VP, *et al.* The impact of ocular blood flow in glaucoma. *Prog Retin Eye Res* 2002;21:359–93.
- Grieshaber MC, Flammer J. Blood flow in glaucoma. *Curr Opin Ophthalmol* 2005;16:79–83.
- Werne A, Harris A, Moore D. The circadian variations insystemic blood pressure, ocular perfusion pressure, and ocular lood flow: risk factors for glaucoma? *Surv Ophthalmol* 2008;53:559–67.
- Tezel G, Yang X, Luo C, *et al.* Hemoglobin expression and regulation in glaucoma: insights into retinal ganglion cell oxygenation. *Invest Ophthalmol Vis Sci* 2010;51:907–19.
- Venkataraman ST, Flanagan JG, Hudson C. Vascular reactivity of optic nerve head and retinal blood vessels in glaucoma--a review. *Microcirculation* 2010;17:568–81.
- Jia Y, Morrison JC, Tokayer J, *et al.* Quantitative OCT angiography of optic nerve head blood flow. *Biomed Opt Express* 2012;3:3127–37.
- Liu L, Jia Y, Takusagawa HL, *et al.* Optical coherence tomography angiography of the peripapillary retina in glaucoma. *JAMA Ophthalmol* 2015;133:1045–52.
- Jia Y, Wei E, Wang X, *et al.* Optical coherence tomography angiography of optic disc perfusion in glaucoma. *Ophthalmology* 2014;121:1322–32.
- Yarmohammadi A, Zangwill LM, Diniz-Filho A, *et al.* Relationship between optical coherence tomography angiography vessel density and severity of visual field loss in glaucoma. *Ophthalmology* 2016;123:2498–508.
- Manalastas PIC, Zangwill LM, Daga FB, *et al.* The association between macula and ONH optical coherence tomography angiography (OCT-A) vessel densities in glaucoma, glaucoma suspect, and healthy eyes. *J Glaucoma* 2018;27:227–32.
- Moghim S, Zangwill LM, Penteado RC, *et al.* Macular and optic nerve head vessel density and progressive retinal nerve fiber layer loss in glaucoma. *Ophthalmology* 2018;125:1720–8.
- Monteiro-Henriques I, Rocha-Sousa A, Barbosa-Breda J. Optical coherence tomography angiography changes in cardiovascular systemic diseases and risk factors: a review. *Acta Ophthalmol* 2022;100:e1–15.
- Gonzalez de la Rosa M, Gonzalez-Hernandez M, Sigut J, *et al.* Measuring hemoglobin levels in the optic nerve head: comparisons with other structural and functional parameters of glaucoma. *Invest Ophthalmol Vis Sci* 2013;54:482–9.
- Pena-Betancor C, Gonzalez-Hernandez M, Fumero-Batista F, *et al.* Estimation of the relative amount of hemoglobin in the cup and neuroretinal rim using stereoscopic color fundus images. *Invest Ophthalmol Vis Sci* 2015;56:1562–8.
- Gonzalez de la Rosa M, Gonzalez-Hernandez M, Mendez C. Glaucoma imaging: Measuring haemoglobin levels in the optic nerve head for glaucoma management. In: Ferreras A, ed. Heidelberg: Glaucoma Imaging, Springer, 2016: 265–80.
- Medina-Mesa E, Gonzalez-Hernandez M, Sigut J, *et al.* Estimating the amount of hemoglobin in the neuroretinal rim using color images and OCT. *Curr Eye Res* 2016;41:798–805.
- Gonzalez-Hernandez M, Sigut Saavedra J, Gonzalez de la Rosa M. Relationship between retinal nerve fiber layer thickness and hemoglobin present in the optic nerve head in glaucoma. *J Ophthalmol* 2017;2017:2340236.
- Gonzalez-Hernandez M, Gonzalez-Hernandez D, Perez-Barbudo D, *et al.* Fully automated colorimetric analysis of the optic nerve aided by deep learning and its association with perimetry and OCT for the study of glaucoma. *J Clin Med* 2021;10:3231.
- Wang X, Jiang C, Ko T, *et al.* Correlation between optic disc perfusion and glaucomatous severity in patients with open-angle glaucoma: an optical coherence tomography angiography study. *Graefes Arch Clin Exp Ophthalmol* 2015;253:1557–64.
- Miguel A, Silva A, Barbosa-Breda J, *et al.* OCT-angiography detects longitudinal microvascular changes in glaucoma: a systematic review. *Br J Ophthalmol* 2022;106:667–75.
- Zhang M, Jia F, Li N, *et al.* Quantitative analysis of the RPe vessel density and the RNFL thickness in patients with type 2 diabetes mellitus by using OCT angiography. *Ophthalmic Res* 2021;64:951–9.
- Dastiridou A, Kassos I, Samouilidou M, *et al.* Age and signal strength-related changes in vessel density in the choroid and the retina: an OCT angiography study of the macula and optic disc. *Acta Ophthalmol* 2022;100:e1095–102.



- 25 Brücher VC, Storp JJ, Eter N, *et al.* Optical coherence tomography angiography-derived flow density: a review of the influencing factors. *Graefes Arch Clin Exp Ophthalmol* 2020;258:701–10.
- 26 Allen L. Ocular fundus photography: suggestions for achieving consistently good pictures and Instructions for stereoscopic photography. *Am J Ophthalmol* 1964;57:13–28.
- 27 Thomson S. Retinal topography with the Heidelberg retina tomograph. *J Audiov Media Med* 1994;17:156–60.
- 28 Huang D, Swanson EA, Lin CP, *et al.* Optical coherence tomography. *Science* 1991;254:1178–81.
- 29 Mitchell P, Smith W, Chey T, *et al.* Open-angle glaucoma and diabetes: the blue mountains eye study, Australia. *Ophthalmology* 1997;104:712–8.
- 30 Bonovas S, Peponis V, Filioussi K. Diabetes mellitus as a risk factor for primary open-angle glaucoma: a meta-analysis. *Diabet Med* 2004;21:609–14.
- 31 Zhou M, Wang W, Huang W, *et al.* Diabetes mellitus as a risk factor for open-angle glaucoma: a systematic review and meta-analysis. *PLoS One* 2014;9:e102972.
- 32 Mendez-Hernandez C, Wang S, Arribas-Pardo P, *et al.* Diagnostic validity of optic nerve head colorimetric assessment and optical coherence tomography angiography in patients with glaucoma. *Br J Ophthalmol* 2021;105:957–63.