



Since January 2020 Elsevier has created a COVID-19 resource centre with free information in English and Mandarin on the novel coronavirus COVID-19. The COVID-19 resource centre is hosted on Elsevier Connect, the company's public news and information website.

Elsevier hereby grants permission to make all its COVID-19-related research that is available on the COVID-19 resource centre - including this research content - immediately available in PubMed Central and other publicly funded repositories, such as the WHO COVID database with rights for unrestricted research re-use and analyses in any form or by any means with acknowledgement of the original source. These permissions are granted for free by Elsevier for as long as the COVID-19 resource centre remains active.

BRESO 51435

Microglial cell response to neuronal degeneration in the brain of brindled mouse

Masaki Ohno, Yasuto Higashi and Kinuko Suzuki

Department of Pathology, University of North Carolina at Chapel Hill, Chapel Hill, NC 27599 (USA)

(Accepted 24 December 1991)

Key words: Neuronal degeneration; Microglia; Macrophage; Ia expression; Brindled mouse

Reactive changes of microglia in response to neuronal degeneration were investigated in the brains of brindled mottled mice with immunocytochemical technique. This mutant has a genetic defect in copper metabolism and spontaneous neuronal degeneration develops around postnatal day 10, in particular in the parasagittal regions of the cerebral cortex and thalamus. The antibodies to macrophage specific antigen, F4/80 and to type-three complement receptor, Mac-1 were used for the study. Reactive morphological changes of microglia, which are immuno-reactive to the antibodies to F4/80 and/or Mac-1, were demonstrated in areas corresponding to those of neuronal degeneration, coincident with the emergence of cells expressing major histocompatibility complex class II, Ia, antigen. Some of the Ia expressing cells had morphological features of ramified microglia, while others were rod shaped with few processes and were mostly located in the perivascular regions. The focal nature of such cellular changes suggests that signal(s) from the degenerating neurons may be responsible for microglial activation and cellular expression of the Ia antigen in the brain of the brindled mouse.

INTRODUCTION

Microglia, first described by del Rio-Hortega^{6,7} has been well recognized in human neurodegenerative lesions. For many years, there had been controversies as to the origin of microglia but by now it is generally accepted that microglia are cells of the monocyte lineage. More recently, microglia and brain macrophages have drawn the special attention of many investigators because of their presumed active roles in the Acquired Immune Deficiency Syndrome (AIDS), Alzheimer's disease and multiple sclerosis^{8,14,16,20,27,28,30}. Reactions of microglia to neuronal damage have been investigated experimentally in 6-hydroxydopamine-induced lesions in the substantia nigra¹ and in the facial nerve nuclei induced either by axotomy¹⁵ or by an intra-axonal injection of toxic ricin⁴³. However, the reactions of microglia to these experimentally induced lesions are temporal events and do not reflect the spontaneous and gradual neuronal degeneration seen in neurodegenerative diseases.

Spontaneous neuronal degeneration in the well defined areas of the cerebral cortex and thalamus is a neuropathological feature in the hemizygous brindled mottled mouse, an x-linked recessive mutant with a genetic defect in copper metabolism^{50,51}. In this murine mutant, neuronal degeneration gradually develops around the

postnatal day (P)10, and death usually occurs before reaching P15 with extensive neuronal degeneration. Chronological events of neuronal degeneration in this mutant have been studied in detail⁵⁰. Therefore, we investigated temporo-spatial microglial reactions to neuronal degeneration, caused by a metabolic perturbation using this mutant. We also investigated the effects of neonatal malnutrition (or starvation) on microglial reactions, since these mutant mice became markedly emaciated at the terminal stage. The results indicate that morphological alterations of microglia occurred regionally, coincident with neuronal degeneration. Also, as has been noted in several neurodegenerative diseases in humans²⁷ as well as in an experimentally induced neuronal injury⁴², major histocompatibility complex (MHC) class II antigen, Ia, expressing cells appeared in or in close vicinity to the site of neuronal degeneration. Some of these Ia expressing cells had distinct morphological features of ramified microglia but others were rod shaped with few processes resembling perivascular microglia²⁴.

MATERIALS AND METHODS

Mice

The mice used in the experiments were offsprings of a brindled heterozygous female (C3H/HeJ-MO^{br-1}/+) and a C57BL/6J male, originally from the Jackson Laboratory (Bar Harbor, Maine, USA). The colony of brindled mice was maintained by interbreeding of

the offspring. The mice were housed in constant temperature and under a 12 h light/dark cycle. A total of 23 hemizygous males and 21 littermate male controls was used for the study. They were killed at postnatal days (P)3, 5, 7, 10, 12 and 14.

A total of 7 normal littermate mice were used to examine the effects of malnutrition. Following the methods applied previously⁵⁰, normal pups were allowed to be fed only 6 h per day from P5 and killed at P8, 10 or 15. The body weights of these mice were comparable to those of hemizygous mice.

Tissue preparations

The mice were anesthetized with ethylether and were perfused briefly via the left cardiac ventricle with physiological saline, followed by a periodate-lysine-paraformaldehyde (PLP) fixative²⁹ for 10 min. The brains were removed immediately and immersed in the same fixative for 2 h and rinsed for 24–48 h in 0.1 M phosphate buffered saline (PBS), pH 7.4 containing 15% sucrose at 4°C. Coronal sections of the cerebrum, 30–50 μ m thick were cut serially with a vibratome and processed for immunocytochemistry.

Immunocytochemistry

The primary antibodies used were monoclonal antibodies against mouse Mac-1 (complement receptor, type three) antigen [MAB-Mac-1] (Boehringer Mannheim, Indianapolis, IN), macrophage specific antigen F4/80 [F4/80]³⁴ (Serotec, Oxford, UK), mouse Ia antigen [MAB-Ia] (Boehringer Mannheim, Indianapolis, IN) and glial fibrillary acidic protein [GFAP] (Dako, Carpinteria, CA). Biotinylated rabbit anti rat IgG (mouse adsorbed), avidin-biotin horseradish peroxidase complex kit (ABC-Elite kit) were purchased from the Vector Laboratory (Burlingame, CA).

The immunocytochemical procedures were essentially the same as reported previously¹⁹. In brief, the sections were incubated with primary antibodies overnight at 4°C and then sequentially incubated with biotinylated rabbit anti-rat IgG (1:100 in PBS) for 2 h at room temperature, and in 1% ABC-Elite reagent for 1 h. Primary antibodies were diluted with PBS (1:300 for F4/80; 1:500 for MAB-Mac-1; 1:300 for MAB-Ia). An antibody for GFAP was diluted at 1:20,000 with PBS containing 0.3% triton-X-100. After the first and second incubations, the sections were washed 3 times for 10 min each in the PBS and then developed with 0.05% diaminobenzidine (DAB) (Sigma, St Louis, MO) or DAB-nickel¹¹ in 0.1 M Tris buffer containing 0.01–0.005% hydrogen peroxide for 5 min. DAB reaction was intensified by incubating sections with a solution of 1% osmium tetroxide for 30 min. After being placed on the silane coated glass slides, the sections were dehydrated and mounted

with Permount (Fisher Scientific, Pittsburgh, PA). Control sections were incubated without primary antibody.

Immunoelectron microscopy

After immunocytochemical visualization with MAB-Mac-1 or MAB-Ia as stated above, the sections were dehydrated in graded concentrations of ethanol and embedded in poly/Bed 812 (Polyscience Inc, Warrington, PA). One μ m thick sections were stained with Toluidine blue and examined with a light microscope. Immuno-reactive cells were identified on the section and the block trimmed for thin sectioning. Ultrathin sections were lightly stained with lead citrate and uranyl acetate and examined with a Zeiss 10A electron microscope.

RESULTS

MAB-Mac-1 or F4/80 immuno-reactive cells (Mac-1 or F4/80 positive cells)

Normal control mice. In agreement with the previous report by Perry et al.³⁴, there were many F4/80 positive cells in the cerebrum of the mice younger than P7. Mac-1 positive cells were also identified but were very faintly stained in the brains of these young mice. On P3, many F4/80 positive cells had round cell bodies with a few processes (primitive microglia³²) or without processes (ameboid microglia) and were concentrated in the corpus callosum, paraventricular white matter and internal capsule. A few F4/80 positive ramified microglia were also recognized mostly in the cerebral cortex (Fig. 1A). Mac-1 and/or F4/80 positive ramified microglia increased but primitive microglia were still abundant in the cerebral cortex on P5. On P7, most of the F4/80 and/or Mac-1 positive cells in the gray matter were ramified microglia although a few ameboid and primitive microglia were still scattered in the superficial layers of the cerebral cortex. After P10, almost all Mac-1 positive cells had a shape of ramified microglia with well developed

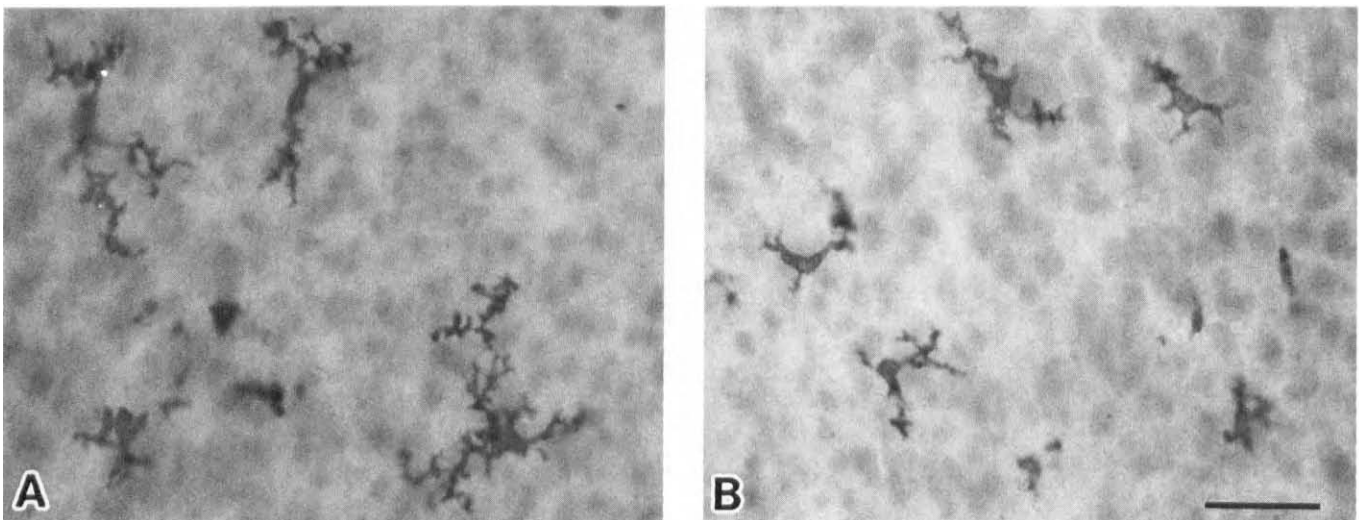


Fig. 1. F4/80 positive microglia in the cerebral cortices at postnatal day 5 (P5), control (A) and hemizygous (B) mice. The processes of microglia in the hemizygous brain (B) are not well developed. Parietal cortex. Bar = 50 μ m.

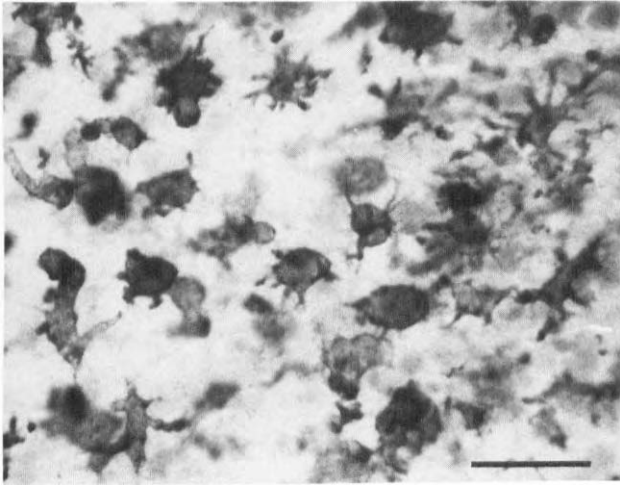


Fig. 2. Various types of Mac-1 positive cells seen in the cingulate cortex of hemizygous mouse at P14. Bar = 50 μ m.

delicate branching processes.

Brindled hemizygous mice. On P3 and 5, most of the F4/80 positive cells in the cerebrum were primitive microglia (Fig. 1B) but gradually ramified microglia increased in number. On P7, the morphology of both F4/80 positive and Mac-1 positive microglia in the cerebral cortex in hemizygous mice were similar to that of controls. However, after P10, Mac-1 positive cells with various morphological features (reactive microglia/macrophages) appeared in the cerebrum, in addition to the ramified microglia (Fig. 2). Some of these reactive microglia/macrophages were rod-shaped or round-shaped with only a few processes, while others had numerous convoluted thick processes suggestive of the transitional form from the ramified microglia. These reactive micro-


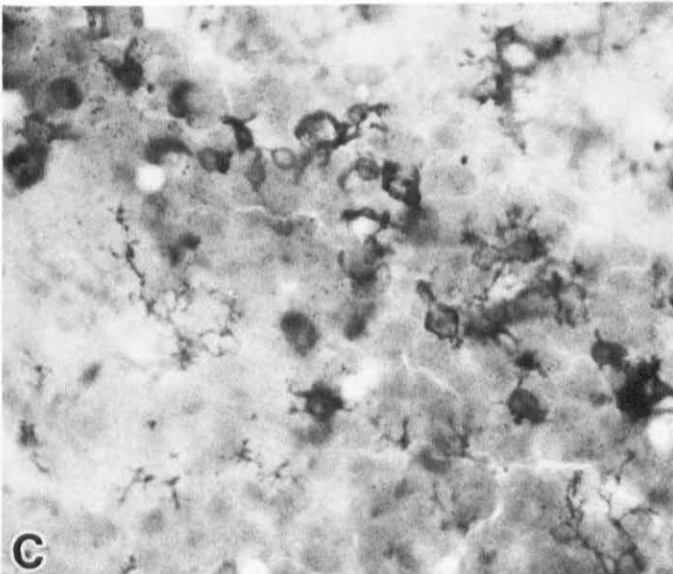

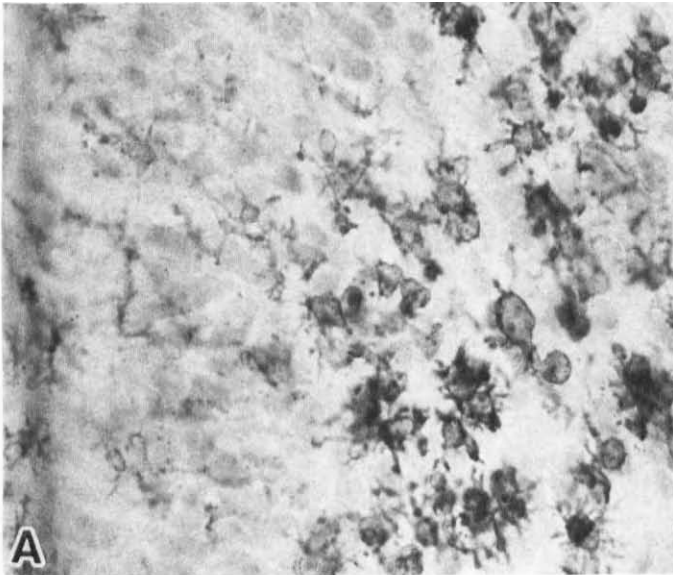


Fig. 3. Mac-1 positive reactive microglia/macrophages in the cerebrum of the hemizygous mouse at P10. Cingulate cortex (A), piriform cortex (B), hippocampus (C) and internal capsule (D). These reactive cells are well localized in the regions of neuronal degeneration. In the areas where degenerating neurons are not present, ramified microglia are well identified. Bar = 100 μ m.

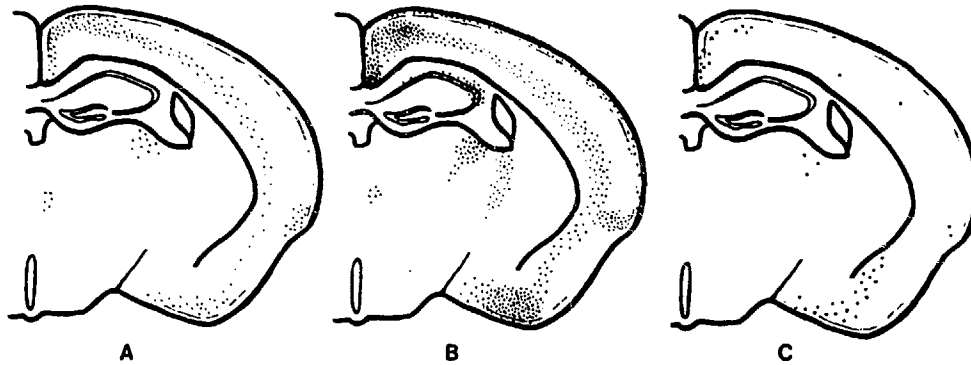


Fig. 4. Schematic drawings indicating the distribution of degenerating neurons (A), reactive microglia/macrophages (B) and Ia expressing cells (C) in the cerebri of hemizygous mice at P12 or P13.

glia/macrophages were most numerous in the cingulate cortex (Fig. 3A), cortex around the sulcus rhinalis, piriform cortex (Fig. 3B), hippocampus (Fig. 3C), lateral thalamus and the internal capsule (Fig. 3D). In the frontal and parietal cortices where a laminar pattern of neuronal degeneration was observed (Fig. 4A), these reactive microglia/macrophages were distributed in a well defined laminar pattern (Fig. 4B). Reactive microglia/macrophages were more numerous with intense immunoreactivity on P14 when neuronal degeneration was more advanced. At ultrastructural level, Mac-1 positive ramified microglia had slender processes and scant perikaryal cytoplasm and were often observed as perineuronal cells (Fig. 5A). Some degenerating neurons were surrounded by the processes of Mac-1 immuno-reactive cells (Fig. 5B), which sometimes contained electron-dense granular tissue debris.

Malnourished mice. There appeared to be some delay in differentiation of microglia in these mice and even on P10, primitive microglia were still well recognized in the cerebral cortex (data not shown). However, reactive microglia/macrophages were never seen in the cerebrum of these mice.

MAB-Ia immuno-reactive cells (Ia positive cells)

Normal control mice. Ia positive cells could be detected in the leptomeninges and choroid plexuses but rarely in the brains of control mice at any age. When they were found in the brain, they tended to be located adjacent to blood vessels.

Brindled hemizygous mice. Coincident with the emergence of reactive microglia/macrophages in the cerebrum, a considerable number of Ia positive cells were identified in the cingulate and piriform cortices and lateral thalamus where neuronal degeneration was most extensive. A few Ia positive cells were also noted in the hippocampus and basal ganglia (Fig. 4C). Some Ia positive cells had morphological features of ramified micro-

glia with delicate processes (Fig. 6), while others were rod-shaped (Fig. 7A). The former was predominantly found in the piriform cortex. The latter was located in the cingulate as well as in the piriform cortices. These rod-shaped Ia positive cells were often located in the perivascular region (Fig. 7B) although ultrastructural features of the nuclear chromatin pattern and perikarya of these cells were closely similar to those of Mac-1 positive perineuronal microglia (Fig. 5A). Ia positive cells were scattered in the leptomeninges over the cingulate and piriform cortices where some Ia positive cells were found in the subpial regions (Fig. 8).

Malnourished mice. Similar to control mice, only rare Ia positive cells were recognized in the perivascular regions in the brain.

Immunocytochemistry with anti-GFAP antibody

Astrocytes immuno-reactive with anti-GFAP antibody were recognized in the brains of both control and hemizygous mice. In the latter at P12, intensely immuno-reactive astrocytes tended to be present in laminar distribution corresponding to the site of neuronal degeneration (Fig. 4A). On P14, however, intensely immuno-reactive astrocytes were seen throughout all layers of the cerebral cortex. The immuno-reactivity was also enhanced on astrocytes in hippocampus, piriform cortex and internal capsule (data not shown) of the hemizygous mouse.

DISCUSSION

Our results show that the developmental patterns of microglial maturation and differentiation in the brindled hemizygous mice were closely similar, if not identical, to those of littermate control mice. In agreement with an earlier report by Perry et al.³⁴, we noted that immuno-reactivity of immature microglia to MAB-Mac-1 was very weak before P10. With age, immature microglia de-

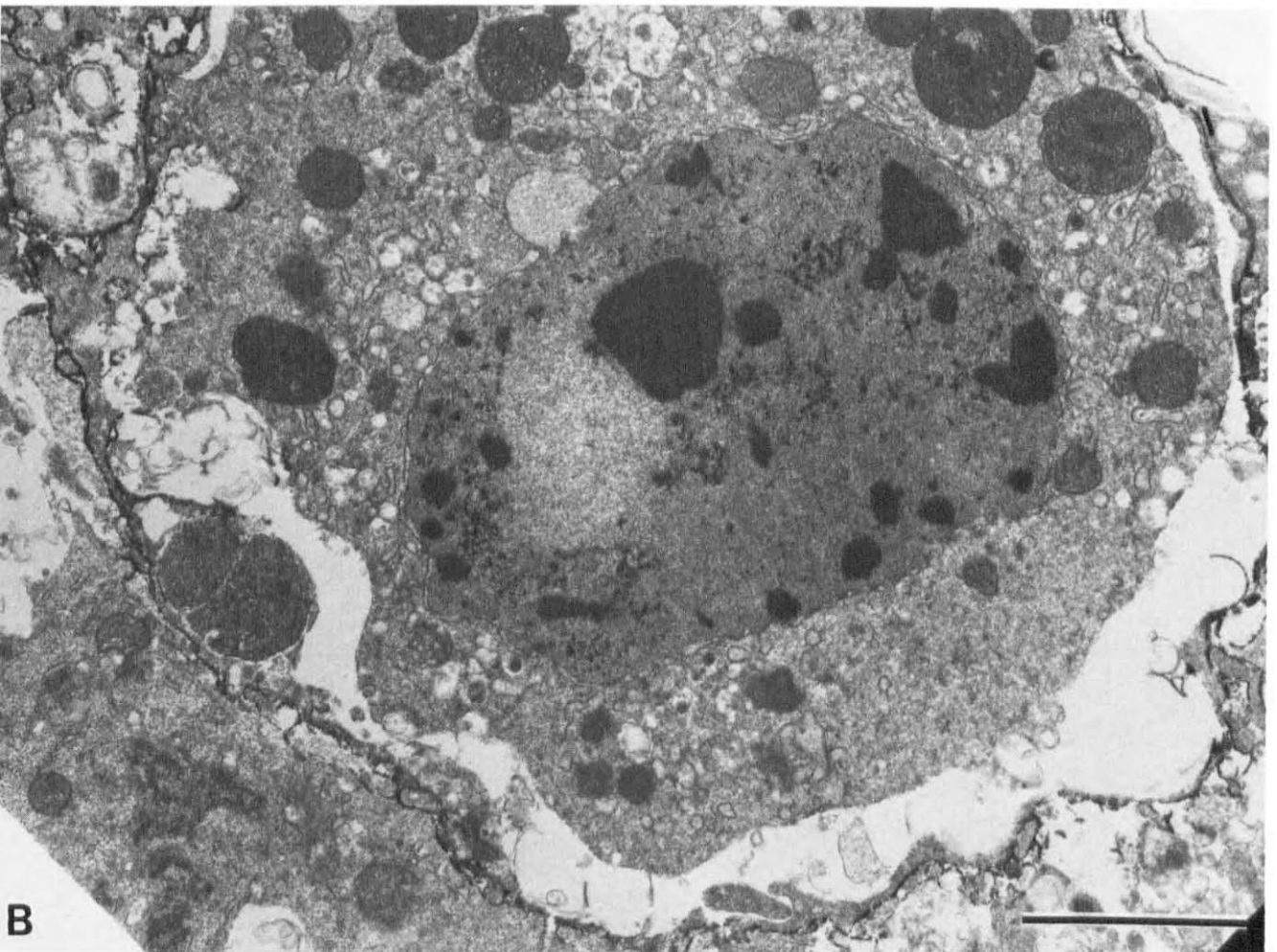
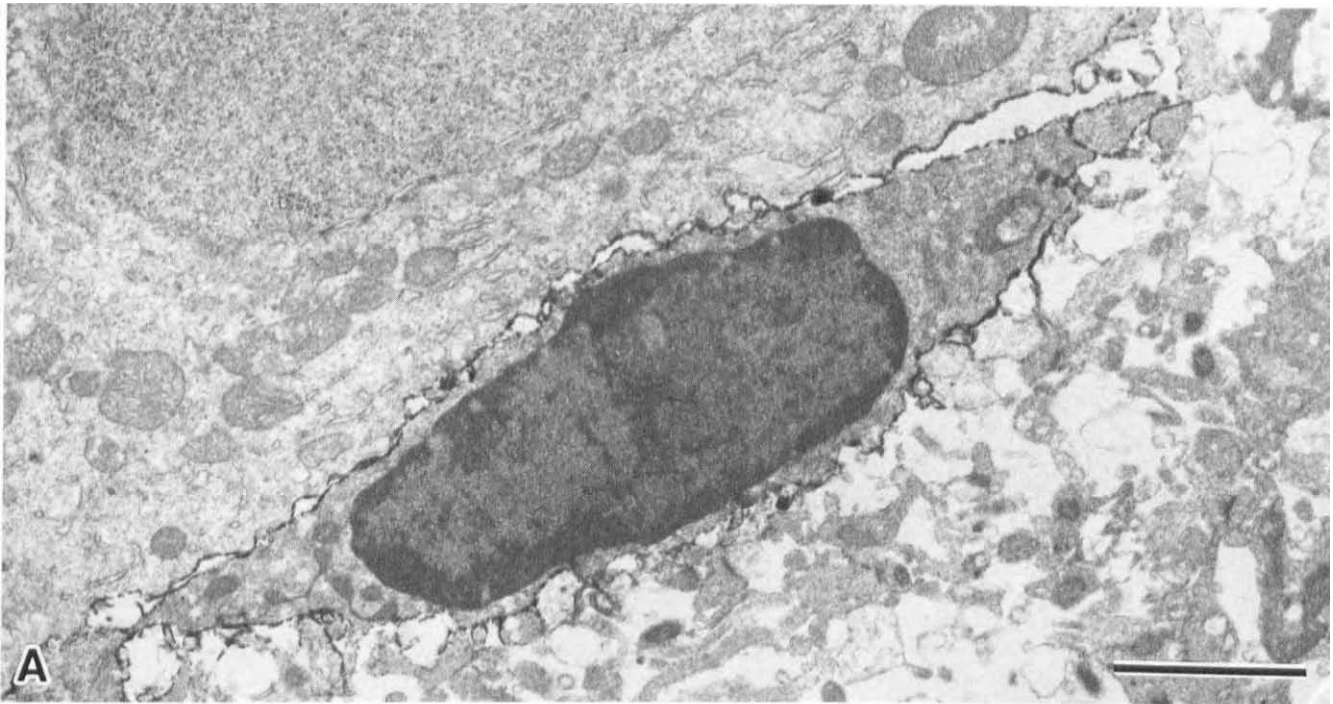


Fig. 5. A: an electron micrograph of a perineuronal microglia. Immuno-reactive product is well localized on its plasma membrane. MAb-Mac-1. Bar= 2 μ m. **B:** an electron micrograph of a degenerating neuron, surrounded by microglial processes. MAb-Mac-1. Bar= 2 μ m.




Fig. 6. Ia expressing ramified microglia in the piriform cortex of hemizygous mouse at P10. Bar = 50 μ m.

creased and Mac-1 positive ramified microglia increased. After P10, the majority of microglia in the brains of control mice were Mac-1 positive ramified microglia. In the brindled hemizygous mice, there appeared to be more immature microglia on P5 suggesting some delay in maturation but such a difference was no longer ap-

preciated on P7 when the majority of microglia were ramified in both hemizygous and control brains. After P10, with progression of neuronal degeneration, various shaped Mac-1 positive cells (reactive microglia/macrophages) emerged in the brains of brindled hemizygous mice. Morphological features of reactive microglia/macrophages described here were similar to those of cells described as activated, phagocytic or reactive microglia in other pathological conditions^{4,6,7,35,40}.

Our previous neuropathological study of brindled hemizygous mice showed that in the cingulate cortex early neuronal changes, as manifested by enlargement of mitochondria, became noticeable as early as P4 but neuronal degeneration was observed after P10^{50,51}. Mac-1 positive reactive microglia/macrophages appeared on P10 predominantly in the regions where neuronal degeneration was noted, suggesting that degenerating neurons release some signals or factors causing such morphological transformation of microglia. Our observation is in agreement with that of Streit and Kreutzberg who noted reactive changes of microglia in ricin injected facial nuclei only after irreversible neuronal damage had occurred⁴³.

The Mac-1 antigen is intimately associated with the type three complement receptor (CR3) on macrophages^{2,39} and mediates the attachment and phagocytosis of particles coated with C3bi by granulocytes and mac-

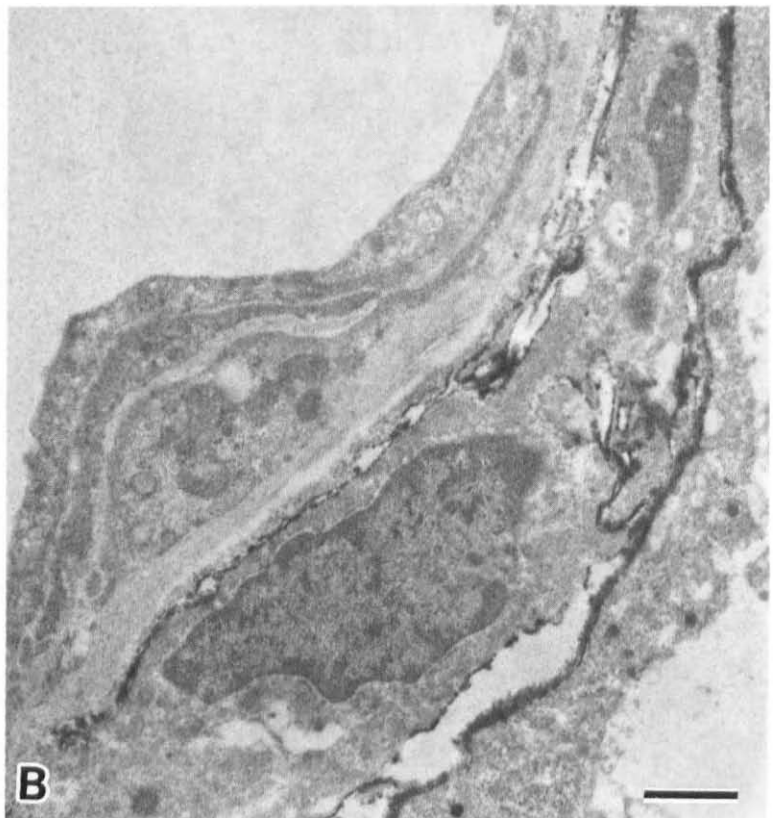
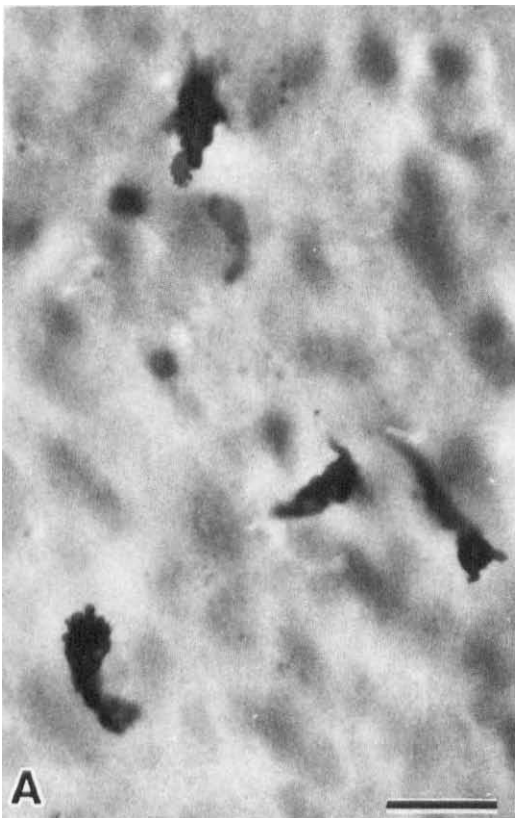

Fig. 7. A: Ia expressing rod-shaped cells in the cingulate cortex of hemizygous mouse at P14. Bar = 25 μ m. B: an electron micrograph of an Ia expressing cell in the perivascular region. Bar = 1 μ m.

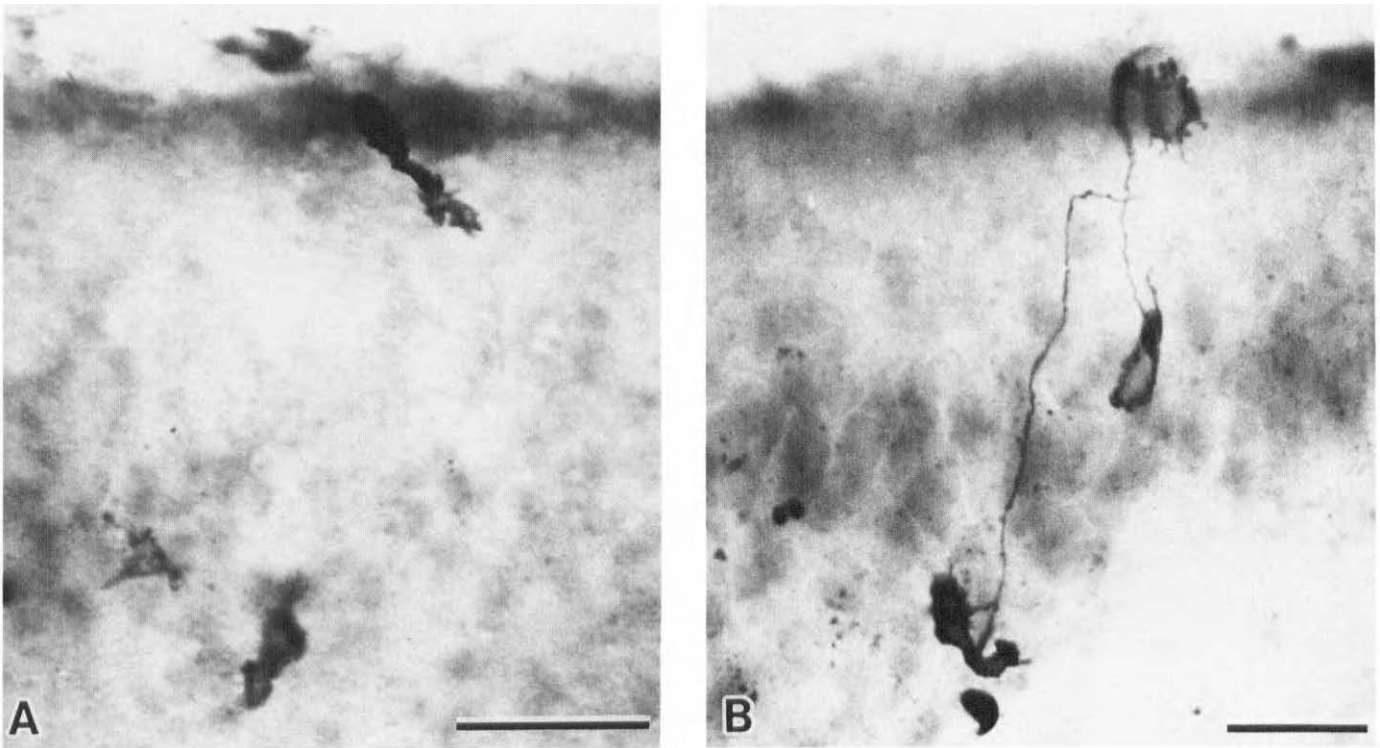


Fig. 8. Ia expressing cells in the pial and subpial regions in the cingulate cortex of hemizygous mouse. A: P12, Bar = 50 μm . B: P14, Bar = 25 μm .

rophages⁴⁹. It also appears to play an important role in adhesion dependent functions such as granulocyte chemotaxis, adherence to surface and aggregation³⁹. Thus, the pronounced immuno-reactivity of these reactive microglia/macrophages with MAb-Mac-1 may indicate elevated cellular functions that include phagocytic, secretory or adhesive capacities^{5,15,39,49}.

Although mechanisms and/or regulation of microglial transformations *in vivo* are not well understood, several factors such as gamma interferon, the interleukins and granulocytes/macrophage colony stimulating factor (G/M-CSF) are known to induce microglial transformations *in vitro*^{10,12,46}. More recently Giulian et al. found two microglial growth factors in the cerebral cortex of rat between embryonic day E-16 and postnatal day PN-1 and in the injured brain tissue¹³. These authors found that one of them, MM₁, stimulated proliferation of mononuclear phagocytes from bone marrow but not the other, MM₂. Interestingly, when the activities of these growth factors were monitored using astrocytes *in vitro*, they found that astrocytes did not secrete MM₁. Thus, their result suggests that the cells, other than astrocytes, may be responsible for the stimulation of mononuclear phagocytes.

Shafit-Zagardo et al. reported intensely GFAP immuno-reactive astrocytes throughout the cortex in the hemizygous brindled mouse on P15³⁷. When we studied

GFAP immuno-reactivity of astrocytes on P12, preferential distribution of strongly immuno-reactive astrocytes was recognized in the areas corresponding to neuronal degeneration. This result also suggests that astrocytes may be regionally activated by degenerating neurons or by activated microglia.

In the areas of neuronal degeneration in the brain of the hemizygous mouse, major histocompatibility complex class II antigen, Ia, expressing cells were observed. Many of them were rod shaped but some were morphologically identical to ramified microglia. Some rod shaped Ia positive cells were located in the subarachnoid space and also in the subpial region of cingulate cortex where neuronal degeneration was most extensive, suggesting penetration of Ia positive cells into the brain parenchyma through the pia-arachnoid in response to signals derived from degenerating neurons. Some Ia immuno-reactive cells had morphological features of ramified microglia. Whether rod shaped Ia immuno-reactive cells transformed to ramified microglia or Ia expression was induced in ramified microglia is yet to be studied.

Ia expressing cells have been considered to play an important role in the initiation of cellular immune response^{3,48}. In the central nervous system, Ia expression was reported in varieties of cell types including microglia^{18,26,38,44,47} and was thought to be related to immuno-mediated disease processes such as multiple sclerosis, ex-

perimental allergic encephalomyelitis (EAE), experimental allergic neuritis (EAN), etc. However, more recently, Ia expression has been reported in microglia in neurodegenerative diseases such as Parkinson's disease and Alzheimer's disease²⁷ and in animals following axotomy^{41,42} or Wallerian degeneration²³. We have seen many Ia expressing cells in the brain and peripheral nerves of the twitcher mouse, an authentic murine model of the metabolic demyelinating disorder Krabbe's disease in humans¹⁹.

These recent observations of Ia expression in apparently non-immune mediated diseases suggest some additional role of Ia molecule in cellular degeneration. Alternatively, it is possible that some immunological mechanisms are involved in cellular degeneration in these pathological conditions in humans as well as in experimental animals. In the twitcher mouse with major pathological changes in the white matter, Ia expressing cells were more numerous in the white matter¹⁹, while in the brindled mouse with pronounced neuronal degeneration, Ia expressing cells were found strictly in the gray matter. These observations suggest that Ia expression is reg-

ulated by local pathological processes. Ia antigen expression could be induced by gamma interferon in vivo³¹ and in vitro^{36,45}, and systemic treatment with interferon gamma alone or in combination with tumor necrosis factor alpha causes microglial cell processes to express class I and class II MHC antigens¹⁷. Gamma-interferon-like immunoreactivity has been shown to be present in certain neurons of the central and peripheral nervous system in normal animals^{9,22,25}. More recently, transient expression of gamma-interferon-like immunoreactivity has been demonstrated in the axotomized rat motor neurons³³. Therefore, it is possible that gamma-interferon-like immunoreactivity may be expressed in the degenerating neurons in the brindled mouse, although the expression of such immuno-reactivity by neurons may not be necessarily related to the Ia induction in non-neuronal cells²¹.

Acknowledgements. This work was supported in part by U.S.P.H.S. grants NS-24453, HD-03110 and ES-01104. The authors thank Ms. Clarita Langaman for tissue preparation for electron microscopy, Ms. Deborah Langford for photographic work and Ms. Deborah Sears for manuscript preparation.

REFERENCES

- Akiyama, H. and McGeer, P.L., Microglial response to 6-hydroxydopamine-induced substantia nigra lesions, *Brain Res.*, 489 (1989) 247-253.
- Beller, D.I., Springer, T.A. and Schreiber, R.D., Anti-Mac-1 selectively inhibits the mouse and human type three complement receptor, *J. Exp. Med.*, 156 (1982) 1000-1009.
- Benacerraf, B., Role of MHC gene production in immune regulation, *Science*, 212 (1981) 1229-1238.
- Brück, W. and Friede, R.L., Anti-macrophage CR3 antibody blocks myelin phagocytosis by macrophages in vitro, *Acta Neuropathol. (Berl.)*, 80 (1990) 415-418.
- Colton, C.A. and Gilbert, D.L., Production of superoxide anions by a CNS macrophage, the microglia, *FEBS Lett.*, 223 (1987) 284-288.
- del Rio-Hortega, P., El 'tercer elemento' de los centros nerviosos. I. La microglia en estado normal. II. Intervencion de la microglia en los procesos pathologicos. III. Naturaleza probable de la microglia, *Bol. Soc. Esp. Biol.*, 9 (1919) 68-120.
- del Rio-Hortega, P., Microglia. In W. Penfield (Ed.), *Cytology and Cellular Pathology of the Nervous System*, Vol. 2, Paul B. Hoeber, New York, 1932, pp. 481-534.
- Dickson, D.W., Mattiace, L.A., Kure, K., Huchins, K., Lyman, W.D. and Brosnan, C.F., Biology of disease. Microglia in human disease, with an emphasis on acquired immune deficiency syndrome, *Lab. Invest.*, 64 (1991) 135-156.
- Eneroth, A., Kristensson, K., Ljungdahl, A. and Olsson, T., Interferon- γ -like-immunoreactivity in developing rat spinal ganglia neurons in vivo and in vitro, *J. Neurocytol.*, 20 (1991) 225-231.
- Frei, K., Bodmer, S., Schwerdel, C. and Fontana, A., Astrocyte-derived interleukin 3 as a growth factor for microglia cells and peritoneal macrophages, *J. Immunol.*, 137 (1986) 3521-3527.
- Fujimiya, M., Kimura, H. and Maeda, T., Postnatal development of serotonin nerve fibers in the somatosensory cortex of mice studied by immunocytochemistry, *J. Comp. Neurol.*, 246 (1986) 191-201.
- Giulian, D. and Ingeman, J.E., Colony-stimulating factors as promoters of ameboid microglia, *J. Neurosci.*, 8 (1988) 4707-4717.
- Giulian, D., Johnson, B., Krebs, J.F., George, J.K. and Tapscott, M., Microglial mitogens are produced in the developing and injured mammalian brain, *J. Cell Biol.*, 112 (1991) 323-333.
- Graeber, M.B. and Streit, W.J., Microglia: immune network in the CNS, *Brain Pathol.*, 1 (1990) 2-5.
- Graeber, M.B., Streit, W.J. and Kreutzberg, G.W., Axotomy of the rat facial nerve leads to increased CR3 complement receptor expression by activated microglial cells, *J. Neurosci. Res.*, 21 (1988) 18-24.
- Hayashi, T., Morimoto, C., Burks, J.S., Kerr, C. and Hauser, S.L., Dual label immunocytochemistry of the active multiple sclerosis lesions; major histocompatibility complex and activation antigens, *Ann. Neurol.*, 24 (1988) 523-531.
- Hickey, W.F., T-lymphocyte entry and antigen recognition in the central nervous system. In R. Ader, N. Cohen and D. Felten, (Eds.), *Psychoneuroimmunology II.*, Academic Press, San Diego, 1990, pp. 149-175.
- Hickey, W.F., Osborn, J.P. and Kirby, W.M., Expression of Ia molecules by astrocytes during acute experimental allergic encephalomyelitis in the Lewis rat, *Cell Immunol.*, 91 (1985) 528-535.
- Higashi, Y., Komiyama, A. and Suzuki, K., The twitcher mouse: immunocytochemical study of Ia expression in macrophages, *J. Neuropathol. Exp. Neurol.*, 51 (1992) 47-57.
- Itagaki, S., McGeer, P.L., Akiyama, H., Zhu, S. and Selkoe, D., Relationships of microglia and astrocytes to amyloid deposits of Alzheimer's disease, *J. Neuroimmunol.*, 24 (1989) 173-182.
- Kiefer, R., Haas, A. and Kreutzberg, G.W., Gamma interferon-like immunoreactive material in rat neurons: evidence against a close relationship to gamma interferon, *Neuroscience*, 45 (1991) 551-560.
- Kiefer, R. and Kreutzberg, G.W., Gamma interferon-like immuno-reactivity in the rat nervous system, *Neuroscience*, 37 (1990) 725-734.
- Konno, H., Yamamoto, T., Iwasaki, Y., Suzuki, H., Saitoh, T.

- and Terunuma, H., Wallerian degeneration induces Ia-antigen expression in the rat brain, *J. Neuroimmunol.*, 25 (1989) 151-159.
- 24 Lassmann, H., Zimprich, F., Vass, K. and Hickey, W.F., Microglial cells are a component of the perivascular glia limitans, *J. Neurosci. Res.*, 28 (1991) 236-243.
 - 25 Ljungdahl, Å., Olsson, T., Van der Meide, P.H., Holmdahl, R., Klareskog, L. and Höjeberg, B., Interferon-gamma-like immuno-reactivity in certain neurons of the central and peripheral nervous system, *J. Neurosci. Res.*, 24 (1989) 451-456.
 - 26 Male, D.R., Pryce, G. and Hughes, C.C.W., Antigen presentation in the brain: MHC induction on brain endothelium and astrocytes compared, *Immunology*, 60 (1987) 453-459.
 - 27 McGeer, P.L., Itagaki, S., Boyes, B.E. and McGeer, E.G., Reactive microglia are positive for HLA-DR in the substantia nigra of Parkinson's and Alzheimer's disease brains, *Neurology*, 38 (1988) 1285-1291.
 - 28 McGeer, P.L., Itagaki, S. and McGeer, E.G., Expression of the histocompatibility glycoprotein HLA-DR in neurological disease, *Acta Neuropathol.*, 76 (1988) 550-557.
 - 29 McLean, I.W. and Nakane, P.K., Periodate-lysine-paraformaldehyde fixative, a new fixative for immunoelectron microscopy, *J. Histochem. Cytochem.*, 22 (1974) 1077-1083.
 - 30 Michaels, J., Price, R.W. and Rosenblum, M.K., Microglia in the giant cell encephalitis of acquired immune deficiency syndrome: proliferation, infection and fusion, *Acta Neuropathol. (Berl.)*, 76 (1988) 373-379.
 - 31 Momburg, F., Koch, N., Moller, P., Moldenhauer, G., Butcher, G.W. and Hammerling, G.J., Differential expression of Ia and Ia-associated invariant chain in mouse tissue after in vivo treatment with IFN- γ , *J. Immunol.*, 136 (1983) 940-948.
 - 32 Murabe, Y. and Sano, Y., Morphological studies on neuroglia. VI. Postnatal development of microglial cells, *Cell Tissue Res.*, 225 (1982) 469-485.
 - 33 Olsson, T., Kristensson, K., Ljungdahl, Å., Maehlen, J., Holmdahl, R. and Klareskog, L., Gamma-interferon-like immuno-reactivity in axotomized rat motor neurons, *J. Neurosci.*, 9 (1989) 3870-3875.
 - 34 Perry, V.H., Hume, D.A. and Gordon, S., Immunohistochemical localization of macrophages and microglia in the adult and developing mouse brain, *Neuroscience*, 15 (1985) 313-326.
 - 35 Polak, M., D'Amelio, F., Johnson, J.E. and Haymaker, W., Microglial cells: origins and reactions. In W. Haymaker and R.D. Adams (Eds.), *Histology and Histopathology of the Nervous System*, Charles C. Thomas, Springfield, 1982, pp. 481-559.
 - 36 Sasaki, A., Levison, S.W. and Ting, J.P.Y., Comparison and quantitation of Ia antigen expression on cultured macroglia and ameboid microglia from Lewis rat cerebral cortex: analyses and implications, *J. Neuroimmunol.*, 25 (1989) 63-74.
 - 37 Shafit-Zagardo, B., Peterson, C. and Goldman, J.E., Rapid increases in glial fibrillary acidic protein mRNA and protein levels in the copper-deficient brindled mouse, *J. Neurochem.*, 51 (1988) 1258-1266.
 - 38 Sobel, R.A., Blachette, B.W., Bhan, A.K. and Colvin, R.B., The immunopathology of experimental allergic encephalomyelitis. II. Endothelial cell Ia increases prior to inflammatory cell infiltration, *J. Immunol.*, 132 (1984) 2402-2407.
 - 39 Springer, T.A. and Anderson, D.C., Leukocyte complement receptors and adhesion proteins in the inflammatory response: insights from an experiment of nature, *Biochem. Soc. Symp.*, 51 (1986) 47-57.
 - 40 Streit, W.J., Graeber, M.B. and Kreutzberg, G.W., Functional plasticity of microglia: a review, *Glia*, 1 (1988) 301-307.
 - 41 Streit, W.J., Graeber, M.B. and Kreutzberg, G.W., Expression of Ia antigen on perivascular and microglial cells after sublethal and lethal motor neuron injury, *Exp. Neurol.*, 105 (1989) 115-126.
 - 42 Streit, W.J., Graeber, M.B. and Kreutzberg, G.W., Peripheral nerve lesion produces increased levels of major histocompatibility complex antigens in the central nervous system, *J. Neuroimmunol.*, 25 (1989) 117-123.
 - 43 Streit, W.J. and Kreutzberg, G.W., Response of endogenous glial cells to motor neuron degeneration induced by toxic ricin, *J. Comp. Neurol.*, 268 (1988) 248-263.
 - 44 Suzumura, A., Lavi, E., Weiss, S.R. and Silberberg, D.H., Coronavirus infection induces H-2 antigen expression on oligodendrocytes and astrocytes, *Science*, 232 (1986) 991-993.
 - 45 Suzumura, A., Mezitiz, S.G.E., Gonatas, N.K. and Silberberg, D.H., MHC antigen expression on bulk isolated macrophage-microglia from newborn mouse brain: induction of Ia antigen expression by gamma-interferon, *J. Neuroimmunol.*, 15 (1987) 263-278.
 - 46 Suzumura, A., Sawada, M., Yamamoto, H. and Marunouchi, T., Effects of colony stimulating factors on isolated microglia in vitro, *J. Neuroimmunol.*, 30 (1990) 111-120.
 - 47 Ting, J-P., Shigekawa, Y., Linthicum, S., Weiner, L.P. and Frelinger, J.A., Expression and synthesis of murine immune response-associated (Ia) antigen by brain cells, *Proc. Natl. Acad. Sci. USA*, 78 (1981) 3170-3174.
 - 48 Unanue, E.R., Antigen-presenting function of the macrophages, *Annu. Rev. Immunol.*, 2 (1984) 395-428.
 - 49 Wright, S.D., Rao, P.E., Van Voorhis, W.C., Craigmyle, L.S., Iida, K., Talle, M.A., Westberg, E.F., Goldstein, G. and Silverstein, S.C., Identification of C3bi receptor of human monocytes and macrophages by using monoclonal antibodies, *Proc. Natl. Acad. Sci. USA*, 80 (1983) 5699-5703.
 - 50 Yajima, K. and Suzuki, K., Neuronal degeneration in the brain of the brindled mouse. A light microscope study, *J. Neuropathol. Exp. Neurol.*, 38 (1979) 35-46.
 - 51 Yajima, K. and Suzuki, K., Neuronal degeneration in the brain of the brindled mouse. An ultrastructural study of the cerebral cortical neurons, *Acta Neuropathol. (Berl.)*, 45 (1979) 17-25.