

The Curious Case of an Elusive Solitary Plaque

Abstract

A 60-year-old male patient presented with a solitary pink plaque over the inner aspect of the left forearm of 4 years duration. The lesion was persistent and unresponsive to treatment. A skin biopsy was done with differential diagnosis of lupus vulgaris, tuberculoid leprosy, and granuloma annulare. Histopathology revealed features suggestive of morphea and the patient was treated accordingly. Despite treatment, the lesion continued to grow in size and a repeat biopsy was done as clinical doubt regarding the diagnosis persisted. Dermoscopy, KOH wet mount, and histopathology revealed characteristic features that clinched the diagnosis and aided in correct management of the patient with complete clearance of lesion after 4 months of therapy.

Keywords: Dermoscopy, histopathology, solitary plaque

Clinical Findings

A 60-year-old male patient presented with a solitary pink colored skin lesion over the inner aspect of the left forearm of 4 years duration. The lesion started as a small pea-sized eruption and progressed gradually to increase in size and assumed an annular pattern. There was a history of occasional itching. The patient could not recall any history of trauma and had been treated with various topical agents (mostly steroids), exact details of which were unavailable. There was no history of any other significant illness. Examination revealed multiple tiny erythematous papules coalescing together in an annular pattern to form a plaque with relative central clearing and pseudopod like extensions into the surrounding normal skin on the flexor aspect of the left forearm [Figure 1a]. Systemic examination was within normal limits. Granuloma annulare, tuberculoid leprosy, and lupus vulgaris were considered as differentials. All routine investigations were found to be normal. The Mantoux test was negative. A skin biopsy revealed sparse superficial and deep perivascular lymphocytic infiltrate, flattening of epidermal rete pattern and thinning of reticular dermal collagen placed parallel to surface epidermis with sweat units present in the mid-reticular dermis [Figure 1b].

This is an open access journal, and articles are distributed under the terms of the Creative Commons Attribution-NonCommercial-ShareAlike 4.0 License, which allows others to remix, tweak, and build upon the work non-commercially, as long as appropriate credit is given and the new creations are licensed under the identical terms.

For reprints contact: reprints@medknow.com

A histopathological diagnosis of morphea was made and a deeper biopsy was suggested if diagnostic doubt persisted. The patient over the next 4 months was treated with a topical tacrolimus 0.1% ointment and a topical calcipotriol 0.005% ointment.

The lesion continued to grow in size without any signs of improvement. Erythematous to violaceous nodules coalescing to form a plaque were seen with yellowish crusting, brown spots, and scaling [Figure 2a]. Clinical doubt regarding the diagnosis persisted and a repeat biopsy was done with a differential of lupus vulgaris and subcutaneous fungal infection. Dermoscopy of the lesion revealed a white net-like pattern in the background with structureless pink, white, and yellow areas. The lesion was studded with scales, crusts, and reddish-brown to black dots [Figure 2b]. A KOH mount from the lesion showed multiple brown colored, septate sclerotic bodies [Figure 2c]. Histopathology revealed upper and mid-dermal nodular dense tuberculoid and suppurative granulomatous infiltrate composed of lymphocytes, plasma cells, histiocytes, and epithelioid cells with occasional Langhans giant cells and small collection of neutrophils. Epidermis showed moderate spongiotic psoriasiform change. Clusters of thick-walled brown colored refractile yeast cells were seen within some giant cells and extracellularly [Figure 2d].

How to cite this article: Katoch S, Barua TN, Barua KN. The curious case of an elusive solitary plaque. Indian Dermatol Online J 2020;11:288-90.

Received: September, 2019. **Accepted:** November, 2019.
Published: March, 2020.

Saloni Katoch,
Taranga N. Barua,
Khagendra N. Barua

Department of Dermatology,
Venereology, and Leprosy,
Dr. KN Barua Institute of
Dermatological Sciences,
Guwahati, Assam, India

Address for correspondence:

Dr. Saloni Katoch,
Dr. KN Barua Institute of
Dermatological Sciences,
Guwahati - 781 005, Assam,
India.
E-mail: saloni.katoch@gmail.
com

Access this article online

Website: www.idoj.in

DOI: 10.4103/idoj.IDOJ_457_19

Quick Response Code:



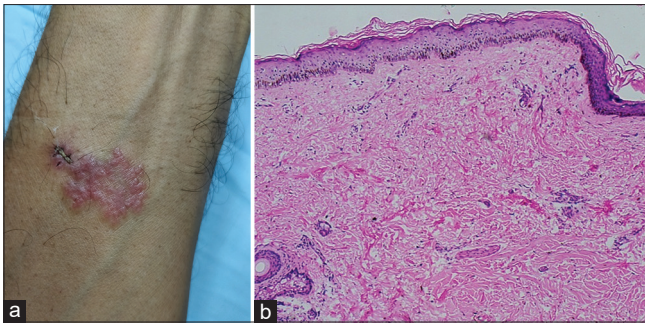


Figure 1: (a): Multiple erythematous papules coalescing to form a plaque with central clearing in an annular pattern on the flexor aspect of the left forearm. (b): Flattening of the rete ridges, sparse superficial and deep lymphohistiocytic infiltrate and reticular collagen thinned at places, arranged parallel to the surface epidermis suggestive of morphea (H and E 100×)

What Is Your Diagnosis?

Chromoblastomycosis.

Clinical Course

The patient was started on oral itraconazole 200 mg daily along with biweekly sessions of cryotherapy. As the treatment progressed the reddish-brown dots disappeared and the lesion regressed completely after 4 months of treatment [Figure 3]. The patient's liver and renal parameters were monitored regularly while he was on oral itraconazole.

Discussion

Chromoblastomycosis is a chronic, granulomatous cutaneous and subcutaneous fungal infection caused by pigmented dematiaceous fungi. It is primarily a tropical or subtropical disease with the most common etiological agent being *Fonsecaea pedrosoi*, *Phialophora verrucosa*, and *Cladophialophora carrionii*.^[1] This disease can be a diagnostic and therapeutic challenge for dermatologists with its polymorphic presentation, variable response to treatment and frequent relapses. The lesions are mainly seen over the extremities due to traumatic inoculation from an environmental source. The initial lesions are usually smooth pink-colored papules which gradually increase in size and become scaly. As time passes, a more polymorphic clinical picture develops which may be associated with itching. As a result of transepithelial elimination, small hematic crusts with cellular debris and fungal elements may be visible as black dots over the lesion. The various clinical types described are nodular, plaque-type, tumoral, cicatricial, and verrucous. Lesions can also be graded based on severity as mild (solitary nodule or plaque less than 5 cm in diameter), moderate (nodular, verrucous or plaque-type measuring less than 15 cm in diameter), and severe (any type of lesion covering extensive cutaneous regions).^[2] Our patient's presentation was primarily that of the plaque type, though papules and nodules were also

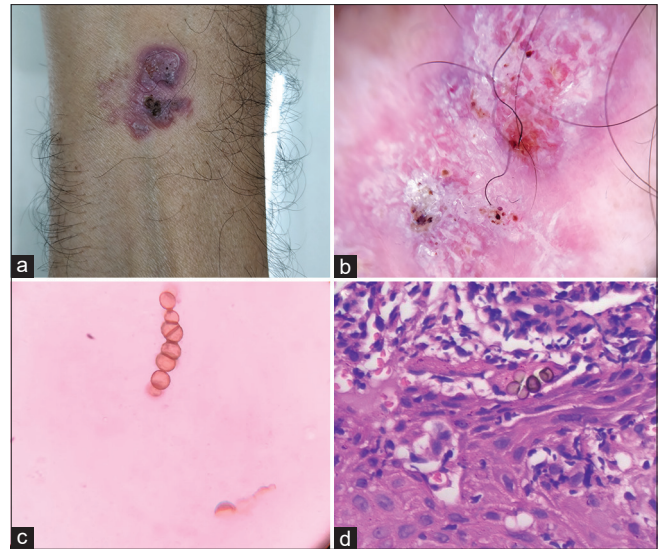


Figure 2: (a): Erythematous to violaceous papules and nodules studded with brown to black hemorrhagic crusts and scaling. (b): Dermoscopy revealed a pink and white background with a white net-like pattern with polymorphous blood vessels, multiple red-brown to black dots, scaling and crusting (DermLite DL4, 10×, Polarized mode). (c): KOH wet mount of the overlying crusts show multiple brown colored, septate medlar bodies. (d): Cluster of thick-walled refractile yeast cells, "Cluster of pennies appearance" seen on repeat biopsy (H and E 400×)

present through the various stages of clinical evolution. The severity was graded as mild as the lesion was less than 5 cm in diameter.

Diagnosis of chromoblastomycosis is confirmed by the presence of muriform cells in the tissue and identification of the causal agent in culture. Direct microscopic KOH wet mount examination reveals brown colored, thick-walled muriform cells known by various names such as medlar bodies, copper pennies, chromo or fumagoid bodies, and sclerotic cells.^[3] The presence of reddish-brown and black dots corresponding to the fungal sclerotic bodies and hemorrhage are the most useful dermoscopic feature in diagnosing this infection. Other dermoscopic findings include the white net-like pattern with polymorphous vessels, crusts, scaling and structureless pink, white and yellow areas. A dermoscopic examination may aid in the diagnosis wherein clinical signs are subtle. Histopathology shows pseudoepitheliomatous hyperplasia with intraepidermal abscess and granulomatous inflammation in the dermis with epithelioid histiocytes and multinucleated giant cells containing medlar bodies. Septate, brown, oval-to-round, thick-walled sclerotic bodies (cluster of pennies appearance) can be seen both intracellularly and lying freely in the dermis on higher magnification.^[4,5] Treatment includes high doses of itraconazole (200–400 mg/day) or terbinafine (500 mg/day) with or without physical modalities like cryotherapy, thermotherapy, and surgical excision.^[1-3,5,6]

The average time between the occurrence of the disease and diagnosis was reported as 14 years.^[7] Due to the

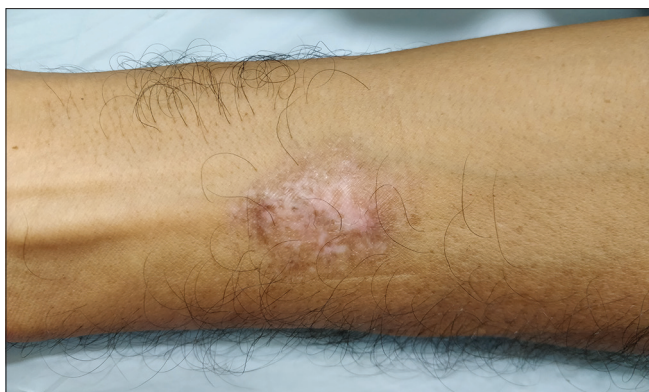

Figure 3: Complete regression of the lesion after 4 months of treatment

polymorphous nature of the presentation, the clinical picture can be misleading and differentials can include other fungal infections such as fixed sporotrichosis, bacterial infections like cutaneous tuberculosis, leprosy, actinomycetoma, mycobacteriosis, and others like cutaneous leishmaniasis, verrucae, squamous cell carcinoma, psoriasis, sarcoidosis, and Bowen's disease.^[3] Our patient was diagnosed with chromoblastomycosis after a period of 4 years. The initial biopsy findings suggestive of morphea could be attributed to scarring sometimes seen in the plaque and cicatricial types or in a previously healed area of this chronic fungal infection. The clinical morphology of the lesion could also have been modified due to the use of various topical medications. Furthermore, this case highlights that differentials for a solitary plaque should include infections (deep fungal, mycobacterial, atypical mycobacterial, and leishmaniasis), cutaneous tumors, granuloma annulare, and other inflammatory skin conditions. Our patient responded well to treatment as he was immunocompetent and the lesion was localized and mild in severity.

Declaration of patient consent

The authors certify that they have obtained all appropriate patient consent forms. In the form the patient(s) has/have given his/her/their consent for his/her/their images and other clinical information to be reported in the journal. The patients understand that their names and initials will not be published and due efforts will be made to conceal their identity, but anonymity cannot be guaranteed.

Financial support and sponsorship

Nil.

Conflicts of interest

There are no conflicts of interest.

References

1. Krzyściak PM, Pindycka-Piaszczyńska M, Piaszczyński M. Chromoblastomycosis. *Postępy Dermatol Alergol* 2014;31:310-21.
2. Queiroz-Telles F, Esterre P, Perez-Blanco M, Vitale RG, Salgado CG, Bonifaz A. Chromoblastomycosis: An overview of clinical manifestations, diagnosis and treatment. *Med Mycol* 2009;47:3-15.
3. Queiroz-Telles F, de Hoog S, Santos DW, Salgado CG, Vicente VA, Bonifaz A, *et al.* Chromoblastomycosis. *Clin Microbiol Rev* 2017;30:233-76.
4. Jayasree P, Malakar S, Raja H, Gopinathan Nair N. Dermoscopic features in nodular chromoblastomycosis. *Int J Dermatol* 2019;58:e107-9.
5. Subhadarshani S, Yadav D. Dermoscopy of chromoblastomycosis. *Dermatol Pract Concept* 2017;7:23-4.
6. Tang J, Zhuang K, Ran X, Dai Y, Ran Y. Chromoblastomycosis caused by *Cladophialophora carrionii*. *Indian J Dermatol Venereol Leprol* 2017;83:482-5.
7. Minotto R, Bernardi CD, Mallmann LF, Edelweiss MI, Scroferneker ML. Chromoblastomycosis: A review of 100 cases in the state of Rio Grande do Sul, Brazil. *J Am Acad Dermatol* 2001;44:585-92.