

Next-generation sequencing of pancreatic cyst wall specimens obtained using micro-forceps for improving diagnostic accuracy



Authors

Stuart Astbury^{1,2}, Aishwarya Baskar¹, Jane I. Grove^{1,2}, Philip Kaye³, Aloysious D. Aravinthan^{1,2}, Martin W. James², Christopher Clarke⁴, Guruprasad P. Aithal^{1,2}, Suresh Vasam Venkatachalapathy²

Institutions

- 1 Nottingham Digestive Diseases Centre, Translational Medical Sciences, School of Medicine, University of Nottingham, Nottingham, UK
- 2 NIHR Nottingham Biomedical Research Centre, Nottingham University Hospitals NHS Trust and the University of Nottingham, Nottingham, UK
- 3 Department of Pathology, Nottingham University Hospitals NHS Trust, Nottingham, UK
- 4 Department of Radiology, Nottingham University Hospitals NHS Trust, Nottingham, UK

Key words

Pancreatobiliary (ERCP/PTCD), Tissue diagnosis, Endoscopic ultrasonography, Pancreas, Fine-needle aspiration/biopsy, GI Pathology

received 22.3.2023

accepted after revision 15.6.2023

accepted manuscript online 31.08.2023

Bibliography

Endosc Int Open ; 11: E983–E991

DOI 10.1055/a-2163-8805

ISSN 2364-3722

© 2023. The Author(s).

This is an open access article published by Thieme under the terms of the Creative Commons Attribution-NonDerivative-NonCommercial License, permitting copying and reproduction so long as the original work is given appropriate credit. Contents may not be used for commercial purposes, or adapted, remixed, transformed or built upon. (<https://creativecommons.org/licenses/by-nc-nd/4.0/>)

Georg Thieme Verlag KG, Rüdigerstraße 14,
70469 Stuttgart, Germany

Corresponding author

Suresh Vasam Venkatachalapathy, MRCP (UK), NIHR Nottingham Biomedical Research Centre, Nottingham University Hospitals NHS Trust and University of Nottingham, Nottingham, UK
suresh.venkatachalapathy@nuh.nhs.uk

Additional material is available at
<https://doi.org/10.1055/a-2163-8805>

ABSTRACT

Background and study aims Pancreatic cysts are common incidental findings, with an estimated prevalence of 13% to 15% in imaging done for other reasons. Diagnosis often relies on collection of cyst fluid, but tissue sampling using micro-forceps may allow for a more reliable diagnosis and higher yield of DNA for next-generation sequencing (NGS). The primary aim was to assess the performance of NGS in identifying mucinous cyst. The secondary aims were to assess DNA yield between the cyst fluid and cyst wall tissue, complication rate and performance of conventional investigations.

Patients and methods Twenty-four patients referred for endoscopic ultrasound were recruited. Biopsies were taken using micro-forceps and the AmpliSeq Cancer Hotspot panel was used for NGS, a polymerase chain reaction assay targeting several hotspots within 50 genes, including *GNAS*, *KRAS* and *VHL*.

Results The concentration of DNA extracted from 24 cyst wall samples was significantly higher than in the nine of 24 available matched cyst fluid samples. The sensitivity, specificity, and diagnostic accuracy of NGS for diagnosing mucinous cyst were 93%, 50% and 84%; for standard of care, they were 66.6%, 50% and 63.1%; and for standard of care with NGS, they were 100%, 50%, and 89.4% respectively. Cyst wall biopsy was able to diagnose 19 of 24 cysts (4 high risk, 7 intraductal papillary mucinous neoplasms, 4 cysts of mucinous origin, and 4 benign).

Conclusions NGS data correlate well with histology and may aid in diagnosis and risk stratification of pancreatic cysts. Cyst wall biopsy performs well in diagnosing cysts but was inadequate in five of 24 patients.

Introduction

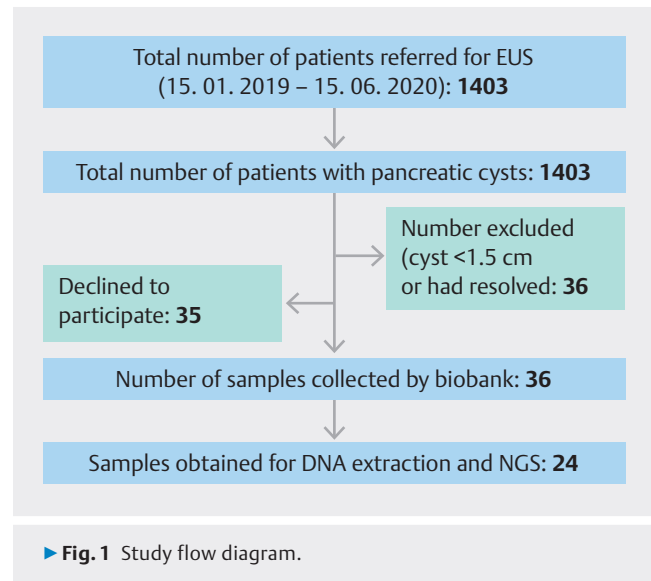
Pancreatic cancer is the fourth leading cause of death with a median 5-year survival rate of 4% [1]; overall median survival is 4.6 months from diagnosis [2]. Early diagnosis of pancreatic cancer remains a major challenge and is one of the root causes of the lack of improvement in outcomes for pancreatic cancer worldwide [3]. The Cancer of the Pancreas Screening Study (CAPS3) revealed that 10% of the population screened with a family history of pancreatic cancer had intraductal papillary mucinous neoplasms (IPMNs) [4]. In a secondary screening program involving the European Registry of Hereditary Pancreatitis and Familial Pancreatic Cancer (EUROPAC), cystic lesions were the most common finding, of which more than half were IPMNs, although these were independent of genetic predisposition [5]. In this group of patients, earlier diagnosis of high-risk cysts may change their treatment and, therefore, outcome.

The incidence of pancreatic cysts is 2.5% in the general population but steadily increases to 10% in patients over the age of 70 [6, 7]. Approximately 15% of patients who undergo computed tomography (CT) or magnetic resonance imaging (MRI) for unrelated reasons will have a pancreatic cyst [8]. Common pancreatic cysts include serous cystadenomas (SCAs), pancreatic pseudocysts, mucinous cyst neoplasms (MCN), and IPMNs. SCAs and pancreatic pseudocysts are non-mucinous and do not carry malignant potential. However, MCNs and IPMNs have the potential for malignant transformation (35%–50%) and the annual malignant transformation risk is 2%, necessitating regular follow-up [9, 10].

At present, there is no single investigation that will accurately differentiate between high-risk cysts that need intervention, intermediate cysts that require surveillance, and low-risk cysts, which do not require further surveillance. The current standard of care (SOC) for patients with pancreatic cysts is to have either CT or MRI with or without endoscopic ultrasound (EUS) and cyst fluid assessment for carcinoembryonic antigen (CEA), amylase, and cytology when a sufficient amount of cyst fluid can be aspirated [11].

Next-generation sequencing (NGS) of cyst fluid has shown promise in improving the diagnostic accuracy of differentiating pancreatic cysts [12]. Singhi et al. extracted DNA from cyst fluid and used a deep sequencing panel, targeting mutations in *KRAS/GNAS* and *TP53/PIK3CA/PTEN* to identify IPMN and advanced neoplasia, respectively. Other studies have demonstrated the utility of NGS for stratifying pancreatic cysts, potentially biasing results toward cysts that more readily shed DNA [13, 14, 15]. In addition, aspiration of adequate fluid through a fine-needle aspiration (FNA) needle for cytology and DNA extraction is more challenging as the viscosity of cyst fluid increases [16].

Micro forceps are biopsy forceps that can be passed through a 19G FNA needle, allowing sampling of pancreatic cyst wall tissue [17]. We conducted a prospective observational study to test the effectiveness of the Moray micro forceps at increasing the amount of DNA available for NGS relative to that of cyst fluid, and whether this could provide an aid to standard histological and radiological diagnosis. We evaluated the use of cyst



wall biopsies obtained with Moray micro forceps compared to cyst fluid sampling for earlier detection of somatic variants indicating potential for cancer development, and whether it could aid in diagnosis of progressive cyst types.

Patients and methods

This was a single-center, prospective, observational cohort study. Patients were recruited from Nottingham University Hospitals NHS Trust. Ethics approval was obtained from the Nottingham Health Science Biobank Access Committee (Reference: 15/NW/0685, approval ACP000282). All work was carried out in accordance with the Declaration of Helsinki.

All adult patients with pancreatic cyst(s) ≥ 1.5 cm diameter who were referred for EUS assessment from the regional hepato-pancreato-biliary multidisciplinary meeting between January 15, 2019 and June 15, 2020 were eligible for inclusion. Patients with a cyst < 1.5 cm or who were clinically diagnosed with pseudocysts were excluded from the study. Patient demographics, cytology, histopathology, imaging findings, CEA analysis, fluid amylase, and EUS findings were documented. The study is outlined as a flow diagram in ► Fig. 1.

Primary and secondary objectives

The primary objective of the study was to identify whether a larger quantity of DNA suitable and sufficient for NGS can be obtained from the cyst wall compared to cyst fluid. The secondary objectives were to assess: 1) if NGS alone or in combination with standard of care (CT/MRI + EUS assessment \pm fluid CEA \pm fluid amylase) improves the sensitivity, specificity, and diagnostic accuracy of mucinous cyst identification; 2) adequacy of samples for histological assessment; and 3) complications associated with the cyst wall biopsy using Moray micro forceps.

EUS procedure and cyst wall biopsy

The procedure was carried out under conscious sedation using a combination of fentanyl and midazolam. EUS was performed by independent endo-sonographers who had received formal training in the FNA technique. Using EUS, the cyst was identified, evaluated for any high-risk features (>3 cm, dilated pancreatic duct >9 mm, enhancing wall, mural nodule), and the most accessible portion of the cyst adjacent to the mucosa on EUS was selected. A 19G FNA needle was then introduced into the cyst with 5 to 10 mL dry suction. Fluid was aspirated where possible, allowing the cyst to partially collapse and was sent for amylase, CEA, and the surplus sample was snap-frozen in liquid nitrogen for DNA extraction. Through the FNA needle, Moray micro forceps were introduced into the cyst, opened under ultrasound guidance, withdrawn close to the needle tip, needle tip advanced to the opposite wall, biopsy forceps closed, needle gently withdrawn until there was denting of the cyst wall and then the biopsy forceps were removed in a single motion. This was repeated three to five times and intravenous antibiotics were given at the end of the procedure. Samples were placed in formalin for routine histology and surplus tissue was immediately snap-frozen in liquid nitrogen and stored at -80°C.

Histopathological and radiological analysis

The CT/MRI images were evaluated by an expert independent radiologist blinded to clinical information, previous radiology reports, and laboratory results. Similarly, histology was evaluated by an independent histopathologist blinded to the clinical, radiological, and laboratory biochemical information. The slides were prepared at Nottingham University Hospitals NHS Trust, stained for hematoxylin and eosin (H&E) and sent to the histopathologist with an anonymized numeric code.

DNA extraction and NGS of cyst wall biopsies and cyst fluid

DNA was extracted from cyst wall samples using the Qiagen QIAmp DNA Micro kit and quantified using a Qubit Fluorometer. Polymerase chain reaction amplicons were generated using the AmpliSeq for Illumina Cancer Hotspot Panel v2 (primer sequences in Supplementary Table 1) and sequenced on an Illumina MiSeq. Demultiplexed paired end reads were filtered for erroneously short and long sequences, low-quality scores (<Phred 30) and adapter sequences using Trimmomatic. Alignment to the human genome reference hg38 was carried out using bwa-mem [18]. The remaining processing was carried out following Genome Analysis Tool Kit best practices [19], alignments were filtered using BaseRecalibrator, and somatic variants were called using Mutect2 and FilterMutectCalls [20]. Because healthy cyst-adjacent pancreatic tissue from each participant was not available as a control, a panel of normal samples was constructed using publicly available data from the 1000 Genomes project [21] to filter alignment artifacts, and the gnomAD database [22] was used to filter known germline variants. Finally, the filtered list of variants for each sample was annotated using SNPeff [23] to identify coding and non-coding variants. The limit of detection used was a mutant allele

frequency (MAF) of 1%, with a minimum sequencing depth of 7000x. Due to the small sample size, the list of targets used for analysis was limited to genes with hotspots previously linked to pancreatic malignancies according to the Catalogue of Somatic Mutations in Cancer (COSMIC) database [24].

Confirmatory NGS was carried out on cyst fluid where samples were available. DNA was extracted using the Qiagen ccfDNA extraction kit and primers from the AmpliSeq panel were used to amplify relevant amplicons (sequences are highlighted in Supplementary Table 1). Amplified DNA was cleaned using the Qiagen PCR cleanup kit and normalized to 20 ng/μL. Samples were sequenced by Azenta/GENEWIZ (Essex, UK). Raw sequence data were processed using an identical workflow to that described above for the cyst wall samples.

Case definition

Four patients in the study had surgical resection. The cyst wall biopsy specimens were compared against the resected surgical specimen. The cyst wall biopsy correlated well with the surgical specimen. Hence, cyst wall tissue histopathology was used as the standard and all parameters were compared against histopathological diagnosis. SOC is defined as patients having CT/MRI ± EUS ± cytology ± fluid CEA/amylase to determine whether they have high-risk cysts.

Statistical analysis

Categorical variables were presented as numbers with percentages; continuous variables were presented as median and interquartile range (IQR). Statistical analyses were performed using Prism 9 (GraphPad Inc., San Diego, California, United States) and SPSS Statistics for Windows, Version 28.0 (IBM, Armonk, New York, United States). $P < 0.05$ was considered to indicate statistical significance. Diagnostic accuracy for individual diagnostic tests/parameters was calculated using sensitivity, specificity, positive predictive value, negative predictive value, positive likelihood ratio, and negative likelihood ratio.

Results

Clinical characterization of patients

Twenty-four patients (54% female) were prospectively recruited to the study (► **Table 1**); the median age was 71 years (IQR 59–78). Sixteen patients (67%) were of European descent, one (4%) was Asian and for seven (32%) the ethnicity was not known. After the procedure, patients were followed up for a median of 491 days (IQR 126–674).

Histological analysis

The histopathologist was able to give a definite diagnosis based on H&E staining in 15 of 24 cases (62.5%), probable diagnosis in four of 24 cases (16.6%), and in five of 24 cases (20.8%), the sample was inadequate for diagnosis, although the sample was macroscopically visible in all patients at the time of acquisition. The histological outcomes are shown in ► **Table 1**. Cyst wall biopsy specimens were compared against resected surgical specimens in four available cases.

► **Table 1** Cohort characteristics and histological diagnosis based on cyst wall biopsy.

Patient demographic data	Median (IQR) or n (%)
Sex	13 female (54%)
Age	71 (59–78)
Ethnicity	
▪ European	16 (67%)
▪ Non-European (Pakistan)	1 (4%)
Unknown	7 (32%)
Cyst etiology	
Malignant	
▪ Adenocarcinoma	1 (4.1%)
▪ NET	3 (12.5%)
Mucinous cyst	
▪ IPMN	7 (29.2%)
▪ Probable cyst of mucinous origin	4 (16.7%)
Non-mucinous cyst	
▪ Benign epithelial cyst	1 (4.1%)
▪ Lymphoepithelial cyst	1 (4.1%)
▪ SCA	1 (4.1%)
▪ Pseudocyst	1 (4.1%)
▪ Inadequate tissue for diagnosis	5 (20.8%)

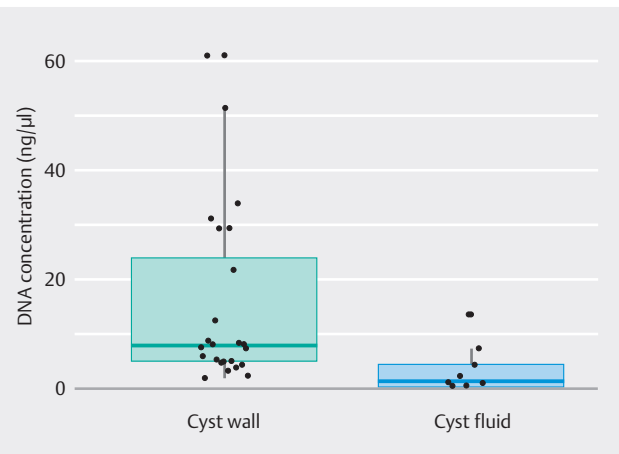
IQR, interquartile range; NET, neuroendocrine tumor; IPMN, intraductal papillary mucinous neoplasm; SCA, serous cystadenoma.

Radiological analysis

Twenty-two of 24 patients (91.7%) had either a CT or MRI scan. In two patients, the CT/ MRI was performed in referring hospitals and the images could not be retrieved for independent evaluation. Communication with the pancreatic duct (PD) was established in only patients (27.7%). The main PD was visualized in 14 of 22 patients (63.6%) and the median diameter was 3 mm (IQR 1–2). Mural nodules and septations were identified in four (18.1%) and three patients (13.6%), respectively. Fifteen of 22 (68.2%) were reported as side branch IPMNs (SB-IPMNs), five as MCNs, one serous cystic neoplasm and one adenocarcinoma.

EUS and fluid cytology

The median diameter of the PC was 25 mm (IQR 16–33). The median PD diameter was 2 mm (IQR 2–3.5) and communication of the cyst with the PD was defined in 23 patients (95.8%). Mural nodules and septations were identified in four of 24 (16.6%) and seven of 24 (29.1%), respectively. Obtaining fluid for cytology from the cyst was feasible in 16 of 24 patients (66.6%), but definite diagnosis from fluid cytology was possible in four of 16 (25%) of these patients. The low aspiration rate was due to in-



► **Fig. 2** Comparison of DNA concentration (ng/μL) obtained from cyst wall and cyst fluid samples, $P=0.0028$ Mann-Whitney U test.

creased viscosity of the fluid. The remainder had either bland epithelium or the sample was acellular. Aspirated cyst fluid was sent for CEA and amylase analysis. CEA analysis was possible in seven of 24 (29.1%) and amylase in 12 of 24 patients (50%). This was because the volume of fluid aspirated was only sufficient for the analysis of amylase.

Follow-up and serious adverse events

One patient developed acute severe pancreatitis requiring prolonged hospitalization. There were no other complications secondary to the procedure and there were no deaths within 30 days of the procedure. Follow-up information was available for all patients. The median follow-up period was 491 days (IQR 125–674). Four patients had surgical resection, two patients had successful radiofrequency ablation of the cyst, one had progression of the cyst, seven had stable cysts, four were discharged with benign cysts, three were discharged after intervention, and three died (2 within 12 months and 1 within 2 years). The patients who died had adenocarcinoma (126 days - progression of cancer), IPMNs with low-grade dysplasia (74 days - sepsis) and IPMNs with high-grade dysplasia (514 days - progression to cancer). The patient who had high-grade dysplasia progressed to cancer and died because of locally advanced pancreatic cancer.

Evaluation of DNA yield from samples

Of the 16 cyst fluid samples collected, sufficient DNA for NGS was obtained from nine samples; whereas sufficient DNA was extracted from 24 of 24 (100%) of the cyst wall biopsy samples. The median concentration of DNA from cyst fluid and cyst wall was 1.03 ng/μL (IQR 0.28–5.79) and 7.71 ng/μL (IQR 4.74–27.5), respectively (► **Fig. 2**). The difference between the DNA quantity obtained from the cyst wall tissue and the cyst fluid was significant ($P=0.003$, Mann-Whitney U test).

Next-generation sequencing of cyst wall DNA

Mutations in *KRAS* or *GNAS* were found in all seven IPMN samples, and in two of four samples graded as probable mucinous cyst. The remaining two probable mucinous cysts displayed mutations in *TP53*. Of the five samples with an unknown diagnosis based on histology, two carried mutations in *KRAS* or *GNAS* and another contained a mutation in *TP53*. Of the four benign cysts, one sample (a pseudocyst) contained a *KRAS* and *VHL* mutation. Mutations are summarized in ► **Table 2**.

Confirmatory NGS in cyst fluid samples

Confirmatory sequencing was carried out in DNA extracted from cyst fluid on hits in the top four genes linked to pancreatic cancer or IPMNs (*KRAS*, *GNAS*, *TP53*, *VHL*). Variants were confirmed in four of 11 hits found in cyst wall DNA. A further two variants found in the cyst wall DNA were detected in the cyst fluid but failed to pass the Mutect2 quality filter (► **Table 3**). No additional variants were detected in cyst fluid DNA that were not detected in the corresponding cyst wall DNA.

Evaluation of the diagnostic accuracy of NGS

The sensitivity, specificity, and diagnostic accuracy of SOC for diagnosing a cyst that needs surveillance or treatment were 66.6%, 50%, and 63.1%, respectively. NGS of the cyst wall sample performed better than SOC with sensitivity of 93.3%, specificity 50%, and diagnostic accuracy of 84.2%. Combining SOC with NGS improved the above to 100%, 50%, and 89.2%, respectively (► **Table 4**). The sensitivity, specificity, and diagnostic accuracy of EUS + fluid cytology for identifying mucinous cysts were 40%, 100%, and 52%, respectively (► **Table 2**). The sensitivity, specificity, and diagnostic accuracy of cytology were 12.5%, 100%, and 30%, respectively. They were 100%, 25%, and 82% for CT/MRI, respectively.

Discussion

This is the first study to demonstrate that the yield of extracted DNA is significantly higher from cyst wall tissue samples compared to cyst fluid. The micro forceps yielded sufficient cyst wall tissue for histological analysis in 79% of patients (19/24). In contrast, DNA adequate to perform NGS was obtained from all cyst wall samples. The diagnostic accuracy for current SOC is 63% but the addition of molecular analysis of cyst wall samples improved the diagnostic accuracy to 89%.

The cyst wall histology correlated well with the surgical specimens; identified high-risk cysts (4/24) that needed surgical intervention and four of 24 had benign cysts who did not need surveillance. However, successful diagnostic histology was obtained in only 79% of patients. Molecular analysis of the cyst wall may be an important adjunct for improving the diagnostic accuracy of cysts in the rest of the patients. Hence, histology in conjunction with NGS may help to accurately diagnose high-risk pancreatic cysts that need urgent intervention, mucinous cysts that need surveillance, and low risk non-mucinous cysts in about which patients can be reassured and discharged. Large

multicenter studies with longer follow-up are needed to confirm or refute the above hypothesis.

The low DNA yield obtained from cyst fluid samples is likely due to the highly variable number of cells shed from the cyst. The source of DNA is due to exfoliation of cyst epithelial cell into the cyst cavity and this may vary from cyst to cyst. It may also be dependent on the amount of fluid aspirated from the cyst. Moreover, this was a biobank study; hence, only surplus volume of fluid was sent for NGS analysis. This may have contributed to low yield. The performance of NGS on both cyst fluid and cyst wall biopsies are almost similar but the rate-limiting factor may be aspiration of sufficient fluid for NGS analysis (after sending it for biochemical analysis). Further studies may need to address the right amount of fluid for successful NGS analysis. Obtaining cyst wall tissue with “through the needle” micro forceps is a feasible method for increasing the DNA yield from pancreatic cysts. It was possible to do NGS analysis in all cyst wall biopsy samples even though they were small. It requires minimal training and can be carried out by endosonographers who are trained to do FNA of cysts.

Up to 15% of pancreatic cancers are secondary to mucinous pancreatic cysts [25]. Because pancreatic cancers are aggressive and associated with poor survival, the current SOC is to assess cysts and survey them with either 6-month or annual CT/MRI scans until the patients become unfit for pancreatic resection [11]. This is associated with increased cost burden to the health care system. It may cause significant anxiety to patients not knowing the type of cysts they have. Molecular analysis of the cyst wall samples with histology may help alleviate that problem.

In this study, the median follow-up period was relatively short (491 days) for pancreatic cysts. Further, during the follow-up period there was no overt progression of the cyst lesions. The follow-up scans did not suggest any signs of complications such as pancreatitis/intra-cystic bleeding. Patients who died had pancreatic adenocarcinomas and IPMNs with low- and high-grade dysplasia. Except for one case of pancreatitis, there were no other serious adverse events (AEs). This is in line with other studies in which the quoted pancreatitis risk following cyst wall biopsy is 3% to 7% [26]. This is slightly higher than the risk of pancreatitis (2.6%) following FNA of a pancreatic cyst [27], although the most recent multicenter study using flexible needles reported a serious AE rate of 1.2% (0.2%-3.5%) [28].

The AmpliSeq panel utilized for this study targets multiple hotspots of 50 genes, which have been narrowed down to genes linked to pancreatic cysts and cancer previously using the COSMIC database [24], and the remainder are included in supplementary data. Mutations in *KRAS* and *GNAS* have been proposed as a potential diagnostic test for IPMN but they have also been shown to lack the specificity required to detect MCNs [29]. Similar to previous studies using cyst fluid [12, 14, 30], we identified *KRAS* and/or *GNAS* mutations in 100% of IPMN cases. As expected, all detected *KRAS* mutations were at codons 12 and 61, the most frequently linked to pancreatic cancer according to the COSMIC database [24]. All but one of the detected *GNAS* mutations were found at codon 844, which has also been

► **Table 2** Somatic protein coding mutations with over 1% prevalence in pancreatic cyst samples.

Patient	Diagnosis	KRAS	GNAS	TP53	VHL	NRAS	CTNNB1	PTEN	AKT1
1	ADC	p.G12R (10%)	–	–	–	–	–	–	–
2	NET	–	–	–	–	–	–	–	–
3	NET	–	–	–	–	–	–	–	–
4	NET	–	–	–	–	–	–	–	–
5	IPMN (high grade)	–	p.A844H (31%)	–	–	–	–	–	–
6	IPMN (low grade)	p.Q61H (40%)	p.R844C (55%)	–	–	–	–	–	–
7	IPMN (low grade)	p.G12D (8%)	p.R844H (8%)	–	–	–	–	–	p.T172A (1.3%)
8	IPMN (low grade)	–	p.R844C (3%)	–	–	–	–	–	–
9	IPMN (low grade)	p.G12D (20%)	–	–	–	–	–	–	–
10	IPMN (low grade)	p.G12V (6%)	–	–	–	–	–	–	–
11	IPMN (low grade)	p.G12A (5%)	p.R844H (10%)	–	–	–	p.T411 (6.6%)	–	–
12	Probable mucinous cyst	–	p.R844H (35%)	–	–	–	–	–	–
13	Probable mucinous cyst	p.Q61H (2%)	–	–	–	–	–	–	–
14	Probable mucinous cyst	–	–	p.P85A (2.9%)	–	–	–	–	–
15	Probable mucinous cyst	–	–	p.V217A (2.5%)	–	–	–	–	–
16	PSC	–	p.A866G (1.5%)	–	p.L85P (1.5%)	–	–	–	–
17	EC	–	–	–	–	–	–	–	–
18	LEC	–	–	–	–	–	–	–	–
19	SCA	–	–	–	–	–	–	p.Y350H (7%)	–
20	Unknown	–	–	–	p.R161* (6%)	–	–	–	–
21	Unknown	–	p.R844H (2.2%)	–	–	–	–	–	–
22	Unknown	–	–	p.V217A (2.6%)	p.K171* (14.1%)	–	–	–	–
23	Unknown	p.G12V (4%)	–	–	–	–	–	–	–
24	Unknown	p.Q61H (11%)	–	–	–	p.Q31G (4.1%)	–	–	–

PSC, pseudocyst; EC, epithelial cyst; IPMN, intraductal papillary mucinous neoplasm; SCA, serous cystadenoma; NET, neuroendocrine tumor; LEC, lymphoepithelial cyst; ADC, adenocarcinoma; NGS, next-generation sequencing.

*Indicates a stop codon. All mutant allele frequencies are expressed as percentage of sequence reads containing the mutation compared to the hg38 reference genome wild type sequence. The NGS was compared against histology.

► **Table 3** Confirmation of *GNAS*, *KRAS*, *TP53* and *VHL* variants detected in cyst wall DNA using DNA extracted from cyst fluid.

Patient	Cyst wall variant (MAF)	Present in cyst fluid (MAF)
7	<i>KRAS</i> G12D (8%)	<i>KRAS</i> G12D (45%)
7	<i>GNAS</i> R844H (8%)	<i>GNAS</i> R844H (39%)
8	<i>GNAS</i> R844C (3%)	<i>GNAS</i> R844C (7%)
9	<i>KRAS</i> G12D (20%)	<i>KRAS</i> G12D (40%)
12	<i>GNAS</i> R844H (35%)	NA [†]
13	<i>KRAS</i> Q61H (2%)	NA
16	<i>GNAS</i> A866G (1.5%)	NA
16	<i>VHL</i> L85P (1.5%)	NA
20	<i>VHL</i> R161* (6%)	NA
22	<i>TP53</i> V217A (2.6%)	NA
22	<i>VHL</i> K171* (14%)	NA [†]

[†]Indicates variant that is present in NGS data but falls below Mutect2 quality filters.

linked to pancreatic cancer and IPMN [31]. A single pseudocyst sample carried a mutation at codon 866, which to our knowledge has not been linked to any cancers. Similar to work in cyst fluid, of the four cysts diagnosed as “probable mucinous cyst” by a pathologist, two were not found to contain any *KRAS* or *GNAS* mutations. *TP53* mutations were observed in three samples (1 at codon 85 and 2 at codon 217), neither of these sites are associated with pancreatic cancer in COSMIC, but somatic mutations in *TP53* at any point have been shown to aid in prediction of outcome of pancreatic adenocarcinoma [32].

We endeavored to test matched cyst fluid samples from patients from whom samples could be obtained and sufficient DNA could be extracted. No additional mutations were detected in cyst fluid that were not present in the cyst wall; however confirmatory work was limited to amplicons in which mutations were already detected, and a full screen with the AmpliSeq panel would be required to confirm this definitively. Interestingly, in two cases, inspection of the raw variant call data output from Mutect2 revealed that mutations were detected in cyst fluid, before being removed by the default quality filter. To our knowledge, this is the first study directly comparing cyst wall and cyst fluid DNA samples from the same patient, and it suggests that cyst wall biopsy can provide an increased level of detection of somatic mutations compared to cyst fluid. In addition, variant allele frequencies were significantly different between cyst wall and cyst fluid. There are several potential explanations for this. Cysts with a larger solid component will shed more DNA into the cyst fluid, which could affect variant allele frequencies simply through differences in the amount of DNA sampled. This bias is avoided by sampling the tissue directly [33]. However, extensive genetic heterogeneity within IPMNs has been demonstrated using single-cell sequencing, meaning

► **Table 4** Sensitivity, specificity and diagnostic accuracy of different investigations.

Investigation	Sensitivity (%)	Specificity (%)	Diagnostic accuracy (%)
Fluid CEA + amylase	12.5	100	30
Cytology	23.08	100	33.3
EUS + cytology	40	100	52
NGS	93.3	50	84.2
SOC	66.6	50	63.1
NGS + SOC	100	50	89.4

CEA, carcinoembryonic antigen; EUS, endoscopic ultrasound; SOC, standard of care; NGS, next-generation sequencing.

results could still be biased depending on the part of the cyst that was sampled [34].

The limitations of the study are recruitment from a single center, a small sample size, and a relatively short follow-up period. The authors are aware that this may lead to selection bias and an increased intervention effect; therefore, the results cannot be generalized to a wider population. The authors tried to minimize these effects by blinding the histopathologist, radiologist, and bioinformatician to patient information. In addition, Moray micro forceps can only be passed through a 19G needle, which may not be feasible in a portion of cases depending on the site and size of the pancreatic cyst. A recent study demonstrated that use of a flexible needle increased the success rate for EUS-FNA to 89% compared to 75% with the standard needle that we used in this study [28]. Another limitation is the size of the sample obtained. The samples obtained were too small for conclusive histological diagnosis in about one-fifth of the patients. To our knowledge, one other study has assessed the utility of NGS of cyst wall biopsies in diagnosis, using formalin-fixed paraffin-embedded (FFPE) tissue. Although DNA concentrations were not reported, this study demonstrated that almost 20% of cyst wall specimens recovered from FFPE were unsuitable for NGS, whereas our use of fresh frozen tissue resulted in no excluded samples and a greater average sequencing depth [35].

Conclusions

In conclusion, this study demonstrates that it is feasible to obtain cyst wall samples for histological analysis and NGS. The quantity of DNA obtained from tissue was significantly greater than the cyst fluid samples. Larger studies are needed to assess if NGS and cyst wall histology will aid in accurately characterizing cysts as high-risk and requiring intervention, those requiring surveillance, and low risk about which patients can be reassured before being discharged.

Acknowledgement

The authors acknowledge the support of the NIHR Nottingham Biomedical Research Centre (grant BRC-1215-20003 and NIHR203310). The views expressed are those of the authors and not necessarily those of the NHS, NIHR, or the Department of Health and Social Care. The authors are grateful to Dr Nadine Holmes and the DeepSeq facility, School of Life Sciences, University of Nottingham for carrying out the NGS, and to Melanie Lingaya, Davor Kresnik, Samatha Warburton, Sian Parkes, Violeta Anuskievic and Rachelle Boxhall for support with sample storage, processing, and training nurses on Moray forceps.

Conflict of Interest

The authors declare that they have no conflict of interest.

Funding

Nottingham Biomedical Research Centre
<http://dx.doi.org/10.13039/501100000272>
 BRC-1215-20003 and NIHR203310

References

- [1] Vincent A, Herman J, Schulick R et al. Pancreatic cancer. *Lancet* 2011; 378: 607–620 doi:10.1016/S0140-6736(10)62307-0
- [2] Carrato A, Falcone A, Ducreux M et al. A systematic review of the burden of pancreatic cancer in Europe: real-world impact on survival, quality of life and costs. *J Gastrointest Cancer* 2015; 46: 201–211 doi:10.1007/s12029-015-9724-1
- [3] Walter FM, Mills K, Mendonca SC et al. Symptoms and patient factors associated with diagnostic intervals for pancreatic cancer (SYMPTOM pancreatic study): a prospective cohort study. *Lancet Gastroenterol Hepatol* 2016; 1: 298–306
- [4] Canto MI, Schulick RD, Kamel IR et al. 415g: screening for familial pancreatic neoplasia: a prospective, multicenter blinded study of EUS, CT, and secretin-MRCP (The NCI-Spore Lustgarten Foundation Cancer of the Pancreas CAPS 3 Study). *Gastrointest Endosc* 2010; 71: AB119
- [5] Sheel ARG, Harrison S, Sarantis I et al. Identification of cystic lesions by secondary screening of familial pancreatic cancer (FPC) kindreds is not associated with the stratified risk of cancer. *Am J Gastroenterol* 2019; 114: 155–164
- [6] Laffan TA, Horton KM, Klein AP et al. Prevalence of unsuspected pancreatic cysts on MDCT. *Am J Roentgenol* 2008; 191: 802–807 doi:10.2214/AJR.07.3340
- [7] de Jong K, Nio CY, Mearadji B et al. Disappointing interobserver agreement among radiologists for a classifying diagnosis of pancreatic cysts using magnetic resonance imaging. *Pancreas* 2012; 41: 278–282
- [8] Farrell JJ. Prevalence, diagnosis and management of pancreatic cystic neoplasms: current status and future directions. *Gut Liver* 2015; 9: 571–589 doi:10.5009/gnl15063
- [9] Grenacher L, Strauss A, Bergmann F et al. Cyst features and risk of malignancy in intraductal papillary mucinous neoplasms of the pancreas: imaging and pathology. *Viszeralmedizin* 2015; 31: 31–37 doi:10.1159/000375254
- [10] Keane MG, Afghani E. A Review of the diagnosis and management of premalignant pancreatic cystic lesions. *J Clin Med* 2021; 10: doi:10.3390/jcm10061284
- [11] European Study Group on Cystic Tumours of the Pancreas. European evidence-based guidelines on pancreatic cystic neoplasms. *Gut* 2018; 67: 789–804
- [12] Singhi AD, McGrath K, Brand RE et al. Preoperative next-generation sequencing of pancreatic cyst fluid is highly accurate in cyst classification and detection of advanced neoplasia. *Gut* 2017; 67: 2131–2141 doi:10.1136/gutjnl-2016-313586
- [13] Jones M, Zheng Z, Wang J et al. Impact of next-generation sequencing on the clinical diagnosis of pancreatic cysts. *Gastrointest Endosc* 2016; 83: 140–148 doi:10.1016/j.gie.2015.06.047
- [14] Rosenbaum MW, Jones M, Dudley JC et al. Next-generation sequencing adds value to the preoperative diagnosis of pancreatic cysts. *Cancer Cytopathol* 2017; 125: 41–47 doi:10.1002/cncy.21775
- [15] Paniccia A, Polanco PM, Boone BA et al. Prospective, multi-institutional, real-time next-generation sequencing of pancreatic cyst fluid reveals diverse genomic alterations that improve the clinical management of pancreatic cysts. *Gastroenterology* 2023; 164: 117–133
- [16] Khalid A, McGrath KM, Zahid M et al. The role of pancreatic cyst fluid molecular analysis in predicting cyst pathology. *Clin Gastroenterol Hepatol* 2005; 3: 967–973 doi:10.1016/s1542-3565(05)00409-x
- [17] Zhang ML, Arpin RN, Brugge WR et al. Moray micro forceps biopsy improves the diagnosis of specific pancreatic cysts. *Cancer Cytopathol* 2018; 126: 414–420 doi:10.1002/cncy.21988
- [18] Li H, Durbin R. Fast and accurate short read alignment with Burrows-Wheeler transform. *Bioinformatics* 2009; 25: 1754–1760 doi:10.1093/bioinformatics/btp324
- [19] DePristo MA, Banks E, Poplin R et al. A framework for variation discovery and genotyping using next-generation DNA sequencing data. *Nat Genet* 2011; 43: 491–498 doi:10.1038/ng.806
- [20] Benjamin D, Sato T, Cibulskis K et al. Calling Somatic SNVs and Indels with Mutect2. *bioRxiv* 2019: doi:10.1101/861054
- [21] The 1000 Genomes Project Consortium. A global reference for human genetic variation. *Nature* 2015; 526: 68–74
- [22] Karczewski KJ, Francioli LC, Tiao G et al. The mutational constraint spectrum quantified from variation in 141,456 humans. *Nature* 2020; 581: 434–443
- [23] Cingolani P, Platts A, Wang le L et al. A program for annotating and predicting the effects of single nucleotide polymorphisms, SnpEff: SNPs in the genome of *Drosophila melanogaster* strain w1118; iso-2; iso-3. *Fly (Austin)* 2012; 6: 80–92 doi:10.4161/fly.19695
- [24] Tate JG, Bamford S, Jubb HC et al. COSMIC: the Catalogue Of Somatic Mutations In Cancer. *Nucleic Acids Res* 2019; 47: D941–D947 doi:10.1093/nar/gky1015
- [25] Singhi AD, Koay EJ, Chari ST et al. Early detection of pancreatic cancer: opportunities and challenges. *Gastroenterology* 2019; 156: 2024–2040 doi:10.1053/j.gastro.2019.01.259
- [26] Balaban VD, Cazacu IM, Pinte L et al. EUS-through-the-needle micro-biopsy forceps in pancreatic cystic lesions: A systematic review. *Endosc Ultrasound* 2021; 10: 19 doi:10.4103/eus.eus_23_20
- [27] Siddiqui AA, Shahid H, Shah A et al. High risk of acute pancreatitis after endoscopic ultrasound-guided fine needle aspiration of side branch intraductal papillary mucinous neoplasms. *Endosc Ultrasound* 2015; 4: 109 doi:10.4103/2303-9027.156728
- [28] Al-Haddad M, Wallace MB, Brugge W et al. Fine-needle aspiration of pancreatic cystic lesions: a randomized study with long-term follow-up comparing standard and flexible needles. *Endoscopy* 2021; 53: 1132–1140
- [29] Singhi AD, Nikiforova MN, Fasanella KE et al. Preoperative GNAS and KRAS testing in the diagnosis of pancreatic mucinous cysts. *Clin Cancer Res* 2014; 20: 4381–4389 doi:10.1158/1078-0432.CCR-14-0513

- [30] Faias S, Duarte M, Albuquerque C et al. Clinical Impact of KRAS and GNAS analysis added to CEA and Cytology in Pancreatic cystic fluid obtained by EUS-FNA. *Dig Dis Sci* 2018; 63: 2351–2361
- [31] Tan MC, Basturk O, Brannon AR et al. GNAS and KRAS mutations define separate progression pathways in intraductal papillary mucinous neoplasm-associated carcinoma. *J Am Coll Surg* 2015; 220: 845–854 doi:10.1016/j.jamcollsurg.2014.11.029
- [32] Shoucair S, Habib JR, Pu N et al. Comprehensive analysis of somatic mutations in driver genes of resected pancreatic ductal adenocarcinoma reveals KRAS G12D and mutant TP53 combination as an independent predictor of clinical outcome. *Ann Surg Oncol* 2022; 29: 2720–2731 doi:10.1245/s10434-021-11081-z
- [33] Khalid A, Zahid M, Finkelstein SD et al. Pancreatic cyst fluid DNA analysis in evaluating pancreatic cysts: a report of the PANDA study. *Gastrointest Endosc* 2009; 69: 1095–1102 doi:10.1016/j.gie.2008.07.033
- [34] Kuboki Y, Fischer CG, Beleva Guthrie V et al. Single-cell sequencing defines genetic heterogeneity in pancreatic cancer precursor lesions. *J Pathol* 2019; 247: 347–356
- [35] Rift CV, Melchior LC, Kovacevic B et al. Targeted next-generation sequencing of EUS-guided through-the-needle-biopsy sampling from pancreatic cystic lesions. *Gastrointest Endosc* 2022; 97: 50–58.e4