

## Biphasic Zika Illness With Rash and Joint Pain

Srilatha Edupuganti,<sup>1,3</sup> Muktha S. Natrajan,<sup>1,3</sup> Nadine Rouphael,<sup>1,3</sup> Lilin Lai,<sup>1,3</sup> Yongxian Xu,<sup>1,3</sup> Matthew Feldhammer,<sup>2</sup> Charles Hill,<sup>2</sup> Shital M. Patel,<sup>4</sup> Sara Jo Johnson,<sup>1,3</sup> Mary Bower,<sup>1,3</sup> Rodion Gorchakov,<sup>5</sup> Rebecca Berry,<sup>5</sup> Kristy O. Murray,<sup>5</sup> and Mark J. Mulligan<sup>1,3</sup>

<sup>1</sup>Division of Infectious Diseases, Department of Medicine, and <sup>2</sup>Department of Pathology, Emory University School of Medicine, Atlanta, Georgia; <sup>3</sup>The Hope Clinic of the Emory Vaccine Center, Emory University School of Medicine, Decatur, Georgia; <sup>4</sup>Department of Medicine and Molecular Virology and Microbiology, Baylor College of Medicine, Houston, Texas; and <sup>5</sup>Pediatrics-Tropical Medicine, Texas Children's Hospital, Baylor College of Medicine, Houston, Texas

During the current Zika virus (ZIKV) outbreak, acute symptomatic ZIKV infection in adults appears to be a mild-to-moderate, self-limited illness. We present a case of ZIKV rash illness that improved and then relapsed without repeat exposure to ZIKV. Clinicians should be alert for relapses in patients with ZIKV infection.

**Keywords.** joint pains; rash; relapse; Zika illness.

Zika virus (ZIKV) is a member of the *Flaviviridae* family and is primarily transmitted by *Aedes* mosquitoes to humans [1]. There were explosive outbreaks of ZIKV infections in the Americas and the islands of the Caribbean Sea in 2016. In the continental United States, as of May 31, 2017, 4952 travel-associated cases of ZIKV infection have been reported [2]. A smaller number of autochthonous cases (n = 224) in Florida and Texas have occurred since July 2016 [2]. Symptomatic ZIKV infection in healthy people is typically described as a self-limited illness with fever, rash, conjunctivitis, arthralgia, myalgia, and headache [1]. The 2 most serious complications of ZIKV infection include Congenital Zika Syndrome in an infected fetus and neurological complications such as Guillain-Barré syndrome (GBS) in adults [1, 3, 4]. In this study, we describe a case of acute ZIKV infection in an adult that evolved into a biphasic illness.

## CASE PRESENTATION

In September 2016, a 60-year-old man presented to his primary care doctor with 4 days of fatigue, subjective fever, chills, dull headache, rash, muscle pains, red itchy eyes, abdominal pain, and burning pain with urination 3 days after returning from a vacation in Miami, Florida. He also reported swelling and pain in both hands and had moderate joint pain of both hips and knees. These symptoms interfered with his daily activities and he remained bed bound for 3 days. On examination, he had normal vital signs, bilateral conjunctival injection, erythema of nares, tympanic membranes and pharynx, enlarged bilateral posterior auricular nodes, and a generalized erythematous papular rash (worst on feet and ankles), but no joint effusions. His range of motion was limited in his hands due to swelling (Figure 1A and B) and pain in his fingers.

Over the next 2 weeks, most of the patient's symptoms resolved except for mild fatigue, residual joint discomfort, and fading conjunctivitis. Four weeks after the onset of initial symptoms, he returned to our clinic with relapse of generalized erythematous papular rash, worsening of conjunctival injection, desquamation on bilateral palms, exacerbation of pain in hip joints, and swelling and pain in hands (Figure 1C). These symptoms were milder than that of the initial presentation. All of these recurrent symptoms gradually resolved over 2 weeks (6 weeks after initial presentation).

His past medical history is notable for presumed nonalcoholic steatohepatitis, thrombocytopenia of unknown etiology, hypertension, obesity, and obstructive sleep apnea. Medications include alprazolam (as needed for sleep) and olmesartan medoxomil/hydrochlorothiazide for hypertension. He consumes moderate amounts of alcohol and is a long-time cigar smoker. The patient was originally from the French Basque Country, served in the French military, and recalls receipt of a yellow fever virus (YFV) vaccine at least 25 years prior. He had an extensive travel history to areas endemic for dengue. He has been residing in the United States for more than 17 years. He traveled to Miami with family members and recalled mosquito bites. A 35-year-old male family member who resided in the same area of Miami had a similar rash illness in the same time frame as our patient, and he was also confirmed by molecular testing to have acute ZIKV infection.

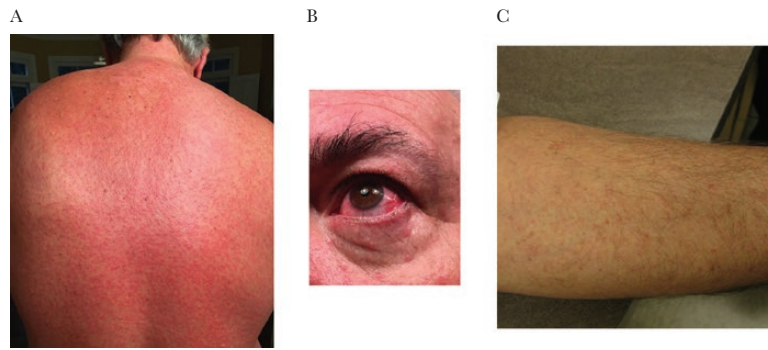
At initial presentation, 5 days after symptom onset, clinical laboratory studies showed normal white blood cell count and differential, platelets 74 000/ $\mu$ L (his usual level was 80 000/ $\mu$ L; normal range 140–400 thousand/ $\mu$ L), normal creatinine, normal urinalysis, and negative hepatitis B surface antigen, hepatitis C antibody, and human immunodeficiency virus

Received 6 April 2017; editorial decision 19 June 2017; accepted 19 June 2017.

Correspondence: S. Edupuganti, MD, MPH, 500 Irvin Ct, Suite 200, Decatur, GA 30030 (sedupug@emory.edu).

Open Forum Infectious Diseases®

© The Author 2017. Published by Oxford University Press on behalf of Infectious Diseases Society of America. This is an Open Access article distributed under the terms of the Creative Commons Attribution-NonCommercial-NoDerivs licence (<http://creativecommons.org/licenses/by-nc-nd/4.0/>), which permits non-commercial reproduction and distribution of the work, in any medium, provided the original work is not altered or transformed in any way, and that the work is properly cited. For commercial re-use, please contact journals.permissions@oup.com. DOI: 10.1093/ofid/ofx133



**Figure 1.** Sixty-year-old man with (A) generalized rash and (B) conjunctivitis during initial acute Zika illness. (C) Relapse of generalized rash 4 weeks after onset of acute illness; right arm is shown here.

fourth-generation Ag/Ab test. Aspartate aminotransferase (AST) and alanine aminotransferase (ALT) were 128 (range 10–35 U/L) and 171 (range 9–46 U/L), respectively, compared with his baseline AST/ALT of 67/80. Zika virus infection was diagnosed by his primary physician with a positive qualitative ZIKV ribonucleic acid (RNA) real-time reverse-transcription polymerase chain reaction (RT-PCR) in urine and serum at a local laboratory (Quest Diagnostics), 5 days postsymptom onset (Table 1); additional sample from this time point was not available for further testing. Dengue virus (DENV) RNA was not detected in subsequent samples; chikungunya virus (CHKV) and West Nile virus (WNV) PCRs were not performed.

**Table 1. Zika Virus RNA by RT-PCR, Serology, and Neutralizing Antibody Titers**

Days Post Onset of Symptoms	5	13	34	76
<b>Zika Virus RT-PCR</b>				
Serum	Positive	Negative	Negative	Negative
Urine	Positive	Negative	Negative	Negative
Whole Blood	ND	Positive BQL	Positive BQL	Positive BQL
Saliva	ND	Negative	Negative	Negative
Semen	ND	ND	Positive BQL	Negative
<b>Dengue Virus RT-PCR</b>				
Serum	ND	Negative	Negative	Negative
<b>Zika Virus Serology</b>				
ZIKV IgM <sup>a</sup> ELISA	ND	8.9	8.9	3.6
ZIKV IgG ELISA	ND	7.1	7.2	5.7
<b>Neutralizing Antibody Titers</b>				
ZIKV FRNT <sub>50</sub>	ND	3028	1003	543
DENV1 FRNT <sub>50</sub>	ND	2419	1791	413
DENV2 FRNT <sub>50</sub>	ND	1709	306	138
DENV3 FRNT <sub>50</sub>	ND	1411	2020	637
DENV4 FRNT <sub>50</sub>	ND	2191	390	164

Abbreviations: BQL, below quantifiable limit; DENV1,2,3,4, dengue serotypes 1 to 4; ELISA, enzyme-linked immunosorbent assay; FRNT<sub>50</sub>, serum titer with ≥50% reduction in number of foci in the Focus Reduction Neutralization Test; IgG, immunoglobulin; ND, not done; RNA, ribonucleic acid; RT-PCR, reverse-transcription polymerase chain reaction; ZIKV, Zika virus.

<sup>a</sup>IgM and IgG ELISA interpretation: negative <2, equivocal ≥2 to <3, positive ≥3.

The patient provided informed consent to join a natural history study of Zika virus infection (NIH/NIAID/DMID 16-0017), which was approved by Emory University Institutional Review Board. Signs and symptoms, clinical laboratory tests, and virologic and immunologic assays were performed at time points designated as days post onset of symptoms (DPO). Specimens were tested for ZIKV using quantitative real-time RT-PCR assay [5]. On DPOs 13, 34, and 76, his serum, urine, and saliva were negative for ZIKV RNA, but whole blood was positive on all 3 days at a low level (Table 1). His semen contained ZIKV RNA on DPO 34 but was negative on DPO 76. Serologic testing for anti-ZIKV immunoglobulin (Ig)M (monoclonal antibody capture enzyme-linked immunosorbent assay) was positive on DPO 13 and remained positive on DPO 76 [6]. Neutralizing antibody titer (by 50% focus reduction neutralization test or FRNT<sub>50</sub>) for ZIKV peaked on DPO 13 (3028), and DENV-1–4 titers were also positive (1411–2419). ELISpot assays for antibody-secreting cells against ZIKV, DENV 1–4, WNV, and YFV were negative on DPO 13. On DPOs 13 and 34, antiviral CD4<sup>+</sup> and CD8<sup>+</sup> T cells against peptides from multiple ZIKV proteins were present (Table 2).

## DISCUSSION

Zika illness is generally described as a self-limited illness that typically resolves within 1 to 2 weeks after symptom onset [1]. The patient presented here acquired ZIKV infection via autochthonous transmission in the continental United States. He had an interesting biphasic Zika illness with initial improvement and near resolution of signs and symptoms and then a relapse of rash and worsening joint pains and conjunctivitis 4 weeks after acute infection. Concurrent infection with other arboviruses such as CHKV and DENV have been reported in ZIKV outbreaks [7]. However, it is highly unlikely that our patient had either of these as concurrent infections. Dengue virus real-time RT-PCR of whole blood samples collected on DPOs 13, 34, and 76 were negative [8], and only 2 cases of locally acquired dengue infection were reported in Florida in 2016 [9]. It is also unlikely that he had concurrent infection with CHKV because no locally

**Table 2. ZIKV-Specific CD4<sup>+</sup> and CD8<sup>+</sup> T-Cell Responses in PBMC From DPOs 13 and 34<sup>a</sup>**

	DPO	C	prM	E	NS1	NS2A	NS2B	NS3	NS5
CD4 <sup>+</sup> T Cells	<b>13</b>	0.007	0.002	0.074	<b>0.114</b>	0.027	0.065	<b>0.137</b>	<b>0.138</b>
	<b>34</b>	0.015	0.01	0.037	0.092	0.007	0.021	0.077	0.089
CD8 <sup>+</sup> T Cells	<b>13</b>	0.027	<b>0.161</b>	<b>0.174</b>	0.039	0.034	0.028	<b>0.106</b>	<b>0.162</b>
	<b>34</b>	0.009	0.034	<b>0.112</b>	0.036	0.011	0.009	0.061	<b>0.133</b>

Abbreviations: DPOs, days post onset of symptoms; IFN, interferon; IL, interleukin; PBMC, peripheral blood mononuclear cells; MIP, macrophage inflammatory protein; TNF, tumor necrosis factor.

<sup>a</sup>The percentages of cytokine-producing cells among all CD4<sup>+</sup> or CD8<sup>+</sup> T cells are shown, and these were determined by intracellular cytokine staining and flow cytometry; data for peptide pools spanning 8 of the 10 ZIKV proteins are presented. Production of 5 cytokines (IFN $\gamma$ , IL2, TNF $\alpha$ , CD107, and MIP-1b) were summed in a Boolean analysis. Percentages >0.1% (bolded in the table) were considered significantly elevated relative to healthy human controls (data not shown). CD4<sup>+</sup> T cells mounted their strongest responses against the nonstructural proteins NS1, NS3, and NS5, on DPO 13 and were decreased on DPO 34. CD8<sup>+</sup> T cells mounted their strongest responses against the structural proteins prM and E and the nonstructural proteins NS3 and NS5 (again DPO 13 > DPO 34).

acquired chikungunya cases were reported in Florida in 2016 [9]. There were 6 cases of WNV in Florida in 2016 and none were in the Miami area [9].

Biphasic illness had been described with other flaviviruses such as dengue where the fever lasts for 5 to 7 days during initial infection followed by resolution [10, 11]. Relapse (in ~5% of cases) of a second phase of fever lasting 1 to 2 days (“saddleback” pattern) has been associated with more severe illness [10, 11]. In these cases, as the rash fades or desquamates, localized clusters of petechiae on the extensor surfaces of the limbs may remain. Recovery may be followed by a prolonged period of listlessness, easy fatigability, and even depression [10]. The pathogenesis of this phenomenon in dengue remains unknown. To further elucidate the cause of relapsing rash, a skin biopsy may have been useful but was not performed in our patient. Skin biopsy findings of ZIKV rash in a pregnant woman showed mild lymphocytic infiltration in the upper dermis mixed with neutrophils [12]. There are anecdotal reports of recurrent Zika rash syndromes, but none have been reported in literature.

The pathogenesis of the biphasic pattern of ZIKV illness is not known. Perhaps it is related to ongoing viremia, older age, or comorbid illnesses that could lead to aberrant immune responses. Rebound viremia was noted in experimental ZIKV infection of nonhuman primates, 30 days postinfection [13]. Persistence of virus in sanctuary sites such as the testes and central nervous system were considered as possible sources [13]. In serum, the median time to loss of detection of ZIKV RNA by PCR was 14 days (95% confidence interval, 11–17 days) in a large cohort of patients observed in Puerto Rico [14]. In comparison, DENV could be detected in serum up to 10 days [14]. At the time of recurrent illness (DPO 34), our patient was negative for ZIKV in serum but had detectable ZIKV RNA in both whole blood and in semen [15]. However, detection of viral RNA does not necessarily correlate with infectious virus [14]. Age and comorbid illness such as liver disease may have contributed to our patient’s relapse of signs and symptoms. Although our patient did not have any signs of neurological disease, older men are reported to have more severe ZIKV-related GBS [4].

Our patient had pre-existing immunity to DENV, which is consistent with his extensive travel to dengue-endemic areas. High-neutralizing antibody titers against DENV during early ZIKV infection in our patient is consistent with a secondary flavivirus infection [5, 6]. In this patient, the roles of pre-existing flavivirus immunity (from both past DENV infection and YFV vaccination) and its contribution to the biphasic illness remain unknown.

## CONCLUSIONS

Zika virus illness can present as a biphasic illness with relapse of symptoms after initial improvement or resolution. The etiology of a biphasic presentation remains unclear but could be due to persistent viremia or viral persistence in so-called “sanctuary sites” and could be an indicator of more severe illness.

## Acknowledgments

We thank the staff at the Hope Clinic (Allison Beck, Dean Kleinhenz, Jo Ann Sadowski, and Jean Winter) and the Hope Clinic laboratory personnel (Pamela Lankford-Turner, Sree Aramgam, Dongli Wang, and Vinit Karmali).

**Financial support.** This work was funded by the National Institutes of Health/National Institutes of Allergy and Infectious Diseases/Division of Microbiology and Infectious Diseases/Vaccine and Treatment Evaluation Units at Emory University (Contract No. HHSN272201300018I funding the DMID 16-0017 study) and at the Baylor College of Medicine (Contract No. HHSN27220130015I). Additional funding was provided by the Georgia Research Alliance.

**Potential conflicts of interest.** All authors: No reported conflicts of interest. All authors have submitted the ICMJE Form for Disclosure of Potential Conflicts of Interest. Conflicts that the editors consider relevant to the content of the manuscript have been disclosed.

## References

- Petersen LR, Jamieson DJ, Powers AM, Honein MA. Zika virus. *N Engl J Med* 2016; 374:1552–63.
- Centers for Disease Control and Prevention. Zika Virus: 2017 Case Counts in the US. Available at: <https://www.cdc.gov/zika/reporting/2017-case-counts.html>. Accessed 2 June 2017.
- Broutet N, Krauer F, Riesen M, et al. Zika virus as a cause of neurologic disorders. *N Engl J Med* 2016; 374:1506–9.
- Dos Santos T, Rodriguez A, Almiron M, et al. Zika virus and the Guillain-Barré Syndrome - case series from seven countries. *N Engl J Med* 2016; 375:1598–601.
- Lanciotti RS, Kosoy OL, Laven JJ, et al. Genetic and serologic properties of Zika virus associated with an epidemic, Yap State, Micronesia, 2007. *Emerg Infect Dis* 2008; 14:1232–9.

6. Rabe IB, Staples JE, Villanueva J, et al. Interim guidance for interpretation of Zika virus antibody test results. *MMWR Morb Mortal Wkly Rep* **2016**; 65:543–6.
7. Roth A, Mercier A, Lepers C, et al. Concurrent outbreaks of dengue, chikungunya and Zika virus infections - an unprecedented epidemic wave of mosquito-borne viruses in the Pacific 2012–2014. *Euro Surveill* **2014**; 19: pii20929.
8. Gurukumar KR, Priyadarshini D, Patil JA, et al. Development of real time PCR for detection and quantitation of dengue viruses. *Virology* **2009**; 6:10.
9. Florida Department of Health. Florida Arbovirus Surveillance. Week 52: December 25-31, 2016. Available at: [http://www.floridahealth.gov/diseases-and-conditions/mosquito-borne-diseases/\\_documents/2016/week52ArbovirusReport-12-31-16.pdf](http://www.floridahealth.gov/diseases-and-conditions/mosquito-borne-diseases/_documents/2016/week52ArbovirusReport-12-31-16.pdf). Accessed 5 June 2017.
10. Bennett JE, Dolin R, Blaser MJ. *Mandell, Douglas, and Bennett's Principles and Practice of Infectious Diseases*. 8th ed. Philadelphia, PA: Elsevier/Saunders, **2015**.
11. Ng DH, Wong JG, Thein TL, et al. The Significance of prolonged and saddleback fever in hospitalised adult dengue. *PLoS One* **2016**; 11:e0167025.
12. Chen L, Hafeez F, Curry CL, Elgart G. Cutaneous eruption in a U.S. woman with locally acquired Zika virus infection. *N Engl J Med* **2017**; 376:400–1.
13. Koide F, Goebel S, Snyder B, et al. Development of a Zika virus infection model in cynomolgus macaques. *Front Microbiol* **2016**; 7:2028.
14. Paz-Bailey G, Rosenberg ES, Doyle K, et al. Persistence of Zika virus in body fluids - preliminary report. *N Engl J Med* **2017**; doi: 10.1056/NEJMoa1613108.
15. Matheron S, d'Ortenzio E, Leparac-Goffart I, et al. Long-lasting persistence of Zika virus in semen. *Clin Infect Dis* **2016**; 63:1264.