



Triathlete with Multiple Stress Fractures in the Lower Limbs: Case Report and Literature Review*

Triatleta com múltiplas fraturas por estresse nos membros inferiores: Relato de um caso e revisão da literatura

Adriano Fernando Mendes Junior¹ Caio Gomes Tabet² Samuel Lopes Mendes³
Marcus da Matta Abreu⁴ Nathália Carvalho de Figueirêdo⁵

¹ Sports Trauma Outpatient Clinic, Hospital Universitário, Universidade Federal de Juiz de Fora, Juiz de Fora, MG, Brazil

² Medical Residency Program in Orthopedics and Traumatology, Hospital Universitário, Universidade Federal de Juiz de Fora, Juiz de Fora, MG, Brazil

³ Department of Orthopedics and Traumatology, Santa Casa de Misericórdia de Juiz de Fora, Juiz de Fora, MG, Brazil

⁴ Urgency and Emergency Medicine and Sports Medicine Courses, Universidade Federal de Juiz de Fora, Juiz de Fora, MG, Brazil

⁵ Department of Sports Medicine, Esporte Clube Vitória, Salvador, BA, Brazil

Address for correspondence Adriano Fernando Mendes Júnior, MD, MSc., Rua Luiz Perry, 165, apto. 703, Santa Helena, Juiz de Fora, MG, 36015-380, Brazil (e-mail: adrianofmjr@yahoo.com.br).

Rev Bras Ortop 2021;56(6):813–818.

Abstract

Recurrent stress fractures rarely affect the same athlete. We present the case of a female triathlete who suffered multiple stress fractures in both tibias, the right fibula, and the left femoral neck. Conservative treatment was instituted in all episodes, with rest, reduced training load, and physical therapy rehabilitation. The relative energy deficiency in sport syndrome, along with an eating disorder, training overload, and osteopenia, was identified as a risk factor. Although rare, multiple stress fractures can occur in female triathletes. These patients must be screened for risk factors associated with biomechanics, nutrition, and training to develop an effective prevention and treatment program.

Keywords

- ▶ fractures, stress
- ▶ female athlete triad syndrome
- ▶ case reports

Resumo

Fraturas por estresse recorrentes num mesmo atleta são raras. Apresentamos o caso de uma triatleta que sofreu múltiplas fraturas por estresse na tíbia bilateral, na fíbula direita e no colo femoral esquerdo. O tratamento conservador foi instituído em todos

* Study developed at Hospital Universitário, Universidade Federal de Juiz de Fora, Juiz de Fora, MG, Brazil.

received
May 5, 2020
accepted
March 8, 2021

DOI <https://doi.org/10.1055/s-0041-1739404>.
ISSN 0102-3616.

© 2021. Sociedade Brasileira de Ortopedia e Traumatologia. All rights reserved.
This is an open access article published by Thieme under the terms of the Creative Commons Attribution-NonDerivative-NonCommercial-License, permitting copying and reproduction so long as the original work is given appropriate credit. Contents may not be used for commercial purposes, or adapted, remixed, transformed or built upon. (<https://creativecommons.org/licenses/by-nc-nd/4.0/>)
Thieme Revinter Publicações Ltda., Rua do Matoso 170, Rio de Janeiro, RJ, CEP 20270-135, Brazil

Palavras-chave

- ▶ fraturas de estresse
- ▶ síndrome da tríade da mulher atleta
- ▶ relatos de casos

os episódios, com repouso, redução da carga de treino e reabilitação fisioterápica. Foi identificada como fator de risco a síndrome da deficiência energética relativa no esporte, com distúrbio alimentar, sobrecarga de treino e osteopenia. Mesmo que seja raro, múltiplas fraturas por estresse podem ocorrer em mulheres triatletas, nas quais é importante avaliar os fatores de risco associados à biomecânica, nutrição e ao treinamento para arquitetar um programa de prevenção e tratamento efetivo.

Introduction

Recurrent stress fractures rarely affect the same athlete. They account alone for 10% of sports injuries.¹ These fractures are considered atypical cases, requiring screening for predisposing factors.^{2,3} Female athlete triad syndrome was redefined to a broader spectrum, now called relative energy deficiency

in sport (RED-S) syndrome.³ This syndrome mainly results from metabolic changes due to nutritional imbalances. Athletes with RED-S syndrome are at an increased risk for fractures, as this condition is associated with hormonal dysfunction and reduced bone mineral density (BMD).³

The present study describes the case of a female triathlete with RED-S syndrome with multiple stress fractures and

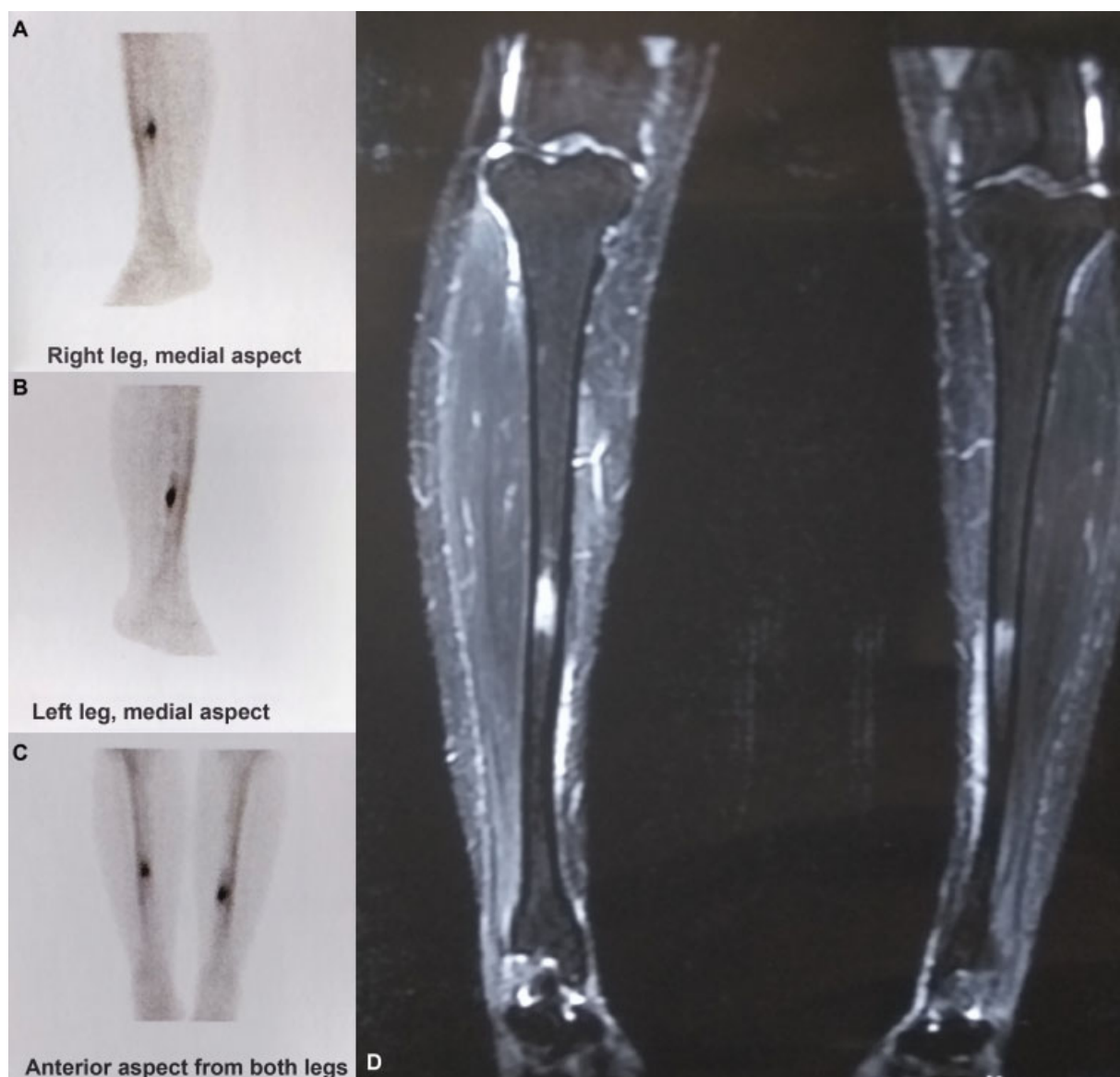


Fig. 1 Test images revealing tibial stress fractures. (A, B and C). Bone scintigraphy scan images, (D) T2-weighted magnetic resonance imaging scan.

reviews the associated risk factors. An informed consent form was signed by the patient. This manuscript was written according to the CARE guidelines for case reports⁴ and approved by the research ethics committee (CAAE 22982819.8.0000.5133).

Case Report

The patient described in the present report is a 34-year-old female triathlete, with a body mass index (BMI) of 20 kg/cm², and a history of polycystic ovary syndrome, bulimia (sic), menstrual irregularity, and anxiety disorder.

Eight years ago, after 6 months of running (4 times a week) supervised by a physical educator, the patient complained of atraumatic, progressive pain in the anterior aspect of the right leg, which worsened, became bilateral, and prevented

training. She was evaluated by an orthopedist, who suspected a stress fracture. Bone scintigraphy and magnetic resonance imaging (MRI) scans revealed bilateral damage to the posterior cortex of the tibial diaphysis (–Figure 1). At the time, the patient reported that she was voluntarily on a caloric deficit diet for weight loss and presented a bulimic behavior. The treatment was conservative, with no sports practice for 2 months. The patient was referred to a sports dietitian for a dietary energy readjustment but had no specific treatment for bulimia. In addition, the patient visited a gynecologist, who told her that her hormonal tests came back normal (sic). Physical activity was resumed with walking and cycling, progressing under supervision; lack of pain was a criterion for training intensification. The patient resumed running after 8 months, and also practiced swimming and cycling with no complaints. She was followed up by

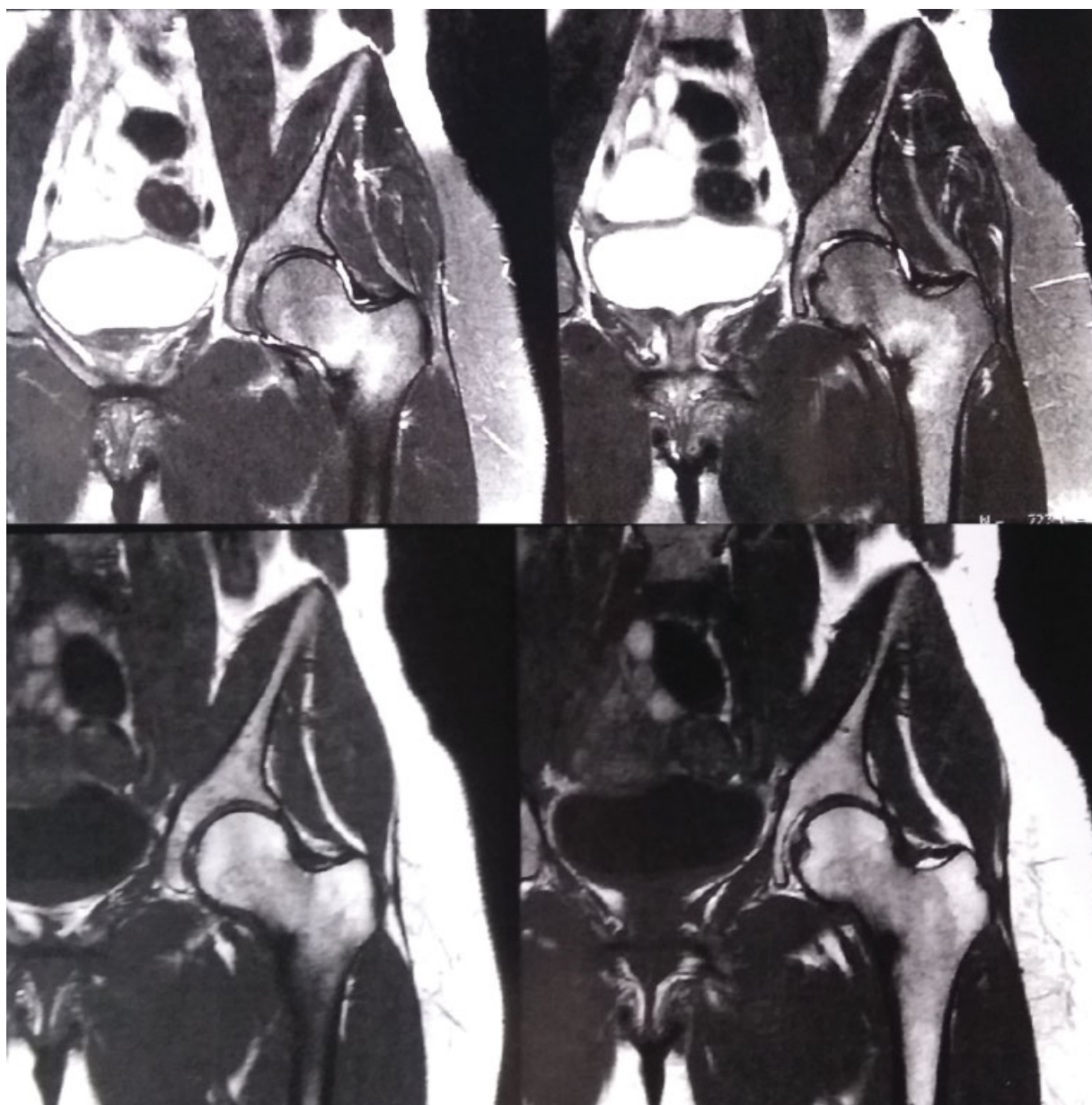


Fig. 2 T2-weighted magnetic resonance imaging scan revealing a hypersignal at the medial cortex of the femoral neck.

a dietitian and reported an adequate energy supply. Although the patient did not seek medical advice for bulimia, she stated that there was no recurrence of these symptoms after nutritional treatment.

Three years later, under a high-intensity daily training for triathlon, the patient complained of insidious pain in the lateral aspect of the right leg when running, preventing the practice. An orthopedic medical evaluation was performed, and an MRI scan showed a stress fracture in the right fibular diaphysis. The patient reported using insoles for pronated feet, which were prescribed by a physical therapist. We advised her to stop running, which lasted for 8 months, and to maintain lower limb muscle strengthening and proprioception with swimming and cycling at a reduced intensity and incremental progressive load supervised by a coach.

Upon resuming running, she was instructed not to use the insoles anymore and to wear comfortable sneakers for training and competitions. After 1 year, during a medical visit, the patient reported being asymptomatic; biochemical tests revealed no alterations, and bone density scan showed osteopenia. We prescribed a daily oral supplementation with calcium (500 mg) and vitamin D (1,000 IU).

Two years after the last fracture, with no symptoms and still under nutritional care, during a high-intensity training cycle supervised by a coach, the patient started to feel progressive left hip pain when running; the pain was refractory to a decrease in training volume. A new orthopedic medical evaluation diagnosed a stress fracture in the medial cortex of the left femoral neck (→ **Figure 2**). As a treatment, the patient was instructed to restrict load on the limb and to

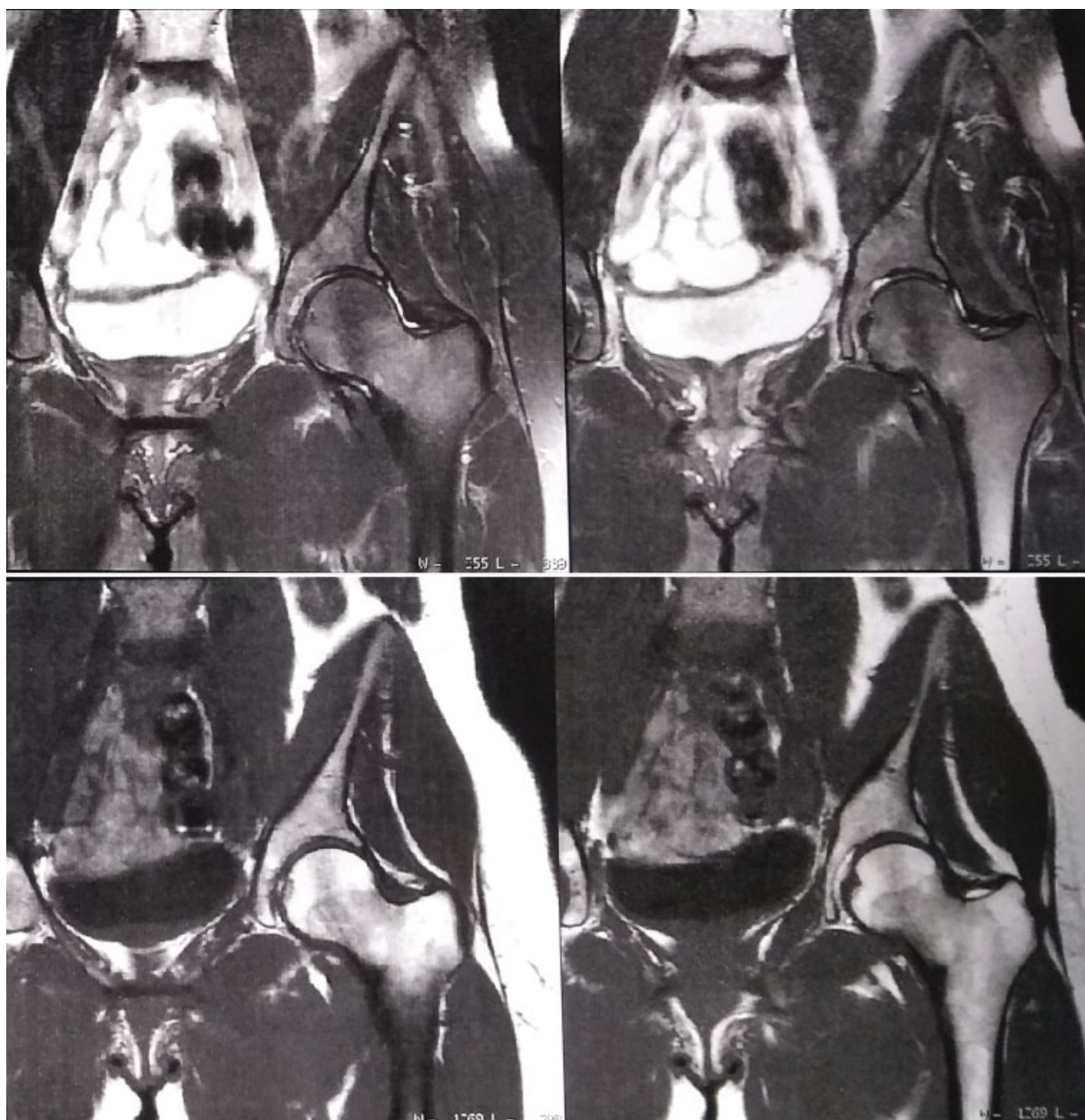


Fig. 3 T2-weighted magnetic resonance imaging scan confirming femoral neck fracture consolidation.

use crutches. After 15 days, she resumed swimming (free-style), twice a week. After 2 months, she was pain-free and resumed cycling, with slow load and training volume progression. Four months after the diagnosis, at a medical visit, a new MRI scan was requested (–Figure 3), which revealed fracture consolidation. Running was resumed, with weekly progression of 10% of the training volume, accompanied by a physical educator. Eight months after the diagnosis of femoral neck fracture, the patient returned to triathlon, participating in two competitions with no complaints (–Figure 4).

Discussion

Stress fractures occur in healthy athletes submitted to cyclic physical overload; bone turnover imbalance and osteoclastic activity predominance result in microfractures and, eventually, complete fractures.⁵ This case describes an apparently healthy athlete who had four stress fractures. The most common symptom of stress fracture is mechanical pain;⁶ the lower limbs are more commonly affected, accounting for almost 90% of cases.⁷ In running, stress fractures are associated with training overload, especially when the weekly mileage is high.^{6,7} Running was the common training at all occurrences, highlighting it as a risk factor.

Additional risk factors for recurrent fractures include reduced vitamin D levels, eating disorders, anxiety, calorie deficit, menstrual disorders, BMI < 21 kg/m², and low BMD.^{2,6,7} Together, these conditions result in RED-S syndrome.³ The imbalance between energy intake and expenditure, associated with exhaustive training and excessive concerns with performance and aesthetics, leads to hormonal dysfunction, with an increased risk for stress fractures.^{3,8} We believe that despite the occurrence of other fractures, the sustained good nutrition helped the treatment of the first injury and the follow-up of subsequent events. Biomechanical changes of the plantar arch and footstep types are potential risk factors for stress fractures, but clinical evi-

dence is low.⁸ We decided to ask the patient not to use the prescribed insoles, and there was no fibular fracture recurrence.

Biochemical tests, including calcium, 25(OH)D₃, and albumin levels, are requested during the investigation for multiple fractures.⁹ As for imaging tests, the gold standard is MRI, with 100% sensitivity and 85% specificity.¹⁰ Bone mineral density scan is indicated when RED-S syndrome is suspected.^{2,3} In our case, despite the normal findings in biochemical tests, calcium and vitamin D supplementation were instituted due to osteopenia.

Stress fractures are differentiated into “low” and “high” risk of pseudoarthrosis and refracture without surgical treatment.⁹ The patient’s fractures were classified as “low risk” since cortical strength was not affected. These injuries are conservatively managed,⁹ as performed in this case report. To prevent the fracture from becoming complete, patients should rest or reduce load for some time, but no immobilization is required.^{9,10} The gradual return to sports occurs after 10 to 14 days with normal radiographic findings and no pain.² Physical rehabilitation includes physical conditioning with no impact, and training adapted to the sports gesture, with 25% less training volume and 10% weekly increase at the tolerated load.^{2,3} Decreased high-intensity cycles are recommended, along with an adequate energy supply.^{3,6} Unrestricted practice is medically authorized only when a new MRI scan shows bone healing.^{9,10}

The strengths of this report included the rarity of the case, the occurrence of fractures during the same gesture (running), and the favorable evolution with treatment and secondary prevention. The main limitation of the study was the difficult access to the implemented training program, as its details could demonstrate an association between overload and multiple stress fractures.

Multiple stress fractures in female triathletes are rare. These injuries can be associated with risk factors, such as inadequate nutrition, bulimic behavior, and training

- 2012 = The patient started to run as an amateur.
- 2012 = Left and right tibial stress fractures. Temporary running suspension and slow progression of training volume.
- 2014 = The patient started triathlon.
- 2015 = Right fibular stress fracture. Training load reduction and specific physical therapy.
- 2016 = Osteopenia diagnosis and supplementation start.
- April 2017 = Medial cortical stress fracture at the left femoral neck. Patient is advised to use crutches, with subsequent return to swimming and physical therapy rehabilitation.
- August 2017 = Bone healing is confirmed and gradual return to running and cycling.

Fig. 4 Timeline.

overload. The identification of these factors is critical to treat such injuries and perform an effective secondary prevention in triathlon.

Financial Support

There was no financial support from public, commercial, or non-profit sources.

Conflict of Interests

The authors declare no conflict of interests.

Acknowledgments

The authors are grateful to prof. Anelise Monteiro for formatting this article.

References

- 1 Romani WA, Gieck JH, Perrin DH, Saliba EN, Kahler DM. Mechanisms and management of stress fractures in physically active persons. *J Athl Train* 2002;37(03):306–314
- 2 Astur DC, Zanatta F, Arliani GG, et al. Fraturas por estresse: definição, diagnóstico e tratamento. *Rev Bras Ortop* 2016;51(01):3–10
- 3 Mountjoy M, Sundgot-Borgen J, Burke L, et al. The IOC consensus statement: beyond the Female Athlete Triad—Relative Energy Deficiency in Sport (RED-S). *Br J Sports Med* 2014;48(07):491–497
- 4 Riley DS, Barber MS, Kienle GS, et al. CARE guidelines for case reports: explanation and elaboration document. *J Clin Epidemiol* 2017;89:218–235
- 5 Harrast MA, Colonno D. Stress fractures in runners. *Clin Sports Med* 2010;29(03):399–416
- 6 Royer M, Thomas T, Cesini J, Legrand E. Stress fractures in 2011: practical approach. *Joint Bone Spine* 2012;79(Suppl 2):S86–S90
- 7 Korpelainen R, Orava S, Karpakka J, Siira P, Hulkko A. Risk factors for recurrent stress fractures in athletes. *Am J Sports Med* 2001;29(03):304–310
- 8 Goolsby MA, Boniquit N. Bone health in athletes. *Sports Health* 2017;9(02):108–117
- 9 Miller TL, Kaeding CC. ISAKOS clinical update on stress fractures: Classification and management. *ISAKOS Newsletter* 2015;1:24–27
- 10 McInnis KC, Ramey LN. High-risk stress fractures: diagnosis and management. *PM R* 2016;8(3, Suppl):S113–S124