

# The feasibility and radiological features of sacral alar iliac fixation in an adult population: a 3D imaging study

Ai-Min Wu, Yong-Long Chi, Wen-Fei Ni and Yi-Xing Huang

Department of Orthopaedic Surgery, Second Affiliated Hospital of Wenzhou Medical University, Zhejiang Spinal Research Center, Wenzhou, Zhejiang, China

## ABSTRACT

**Background:** Surgical treatments for adult spinal deformities often include pelvic fixation, and the feasibility of sacral-2 alar iliac (S2AI) screw fixation has been shown previously. However, sometimes S2AI screw fixation cannot be applied due to the presence of an osteolytic lesion or trauma or because the biomechanical properties of only an S2AI screw is insufficient. Therefore, we questioned the feasibility of using sacral AI screws in other segments and determined whether S3AI and S4AI screws have the potential to be used for sacral fractures. The aim of this study was to investigate the feasibility and radiological features of sacral AI fixation in S1–S4 in an adult population using 3D imaging techniques. **Methods:** Computed tomography (CT) scans were taken of 45 patients and were imported into Mimics (Version 10.01, Materialise, Belgium) software to reconstruct the 3D digital images. Next, a cylinder (radius of 3.5 mm) was drawn to imitate the screw trajectory of a S1–4 AI screw, and every imitated screw in each segment was adjusted to a maximum upward and downward angle to acquire the feasible region. The parameters of the S1–4AI screw trajectories were measured. **Results:** Sacral AI screws could be successfully imitated using 3D digital imaging. The S4AI screw trajectory could be obtained in 19 of 45 patient images (42.2%), while the feasibility rates of S1AI, S2AI, and S3AI screw fixation were 100%, 100%, and 91.1% (41/45), respectively. The feasible regions of S1AI, S2AI, and S3AI screw trajectories were wide enough, while the adjustable angle of S4AI screws was very small. **Conclusion:** It is feasible to place S1–2AI screws in the entire adult population and S3–4AI screws in some of the adult population. Furthermore, our study suggested that 3D digital images are suitable to study the feasibility of new screw fixation.

Submitted 30 July 2015

Accepted 20 December 2015

Published 25 January 2016

Corresponding authors

Wen-Fei Ni, wenfeini@yeah.net

Yi-Xing Huang,

spinehuang@126.com

Academic editor

Ferdinand Frauscher

Additional Information and  
Declarations can be found on  
page 7

DOI 10.7717/peerj.1587

© Copyright

2016 Wu et al.

Distributed under

Creative Commons CC-BY 4.0

**OPEN ACCESS**

**Subjects** Orthopedics, Radiology and medical imaging, Surgery and surgical specialties

**Keywords** Sacral fracture, Radiological study, Sacral alar iliac screw, Adult population, 3D digital images, Sacral fracture

## INTRODUCTION

Surgical treatments for adult spinal deformity often include pelvic fixation, and the high rate of pseudarthrosis in distal fixation in spinal deformity is a challenge for spinal surgeons (*Edwards et al., 2004; Edwards et al., 2003; Kim et al., 2006*). A novel technique for sacral-2 alar iliac (S2AI) screw fixation has been introduced for distal fixation (*O'Brien et al., 2009*), and it has been reported that the S2AI screw can be inserted by an

open or percutaneous approach (Martin, Witham & Kebaish, 2011; O'Brien et al., 2010). The percutaneous approach has the advantages of being minimally invasive, causing less blood loss, and having a lower rate of wound infection and quicker postoperative recovery times (Martin, Witham & Kebaish, 2011; Xu et al., 2013). In addition, the feasibility of S2AI screw fixation has been shown by previous studies (Kwan et al., 2012; O'Brien et al., 2010; Zhu et al., 2013).

However, sometimes the S2AI screw cannot be applied due to an osteolytic lesion or trauma (O'Brien et al., 2009) or because the biomechanical properties of only an S2AI screw are insufficient. Therefore, we questioned the feasibility of using sacral AI screws in other segments.

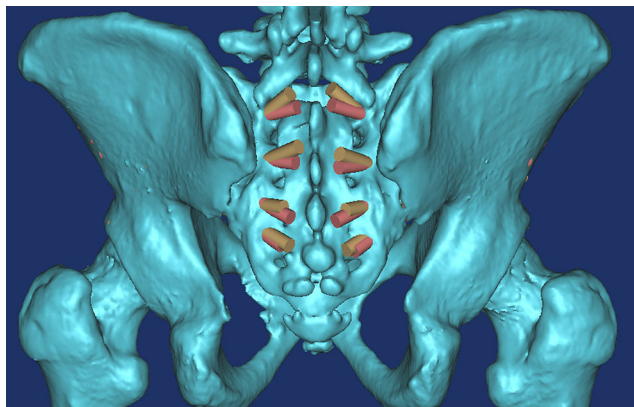
In this study, we used Mimics 3D imaging software (Version 10.01, Materialise, Belgium) to investigate the feasibility of S1–4AI screw fixation. This software has previously been shown to provide an accurate visual screw trajectory (Wu et al., 2013).

## MATERIALS AND METHODS

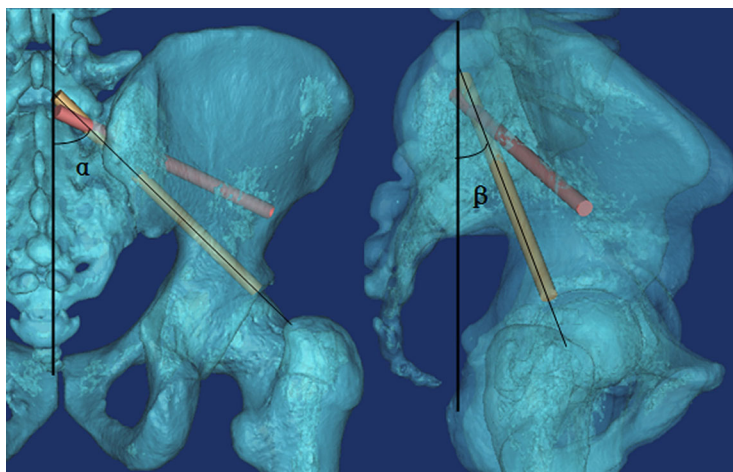
This research was performed following the principles described in the Declaration of Helsinki and was approved by the Institutional Ethics Review Board of the Second Affiliated Hospital of Wenzhou Medical University (No. 2015–30). Written informed consent was obtained from all participants.

Computed tomography (CT) scans (Dicom format) were taken of the pelvic regions of 45 patients and were imported into Mimics software (Version 10.01, Materialise, Belgium) for reconstructing the 3D digital images (Wu et al., 2014), which only takes about 10 minutes for one subject. The mean age of the patients was  $53.6 \pm 19.5$  years old and ranged from 20 to 84 years old. Briefly, their CT scans in DICOM format were imported into Mimics software for three-dimensional (3D) reconstruction; the threshold value was set at “Bone (CT)” as “226-Max,” which is optimal for bone reconstruction. After the 3D digital images were calculated and reconstructed, a cylinder (radius of 3.5 mm) was drawn to imitate the screw trajectory of S1–4AI screws. The feasibilities of S1–4AI screw fixation were first observed by adjusting the angle and the ideal entry point. The ideal entry point was at the inner fovea of the transverse process of the sacrum (Fig. 1), from S1 to S4, and it was a line, not limited to a determined point. To point the screw trajectory away from the dorsal sacral foramina, we chose the screw entry point as the cross of the middle line between the upper and lower dorsal sacral foramina and the line of the inner fovea of the transverse process of the sacrum. After the screw entry point was determined, every imitated screw in each segment was adjusted to the maximum upward and downward angles, which means the screw trajectories were adjusted maximum upward or downward, but not penetrated out of the cortex of the pelvic bone.

The following three measurements were obtained for each imitated screw (Figs. 2 and 3): (1)  $\alpha$ , the angle between the screw trajectory and the erect line from the anteroposterior view (Fig. 2A); (2)  $\beta$ , the angle between the screw trajectory and the erect line from the lateral view (Fig. 2B); and (3) L, the length of the screw inside of the bone (Fig. 3). Moreover, the possible application of percutaneous S3–4AI screw fixation for



**Figure 1** All of the S1AI-S4AI screw trajectories were simulated on 3D digital image; the ideal entry point was at the inner fovea of the transverse process of the sacrum.



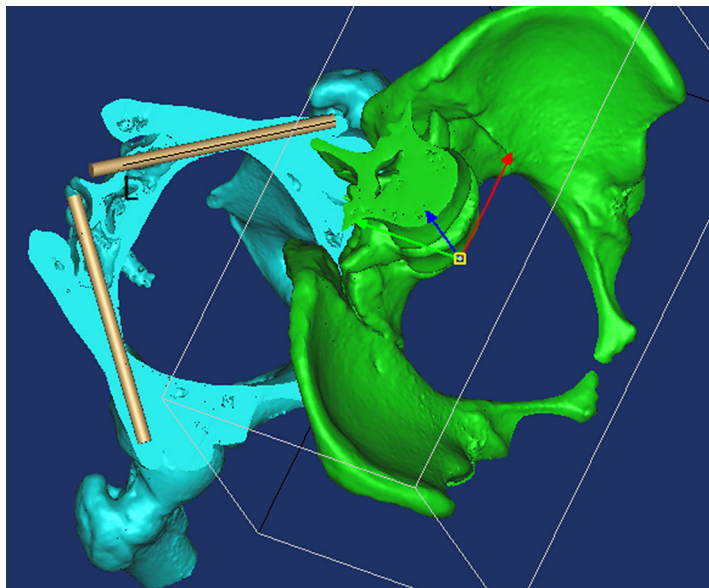
**Figure 2** (A) The angle between the screw trajectory and the erect line from the anteroposterior view; (B) The angle between the screw trajectory and the erect line from the lateral view. (The yellow trajectory is the maximum downward screw; the red trajectory is the maximum upward screw).

sacral fracture was noted and imitated. The measurements were performed by two surgeons (AMW and YXH), and the mean value was used for calculated, the Intraclass Correlation Coefficient (ICC) was calculated to assess how strongly the data from two surgeons resembled each other. The results were represented as “Mean  $\pm$  Standard Deviation.”

## RESULTS

Sacral AI screws could be successfully imitated by 3D digital imaging, the ICC between the data from two surgeons was 0.893, which is  $>0.800$ , means the data measured by two surgeons was strongly consistent to each other.

By observing the 3D images, we found that the ideal screw entry point was at the inner side of the transverse process of the sacrum from S1–S4 (Fig. 1) and that the screw could not be applied at S5. The S4AI screw trajectory could be obtained only in



**Figure 3** By using the “Cut,” “Split,” and “Reposition” functions in the Mimics software, the screw trajectory was clearly observed so that the screw trajectory could be adjusted conveniently. L, The length of the screw inside of bone.

19 of 45 patient images (42.2%); the feasibility rates of S1AI, S2AI, and S3AI were 100%, 100%, and 91.1% (41/45), respectively.

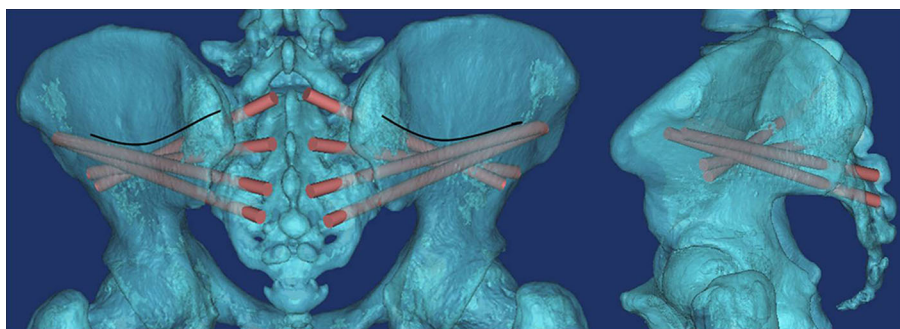
We found that from S1AI to S4AI, the  $\alpha$  angle of maximum upward screw trajectory (Fig. 1A) was gradually increased from  $54.5 \pm 6.71^\circ$  to  $111.2 \pm 4.90^\circ$ , and the  $\beta$  angle of maximum upward screw trajectory (Fig. 1B) was gradually increased from  $43.6 \pm 5.44^\circ$  to  $110.7 \pm 5.06^\circ$ ; while the  $\alpha$  angle of maximum downward screw trajectory was gradually increased from  $39.3 \pm 3.10^\circ$  to  $107.3 \pm 4.94^\circ$ , the  $\beta$  angle was gradually increased from  $30.1 \pm 5.37^\circ$ . And we found that the feasible region of the S1AI, S2AI, and S3AI screw trajectories was wide enough. The average adjustable  $\alpha$  angles of S1AI, S2AI, and S3AI screw trajectories were  $15.24^\circ$ ,  $29.43^\circ$ , and  $19.61^\circ$  in the left side and  $15.03^\circ$ ,  $29.47^\circ$ , and  $20.01^\circ$  in the right side, respectively. In contrast, the average adjustable angle of S4AI screws was very small: only  $4.05^\circ$  in the left side and  $3.58^\circ$  in the right side. Therefore, it was difficult to insert S4AI screws due to the small region of feasibility. The measurement parameters of the S1–4AI screw trajectories are shown in Table 1.

## DISCUSSION

In this study, we determined the feasibility of S1AI screw fixation as well as S2AI, S3AI, and S4AI screw fixation and found that they were all inserted successfully in the adult population. By using the “Cut,” “Split,” and “Reposition” functions in the Mimics software, we could observe the screw trajectory clearly (Fig. 3). We found that the ideal screw entry point was not limited to a determined point but rather the inner fovea line of the transverse process of the sacrum from S1 to S4. In order to describe the trajectory of sacral AI screws in different segments, the entry point of the screw trajectory was chosen as

**Table 1** Parameters of S1–4AI screw trajectory measurements (Mean±standard deviation).

		Maximum upward screw trajectory			Maximum downward screw trajectory		
		$\alpha$ (°)	$\beta$ (°)	L (mm)	$\alpha$ (°)	B (°)	L (mm)
S1AI	Left	54.5 ± 6.71	43.7 ± 5.22	98.7 ± 5.29	39.3 ± 3.10	30.2 ± 5.64	102.1 ± 5.04
(N = 45)	Right	55.8 ± 5.95	43.6 ± 5.44	101.6 ± 5.48	40.8 ± 3.50	30.1 ± 5.37	103.3 ± 6.30
S2AI	Left	79.1 ± 6.33	66.9 ± 4.24	105.8 ± 5.12	49.7 ± 5.78	46.0 ± 3.91	94.7 ± 4.53
(N = 45)	Right	80.32 ± 4.66	67.7 ± 4.51	106.6 ± 5.16	50.85 ± 5.91	48.5 ± 4.16	95.2 ± 4.91
S3AI	Left	96.4 ± 6.57	94.2 ± 4.23	118.6 ± 6.58	76.8 ± 5.57	73.1 ± 3.38	96.4 ± 5.19
(N = 41)	Right	97.6 ± 5.89	95.4 ± 5.26	117.3 ± 6.07	77.5 ± 5.72	73.6 ± 4.21	95.9 ± 5.46
S4AI	Left	111.2 ± 4.90	110.0 ± 5.27	140.4 ± 4.75	107.1 ± 5.84	107.0 ± 5.59	128.2 ± 5.66
(N = 19)	Right	110.9 ± 4.56	110.7 ± 5.06	139.7 ± 3.60	107.3 ± 4.94	107.4 ± 5.23	126.8 ± 4.97



**Figure 4** The region above the arc line is the iliac thin region. If the screw trajectory is adjusted to an upward angle that is too high, it will pierce the cortex of this region.

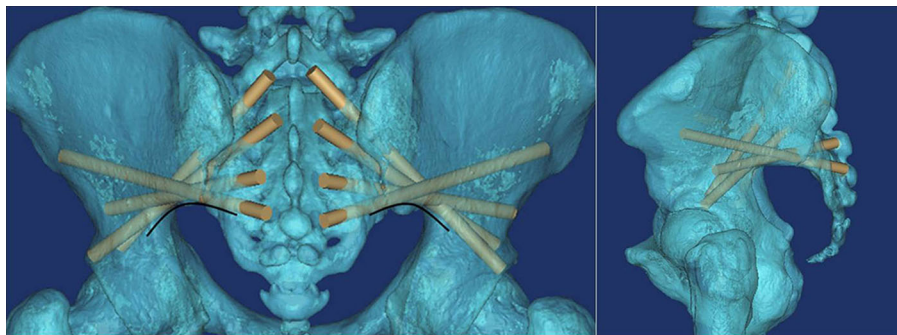
the middle of two adjacent dorsal sacral foramina on the inner fovea line of the transverse process of the sacrum.

Every sacral AI screw trajectory in each segment had a maximum upward angle and a maximum downward angle. If the screw trajectory overstepped the feasible region between the maximum upward angle and the maximum downward angle, the screw will pierce the cortex of the iliac thin region (Fig. 4) or the cortex of the inferior fovea of the ilium (Fig. 5), respectively, and may injure peripheral soft tissue and vessels.

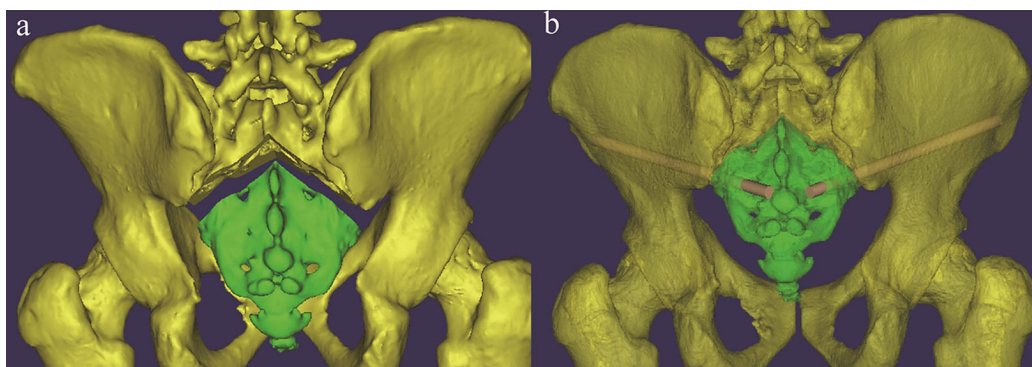
As shown in Table 1, the feasible region of the S1AI, S2AI, and S3AI screw trajectories was wide enough. The average adjustable  $\alpha$  angles of S1AI, S2AI, and S3AI screw trajectories were 15.24°, 29.43°, and 19.61° in the left side and 15.03°, 29.47°, and 20.01° in the right side, respectively. In contrast, the average adjustable angle of S4AI screws was very small: only 4.05° in the left side and 3.58° in the right side. Therefore, it was difficult to insert S4AI screws due to the small region of feasibility.

## VALUE IN CLINICAL CONDITIONS

In this study, more than in previous S2AI screw fixation (Kwan *et al.*, 2012; O'Brien *et al.*, 2010; Zhu *et al.*, 2013), we provide novel fixation of S1–AI, S3AI, and S4AI screws. All S1–4 AI screw trajectories were studied. Therefore, we provide an alternative



**Figure 5** The arc line is the inferior border of the ilium. If the screw trajectory is adjusted to a downward angle that is too high, it will pierce the cortex of the inferior fovea of the ilium.



**Figure 6** (A) Schematic diagram of a patient with a sacral fracture (Fracture was simulated in 3D images); (B) percutaneous S3–AI screw fixation was imitated after reduction.

fixation for surgeons, we believed that our alternative fixation could be performed on following clinical condition.

Firstly, the spine fixation may be extended to pelvic fixation, in S1, surgeons prefer to use an S1 pedicle screw. However, sometimes, the normal osseous structure is destroyed by a lytic lesion or trauma (*Martin, Witham & Kebaish, 2011*) or the application of a pedicle screw in S1 is impossible. For these situations, sacral AI screw fixation (S1–2AI screw fixation) is more suitable.

Secondly, patients with a sacral fracture as shown in *Fig. 6*, which is uncommon in the clinic but does happen sometimes, percutaneous S3AI or S4AI screw fixation is suitable technique for them. Our results shown that S3–4AI screws could performed on part of the adult population; therefore, we suggested that a preoperative CT scan should be obtained and a simulated trajectory should be made to prove the feasibility of S3–4AI screws fixation on them.

Therefore, studying the feasibility of sacral AI screw fixation (including S3–4AI screws) has value, and the technique of sacral AI screw fixation has great potential value in clinical applications as it is theoretically better than traditional pedicle screw fixation and the sacropelvic fixation technique (*O'Brien et al., 2013*).

## Limitations

This is a 3D image study without clinical cases. In a 3D image study, we need some reference line to measure the angles of simulated trajectory. To determine the reference line, we adjusted the 3D image to simulate the patient is left-right symmetry stand position. Then, the erect line was made as the reference line; therefore, this line was subjective, and this is one of the limitation of our this study. In clinical cases, the position was also determined by surgeons subjectively; the angle will be a little different among different surgeons, but this will not influence the feasibility of S1–4 AI Screw fixation on patients. Meanwhile, because of individual variation, we strongly recommend that a preoperative CT scan is obtained and that a detailed preoperative plan is made before sacral AI fixation is applied. Moreover, 3D digital images were suitable to study the feasibility of new screw fixation and could help surgeons to explore the trajectory of screw fixation readily.

## ACKNOWLEDGEMENTS

We would like to thank Kristina Hansen from the “Medjaden Language Edit Company” for editing and proofreading our manuscript.

## ADDITIONAL INFORMATION AND DECLARATIONS

### Funding

This work was supported by the National Natural Science Foundation of China (81501933; 81372014) and the Department of Health of Zhejiang Province, Backbone of Talent Project (2012RCB037). The funders had no role in study design, data collection and analysis, decision to publish, or preparation of the manuscript.

### Grant Disclosures

The following grant information was disclosed by the authors:

National Natural Science Foundation of China: 81501933; 81372014.

Department of Health of Zhejiang Province, Backbone of Talent Project: 2012RCB037.

### Competing Interests

The authors declare that they have no conflict of interest.

### Author Contributions

- Ai-Min Wu conceived and designed the experiments, performed the experiments, analyzed the data, wrote the paper, prepared figures and/or tables, reviewed drafts of the paper.
- Yong-Long Chi analyzed the data.
- Wen-Fei Ni conceived and designed the experiments, wrote the paper, prepared figures and/or tables, reviewed drafts of the paper.

- Yi-Xing Huang conceived and designed the experiments, performed the experiments, wrote the paper, prepared figures and/or tables, reviewed drafts of the paper.

### Human Ethics

The following information was supplied relating to ethical approvals (i.e., approving body and any reference numbers):

This research was performed following the principles described in the Declaration of Helsinki and was approved by the Institutional Ethics Review Board of the Second Affiliated Hospital of Wenzhou Medical University (No.2015–30).

### Data Deposition

The following information was supplied regarding data availability:

Raw data can be found in the [Supplemental Information](#).

### Supplemental Information

Supplemental information for this article can be found online at <http://dx.doi.org/10.7717/peerj.1587#supplemental-information>.

## REFERENCES

- Edwards CC, 2nd, Bridwell KH, Patel A, Rinella AS, Berra A, Lenke LG. 2004. Long adult deformity fusions to L5 and the sacrum. A matched cohort analysis. *Spine (Phila Pa 1976)* **29(18)**:1996–2005.
- Edwards CC, 2nd, Bridwell KH, Patel A, Rinella AS, Jung Kim Y, Berra AB, Della Rocca GJ, Lenke LG. 2003. Thoracolumbar deformity arthrodesis to L5 in adults: the fate of the L5-S1 disc. *Spine (Phila Pa 1976)* **28(18)**:2122–2131.
- Kim YJ, Bridwell KH, Lenke LG, Cho KJ, Edwards CC, 2nd, Rinella AS. 2006. Pseudarthrosis in adult spinal deformity following multisegmental instrumentation and arthrodesis. *Journal of Bone & Joint Surgery* **88(4)**:721–728 DOI 10.2106/JBJS.E.00550.
- Kwan MK, Jeffry A, Chan CY, Saw LB. 2012. A radiological evaluation of the morphometry and safety of S1, S2 and S2-iliac screws in the Asian population using three dimensional computed tomography scan: an analysis of 180 pelvis. *Surgical and Radiologic Anatomy* **34(3)**:217–227 DOI 10.1007/s00276-011-0919-2.
- Martin CT, Witham TF, Kebaish KM. 2011. Sacropelvic fixation: two case reports of a new percutaneous technique. *Spine (Phila Pa 1976)* **36(9)**:E618–E621 DOI 10.1097/BRS.0b013e3181f79aba.
- O'Brien JR, Yu W, Kaufman BE, Bucklen B, Salloum K, Khalil S, Gudipally M. 2013. Biomechanical evaluation of S2 alar iliac screws: the effect of length and quad-cortical purchase as compared to iliac fixation. *Spine (Phila Pa 1976)* **38(20)**:E1250–E1255 DOI 10.1097/BRS.0b013e31829e17ff.
- O'Brien JR, Matteini L, Yu WD, Kebaish KM. 2010. Feasibility of minimally invasive sacropelvic fixation: percutaneous S2 alar iliac fixation. *Spine (Phila Pa 1976)* **35(4)**:460–464 DOI 10.1097/BRS.0b013e3181b95dca.
- O'Brien JR, Yu WD, Bhatnagar R, Sponseller P, Kebaish KM. 2009. An anatomic study of the S2 iliac technique for lumbopelvic screw placement. *Spine (Phila Pa 1976)* **34(12)**:E439–E442 DOI 10.1097/BRS.0b013e3181a4e3e4.



- Wu AM, Tian NF, Wu LJ, He W, Ni WF, Wang XY, Xu HZ, Chi YL. 2013.** A radiological and cadaveric study of oblique lumbar interbody fixation in patients with normal spinal anatomy. *The Bone & Joint Journal* **95-B**:977–982 DOI [10.1302/0301-620X.95B7.31393](https://doi.org/10.1302/0301-620X.95B7.31393).
- Wu AM, Wang S, Weng WQ, Shao ZX, Yang XD, Wang JS, Xu HZ, Chi YL. 2014.** The radiological feature of anterior occiput-to-axis screw fixation as it guides the screw trajectory on 3D printed models: a feasibility study on 3D images and 3D printed models. *Medicine* **93(28)**:e242 DOI [10.1097/MD.0000000000000242](https://doi.org/10.1097/MD.0000000000000242).
- Xu P, Wang H, Liu ZY, Mu WD, Xu SH, Wang LB, Chen C, Cavanaugh JM. 2013.** An evaluation of three-dimensional image-guided technologies in percutaneous pelvic and acetabular lag screw placement. *Journal of Surgical Research* **185(1)**:338–346 DOI [10.1016/j.jss.2013.05.074](https://doi.org/10.1016/j.jss.2013.05.074).
- Zhu F, Bao HD, Yuan S, Wang B, Qiao J, Zhu ZZ, Liu Z, Ding YT, Qiu Y. 2013.** Posterior second sacral alar iliac screw insertion: anatomic study in a Chinese population. *European Spine Journal* **22(7)**:1683–1689 DOI [10.1007/s00586-013-2734-4](https://doi.org/10.1007/s00586-013-2734-4).