

Endrology & Infertility

A case of unprovoked segmental proximal partial thrombosis of the corpus cavernosum

Vi Nguyen*

Department of Urology, University of California, San Diego, USA

Darshan P. Patel

Department of Urology, University of California, San Diego, USA

Tung-Chin Hsieh

Department of Urology, University of California, San Diego, USA

Juan Javier-Desloges

Department of Urology, University of California, San Diego, USA



ARTICLE INFO

Keywords:

Idiopathic partial thrombosis
Corpus cavernosum
Direct oral anticoagulant

ABSTRACT

Partial thrombosis of the corpus cavernosum is an extremely rare and likely underdiagnosed urologic condition. We discuss a case of a 25-year-old male who presented with severe perineal pain and was diagnosed with idiopathic proximal partial thrombosis of the corpus cavernosum via ultrasound and MRI. The patient experienced symptom resolution with evidence of disease regression on follow up MRI after treatment with direct oral anticoagulation. Further studies are needed to fully delineate the pathophysiology of this condition to facilitate development of standardized diagnostic and treatment algorithms.

1. Introduction

Partial thrombosis of the corpus cavernosum is a rare underreported condition; as of 2015, only 56 cases have been reported since 1976.^{1,2} Mean age at presentation is 31 years (range 18–59 years). The proximal third of the corpus cavernosum drains into the cavernous and internal pudendal veins. Due to presence of the fibrous septum, these veins are unable to drain past this mechanical barrier into the dorsal veins during perineal compression and the resulting venous stasis predisposes to thrombus formation exclusively in the proximal segment.²

Hallmark symptoms include perineal pain (72%), painful erections (72%), and perineal swelling (56%).² Most cases are unilateral (75%). Risk factors correspond to Virchow's triad; (1) damage to vessel walls can result from mechanical trauma such as intensive sexual activity; (2) venous stasis can result from prolonged immobility such as extended air

travel time; and (3) hypercoagulability can result from malignancy or underlying hematologic conditions.³

Diagnostic imaging findings include absence of vascular flow on Doppler ultrasound and T2 hypointense signal on MRI in the thrombosed segment.^{3,4} Differential diagnoses include: (1) hematoma, which is associated with trauma or anticoagulation, (2) penile fracture, which is associated with a typical "eggplant deformity" in the setting of sexual activity and a hypochoic tear in the tunica albuginea on Doppler ultrasound, (3) abscess, which is associated with penile cellulitis and fluid collection on ultrasound, and (4) Peyronie's disease, which is associated with pain in the acute phase, palpable plaques, and penile angulation.

The current mainstay treatment is conservative, with regimens consisting of analgesics and anticoagulation.^{2,3} Surgery is reserved for patients with refractory or recurrent symptoms. Surgical intervention was first described in 1976 via takedown of the aforementioned fibrous

* Department of Urology University of California, San Diego 9300 Campus Point Drive, La Jolla, CA, 92037, USA.

E-mail address: vin016@ucsd.edu.

<https://doi.org/10.1016/j.eucr.2023.102426>

Received 8 March 2023; Received in revised form 7 May 2023; Accepted 9 May 2023

Available online 10 May 2023

2214-4420/© 2023 The Authors. Published by Elsevier Inc. This is an open access article under the CC BY-NC-ND license (<http://creativecommons.org/licenses/by-nc-nd/4.0/>).

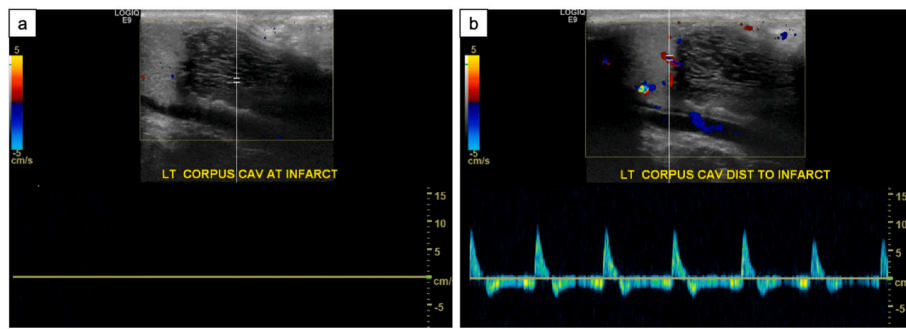


Fig. 1. (a) Hypoechoic area corresponding to the abnormality seen in the left corpus cavernosum with no internal vascularity and absent flow on the spectral Doppler images. (b) Arterial flow is demonstrated in the distal portion of the left corpus cavernosum.

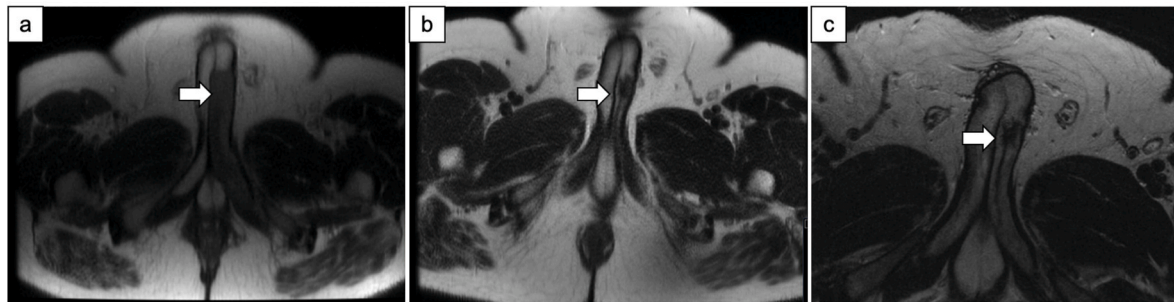


Fig. 2. (a) Initial MRI at presentation with 11.5cm segment from the base to the midportion of left corpora cavernosum with restricted diffusion. (b) Repeat MRI at 4-month interval with 2.1cm area of T2 hypointensity in the left corpus cavernosum at the midportion of the penis decreased from prior. (c) Repeat MRI at 8-month interval with stable 2.1cm area of T2 hypointensity with loss of peripheral enhancement consistent with scar formation.

septum that mechanically separates the proximal and distal corpus cavernosum.¹ Other described surgical approaches include corporotomy, cavernosum-spongiosum shunt, and intracavernosal injection of phenylephrine.⁵

2. Case presentation

We discuss a 25-year-old Caucasian male diagnosed with idiopathic segmental proximal corpus cavernosal thrombosis. His past medical history is notable for Tetralogy of Fallot status post repair in 1997, pulmonary valve replacement in 2012, strabismus, scoliosis, and hypertension. The patient does not have a history of prior venous thromboembolic events or chronic anticoagulation use.

He initially presented to an outside hospital emergency department with 4 days of left perineal and testicular pain and swelling without associated trauma. Physical examination and laboratory studies were unremarkable. Neither a scrotal ultrasound nor a CT abdomen and pelvis demonstrated any acute findings to explain his symptomatology.

He presented 3 days later with progressive penile pain and perineal pain. Physical examination was notable for an exquisitely tender phallus with increasing severity proximally and towards the left side. The left perineal region was tender with radiation to the left testicle. No other palpable deformities were noted. Laboratory studies did not demonstrate leukocytosis, anemia, acute kidney injury, coagulopathy urinary infection, or microscopic hematuria.

A CT abdomen and pelvis demonstrated asymmetric enlargement of the left corpora cavernosa; no discrete penile mass or fluid collection was noted. Hematology was consulted and recommended penile Doppler ultrasound. This demonstrated a hypoechoic area in the proximal left corpus cavernosum with absent flow consistent with thrombosis (Fig. 1a). Arterial flow was preserved distally in the left corpus cavernosum (Fig. 1b). An MRI pelvis was also obtained which demonstrated a hypointense T2 signal along an 11.5cm segment of the

proximal to midportion of the left corpora cavernosum with restricted diffusion and without internal enhancement, concerning for infarction. (Fig. 2a).

Immediate surgical exploration was deferred given the lack of trauma in the patient's clinical history or disruption of tunica albuginea on imaging. Consequently, Hematology recommended an anticoagulation regimen of oral apixaban 10mg twice daily for 7 days followed by 5mg twice daily for 3 months. He was referred to the Hemophilia Center and underlying thrombophilia workup was negative for AT3 deficiency, Factor V Leiden mutation, and prothrombin gene mutation.

Follow up MRI pelvis at 4 months demonstrated a 2.1cm area of T2 hypointensity in the left corpus cavernosum decreased from prior, consistent with fibrosis versus residual thrombosis (Fig. 2b). He was recommended for continuation of anticoagulation for 3 months with repeat MRI. Subsequent follow up MRI pelvis at 8 months redemonstrated this 2.1cm area of T2 hypointensity, however with loss of peripheral enhancement consistent with scar formation (Fig. 2c). His anticoagulation was discontinued by Hematology after this imaging study was reviewed.

3. Discussion

Herein we present a case of a 25-year-old man who presented with idiopathic penile venous thrombosis. He presented with progressively worsening unilateral penile and perineal pain and swelling. The patient was evaluated with CT and MRI; diagnosis was confirmed with ultrasound with Doppler. The imaging modality utilized for follow up studies to assess for resolution of his condition was MRI. The patient was evaluated by Hematology and successfully treated with a direct oral anticoagulant; resolution was seen on repeat imaging after a regimen of apixaban for 8 months. Whereas case reports have identified patients with the aforementioned risk factors, our patient developed his

condition in an idiopathic manner.

Treatment is generally conservative and focuses on supportive measures, though no standardized treatment algorithms exist. Anticoagulation regimens that have been utilized include aspirin, low molecular weight heparin, and direct oral anticoagulation. The duration of systemic anticoagulation rarely exceeds 6 months, however; long-term outcomes remain unknown. Our patient was treated with apixaban for a total of 8 months. His MRI did not demonstrate disruption of the tunica albuginea, thus immediate surgical exploration was not warranted.

4. Conclusion

Partial thrombosis of the corpus cavernosum is a rare urologic condition most frequently occurring in young men. Cardinal symptoms include perineal pain and swelling. Diagnostic imaging findings include absence of vascular flow on Doppler ultrasound, and T2 hypointense signal on MRI in the thrombosed portion of the corpus cavernosum. Management is conservative with administration of analgesics and

anticoagulation, with surgical interventions reserved for recurrent or refractory cases. The current literature is largely comprised of case reports and further studies are needed to fully delineate the pathophysiology of this condition to facilitate development of standardized treatment algorithms.

References

1. Hillis RS, Weems WL. Priapism: an unusual presentation. *J Urol.* 1976;116:124–125.
2. Weyne E, Schillebeeckx C, Jamaer C, et al. Idiopathic partial thrombosis (ipt) of the corpus cavernosum: a hypothesis-generating case series and review of the literature. *J Sex Med.* 2015;12:2118–2125.
3. Goeman L, Joniau S, Oyen R, Claes H, Van Poppel H. Idiopathic partial thrombosis of the corpus cavernosum: conservative management is effective and possible. *Eur Urol.* 2003;44:119–123.
4. Galvin SD, Letts JA, Sampangi NR. Magnetic resonance imaging of partial segmental priapism (segmental thrombosis of corpus cavernosum). *Urology.* 2009;73:275–276.
5. Singh D, Larson T, Campbell K, Dennis M, Yeung L. Surgical management of idiopathic partial thrombosis of the corpus cavernosum. *Sex Med.* 2021;9, 100273.