

# Intravitreal Injection of Bevacizumab in Primary Vitrectomy to Decrease the Rate of Retinal Redetachment: A Randomized Pilot Study

Adib Tousi<sup>1</sup>, MD; Hossein Hasanpour<sup>1</sup>, MD; Masoud Soheilian<sup>2</sup>, MD

<sup>1</sup>Ophthalmic Research Center, Shahid Beheshti University of Medical Sciences, Tehran, Iran

<sup>2</sup>Ocular Tissue Engineering Research Center, Shahid Beheshti University of Medical Sciences, Tehran, Iran

## Abstract

**Purpose:** To evaluate the effect of intravitreal bevacizumab (IVB) as a surgical adjunct in prevention of proliferative vitreoretinopathy (PVR) after retinal detachment surgery.

**Methods:** In this controlled, randomized pilot study, 27 patients with primary retinal detachment undergoing pars plana deep vitrectomy were included. Of these, 12 received IVB at the end of procedure. The anatomic success and best corrected visual acuity (BCVA) were compared to the control group at months 3 and 6 postoperatively.

**Results:** At three month follow-up, 3 of 11 eyes (27.3%) had detached retinas in the IVB group versus 6 of 12 (50.0%) in the control group ( $P = 0.40$ ). At six-month follow-up, 3 of 10 eyes (30%) had detached retinas in the IVB group versus 3 in 8 (37.5%) in the control group ( $P > 0.99$ ). Mean logMAR BCVA improved significantly in both groups relative to baseline, but did not show a significant difference at three-and six-month follow-ups between the two groups.

**Conclusion:** Our preliminary results show neither a benefit nor any harm from intervention in both anatomic and visual outcomes. Our results support conducting additional studies to evaluate the effect of intravitreal bevacizumab on postoperative PVR.

**Keywords:** Bevacizumab; Proliferative Vitreoretinopathy; Retinal Detachment

*J Ophthalmic Vis Res* 2016; 11 (3): 271-276.

## INTRODUCTION

Rhegmatogenous retinal detachment is one of the most devastating sight-threatening conditions of posterior segment of the eye. Different treatment modalities like scleral buckling or pars plana vitrectomy are available

with variable success rates. The most prominent process resulting in anatomic failure after initial successful detachment surgery is proliferative vitreoretinopathy (PVR), defined as the growth and contraction of cellular membranes within the vitreous cavity and on both retinal surfaces.<sup>[1]</sup> Despite improvements in surgical techniques and the use of intraocular tamponades, the rate of postoperative redetachment due to PVR is still 5-10%.<sup>[2]</sup> This process is influenced by different predisposing factors such as the grade of initial PVR, size and number of retinal breaks, extent of detachment, lens status, age, vitreous hemorrhage, and breakdown of blood retinal barrier.<sup>[3-5]</sup> Different

### Correspondence to:

Masoud Soheilian, MD. Labbafinejad Medical Center, Paidarfard St., Boostan 9 St., Pasdaran Ave., Tehran 16666, Iran.

E-mail: masoud\_soheilian@yahoo.com

Received: 25-09-2015 Accepted: 01-06-2016

### Access this article online

Quick Response Code:



Website:

www.jovr.org

DOI:

10.4103/2008-322X.188390

This is an open access article distributed under the terms of the Creative Commons Attribution-NonCommercial-ShareAlike 3.0 License, which allows others to remix, tweak, and build upon the work non-commercially, as long as the author is credited and the new creations are licensed under the identical terms.

For reprints contact: reprints@medknow.com

**How to cite this article:** Tousi A, Hasanpour H, Soheilian M. Intravitreal injection of bevacizumab in primary vitrectomy to decrease the rate of retinal redetachment: A randomized pilot study. *J Ophthalmic Vis Res* 2016;11:271-6.

adjunctive agents like 5-FU and heparin,<sup>[6]</sup> daunomycin,<sup>[7]</sup> colchicine,<sup>[8]</sup> and retinoids<sup>[9]</sup> have been tried intra- or post-operatively to prevent development of PVR with limited success, and the best way to prevent redetachment after an initial success is yet to be determined.

Vascular endothelial growth factor (VEGF) is one of the most important molecules in intraocular proliferative processes, and the possible role of its inhibition has been investigated extensively. Nowadays, these treatments are the first choice in the management of age-related macular degeneration<sup>[10]</sup> and play a major role in the management of diabetic macular edema and diabetic retinopathy.<sup>[11,12]</sup> Although primarily known as an important agent in vascular proliferative processes, studies have implied a role for VEGF in avascular processes like scar formation<sup>[13,14]</sup> as well. There are also reports of increased levels of VEGF in eyes with retinal detachment and the presence of higher levels of VEGF in eyes with higher grades of PVR.<sup>[15,16]</sup> However, reports about the relation of VEGF levels and redetachment rates are contradictory.<sup>[17-19]</sup> Given the favorable results of the use of anti-VEGF agents in intraocular proliferative processes and the dilemma about an adjunct to surgical repair of retinal detachment to prevent PVR, this trial was designed to find if it is useful to add an anti-VEGF agent to the surgical protocol. Herein, the primary results are reported.

## METHODS

This prospective controlled, randomized pilot study was performed on patients recruited from September 2010. Results of cases eligible for report up to September 2012 are presented. The study adhered to tenets of the Declaration of Helsinki, and methods were approved by the Institutional Review Board of the Ophthalmic Research Center of Shahid Beheshti University of Medical Sciences, Tehran, Iran. Twenty seven eyes of 27 patients were primarily enrolled. Four were excluded as complete pre- or post-operative data were not available or patients were lost to follow-up. Inclusion criteria were the presence of primary rhegmatogenous RD with PVR no worse than grade B<sup>[20]</sup> and candidacy for pars plana deep vitrectomy on the discretion of the treating surgeon. Exclusion criteria were age <18 years, history of any kind of retinal detachment surgery in the enrolled eye, history of trauma or uveitis, or the presence of diabetic retinopathy, bleeding diathesis, hepatic or renal failure, age-related macular degeneration, giant retinal tear, or macular hole.

After enrollment, the following data were recorded: Patients' demographic data, lens status, duration of symptoms, extent and location of detached area, and best corrected visual acuity (BCVA, log MAR scale). Before surgery, each patient was given a sealed envelope containing a random assignment to a specific group. These assignments were generated randomly on the basis of a computer-generated list prepared by our statistician.

Patients were prospectively divided into two groups: Intravitreal bevacizumab (IVB) group and control group.

All patients in both groups underwent a standard 3-port 20-gauge vitrectomy. Sampling of undiluted vitreous was performed by vitrectomy probe before opening the inflow port; volumes of the samples ranged from 0.5-1 ml and were immediately frozen and stored at -80°C. 360° vitreous base shaving under scleral depression was performed. No. 240 encircling band was placed based on decision of the surgeon. Perfluorocarbon liquid (DK-Line, Bausch and Lomb, Kingston, UK) was used in all cases followed by endolaser photocoagulation around breaks. Internal tamponade by air-sulfur hexafluoride (SF6) 20% mixture or silicone oil (Oxane 1300, Bausch and Lomb, Kingston, UK) was used in all eyes. In all surgeries, the retina was flat at the end of the procedure. In the IVB group, intravitreal injection of bevacizumab (1.25 mg, 25 mg/ml; Avastin; Roche Ltd. Mannheim, Germany) was performed at the end of the operation with a 30° gauge needle through a sutured sclerotomy.

After surgery, additional data were recorded by the surgeon including size, number, location, and shape of breaks and specified intra-operative procedures.

Patients were scheduled for postoperative examinations on first and 7<sup>th</sup> days and first, second, third, and sixth months after surgery. In the third and sixth months examinations, BCVA and the condition of the retina were recorded by observers masked to the type of intervention. The primary outcome measure was complete retinal reattachment at follow-up visits without any additional postoperative procedures like intravitreal gas injection or reoperation. The secondary outcome of the study was defined as the change in BCVA from baseline to 3- and 6-month follow-up visits. Eyes which needed re-intervention for retinal redetachment were considered as detached in analysis.

Statistical analysis was performed using SPSS statistical software (version 20, IBM Corp., USA). Snellen visual acuities were transformed into logarithm of minimum angle of resolution. For descriptive purposes, mean ± standard deviation, or median (range) were used. To compare data between groups, Chi-square, Fisher exact test, *t*-test, and Mann-Whitney test were used. For comparing VA with baseline values within each group, mixed model with Bonferroni method was used. In order to compare the results adjusted for the baseline status, we used analysis of covariance (ANCOVA). *P* value less than 0.05 was considered statistically significant.

## RESULTS

Of the 27 enrolled patients, 23 and 18 subjects had completely recorded postoperative data after three and six months, respectively. Table 1 provides baseline characteristics of and intraoperative procedures for the patients. There were no significant differences in

**Table 1. Baseline characteristics and surgical procedures**

	Total	Control	IVB	P
Sex (%)				
Male	17 (63.0)	10 (66.7)	7 (58.3)	0.706**
Female	10 (37.0)	5 (33.3)	5 (41.7)	
Age	53.7±13.8	56±13.1	50.9±14.7	0.745 <sup>‡</sup>
	52 (28-74)	55 (37-74)	50.5 (28-70)	
Lens status (%)				
Phakic	12 (44.4)	6 (40.0)	6 (50.0)	0.603*
Pseudophakic	15 (55.6)	9 (60.0)	6 (50.0)	
Time to intervention (day)	38.4±40.9	35.5±35.6	34±48.8	0.581 <sup>‡</sup>
	20 (5-180)	20 (5-120)	20 (5-180)	
Macula (%)				
On	3 (11.1)	1 (6.7)	2 (16.7)	0.569**
Off	24 (88.9)	14 (93.3)	10 (83.3)	
Extent of RD (quadrant) (%)				
<1	3 (11.1)	0 (0.0)	3 (25.0)	0.025 <sup>‡</sup>
1-2	8 (29.6)	4 (26.7)	4 (33.3)	
2-3	5 (18.5)	2 (13.3)	3 (25.0)	
>3	11 (40.7)	9 (60.0)	2 (16.7)	
Size of break (s) (disk diameter) (%)				
<1	1 (4.0)	0 (0.0)	1 (8.3)	0.406 <sup>‡</sup>
1-<2	14 (56.0)	7 (53.8)	7 (58.3)	
2-<3	9 (36.0)	5 (38.5)	4 (33.3)	
≤3	1 (4.0)	1 (7.7)	0 (0.0)	
Number of break (s) (%)				
1	12 (46.2)	6 (42.9)	6 (50.0)	0.781 <sup>‡</sup>
2	6 (23.1)	4 (28.6)	2 (16.7)	
3	6 (23.1)	2 (14.3)	4 (33.3)	
4	1 (3.8)	1 (7.1)	0 (0.0)	
≥5	1 (3.8)	1 (7.1)	0 (0.0)	
Type of break (s) (%)				
HST	16 (61.5)	6 (42.9)	10 (83.3)	0.051**
Hole	13 (50.0)	9 (64.3)	4 (33.3)	0.116*
BCVA (logMAR)	2±0.68	2.04±0.61	1.95±0.79	0.745 <sup>‡</sup>
	2.1 (0.22-2.6)	2.1 (0.3-2.6)	2.2 (0.22-2.6)	
Prophylactic band (%)				
No	7 (25.9)	5 (33.3)	2 (16.7)	0.408**
Yes	20 (74.1)	10 (66.7)	10 (83.3)	
Tamponade (%)				
SF6	15 (55.6)	6 (40.0)	9 (75.0)	0.069*
Silicon oil	12 (44.4)	9 (60.0)	3 (25.0)	

\*Based on Chi-square test; \*\*Based on Fisher exact test; <sup>‡</sup>Based on *t*-test; <sup>‡</sup>Based on Mann-Whitney test. BCVA, best-corrected visual acuity; F, female; IVB, intravitreal bevacizumab; logMAR, logarithm of minimum angle resolution; M, male; RD, retinal detachment; SF6, sulphur hexafluoride

preoperative logMAR visual acuity, age, sex, lens status, and features related to detachment between the two groups. The rate of placement of encircling band and the type of intraocular tamponade was not significantly different in the two groups either. A noteworthy percentage of patients had more than one retinal break, and this percentage was the same in both groups.

All 23 eyes had an attached retina on postoperative day 1. In three eyes, redetachment evolved within three to five weeks, and these cases underwent successful reoperation. At three-month follow-up, 3 of 11 eyes (27.3%) had detached retinas in the IVB group versus 6 of 12 (50.0%) in the control group ( $P = 0.40$  Fisher exact test). At six-month follow-up, 3 of 10 eyes (30%) had

detached retinas in the IVB group versus 3 of 8 (37.5%) in the control group ( $P > 0.99$ ) (The decrease in number is due to loss to follow-up).

The preoperative mean VA was  $2.04 \pm 0.61$  logMAR in the control group and  $1.95 \pm 0.79$  logMAR in the IVB group. At three months, the mean VA was  $1.26 \pm 0.71$  logMAR and  $1.27 \pm 0.71$  logMAR in the control and IVB groups, respectively ( $P < 0.001$  and  $0.012$ , for comparison to the baseline values respectively). At six months postoperatively, the mean BCVA was  $1.16 \pm 0.74$  logMAR and  $0.96 \pm 0.52$  logMAR in the control and IVB groups, respectively ( $P = 0.001$  and  $0.007$ , for comparison to the baseline values respectively) [Figure 1]. The change in visual acuity from baseline to three and six months was statistically significant in both groups; however the difference in BCVA between the two groups at both time points was not significant [Figure 2]. There was no statistically significant difference between the two groups regarding status of the retina at months 3 and 6 ( $P = 0.400$ ,  $P > 0.99$ , respectively) [Table 2].

## DISCUSSION

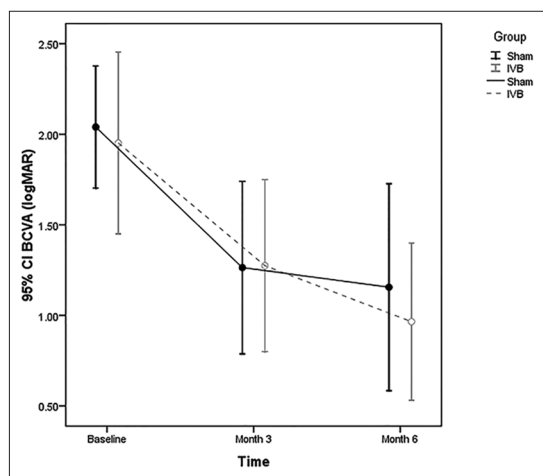
In our preliminary results, we found neither a benefit nor any harm from intervention on both anatomic and visual outcomes; our following study will show if adding intravitreal injection of bevacizumab to surgical protocol is useful or not. Development of proliferative vitreoretinopathy is the main challenge for vitreoretinal surgeons after a primary successful surgery. Although there have been improvements in instruments and

surgical techniques and the choice of procedure for reattachment has shifted from buckling towards vitrectomy,<sup>[21]</sup> the best means to prevent development of PVR still remains unclear. Rasier et al<sup>[15]</sup> compared VEGF levels of 22 eyes with RRD to 12 with no vitreoretinopathy and found significantly higher levels ( $P < 0.001$ ) in eyes

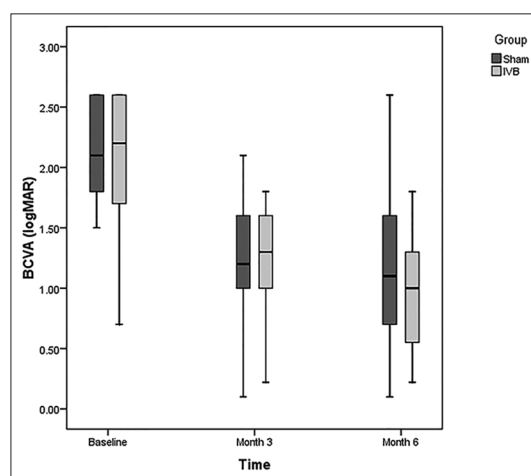
**Table 2. Postoperative anatomic and visual outcomes**

	Total	Control	IVB	P
<b>Retina</b>				
Month 3 (%)				
Off	9 (39.1)	6 (50.0)	3 (27.3)	0.400**
On	14 (60.9)	6 (50.0)	8 (72.7)	
Month 6 (%)				
Off	6 (33.3)	3 (37.5)	3 (30.0)	>0.99**
On	12 (66.7)	5 (62.5)	7 (70.0)	
<b>BCVA</b>				
Baseline				
Value	2±0.68	2.04±0.61	1.95±0.79	
Month 3				
Value	1.27±0.69	1.26±0.71	1.27±0.71	0.842 <sup>§</sup>
Change	-0.72±0.86	-0.82±0.76	-0.62±0.97	
Change (%)	-44	-38	-44	
P-within <sup>ε</sup>		<0.001	0.012	
Month 6				
Value	1.07±0.64	1.16±0.74	0.96±0.52	0.564 <sup>§</sup>
Change	-0.89±0.72	-0.81±0.81	-0.97±0.66	
Change (%)	-44	-38	-49	
P-within <sup>ε</sup>		0.001	0.007	

\*\*Based on Fisher exact test; <sup>§</sup>Based on analysis of covariance adjusted for baseline data; <sup>ε</sup>Based on mixed model adjusted for the multiple comparisons by Bonferroni method. BCVA, best-corrected visual acuity; IVB, intravitreal bevacizumab



**Figure 1.** At three months, the mean VA was  $1.26 \pm 0.71$  logMAR and  $1.27 \pm 0.71$  logMAR in the control and IVB groups, respectively ( $P < 0.001$  and  $0.012$ , respectively). At six months postoperatively, the mean VA was  $1.16 \pm 0.74$  logMAR and  $0.96 \pm 0.52$  logMAR in the control and IVB groups, respectively ( $P = 0.001$  and  $0.007$ , respectively). BCVA, best-corrected visual acuity; IVB, intravitreal bevacizumab; logMAR, logarithm of minimum angle resolution



**Figure 2.** The change in visual acuity from baseline to three and six months was statistically significant in both groups; however the difference in BCVA between the two groups in both intervals was not significant. BCVA, best-corrected visual acuity; IVB, intravitreal bevacizumab; logMAR, logarithm of minimum angle resolution



with RRD. In another study by Citirik et al,<sup>[16]</sup> the average vitreous levels of VEGF was  $15.14 \pm 5.22$  pg/ml in eyes with grade B PVR compared to  $99.15 \pm 38.58$  pg/ml in eyes with grade C PVR. Ricker et al<sup>[17]</sup> reported that the VEGF level of subretinal fluid in eyes that had successful buckling surgery was significantly lower than those that developed postoperative PVR. Although bevacizumab is a well-known agent in aborting vasoproliferative processes like PDR, reports like studies by Memarzadeh et al<sup>[22]</sup> and Pennock et al<sup>[23]</sup> show effectiveness of this molecule in slowing of an avascular process like scar formation or PVR in rabbits. These reports provide a rationale for the current study. To the best of our knowledge, no reports of clinical trials regarding advantages or disadvantages of the use of bevacizumab in the prevention of PVR in humans has been published yet.

The paradox of increased VEGF levels in an avascular process like PVR can be explained by observations by Ricker et al<sup>[24]</sup> and Perrin et al<sup>[25]</sup> which showed that antiangiogenic isoforms of VEGF (so-called VEGF<sub>xxx</sub> b) account for the majority of the total VEGF. These isoforms are products of splicing in the C-terminal exon and inhibit proliferative and vasodilator effects of VEGF<sub>165</sub>.<sup>[26,27]</sup> This may be a reason that there was no difference in the anatomic success rate between the two groups.

Based on the observed redetachment rate of 50% in the control group and 27.3% in the IVB group, our study has only 20% power to detect this difference as statistically significant. Our study revealed that at least 93 samples in each group are needed to have 80% power to detect a 20% improvement in the IVB group in comparison with the control group when type I error is only 5%.

One of the important factors in success after reattachment surgery is the number of retinal breaks, and the high rate of patients with more than one break (57% and 50% in the control and IVB groups, respectively) could be an explanation for the rather high rate of redetachment after initial success.

One limitation of the current study is that patients underwent surgery by different vitreoretinal fellows and senior surgeons, which was not considered in randomization; however, this is a common trend in a referral training center.<sup>[28]</sup>

In summary, our preliminary results support additional studies to find the effect of intravitreal anti-VEGF agents on the results of retinal detachment surgery.

### Financial Support and Sponsorship

Nil.

### Conflicts of Interest

There are no conflicts of interest.

## REFERENCES

1. Pennock S, Haddock LJ, Elliott D, Mukai S, Kazlauskas A. Is neutralizing vitreal growth factors a viable strategy to prevent proliferative vitreoretinopathy? *Prog Retin Eye Res* 2014;40:16-34.
2. Charteris DG, Sethi CS, Lewis GP, Fisher SK. Proliferative vitreoretinopathy-developments in adjunctive treatment and retinal pathology. *Eye (Lond)* 2002;16:369-374.
3. Kirchhof B. Strategies to influence PVR development. *Graefes Arch Clin Exp Ophthalmol* 2004;242:699-703.
4. Kon CH, Asaria RH, Ocleston NL, Khaw PT, Aylward GW. Risk factors for proliferative vitreoretinopathy after primary vitrectomy: A prospective study. *Br J Ophthalmol* 2000;84:506-511.
5. Mitry D, Awan MA, Borooh S, Siddiqui MA, Brogan K, Fleck BW, et al. Surgical outcome and risk stratification for primary retinal detachment repair: Results from the Scottish Retinal Detachment study. *Br J Ophthalmol* 2012;96:730-734.
6. Sundaram V, Barsam A, Virgili G. Intravitreal low molecular weight heparin and 5-fluorouracil for the prevention of proliferative vitreoretinopathy following retinal reattachment surgery. *Cochrane Database Syst Rev* 2010;7:CD006421.
7. Kumar A, Nainiwal S, Choudhary I, Tewari HK, Verma LK. Role of daunorubicin in inhibiting proliferative vitreoretinopathy after retinal detachment surgery. *Clin Experiment Ophthalmol* 2002;30:348-351.
8. Lemor M, Yeo JH, Glaser BM. Oral colchicine for the treatment of experimental traction retinal detachment. *Arch Ophthalmol* 1986;104:1226-1229.
9. Chang YC, Hu DN, Wu WC. Effect of oral 13-cis-retinoic acid treatment on postoperative clinical outcome of eyes with proliferative vitreoretinopathy. *Am J Ophthalmol* 2008;146:440-446.
10. Lim LS, Mitchell P, Seddon JM, Holz FG, Wong TY. Age-related macular degeneration. *Lancet* 2012;379:1728-1738.
11. Yilmaz T, Cordero-Coma M, Gallagher MJ, Teasley LA. Systematic review of intravitreal bevacizumab injection for treatment of primary diabetic macular oedema. *Acta Ophthalmol* 2011;89:709-717.
12. Nicholson BP, Schachat AP. A review of clinical trials of anti-VEGF agents for diabetic retinopathy. *Graefes Arch Clin Exp Ophthalmol* 2010;248:915-930.
13. Pollina EA, Legesse-Miller A, Haley EM, Goodpaster T, Randolph-Habecker J, Collier HA. Regulating the angiogenic balance in tissues. *Cell Cycle* 2008;7:2056-2070.
14. Wilgus TA, Ferreira AM, Oberyzyzn TM, Bergdall VK, Dipietro LA. Regulation of scar formation by vascular endothelial growth factor. *Lab Invest* 2008;88:579-590.
15. Rasier R, Gormus U, Artunay O, Yuzbasioglu E, Oncel M, Bahcecioglu H. Vitreous levels of VEGF, IL-8, and TNF-alpha in retinal detachment. *Curr Eye Res* 2010;35:505-509.
16. Citirik M, Kabatas EU, Batman C, Akin KO, Kabatas N. Vitreous vascular endothelial growth factor concentrations in proliferative diabetic retinopathy versus proliferative vitreoretinopathy. *Ophthalmic Res* 2012;47:7-12.
17. Ricker LJ, Kijlstra A, Kessels AG, de Jager W, Liem AT, Hendrikse F, et al. Interleukin and growth factor levels in subretinal fluid in rhegmatogenous retinal detachment: A case-control study. *PLoS One* 2011;6:e19141.
18. Dieudonné SC, La Heij EC, Diederer RM, Kessels AG, Liem AT, Kijlstra A, et al. Balance of vascular endothelial growth factor and pigment epithelial growth factor prior to development of proliferative vitreoretinopathy. *Ophthalmic Res* 2007;39:148-154.
19. Hoerster R, Hermann MM, Rosentreter A, Muetter PS, Kirchhof B, Fauser S. Profibrotic cytokines in aqueous humour correlate with aqueous flare in patients with rhegmatogenous retinal detachment. *Br J Ophthalmol* 2013;97:450-453.
20. Machemer R, Aaberg TM, Freeman HM, Irvine AR, Lean JS,

- Michels RM. An updated classification of retinal detachment with proliferative vitreoretinopathy. *Am J Ophthalmol* 1991;112:159-165.
21. Heimann H, Hellmich M, Bornfeld N, Bartz-Schmidt KU, Hilgers RD, Foerster MH. Scleral buckling versus primary vitrectomy in rhegmatogenous retinal detachment (SPR Study): Design issues and implications. SPR Study report no 1. *Graefes Arch Clin Exp Ophthalmol* 2001;239:567-574.
  22. Memarzadeh F, Varma R, Lin LT, Parikh JG, Dustin L, Alcaraz A, et al. Postoperative use of bevacizumab as an antifibrotic agent in glaucoma filtration surgery in the rabbit. *Invest Ophthalmol Vis Sci* 2009;50:3233-3237.
  23. Pennock S, Kim D, Mukai S, Kuhnle M, Chun DW, Matsubara J, et al. Ranibizumab is a potential prophylaxis for proliferative vitreoretinopathy, a nonangiogenic blinding disease. *Am J Pathol* 2013;182:1659-1670.
  24. Ricker LJ, Dieudonné SC, Kessels AG, Rennel ES, Berendschot TT, Hendrikse F, et al. Antiangiogenic isoforms of vascular endothelial growth factor predominate in subretinal fluid of patients with rhegmatogenous retinal detachment and proliferative vitreoretinopathy. *Retina* 2012;32:54-59.
  25. Perrin RM, Konopatskaya O, Qiu Y, Harper S, Bates DO, Churchill AJ. Diabetic retinopathy is associated with a switch in splicing from anti- to pro-angiogenic isoforms of vascular endothelial growth factor. *Diabetologia* 2005;48:2422-2427.
  26. Bates DO, Cui TG, Doughty JM, Winkler M, Sugiono M, Shields JD, et al. VEGF165b, an inhibitory splice variant of vascular endothelial growth factor, is down-regulated in renal cell carcinoma. *Cancer Res* 2002;62:4123-4131.
  27. Woolard J, Wang WY, Bevan HS, Qiu Y, Morbidelli L, Pritchard-Jones RO, et al. VEGF165b, an inhibitory vascular endothelial growth factor splice variant: Mechanism of action, *in vivo* effect on angiogenesis and endogenous protein expression. *Cancer Res* 2004;64:7822-7835.
  28. Mazinani BA, Rajendram A, Walter P, Roessler GF. Does surgical experience have an effect on the success of retinal detachment surgery? *Retina* 2012;32:32-37.