



Since January 2020 Elsevier has created a COVID-19 resource centre with free information in English and Mandarin on the novel coronavirus COVID-19. The COVID-19 resource centre is hosted on Elsevier Connect, the company's public news and information website.

Elsevier hereby grants permission to make all its COVID-19-related research that is available on the COVID-19 resource centre - including this research content - immediately available in PubMed Central and other publicly funded repositories, such as the WHO COVID database with rights for unrestricted research re-use and analyses in any form or by any means with acknowledgement of the original source. These permissions are granted for free by Elsevier for as long as the COVID-19 resource centre remains active.



Autopsy findings of post-COVID-19 vaccination deaths in Tokyo Metropolis, Japan, 2021

Hideto Suzuki^{a,*}, Ayako Ro^{a,b}, Aya Takada^{a,c,d}, Kazuyuki Saito^{a,c,d}, Kino Hayashi^a

^a Tokyo Medical Examiner's Office, Tokyo Metropolitan Government, Tokyo, Japan

^b Department of Legal Medicine, St. Marianna University School of Medicine, Kanagawa, Japan

^c Department of Forensic Medicine, Saitama Medical University, Saitama, Japan

^d Department of Forensic Medicine, Graduate School of Medicine, Juntendo University, Tokyo, Japan

ARTICLE INFO

Keywords:

COVID-19 vaccines

Death

Forensic autopsy

ABSTRACT

Background: COVID-19 vaccines have been used across Japan since 17 February 2021, and as of 17 April 2022, 1690 deaths potentially caused by vaccine-related adverse effects have been reported to the Ministry of Health, Labour and Welfare. However, the causal relationship between vaccination and death could not be fully evaluated because of a lack of sufficient information.

Methods: Autopsy cases in which deaths occurred within seven days after COVID-19 vaccination in Tokyo Metropolis and were handled by medical examiners were selected (n = 54). Age, sex, vaccine-related information, cause of death, and possible causal relationship between vaccination and death were examined.

Results: The mean age of the deceased individuals was 68.1 years, and the study sample consisted of 34 males (63.9%) and 20 females (37.0%). Thirty-seven and six individuals received Comirnaty and Spikevax, respectively (68.5% and 11.1% respectively). The manner of death included natural (n = 43), non-natural (n = 8), and undetermined (n = 3). The most frequent cause of death was ischemic heart disease (n = 16). Regarding causal relationships, 46 cases (85.2%) did not show a causal relationship to vaccination, except for myocarditis (n = 3), thrombosis-related death (n = 4), and others (n = 1).

Conclusion: Although many cases of deaths after COVID-19 vaccination in this study showed no definite causal relationship between the vaccination and deaths, some cases showed possible adverse events such as myocarditis. Autopsies are essential for detecting vaccine-related deaths, and the Japanese death investigation system needs to be reinforced from this viewpoint.

1. Introduction

Severe acute respiratory syndrome coronavirus 2 (SARS-CoV-2), the agent responsible for coronavirus disease 2019 (COVID-19), has had a calamitous effect on the world [1,2]. The virus rapidly spread worldwide, leading to one of the most severe pandemics in human history. Vaccination is undoubtedly the most effective tool for preventing infectious disease, and is one of the most important breakthroughs in the history of medical science. The development of COVID-19 vaccines started in January 2020 with the identification of the genetic sequence of SARS-CoV-2 [3]. Vaccination against SARS-CoV-2 virus has proven to be a cornerstone of preventive strategies. The BNT162b2 (Comirnaty, BioNTech/Pfizer) and mRNA-1273 (Spikevax, Moderna) mRNA-based vaccines have demonstrated a high efficacy rate [4,5]. A recent study

confirmed that three doses of BNT162b2 conferred high protection against hospital and emergency department admission due to both the delta and omicron variants in the first 3 months after vaccination [6]. A. Sheikh also showed that in comparison with the second vaccine doses, third or booster vaccine doses are associated with considerable added protection against symptomatic COVID-19 caused by the omicron variant [7].

On the other hand, COVID-19 vaccine-related adverse events, including anaphylaxis [8–11], myocarditis and pericarditis [12–18], and thrombosis with thrombocytopenia syndrome [19–20], have also been reported in the literature. Barda showed that the BNT162b2 was associated with an excess risk of myocarditis in their study in a nationwide mass vaccination setting, although the risk was substantially increased after SARS-CoV-2 infection [21]. Considering the scale of

* Corresponding author at: Tokyo Medical Examiner's Office, Tokyo Metropolitan Government, 4-21-18 Otsuka, Bunkyo-ku, Tokyo 112-0012, Japan.

E-mail address: hideto-@qk9.so-net.ne.jp (H. Suzuki).

<https://doi.org/10.1016/j.legalmed.2022.102134>

Received 5 July 2022; Received in revised form 10 August 2022; Accepted 17 August 2022

Available online 20 August 2022

1344-6223/© 2022 Elsevier B.V. All rights reserved.

vaccination programs both locally and internationally, some deaths may inevitably occur close to a COVID-19 vaccination, raising questions regarding the potential relationship between the death and the recent vaccination.

In Japan, the vaccines that have obtained pharmaceutical approval include BNT162b2, mRNA-1273, ChAdOx1 nCoV-19 (Vaxzevria, AstraZeneca), and NVX-CoV2373 (Novavax). As of June 15, 2022, BNT162b2 and mRNA-1273 are the major vaccines that have been administered so far [22]. The vaccine was first administered to health-care workers starting 17 February 2021, and subsequently offered to senior citizens and then to the general public aged 16 years and above. Those aged 12 years and above were eligible for vaccinations on 1 June 2021 (BNT162b2) and on 3 August 2021 (mRNA-1273). In addition, those aged 5–11 years became eligible for vaccinations on 21 January 2022 (BNT162b2). As of 15 June 2022, more than 103 million (81.9%) individuals in Japan have received at least the first dose of vaccine, and more than 76 million (60.7%) have received the third dose [23]. To monitor potential adverse effects of the vaccines, the Ministry of Health, Labour and Welfare (MHLW) has asked physicians/medical facilities to report suspected cases. The numbers of reported deaths that might be related to vaccine-related adverse effects were 1575 (Comirnaty), 149 (Spikevax), and one case (Vaxzevria) from 17 February 2021 to 15 May 2022 [24]. The council in MHLW discusses causal relationships between vaccination and reported cases and publishes the results. Although no cases have been judged as showing a definite causal relationship between vaccination and death so far, published data shows that causal relationship is unknown in a great majority of reported cases (1714 cases, 99.4%) because of the lack of sufficient information for evaluation of the relationship between vaccination and death [24].

Tokyo Metropolis is a metropolitan prefecture, and the medical examiner system has been implemented in the special wards of Tokyo Metropolis. All medicolegal deaths including natural, non-natural and undetermined manner of death occurred in the special wards of Tokyo Metropolis are reported to the Tokyo Medical Examiner's Office. Medical examiners perform postmortem examinations to determine the manner and cause of death for these cases. Medical examiners also perform autopsies for deceased who died soon after COVID-19 vaccination to investigate if there is any evidence of causation between COVID-19 vaccination and deaths, except for cases showing severe putrefactive changes and cases showing evidence of a cause of death highly unlikely to be related to the vaccination, after reviewing the circumstances of death, the antemortem clinical course, and the postmortem radiographic findings. In this study, we investigated the autopsied cases of deaths occurring soon after COVID-19 vaccination to clarify the actual situation of COVID-19 vaccine-related deaths in Japan.

2. Materials and methods

From 1 April 2021 to 31 December 2021, forensic autopsies of 54 persons who received vaccination against COVID-19 within 7 days before death were performed at the Tokyo Medical Examiner's Office. We collected the relevant documents (death certificates, autopsy reports, and reports of death scene investigations conducted by the police) of those cases, and examined age, sex, vaccine details, dose-related information (first or second dose), interval between vaccination and death, autopsy findings, and cause of death. Autopsy findings included macroscopic findings, histopathological findings, toxicological analysis and the results of blood biochemistry. Histopathological examination was performed in all cases, and blood ethanol levels were measured in all cases except for four cases (No. 5, 9, 27, 44). Toxicological analysis was performed in twenty cases (No. 3, 6, 7, 15, 17–20, 24, 32–34, 39, 40,

43, 45–47, 51, 53). Measurement of tryptase and/or Immunoglobulin E (IgE) was performed in fifteen cases (No. 12, 13, 17, 22, 23, 26, 30, 31, 35, 38, 47, 49, 51, 52, 54).

Among the autopsy findings, signs suggestive of anaphylaxis, thrombosis, myocarditis, and pericarditis were closely examined. In addition, we assessed possible causal relationships between vaccination and death. The Ethics Committee of the Tokyo Medical Examiner's Office approved the study protocol and use of data (the approval number: 2020–3).

3. Results (see Table 1)

The mean age of the deceased individuals was 68.1 years (age range: 24–91 years), and the most frequent age group was 80–89 years ($n = 14$), followed by 70–79 years ($n = 13$), and 50–59 years ($n = 11$). The study sample consisted of 34 males (63.9%) and 20 females (37.0%). Thirty-seven and six individuals received Comirnaty and Spikevax, respectively (68.5% and 11.1% respectively), and information about the vaccine was not available in 11 cases. Twenty and 28 deaths were reported after the first and second doses, respectively (37.0% and 51.9% respectively), and information about the dose was not available in six cases. The interval between the last vaccination and death ranged from 40 min (case 17) to 7 days (case 9).

The manner of death was categorized as natural in 43 cases, non-natural in eight cases (cases 3, 6, 7, 13, 22, 24, 29, and 39), and undetermined in three cases (cases 32, 50, 53). Natural deaths included circulatory system diseases ($n = 26$), digestive system diseases ($n = 5$), endocrine, nutritional, and metabolic diseases ($n = 4$), neoplasms ($n = 4$), respiratory system diseases ($n = 3$), and other diseases ($n = 1$). Ischemic heart disease was the most frequent disease-related cause of death ($n = 16$), and postmortem investigations did not indicate a causal relationship to vaccination in 36 cases of natural death. Non-natural deaths included drowning ($n = 6$) and poisoning ($n = 2$). All cases of drowning happened in a bathtub during bathing, and postmortem investigations did not indicate a causal relationship to vaccination in cases of non-natural death. The three cases of death of undetermined manner showed no significant findings related to vaccination in two cases (cases 32, 50). In the third case (case 53), while the cause of death was not identified, slight lymphocyte and macrophage infiltration in the interstitial space of myocardium was observed. However, a causal relationship between death and vaccination was unknown.

In the assessment of adverse events, myocarditis was found to be the cause of death in two cases (cases 40, 54) (Fig. 1, Fig. 2.), and causal relationships to vaccination were possible. Another case showed myocarditis (case 4) while a competing cause of death (pre-existing ischemic heart disease) was found. A causal relationship to vaccination was possible, but could not be proven beyond doubt. Among the cases showing thrombosis, transverse sinus thrombosis (case 48), ischemic colitis secondary to superior mesenteric artery thrombosis (case 14), and pulmonary artery thromboembolism (case 8, 45) were found to be the causes of death. In cases 48 and 14, the anti-PF4 antibody level could not be measured because of difficulty in serum isolation. A causal relationship to vaccination was possible, but could not be proven beyond doubt. In case 8, chest discomfort was identified before vaccine administration, and organized thrombi were observed both in the pulmonary artery and deep vein of the left lower extremity. Organized thrombi were also found in the deep vein of the extremities in case 45. Causal relationships were unlikely in these cases. None of the cases demonstrated signs suggestive of anaphylaxis, such as laryngeal edema and eosinophilic infiltration. Among fifteen cases in which serum tryptase and/or IgE was measured, elevated levels of tryptase was observed

Table 1
Detailed information concerning the investigated 54 cases.

No.	Age	Gender	Vaccine	Dose	Number of days post-vaccination	Cause of death	Autopsy findings relevant to cause of death	Other findings	Causal relationship
1	72	M	Comirnaty	1	3	Adhesion ileus	Adhesion of the small intestine and enlargement of the duodenum and the small intestine, post sigmoid colectomy	Diabetic ketoacidosis, cardiomegaly, severe coronary sclerosis, liver cirrhosis	No evidence
2	86	F	Comirnaty	1	6	Acute myocardial infarction	Cardiac tamponade due to a rupture of myocardial infarction in the posterior wall, severe coronary sclerosis with thrombus in the left circumflex branch, cardiomegaly	Cavernous hemangioma in the liver	No evidence
3	86	F	Comirnaty	1	1	Drowning	Emphysema aquosum, watery gastric content	Hypertensive and diabetic nephrosclerosis	No evidence
4	91	M	Spikevax	1	6	Ischemic heart disease, myocarditis	Old myocardial infarction in the postlateral wall, severe coronary artery sclerosis, leukocyte and lymphocyte infiltration in the left anterior wall	Diabetic nephropathy, aortic sclerosis	Possible
5	90	M	n.a.	n.a.	3	Ischemic heart disease	Cardiomegaly with old infarction of the anteroseptal wall, severe coronary sclerosis, elevation of NT-pro BNP in blood (27400 pg/ml)	Aortic sclerosis, benign nephrosclerosis	No evidence
6	74	F	Comirnaty	1	6	Drowning	Emphysema aquosum, watery gastric content, pleural effusion	Coronary sclerosis, hypertensive and diabetic nephrosclerosis, Old lung tuberculosis	No evidence
7	87	F	Comirnaty	1	1	Drowning	Emphysema aquosum, watery gastric content, pleural effusion	Benign nephrosclerosis	No evidence
8	79	M	Comirnaty	1	4	Pulmonary artery thromboembolism	Thromboembolism in the bilateral pulmonary trunk, deep vein thrombosis of the left lower extremity (containing organized thrombus)	Cardiomegaly, coronary sclerosis, unruptured abdominal aortic aneurysm, benign nephrosclerosis	Unlikely
9	80	M	Comirnaty	1	7	Volvulus of sigmoid colon	Panperitonitis due to a rupture of the volvulus of the sigmoid colon	Chronic subdural hematoma, Alzheimer's disease	No evidence
10	77	F	Comirnaty	2	3	Incarceration of inguinal hernia	Strangulation ileus due to an incarceration of inguinal hernia, aspiration of vomitus	Chronic pyelonephritis, cardiomegaly, lacuna infarction	No evidence
11	81	M	n.a.	1	1	Ischemic heart disease	Severe coronary sclerosis, cardiomegaly with mild fibrotic scar, elevation of NT-pro BNP in blood (27400 pg/ml)	Aortic sclerosis	No evidence
12	79	F	Comirnaty	2	1	Ischemic heart disease	Severe sclerosis in the left anterior descending coronary artery	Mild amyloid disposition in the interstitial space of the cardiomyocytes	No evidence
13	76	M	Comirnaty	2	1	Drowning	Emphysema aquosum, watery gastric content, pleural effusion	Unruptured thoracic aortic aneurysm, benign nephrosclerosis, multiple renal cysts	No evidence
14	78	F	Comirnaty	1	6	Ischemic colitis	Panperitonitis due to extensive necrosis of the small intestine, thrombus in the peripheral side of the superior mesenteric artery	Coronary sclerosis, aortic sclerosis, fatty liver	Possible
15	82	F	Comirnaty	2	1	Ischemic heart disease	Severe sclerosis with stent implantation in the right and left coronary arteries, multiple small fibrotic scars in the myocardium, elevation of NT-pro BNP in blood (9980 pg/ml)	Benign nephrosclerosis, aortic sclerosis	No evidence
16	77	F	Comirnaty	n.a.	6	Malnutrition	Body mass index 13.2, elevation of acetone in the blood (15.9 µg/ml)	Chronic hepatitis, hepatoma, aortic sclerosis	No evidence
17	83	F	Comirnaty	2	1	Aortic dissection	Rupture of aortic dissection, hemothorax, cystic medial necrosis in the aorta	Aortic sclerosis	No evidence
18	67	F	Comirnaty	2	5	Pyelonephritis	Swelling of the right kidney, neutrophil infiltration in the tubule and the interstitial space of the kidney	Cardiomegaly, coronary sclerosis, end-stage kidney disease	No evidence
19	85	M	Comirnaty	n.a.	6	Hemopneumothorax due to rupture of bulla	Hemothorax (right 350 ml, left 50 ml), multile bulla in the apex, emphysema	Coronary sclerosis, aortic sclerosis, benign nephrosclerosis	No evidence
20	79	M	Comirnaty	n.a.	4	Gastric cancer		Pneumonia, old cerebral infarction, benign	No evidence

(continued on next page)

Table 1 (continued)

No.	Age	Gender	Vaccine	Dose	Number of days post-vaccination	Cause of death	Autopsy findings relevant to cause of death	Other findings	Causal relationship
21	77	M	Comirnaty	1	1	Diabetic ketoacidosis	Carcinomatosis peritonitis due to gastric cancer in the cardia (sized 4 × 4 cm) Elevation of ketone in blood (3590 μmol/l), diabetic nephropathy	nephrosclerosis, aortic sclerosis Cardiomegaly, old cerebral infarction	No evidence
22	87	F	n.a.	1	2	Drowning	Emphysema aquosum, microbubbles in the trachea	Cardiomegaly, benign nephrosclerosis, fatty liver	No evidence
23	70	F	Comirnaty	2	3	Sigmoid colon cancer	Sigmoid colon cancer (sized 4 × 3.2 cm), liver metastasis with extensive hemorrhage and necrosis	Lung edema, pleural effusion	No evidence
24	83	F	n.a.	2	2	Drowning	Emphysema aquosum, watery gastric content	Cardiomegaly, aortic sclerosis, benign nephrosclerosis	No evidence
25	82	M	Comirnaty	2	2	Lung cancer	Hemothorax (right 2100 ml) due to lung cancer (S6, sized 6 × 6 cm), multiple metastasis in the lung and liver	Cardiomegaly, benign nephrosclerosis	No evidence
26	74	F	Comirnaty	2	1	Heart failure due to mitral valve stenosis	Hypertrophy of the anterior mitral leaflet, cardiomegaly, elevation of NT-pro BNP in blood (6220 pg/ml)	Coronary sclerosis, old cerebral infarction	No evidence
27	84	F	Comirnaty	1	2	Acute myocardial infarction	Cardiac tamponade due to a rupture of myocardial infarction in the posterolateral wall	Aortic sclerosis	No evidence
28	59	M	n.a.	1	6	Acute myocardial infarction	Cardiac tamponade due to a rupture of myocardial infarction in the lateral wall, severe coronary sclerosis, cardiomegaly	Aortic sclerosis	No evidence
29	53	F	Comirnaty	1	3	Alcohol intoxication	Blood ethanol level (3.5 mg/ml), urine ethanol level (3.89 mg/ml)	Liver cirrhosis	No evidence
30	65	M	Comirnaty	n.a.	0	Ischemic heart disease	Old myocardial infarction in the anterior and lateral wall, severe sclerosis in the left coronary artery, cardiomegaly	Fatty liver, aortic sclerosis	No evidence
31	66	M	Comirnaty	2	3	Ischemic heart disease	Old myocardial infarction in the anteroseptal wall, severe coronary sclerosis	Lung edema, tonsillar hypertrophy	No evidence
32	69	M	n.a.	n.a.	1	Unknown	–	Severe postmortem change of the whole organ, malnutrition, emphysema, coronary sclerosis	No evidence
33	55	M	Comirnaty	2	0	Bacterial pneumonia	Significant neutrophil infiltration and bacteria in the alveoli of bilateral lungs, aspiration of vomitus, myotonic dystrophy	Coronary sclerosis	No evidence
34	51	M	Comirnaty	2	2	Bacterial pneumonia	Lobar pneumonia in the middle lobe of the right lung, elevation of CRP in blood (28.03 mg/dl)	Liver cirrhosis, malnutrition	No evidence
35	40	M	Spikevax	2	3	Ischemic heart disease	Severe coronary sclerosis	Fatty liver	No evidence
36	65	M	n.a.	2	2	Gastric cancer	Gastric cancer (sized 12 × 10 cm), metastasis in multiple organs (heart, adrenal gland, bone marrow)	Old myocardial infarction, coronary sclerosis	No evidence
37	74	M	Comirnaty	2	1	Ischemic heart disease	Severe coronary sclerosis, lung edema and congestion	Old renal infarction	No evidence
38	88	F	Comirnaty	2	2	Strangulation ileus	Incarceration of hernia (greater omentum), necrosis of the jejunum, secondary pneumonia	Senile amyloidosis, aortic sclerosis, benign nephrosclerosis, old lung tuberculosis	No evidence
39	55	M	Comirnaty	1	2	Poisoning (methamphetamine and antipsychotics)	Methamphetamine (2.69 μg/ml), bromazepam (0.58 μg/ml) and myanserin hydrochloride (0.14 μg/ml) in blood	Fatty liver	No evidence
40	24	M	Spikevax	2	3	Myocarditis	Scattered necrosis and fibrosis of cardiomyocytes with a perivascular pattern of inflammatory cell infiltration (consisting of predominantly lymphocytes)	–	Possible
41	53	M	Comirnaty	1	0	Ischemic heart disease	Severe coronary sclerosis, myocardial infarction in the anteroseptal wall	Fatty liver	No evidence
42	59	M	n.a.	2	6	Diabetic ketoacidosis	Elevation of ketone in blood (13000 μmol/l), dehydration, diabetic nephropathy, fibrosis of the pancreas	Old myocardial infarction, coronary sclerosis	No evidence
43	47	M	Comirnaty	1	5	Ischemic heart disease	Severe coronary sclerosis, contraction band in cardiomyocytes	Fatty liver	No evidence

(continued on next page)

Table 1 (continued)

No.	Age	Gender	Vaccine	Dose	Number of days post-vaccination	Cause of death	Autopsy findings relevant to cause of death	Other findings	Causal relationship
44	84	M	n.a.	2	5	Cor pulmonare due to emphysema	Hypertrophy of the right ventricle, emphysema, elevation of NT-pro BNP in blood (57900 pg/ml)	Bronchitis, coronary sclerosis, old cerebral hemorrhage	No evidence
45	49	M	n.a.	2	5	Pulmonary artery thromboembolism	Thromboembolism in the bilateral pulmonary trunk, deep vein thrombosis of bilateral lower extremities (containing organized thrombus)	Fatty liver	Unlikely
46	67	F	Comirnaty	2	0	Ischemic heart disease	Severe coronary sclerosis, lung edema	Benign nephrosclerosis, aortic sclerosis	No evidence
47	56	M	Spikevax	2	2	Ischemic heart disease	Cardiomegaly with multiple fibrotic scars, severe coronary sclerosis, lung edema and congestion	Benign nephrosclerosis, fatty liver	No evidence
48	52	M	n.a.	1	1	Cerebral hemorrhage	Transverse sinus thrombosis, massive cerebral hemorrhage (sized 10 × 10 cm) with ischemic lesion	Gastromalacia	Possible
49	48	F	Spikevax	1	3	Diabetic ketoacidosis	Elevation of ketone (9820 μmol/l) and HbA1c (10.3%) in blood, dehydration,	–	No evidence
50	39	M	Comirnaty	2	3	Unknown	–	Lung edema, a slight lymphocyte and macrophage infiltration in the internal space of cardiac muscle	Unknown
51	52	M	Comirnaty	2	3	Ischemic heart disease	Severe coronary sclerosis, cardiomegaly, lung edema	Benign nephrosclerosis, fatty liver	No evidence
52	56	M	Comirnaty	2	2	Subarachnoid hemorrhage	Dissection of the left vertebral artery	Lung edema, cardiomegaly	No evidence
53	49	M	Comirnaty	2	0	Unknown	–	Hypoxic encephalopathy, severe coronary sclerosis, cardiomegaly, liver cirrhosis, pneumonia	No evidence
54	39	M	Spikevax	2	3	Myocarditis	Scattered inflammatory cell infiltration (consisting of predominantly monocytes) in the interstitial space of cardiomyocytes/ around the coronary arteries, interstitial edema, eosinophilic and wavy change of cardiomyocytes	Lung edema, coronary sclerosis	Possible

n.a.; not available.

in case 13 (411 μg/L) and case 47 (36.4 μg/L), however, these cases did not show clinical manifestations or histopathological findings suggestive of anaphylaxis.

4. Discussion

There are many autopsy case reports of death suspected of severe adverse effects of COVID-19 vaccine [15–17,25–33], however, few studies investigate autopsy findings and cause of death of a series of death following vaccination with COVID-19 vaccines. Edler reported four death cases after vaccination with Comirnaty. They concluded that a causal relationship between vaccination and death was not established, because three deceased died in the context of pre-existing conditions (severe cardiovascular diseases) and one developed COVID-19 pneumonia as cause of death [34]. Schneider investigated causes of death of eighteen cases died after COVID-19 vaccine, and found one case of myocarditis and two cases of vaccine-induced immune thrombotic thrombocytopenia (VITT) among eighteen cases, whereas the cause of death was attributed to preexisting disease in the remaining fifteen cases [35]. Yeo investigated 33 deaths that occurred within 72 h after COVID-19 mRNA vaccination in Singapore, and found no definite causal relationship between the vaccination and deaths [36]. They also showed that circulatory system diseases (e.g., ischemic heart disease) were the most frequent cause of death. In this study, a majority of cases (85.2%, 46 out of 54 cases) did not show a causal relationship between vaccination and death. In addition, two cases of death from pulmonary artery

thromboembolism may have occurred irrespective of vaccination. Previous studies and our results suggest that the proportion of death by severe adverse events of vaccines is minority in a series of forensic autopsy cases of death following vaccination with COVID-19 vaccines. Due to the large numbers of people being vaccinated, some people may coincidentally experience medical events (e.g., heart attacks) in the days or weeks after vaccination that may not be related to the vaccination, and such deaths are to be expected inevitably.

On the other hand, myocarditis was listed as a cause of death in two cases and as a competing cause of death in one case. In addition, slight lymphocyte and macrophage infiltration was observed in the internal space of cardiac muscle in one case, although the cause of death was unknown. Most cases of myocarditis in vaccine recipients occur in young males, particularly following the second dose [14]. These features are compatible with those observed in cases in this study (cases 40, 54). The reasons for the higher incidence among males are unclear, but may be due to different effects of sex hormones on the cell-mediated immune response, with testosterone promoting a more pronounced Th1 stimulation and estrogen displaying inhibitory effects on pro-inflammatory T cells [18]. The histopathological characteristics of vaccine-associated myocarditis following COVID-19 vaccination have been reported to vary among cases [14–17]. Some of these cases describe areas of acute inflammation with myocyte necrosis and predominantly lymphocytic infiltration [14], whereas others describe diffuse or scattered foci of contraction band necrosis with hypercontracted sarcomeres and predominantly neutrophil and histiocyte infiltrates suggesting

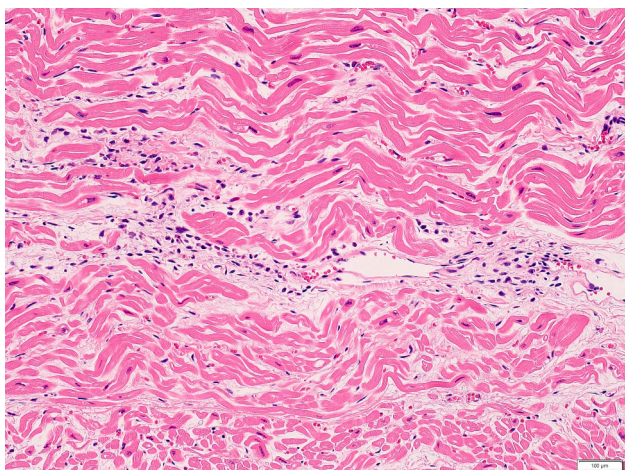


Fig. 1. Inflammatory cell infiltration (consisting of predominantly lymphocytes) was observed in the interstitial space of cardiomyocytes. Fibroblasts were also seen with mild proliferation of collagen fiber (case 40).

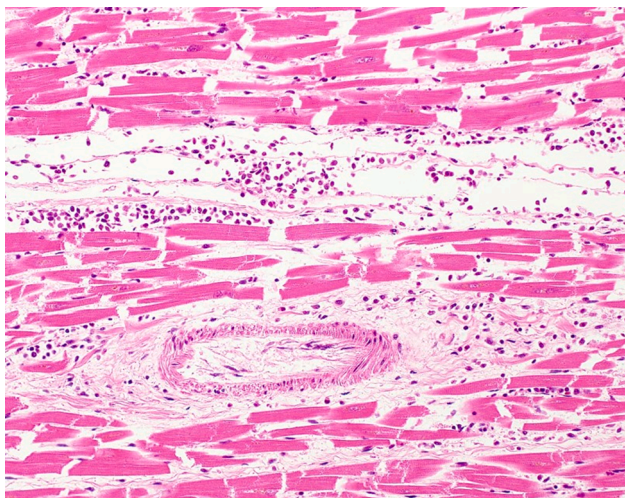


Fig. 2. Scattered inflammatory cell infiltration (consisting of predominantly monocytes) was observed in the interstitial space of cardiomyocytes (case 54) [45].

catecholamine-induced myocardial inflammation [16,17]. In this study, scattered fibrosis was shown in case 40. It is conceivable that this process started with the first vaccination dose and the initial myocardial effects resolved and healed within three weeks. The second dose may have restarted the process.

VITT is characterized by a combination of thrombocytopenia and thrombosis. Different mechanisms could be related to the occurrence of VITT, such as the possible cross-reactivity of antibodies against SARS-CoV-2 spike protein with PF4, the possible interaction between spike protein and platelets, and the platelet expression of spike protein [37]. Thrombosis can occur in both the arterial and, more commonly, venous systems. However, a distinctive feature of VITT is thrombosis in unusual locations, including cerebral venous thrombosis and splanchnic venous thrombosis [35,38]. Based on the autopsy data, the recurrent findings were intracranial hemorrhage and diffused microthrombi located in multiple areas [29]. Cases have been reported to be typically identified between 4 and 30 days after vaccination with vector vaccines Vaxzevria and Janssen [39]. Similar complications can occur following mRNA-based vaccines, although their incidence rate has been estimated to be lower [40]. From these findings, the causal relationship was considered to be possible in case 48 in this study, although anti-PF4 antibody could

not be measured. Regarding thrombosis related complications, immobilization due to common symptoms after vaccination, such as fatigue, fever and muscle/joint pain might be indirectly concerned with a formation of thrombus, in addition to the immunological mechanism mentioned above, however, this involvement is not directly proven by autopsies.

The Japanese death investigation system is still in a developmental stage, and the autopsy rate for medicolegal deaths is only 11.5% (2019) [41]. The police mainly determine whether forensic autopsy should be performed from the criminal standpoint, especially in areas without a medical examiner system [42]. The fundamental law of promoting inquiry of cause of death was established in June 2019 in Japan [40]. This law emphasizes the role of death investigation for improvement of public health, but it is questionable whether this concept has fully infiltrated into Japanese society. Pathological autopsy is another autopsy to investigate cause of death in Japan, especially when patients die suddenly in the hospitals. However, it needs consent of the relatives and the deceased after COVID-19 vaccination has been rarely performed pathological autopsy [43]. As mentioned above, a causal relationship was not fully evaluated in a great majority of cases of deaths occurring after COVID-19 vaccination in Japan because of the lack of sufficient information, suggesting that such cases have rarely undergone autopsy. Therefore, the Japanese death investigation system needs to be reinforced to adequately evaluate causal relationships between death and vaccination.

This study had several limitations. First, the sample size was not large, and all of the data were collected from an area inhabited by approximately 7% of the total Japanese population. Therefore, the results may not be generalizable to the entire Japanese population. Further large-scale studies are needed in the future to address this limitation. Second, blood biochemical test and toxicological analysis were not necessarily performed in this study sample, especially in cases in which causes of death were evident from macroscopic and histopathological findings. The anti-PF4 antibody level was not measured in this study. Five deaths were caused by ischemic heart disease with thrombus in coronary arteries with severe atherosclerotic changes. We considered the severe atherosclerotic changes to be a significant factor of thrombi, but the possibility of VITT may have been underestimated in these cases. Third, regarding number of day post vaccination, we selected persons who received vaccination against COVID-19 within 7 days, because the average of time intervals between vaccine administration and the first symptoms was 7.8 days in the previous study [3], however, further studies including persons who died 14 days or longer after vaccination may clarify delayed presentation of severe adverse effects of vaccination. Fourth, we mainly examined previously known severe adverse effects (e.g., myocarditis) to assess possible causal relationships between vaccination and death, however, we cannot possibly deny that rare complications or complications difficult to be proven by autopsies, such as seizures [44], might be concerned with non-natural death (e.g., drowning during bathing).

In conclusion, although many cases of deaths occurring soon after COVID-19 vaccination in this study showed no definite causal relationship between the vaccination and the death, a few cases showed possible adverse events, such as myocarditis. Autopsies are essential for detecting vaccine-related deaths, but in Japan, many such deceased individuals may not have undergone autopsies, thereby precluding the collection of adequate information to determine a causal relationship between death and vaccination. The Japanese death investigation system needs to be reinforced from this viewpoint.

Declaration of Competing Interest

The authors declare that they have no known competing financial interests or personal relationships that could have appeared to influence the work reported in this paper.

References

- [1] Coronaviridae Study Group of the International Committee on Taxonomy of Viruses, The species severe acute respiratory syndrome-related coronavirus: classifying 2019-nCoV and naming it SARS-CoV-2, *Nat. Microbiol.* 5(2020) 536–544.
- [2] H. Ritchie, E. Mathieu, L.R. Guirao, C. Appel, C. Giattino, E.O. Ospina, et al, Coronavirus pandemic (COVID-19). <https://ourworldindata.org/coronavirus>, 2022 (accessed 15 June 2022).
- [3] F. Sessa, M. Salerno, M. Esposito, N.D. Nunno, P. Zamboni, C. Pomara, Autopsy findings and causality relationship between death and COVID-19 vaccination: a systematic review, *J. Clin. Med.* 10 (2021) 5876, <https://doi.org/10.3390/jcm10245876>.
- [4] F.P. Polack, S.J. Thomas, N. Kitchin, J. Absalon, A. Gurtman, S. Lockhart, J. L. Perez, G. Pérez Marc, E.D. Moreira, C. Zerbini, R. Bailey, K.A. Swanson, S. Roychoudhury, K. Koury, P. Li, W.V. Kalina, D. Cooper, R.W. Frenck, L. L. Hammitt, Ö. Türeci, H. Nell, A. Schaefer, S. Ünal, D.B. Tresnan, S. Mather, P. R. Dormitzer, U. Şahin, K.U. Jansen, W.C. Gruber, Safety and Efficacy of the BNT162b2 mRNA Covid-19 Vaccine, *N. Engl. J. Med.* 383 (27) (2020) 2603–2615.
- [5] L.R. Baden, H.M. El Sahly, B. Essink, K. Kotloff, S. Frey, R. Novak, D. Diemert, S. A. Spector, N. Rouphael, C.B. Creech, J. McGettigan, S. Khetan, N. Segall, J. Solis, A. Brosz, C. Fierro, H. Schwartz, K. Neuzil, L. Corey, P. Gilbert, H. Janes, D. Follmann, M. Marovich, J. Mascola, L. Polakowski, J. Ledgerwood, B.S. Graham, H. Bennett, R. Pajon, C. Knightly, B. Leav, W. Deng, H. Zhou, S. Han, M. Ivarsson, J. Miller, T. Zaks, Efficacy and safety of the mRNA-1273 SARS-CoV-2 vaccine, *N. Engl. J. Med.* 384 (5) (2021) 403–416.
- [6] S.Y. Tartof, J.M. Slezak, L. Puzniak, V. Hong, F. Xie, B.K. Ackerson, S.R. Valluri, L. Jodar, J.M. McLaughlin, Durability of BNT162b2 vaccine against hospital and emergency department admissions due to the omicron and delta variants in a large health system in the USA: a test-negative case–control study, *The Lancet Respiratory Med.* 10 (7) (2022) 689–699.
- [7] A. Sheikh, S. Kerr, M. Woolhouse, J. McMenamin, C. Robertson, C.R. Simpson, T. Millington, T. Shi, U. Agrawal, S. Shahul Hameed, E. Hall, I. Rudan, S.A. Shah, L. Ritchie, S. Stock, C. McCowan, Severity of omicron variant of concern and effectiveness of vaccine boosters against symptomatic disease in Scotland (EAVE II): a national cohort study with nested test-negative design, *The Lancet Infectious Dis.* 22 (7) (2022) 959–966.
- [8] K.G. Blumenthal, L.B. Robinson, C.A. Camargo, E.S. Shenoy, A. Banerji, A. B. Landman, P. Wickner, Acute allergic reactions to mRNA COVID-19 vaccines, *JAMA* 325 (15) (2021) 1562.
- [9] B. Cabanillas, N. Novak, Allergy to COVID-19 vaccines: a current update, *Allergol. Int.* 70 (2021) 313–318.
- [10] I.A. Myles, J.S. Vinciguerra, R.T. Premus, Specialist confirmed allergic reactions to COVID-19 mRNA vaccines at a mass vaccination site, *Vaccine* 39 (2021) 4404–4406, <https://doi.org/10.1016/j.vaccine.2021.06.061>.
- [11] M.-A. Kim, Y.W. Lee, S.R. Kim, J.-H. Kim, T.-K. Min, H.-S. Park, M. Shin, Y.-M. Ye, S. Lee, J. Lee, J.-H. Choi, G.C. Jang, Y.-S. Chang, COVID-19 Vaccine-associated anaphylaxis and allergic reactions: consensus statements of the KAAACI urticaria/angioedema/anaphylaxis working group, *Allergy Asthma, Immunol. Res.* 13 (4) (2021) 526.
- [12] A. Cereda, C. Conca, L. Barbieri, G. Ferrante, G. Tumminello, S. Lucreziotti, et al., Acute myocarditis after the second dose of SARS-CoV-2 vaccine: serendipity or atypical causal relationship? *Anatol. J. Cardiol.* 25 (2021) 522–523, <https://doi.org/10.5152/AnatolJCardiol.2021.99>.
- [13] A. Nevet, Acute myocarditis associated with anti-COVID-19 vaccination, *Clin. Exp. Vaccine Res.* 10(2021)196–197. <https://doi.org/10.7774/cevr.2021.10.2.196>.
- [14] B. Mengesha, A.G. Asenov, B.H. Raccah, O. Amir, O. Pappo, R. Asleh, Severe acute myocarditis after the third (booster) dose of mRNA COVID-19 vaccination, *Vaccines (Basel)*. 10 (2022) 575, <https://doi.org/10.3390/vaccines10040575>.
- [15] R. Ameratunga, S.-T. Woon, M.N. Sheppard, J. Garland, B. Ondruschka, C.X. Wong, R.A.H. Stewart, M. Tatley, S.R. Stables, R.D. Tse, First Identified Case of Fatal Fulminant Necrotizing Eosinophilic Myocarditis Following the Initial Dose of the Pfizer-BioNTech mRNA COVID-19 Vaccine (BNT162b2, Comirnaty): an extremely rare idiosyncratic hypersensitivity reaction, *J. Clin. Immunol.* 42 (3) (2022) 441–447.
- [16] S. Choi, S. Lee, J.W. Seo, M.J. Kim, Y.H. Jeon, J.H. Park, Myocarditis-induced sudden death after BNT162b2 mRNA COVID-19 vaccination in Korea: case report focusing on histopathological findings, *J. Korean Med. Sci.* 36(2021)e286. <https://doi.org/10.3346/jkms.2021.36.e286>.
- [17] J.R. Gill, R. Tashjian, E. Duncanson, Autopsy histopathology cardiac findings in two adolescents following the second COVID-19 vaccine dose, *Arch. Pathol. Lab. Med.* (2022) <https://doi.org/10.5858/arpa.2021-0435-SA>. Online ahead of print.
- [18] S. Heymans, L.T. Cooper, Myocarditis after COVID-19 mRNA vaccination: clinical observations and potential mechanisms, *Nat. Rev. Cardiol.* 19 (2) (2022) 75–77.
- [19] Y. Aladdin, H. Algahtani, B. Shirah, Vaccine-induced immune thrombotic thrombocytopenia with disseminated intravascular coagulation and death following the ChAdOx1 nCoV-19 Vaccine, *J. Stroke and Cerebrovascular Dis.* 30 (9) (2021) 105938.
- [20] M. Franchini, G.M. Liunbruno, M. Pezzo, COVID-19 vaccine-associated immune thrombosis and thrombocytopenia (VITT): diagnostic and therapeutic recommendations for a new syndrome, *Eur. J. Haematol.* 107 (2021) 173–180, <https://doi.org/10.1111/ejh.13665>.
- [21] N. Barda, N. Dagan, Y. Ben-Shlomo, E. Kepten, J. Waxman, R. Ohana, M.A. Hernán, M. Lipsitch, I. Kohane, D. Netzer, B.Y. Reis, R.D. Balicer, Safety of the BNT162b2 mRNA Covid-19 vaccine in a nationwide setting, *N. Engl. J. Med.* 385 (2021) 1078–1090, <https://doi.org/10.1056/NEJMoa2110475>.
- [22] Ministry of Health, Labour and Welfare, Efficacy and safety of the COVID-19 vaccines, https://www.mhlw.go.jp/stf/seisakunitsuite/bunya/vaccine_yuukousei_anzensei.html,2022 (Accessed 16 June 2022).
- [23] Prime Minister's Office of Japan, Number of inoculation of the COVID-19 vaccines, <https://www.kantei.go.jp/jp/headline/kansensho/vaccine.html,2022> (Accessed 16 June 2022).
- [24] Ministry of Health, Labour and Welfare, Report of cases suspected of adverse effects of the COVID-19 vaccines, https://www.mhlw.go.jp/stf/seisakunitsuite/bunya/vaccine_hukuhannou-utagai-houkoku.html,2022 (Accessed 16 June 2022).
- [25] T. H. Bjørnstad-Tuveng, A. Rudjord, P. Anker, Fatal cerebral haemorrhage after COVID-19 vaccine, *Tidsskr. Nor. Laegeforen.* 141(2021)1-4. <https://doi.org/10.4045/tidsskr.21.0312>.
- [26] A. Greinacher, T. Thiele, T.E. Warkentin, K. Weisser, P.A. Kyrle, S. Eichinger, Thrombotic thrombocytopenia after ChAdOx1 nCov-19 vaccination, *N. Engl. J. Med.* 384 (2021) 2092–2101, <https://doi.org/10.1056/NEJMoa2104840>.
- [27] M. Franchini, S. Testa, M. Pezzo, C. Glingani, B. Caruso, I. Terenzi, C. Pognani, S. A. Bellometti, G. Castelli, Cerebral venous thrombosis and thrombocytopenia post-COVID-19 vaccination, *Thromb. Res.* 202(2021)182-183. <https://doi.org/10.1016/j.thromres.2021.04.001>.
- [28] F. Permezel, B. Borojevic, S. Lau, H.H. de Boer, Acute disseminated encephalomyelitis (ADEM) following recent Oxford/AstraZeneca COVID-19 vaccination, *Forensic Sci. Med. Pathol.* 18 (1) (2022) 74–79.
- [29] C. Pomara, F. Sessa, M. Ciacchio, F. Dieli, M. Esposito, S. F. Garozzo, A. Giarratano, D. Prati, F. Rappa, M. Salerno, et al, Post-mortem findings in vaccine-induced thrombotic thrombocytopenia, *Haematologica.* 106(2021)2291–2293. <https://doi.org/10.3324/haematol.2021.279075>.
- [30] N. H. Schultz, I. H. Sørvoll, A. E. Michelsen, L. A. Munthe, F. Lund-Johansen, M. T. Ahlen, M. Wiedmann, A. H. Aamodt, T. H. Skattør, G. E. Tjønnfjord, et al, Thrombosis and thrombocytopenia after ChAdOx1 nCov-19 vaccination, *N. Engl. J. Med.* 384(2021)2124–2130. <https://doi.org/10.1056/NEJMoa2104882>.
- [31] M. Scully, D. Singh, R. Lown, A. Poles, T. Solomon, M. Levi, D. Goldblatt, P. Kotoucek, W. Thomas, W. Lester, Pathologic Antibodies to Platelet Factor 4 after ChAdOx1 nCov-19 Vaccination, *N. Engl. J. Med.* 384(2021)2202–2211. <https://doi.org/10.1056/NEJMoa2105385>.
- [32] I. See, J.R. Su, A. Lale, E.J. Woo, A.Y. Guh, T.T. Shimabukuro, M.B. Streiff, A. K. Rao, A.P. Wheeler, S.F. Beavers, N.P. Durbin, K. Edwards, E. Miller, T. A. Harrington, A. Mba-Jonas, N. Nair, D.T. Nguyen, K.R. Talaat, V.C. Urrutia, S. C. Walker, C.B. Creech, T.A. Clark, F. DeStefano, K.R. Broder, US Case Reports of Cerebral Venous Sinus Thrombosis With Thrombocytopenia After Ad26.COV2.S Vaccination, March 2 to April 21, 2021, *JAMA* 325 (24) (2021) 2448.
- [33] A. K. Verma, K. J. Lavine, C. Y. Lin, Myocarditis after Covid-19 mRNA vaccination, *N. Engl. J. Med.* 385(2021)1332–1334. <https://doi.org/10.1056/NEJMc2109975>.
- [34] C. Edler, A. Klein, A. S. Schröder, J. P. Spherhake, B. Ondruschka, Deaths associated with newly launched SARS-CoV-2 vaccination (Comirnaty®), *Leg. Med. (Tokyo)*. 51(2021)101895. <https://doi.org/10.1016/j.legalmed.2021.101895>.
- [35] J. Schneider, L. Sottmann, A. Greinacher, M. Hagen, H.-U. Kasper, C. Kuhnen, S. Schüller, S. Schmidt, R. Schulz, T. Thiele, C. Thomas, A. Schmeling, Postmortem investigation of fatalities following vaccination with COVID-19 vaccines, *Int. J. Legal Med.* 135 (6) (2021) 2335–2345.
- [36] A. Yeo, B. Kuek, M. Lau, S.R. Tan, S. Chan, Post COVID-19 vaccine deaths-Singapore's early experience, *Forensic Sci. Int.* 332(2022)111199. <https://doi.org/10.1016/j.forsciint.2022.111199>.
- [37] P. Rzymiski, B. Perek, R. Flisiak, Thrombotic thrombocytopenia after COVID-19 vaccination: in search of the underlying mechanism, *Vaccines (Basel)*. 9(2021)559. <https://doi.org/10.3390/vaccines9060559>.
- [38] A.Y. Kim, W. Woo, D.K. Yon, S.W. Lee, J.W. Yang, J.H. Kim, S. Park, A.I. Koyanagi, M.S. Kim, S. Lee, J.I. Shin, L. Smith, Thrombosis patterns and clinical outcome of COVID-19 vaccine-induced immune thrombotic thrombocytopenia: a systematic review and meta-analysis, *Int. J. Infect. Dis.* 119 (2022) 130–139.
- [39] B. Long, R. Bridwell, M. Gottlieb, Thrombosis with thrombocytopenia syndrome associated with COVID-19 vaccines, *Am. J. Emerg. Med.* 49(2021)58-61. <https://doi.org/10.1016/j.ajem.2021.05.054>.
- [40] G. M. Arepally, T. L. Ortel, Vaccine-induced immune thrombotic thrombocytopenia: what we know and do not know, *Blood.* 138(2021) 293-298. <https://doi.org/10.1182/blood.2021012152>.
- [41] Ministry of Health, Labour and Welfare, Promoting inquiry of cause of death, https://www.mhlw.go.jp/stf/seisakunitsuite/bunya/kenkou_iryuu/iryuu/shiinkyuumei.html. (Accessed 16 June 2022).
- [42] H. Suzuki, T. Fukunaga, T. Tanifuji, N. Abe, A. Sadakane, Y. Nakamura, A. Sakamoto, Medicolegal death diagnosis in Tokyo Metropolis, Japan (2010): Comparison of the results of death inquests by medical examiners and medical practitioners, *Legal Medicine* 13 (6) (2011) 273–279.
- [43] The Japanese Society of Pathology, Recommendation pathological autopsy and forensic autopsy for cases dying after COVID-19 vaccination, <https://www.pathology.or.jp/jigyuu/post-2.html>. (Accessed 29 July 2022).
- [44] S.A. Assiri, R.M.M. Althaqafi, K. Alswat, A.A. Alghamdi, N.E. Alomairi, D. M. Nemenqani, Z.S. Ibrahim, A. Elkady, Post COVID-19 vaccination-associated neurological complications, *Neuropsychiatr. Dis. Treat.* 18 (2022) 137–154.
- [45] A. Takada, K. Saito, K. Yoneyama, M. Hara, H. Nakanishi, S. Takahashi, S. Urabe, K. Asakura, K. Hayashi, Cardiac interstitial inflammation in sudden death cases after COVID-19 vaccination: three autopsy cases of post-vaccine “myocarditis”, *Res. Pract. Forensic Med.* 65(2022) in press (English abstract available).