

# Peripheral Pulmonary Emboli Detected by Radial Probe Endobronchial Ultrasound

Xi-Qian Xing<sup>1</sup>, Jiao Yang<sup>2</sup>, Zhi-Dong Li<sup>1</sup>, Yan-Hong Liu<sup>1</sup>, Yi Xiao<sup>1</sup>, Yan-Li Li<sup>1</sup>, Li-Qiong Liu<sup>1</sup>, Li-Hui Zhang<sup>1</sup>, Xu-Wei Wu<sup>1</sup>

<sup>1</sup>First Department of Respiratory Medicine, Yan'an Hospital Affiliated to Kunming Medical University, Kunming, Yunnan 650051, China

<sup>2</sup>First Department of Respiratory Medicine, First Affiliated Hospital of Kunming Medical University, Kunming, Yunnan 650032, China

To the Editor: Endobronchial ultrasound (EBUS) has been utilized as a useful noninvasive diagnostic tool for mediastinal lymph nodes or masses. Recently, convex probe EBUS (CP-EBUS) has recently come to be used to diagnose central pulmonary embolism.<sup>[1-3]</sup> However, CP-EBUS cannot detect peripheral pulmonary embolism. It is here believed that the potential use of EBUS is still underestimated. Until now, there has been few reports showing whether radial probe EBUS (RP-EBUS) can detect peripheral pulmonary embolism. For this reason, we here report a case of a 60-year-old man admitted to our hospital because of enlarged mediastinal lymph nodes.

The patient presented with a 2-month history of coughing and exertional dyspnea, without fever, hemoptysis, and night sweats. Unenhanced computed tomography (CT) of the patient's chest revealed interstitial pneumonia and enlargement of lymph nodes in the bilateral hilar and mediastinum. Laboratory tests showed the concentration of the D-dimer to be 5.30 mg/L, and the samples were positive for the antinuclear antibody, antineutrophil cytoplasmic antibodies (ANCA), perinuclear ANCA, and myeloperoxidase. For this reason, a diagnosis of microscopic polyangiitis was made. However, serum CA125 and CA153 were elevated and CP-EBUS (model BF-UC160F-OL8; Olympus, Tokyo, Japan), transbronchial needle aspiration, was performed to determine the cause of lymph node enlargement. Because of the elevated levels of D-dimer, CP-EBUS was used for central pulmonary emboli. However, no pulmonary emboli were found. For this reason, RP-EBUS (BS-20 to 26R; Olympus, Tokyo, Japan) was used to see if it could detect the peripheral pulmonary emboli.

RP-EBUS showed an orbicular hypoechoic mass in the left lower posterior basal subsegmental pulmonary artery [Figure 1a] and a slightly strong echo mass, which was considered a mural thrombus, in the right lower posterior basal subsegmental pulmonary artery [Figure 1b]. Enhanced CT confirmed multiple emboli in the bilateral lower segmental and subsegmental pulmonary arteries [Figure 1c]. The pathology of mediastinal lymph node was a poorly differentiated carcinoma, but the specific type of cancer could not be determined. Because the lung lesion was not found by CT of the chest, the tumor node metastasis staging of lung cancer was considered to be TxN3M0 IIIB. The patient was treated with anticoagulants and radiotherapy.

Generally, angio-CT is the established diagnostic method. However, angio-CT scan has a radiation level of 10 mSv, which is equivalent to 50 chest radiographs, and it needs iodinated contrast agents.<sup>[4]</sup> Angio-CT is also incompatible with major renal impairment or anaphylactic response to contrast media of patients and it is unfit for a recheck in the short term. Angio-CT is also not suitable for use on pregnant women. The PIOPED II study demonstrated that these contraindications were about 24% of the patients with suspected acute pulmonary embolism.<sup>[5]</sup> Therefore, we need a new approach to diagnose pulmonary embolism.

In this study, the use of RP-EBUS to detect peripheral pulmonary embolism showed RP-EBUS to be a safe and feasible tool for the diagnosis of peripheral pulmonary embolism and it can be performed at the patient's bedside without any need to transport the patient. The advantages of RP-EBUS over CT in detecting peripheral pulmonary embolism is that there is no need for iodinated contrast agents or radiation, so that it may be suitable for patients with major renal impairment and pregnant patients. The disadvantage of RP-EBUS is that it is not compatible with color Doppler, and endoscopic physicians need to have a working knowledge of ultrasound. Randomized, blinded trials will be necessary to assess its usefulness as a primary approach to the diagnosis of peripheral pulmonary embolism.

## Financial support and sponsorship

This study was supported by the grants from National Natural Science Foundation of China (No. 81100037 and 81360049) and Science and Technology Program for Public Wellbeing of Yunnan Province (No. 2014RA020).

## Conflicts of interest

There are no conflicts of interest.

**Address for correspondence:** Dr. Xu-Wei Wu,

First Department of Respiratory Medicine, Yan'an Hospital Affiliated to Kunming Medical University, No. 245 East Renmin Road, Kunming, Yunnan 650051, China  
E-Mail: wuxuweikm@yahoo.com

### Access this article online

#### Quick Response Code:



**Website:**  
www.cmj.org

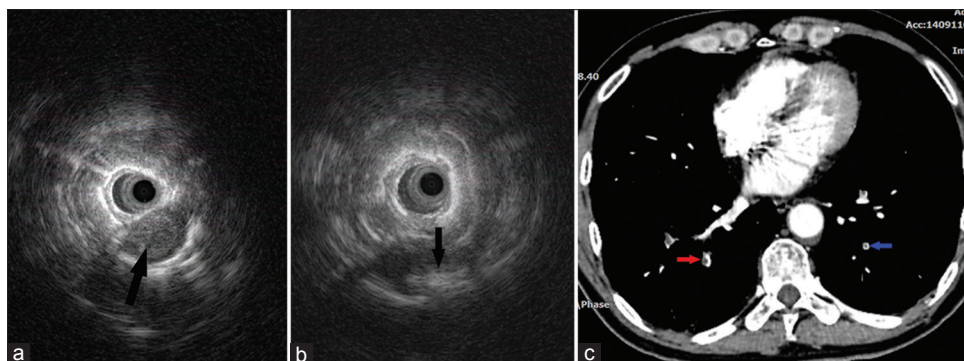
**DOI:**  
10.4103/0366-6999.169119

This is an open access article distributed under the terms of the Creative Commons Attribution-NonCommercial-ShareAlike 3.0 License, which allows others to remix, tweak, and build upon the work non-commercially, as long as the author is credited and the new creations are licensed under the identical terms.

© 2015 Chinese Medical Journal | Produced by Wolters Kluwer - Medknow

**Received:** 19-05-2015 **Edited by:** Li-Min Chen

**How to cite this article:** Xing XQ, Yang J, Li ZD, Liu YH, Xiao Y, Li YL, Liu LQ, Zhang LH, Wu XW. Peripheral Pulmonary Emboli Detected by Radial Probe Endobronchial Ultrasound. *Chin Med J* 2015;128:3116-7.



**Figure 1:** Radial probe endobronchial ultrasound showing endovascular hypoechoic and hyperechoic image in the left and right lower lobe posterior basal subsegmental pulmonary artery, respectively (a and b, arrow); and computed tomography pulmonary angiography showing filling defect in the left and right lower lobe posterior basal subsegmental pulmonary artery (c, arrows).

## REFERENCES

1. Vial MR, Sarkiss M, Lazarus DR, Eapen G. Endobronchial ultrasound-guided diagnosis of pulmonary artery tumor embolus. *Ann Thorac Surg* 2015;99:1816-9.
2. Sentürk A, Argüder E, Babaoglu E, Hezer H, Hasanoglu HC. Diagnostic imaging of pulmonary embolism using endobronchial ultrasound. *Arch Bronconeumol* 2013;49:268-71.
3. Harris K, Chalhoub M. Endobronchial ultrasound as a confirmatory tool for the diagnosis of pulmonary embolism. *Ann Thorac Med* 2014;9:127-8.
4. Brenner DJ, Hall EJ. Computed tomography – An increasing source of radiation exposure. *N Engl J Med* 2007;357:2277-84.
5. Stein PD, Fowler SE, Goodman LR, Gottschalk A, Hales CA, Hull RD, *et al*. Multidetector computed tomography for acute pulmonary embolism. *N Engl J Med* 2006;354:2317-27.