

Monoclonal Gammopathy of Renal Significance: A Molecular Middle Earth between Oncology, Nephrology, and Pathology

Vincenzo L'Imperio^a Giorgio Cazzaniga^a Barbara Vergani^a
Andrew James Smith^b Federico Alberici^{c, d} Fabio Pagni^a

^aDepartment of Medicine and Surgery, Pathology, ASST Monza, San Gerardo Hospital, University of Milan-Bicocca, Monza, Italy; ^bDepartment of Medicine and Surgery, Clinical Proteomics and Metabolomics Unit, University of Milano - Bicocca, Monza, Italy; ^cDepartment of Medical and Surgical Specialties, Radiological Sciences and Public Health, University of Brescia, Brescia, Italy; ^dNephrology Unit, Spedali Civili Hospital, ASST Spedali Civili di Brescia, Brescia, Italy

Keywords

Monoclonal gammopathy of renal significance · Lymphoma · Multiple myeloma · Renal biopsy · Mass spectrometry · Proteomics

Abstract

Background: The renal biopsy represents a cornerstone in the definition of monoclonal gammopathy of renal significance (MGRS), helping in identifying patients with sub-detectable neoplastic clones (MGUS) that would deserve aggressive chemotherapies. However, the rising complexity of this onco-nephrology field is significantly challenging the daily work of nephrologists and nephropathologists, leading to the formation of ultra-specialized international centers with dedicated personnel/instrumentation and stressing the need for a better understanding of the underlying molecular landscape of these entities. **Summary:** In this setting, the application of proteomic techniques, some with in situ capabilities (e.g., MALDI-MS imaging), for the investigation of the most challenging MGRS is progressively shedding light on the pathobiology of these diseases, providing new insights in the diagnosis and prognosis of these cases. This transformation is further enhanced by the application of

next-generation digital pathology platforms, leading to a significant improvement of the cultural background for physicians thanks to second opinions, database and atlas creation, enhancement of diagnostic reports, with obvious repercussions for patients both in terms of turnaround time and appropriateness. **Key Messages:** The present review is aimed at bridging the gap between clinical questions (i.e., a better characterization of MGRS) and the molecular landscape of onco-nephrology entities.

© 2022 The Author(s).

Published by S. Karger AG, Basel

Introduction

The complex interaction between cancer and kidneys has been extensively studied in the last decades, leading to the creation of a translational sub-speciality, onco-nephrology, based on the strict collaboration of pathologists, nephrologists, and oncologists [1, 2]. In this setting, renal disease in patients with hematological malignancies probably represents the most striking example of this peculiar cancer-kidney interplay, especially in cases characterized by the presence of nephrotoxic circulating monoclonal immunoglobulins [3]. Based on the most recent

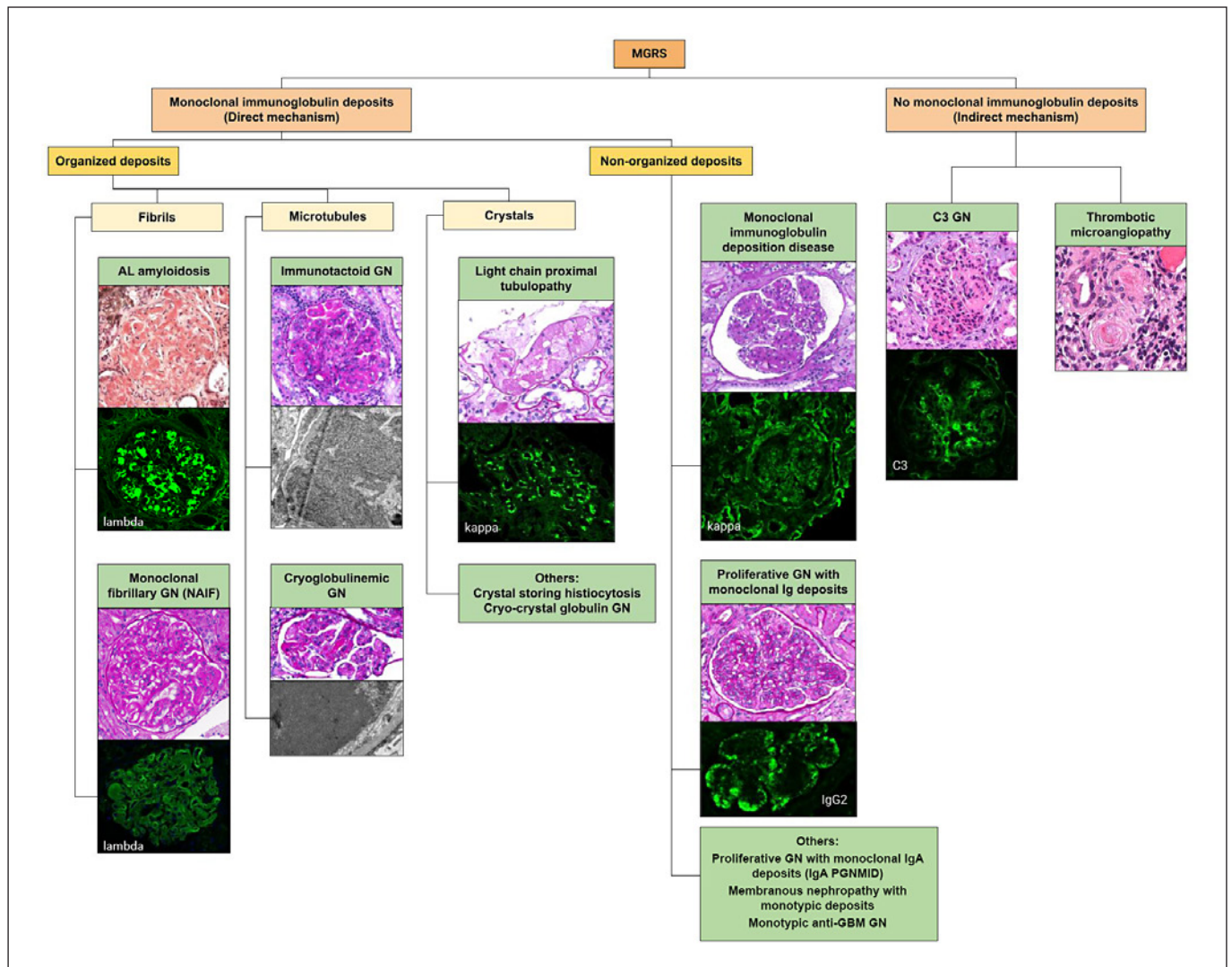


Fig. 1. Schematic view of the current classification of MGRS based on the possible mechanism of damage of the monoclonal immunoglobulin against the kidney (direct vs. indirect) and on the characteristics of the deposits (organized vs. nonorganized). GN, glomerulonephritis. Modified from Leung et al. [16].

recommendations, only patients with overt multiple myeloma (MM), chronic lymphocytic leukemia, or lymphoplasmacytic lymphoma as per International Myeloma Working Group criteria receive chemotherapy [4–6]. The remaining cases, characterized by an isolated monoclonal component (MC) with tumor burden below the threshold of requiring treatment, are labeled as monoclonal gammopathy of undetermined significance (MGUS), thus undergoing hematological follow-up without aggressive treatment. However, starting from 2012 it has become more and more evident that even small amounts of these nephrotoxic immunoglobulins in the absence of

overt tumor burden can significantly impair the renal function, causing different clinical syndromes (e.g., nephrotic) as well as acute kidney injury, leading to the introduction of the MGRS concept [7]. These cases account for about 10% of MGUS, affecting between 0.32% and 0.53% of patients from 50 to 70 years old [8], can anticipate by years the development of the malignancy, and are poorly responsive to standard immunosuppressive therapies used in other immune-mediated glomerulonephritis (GN) [9, 10] with an outcome comparable to that of overt hematological neoplasms [11, 12]. This paradigm shift stressed the importance of an early detection of MGRS

Table 1. Clinical, histopathological, and ultrastructural features of the main MGRS

	Clinical features	LM	IF	Electron microscopy	Treatment
MIDD	Proteinuria (90%) usually nephrotic range, hypertension, and hematuria (75%)	Nodular glomerulosclerosis with ribbon-like thickening of TBMs	Linear positivity along the GBMs and TBMs for the involved MC, usually kappa LC for LCDD	Powdery electron-dense deposits along inner aspects of GMB and outer aspect of TBM	Proteasome inhibitors along with supportive therapy. Renal transplantation could represent an alternative for some patients affected by MIDD
PGNMID	Variable, nonspecific	MPGN pattern with double-contour formation and endocapillary hypercellularity with large, wire-loop-like deposits	Glomerular-limited granular mesangial and capillary deposits of IgG with kappa LC restriction in 73% of cases. IgM and IgA in about 10% of cases. C3 codeposition is constant, C1q in 55–64% of cases	Electron-dense granular deposits mainly located in mesangial and subendothelial spaces	Aggressive treatment if MC is detected; RAS blockade agents if a MC is not detected and the renal function is preserved
Amyloidosis	Proteinuria (73%), usually full nephrotic syndrome	Amorphous deposits, with pale PAS and Jones stain, strong positivity to Congo red stain with typical green-apple birefringence involving the glomeruli, vessels, and interstitium	Smudgy positivity of the deposits for the involved light (in AL cases), heavy (in AH cases) chains, or both (in AHL cases)	Nonbranching, randomly arranged, 8–12 nm diameter fibrils	Chemotherapy even in the absence of full-blown MM
FGN	Renal insufficiency and proteinuria, 36% of which shows a full nephrotic syndrome usually with hematuria	MPGN with GBM double contour and cellular interposition with glomerular restricted, PAS, and Jones-negative mesangial and capillary wall deposits	Mainly mesangial and capillary wall smudgy IgG deposits, rarely linear GBM IgG positivity. About 2% of cases are monotypic	Randomly arranged, nonbranching fibrils of 12–22 nm diameter	RAS blockade agents; rituximab in patients with relatively normal baseline renal function; transplant
IGN	Invariable presence of proteinuria, in 76% in nephrotic range and in 58% with full-blown nephrotic syndrome	Variable patterns of injury, ranging from endocapillary proliferation (35%) to MPGN (29%), followed by membranous pattern of glomerular involvement	Glomerular deposits typically stain positive for IgG and C3 with immunoglobulin LC restriction	Microtubular substructures with distinct hollow centers seen in cross section, 10–90 nm	Not established but clone-directed approach may be the most suitable solution
Cryoglobulinic GN	Nephritic/nephrotic syndrome with various levels of kidney function	MPGN, with characteristic capillary wall ribbon-like and intraluminal globular PAS-positive deposits (cryo-plugs)	Igs and LC positivity reflecting the circulating cryoglobulin composition following the disposition of deposits in LM	Vague, short fibrillary substructures that can be organized as tactoids	Not established but clone-directed approach may be the most suitable solution

MIDD, monoclonal immunoglobulin deposition disease; TBM, tubular basement membrane; GBM, glomerular basement membrane; LCDD, light chain deposition disease; PGNMID, proliferative glomerulonephritis with monoclonal immunoglobulin deposit; MPGN, membranoproliferative glomerulonephritis; RAS, renin-angiotensin system; PAS, periodic acid of Schiff; MM, multiple myeloma; GN, glomerulonephritis.

cases to promptly adopt the most appropriate treatment with aggressive clone-directed therapeutic approaches [13]. The recent introduction of advanced proteomic techniques (e.g., mass spectrometry [MS]) is further twisting the diagnostic assessment and pathogenesis understanding of some of these entities, as in the case of amyloidosis [14]. The deriving complex nosological classification is rapidly changing with the progressive understanding of the direct and indirect nephrotoxic mechanisms of monoclonal immunoglobulins, requiring an elevated nephropathological expertise and a continuous update on the topic (as shown in Fig. 1) [15]. Although the assessment of renal biopsy through “conventional” microscopy techniques, such as light microscopy (LM), immunofluorescence (IF), and transmission electron microscopy, could often be sufficient for the correct classification of MGRS (see Table 1), these are still affected by accuracy issues in challenging cases and the creation of integrated, multicentric digital nephropathology platforms can be useful to overcome these intrinsic limits. This could further enhance the molecular investigation of the most frequent MGRS, with particular attention to the application of tissue and liquid-based proteomics that could in the future highlight a “liquid biopsy” role for urines, as discussed in the present review.

Digital Pathology for the Characterization of MGRS

Some of the major challenges encountered in nephropathology for the assessment of MGRS are represented by the following:

- The need for high expertise to face the complex classification of these entities to solve problematic differential diagnosis [16];
- The need for specific routine tools for the most complete characterization of MGRS (e.g., LM, IF, and EM), which are not always present in all the centers [17, 18];
- The intrinsic limitations of some of these techniques in the MGRS setting (e.g., low sensitivity/specificity for amyloidosis clonality [19]).

To face these challenges, the creation of shared multicenter networks for the correct assessment of MGRS is highly desirable. Currently, only few and rare examples of ultra-specialized reference centers for onco-nephrology exist, which are mainly focused on specific MGRS forms (e.g., amyloidosis) and are not available/accessible in every country. For this reason, the creation of multicenter, digital nephropathology networks dedicated to the study and diagnosis of the whole MGRS group of diseases may

fill the gap existing in the routine practice, complementing the different skills of nephrologists, oncologists, and renal pathologists to improve the comprehensive characterization of MGRS. The employment of next-generation digital pathology platforms may represent a starting point for the enrollment of a retrospective database of cases with available whole slide images for LM, IF, and IHC, with the possibility to upload/retrieve electron microphotographs and complete diagnostic reports. Finally, the presence of a centralized digital nephropathology platform could allow the application of ancillary omic techniques (e.g., proteomics), especially for those based on an *in situ* approach as matrix-assisted laser-desorption/ionization MS imaging (MALDI-MSI), allowing the real-time overlap of the obtained molecular images with the routine histological slides used for the diagnosis.

The Molecular Basis of MGRS: When Light and Heavy Chains Damage the Kidney

As already stressed, the relationship between the circulating MC and the renal deposition is extremely complex. Recent findings stressed the role of specific amino acid sequences of the circulating MC in determining the form and location of the renal deposits (as shown in Fig. 2) [20]. In particular, the amino acid residues in the complementarity-determining region 3 of the V domain of the light chains (LCs) demonstrated a role in the deposition of these molecules in the LC cast nephropathy form [21], whereas single amino acid substitution in the complementarity-determining region 1 of a Fanconi’s syndrome LC prevented the development of proximal tubular lesions [22]. In a similar way, previous attempts to determine the physico-chemical properties of LCs determining their amyloidogenicity were mainly based on *in vitro* studies that did not fully take into account the constellation of physiological conditions that contributes to the deposition of fibrils (e.g., pH, temperature, and cell interaction). Recently, the introduction of new animal model allowed to follow the destiny of amyloidogenic LCs, showing a crucial role for the lysosomes and mesangial cells in the deposition of fibrils, but again failing to demonstrate unique amino acid “fingerprints” useful to identify these fibrillogenic proteins in the pre-deposition state [23]. Although no common structural motifs have been identified yet, the discovery of germline sequences of the V domain and specific amino acid substitution during somatic mutations seems to have a role in the development of LC fibrils [24]. Thus, further investigation of

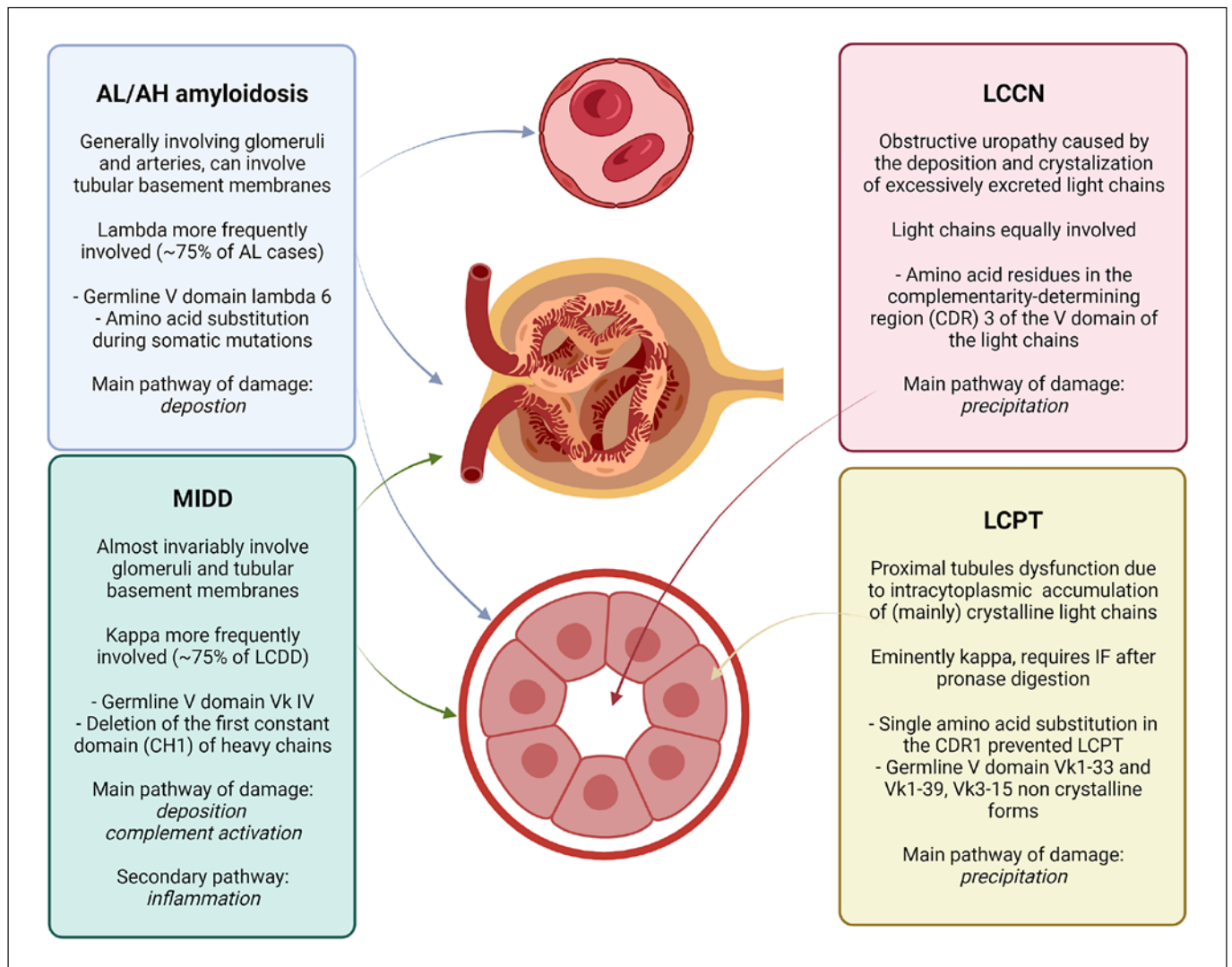


Fig. 2. Possible molecular mechanisms related to light/heavy chain structures that underlies the preferential deposition of MCs in different MGRS forms. AL, light chain amyloidosis; AH, heavy chain amyloidosis; MIDD, monoclonal immunoglobulin deposition disease; LCCN, light chain cast nephropathy; LCPT, light chain proximal tubulopathy. Credit: created with BioRender.

these amino acid sequences could further shed light on the fate of the LCs in the kidney, supported by the proteomic modification of the surrounding microenvironment (e.g., mesangial cells), to define a sort of “fingerprint” that can potentially be used to screen MGUS patients at higher risk to develop MGRS. For these purposes and to add further details on this complex molecular puzzle, several tissue-based proteomic techniques have been used in the past years.

Molecular Tools for the Study of MGRS: Tissue-Based Proteomics

The significant complexity of the MGRS entities led to a revolution in the nosological classification as well as in the available tools to diagnose and appropriately typify these entities on renal biopsy, as already described above. Moreover, this revolution stressed the limitations of some instruments (e.g., IF) routinely employed to characterize some of the most frequent diseases in this context (e.g., amyloidosis), stimulating the employment of additional

and more precise tools for investigative and diagnostic purposes. The most striking example is represented by the routine implementation of laser capture microdissection (LCM) coupled with MS for the identification of the precursor protein in amyloidosis cases, leading to a significant reduction of possible misdiagnosis with obvious therapeutic repercussions [25]. The application of different proteomic approaches led to significant discoveries, elucidating new pathogenetic aspects of different MGRS forms, some of which entered or are progressively being implemented in the clinical practice.

Fibrillary GN

One of the most striking examples is represented by fibrillary GN (FGN), whose pathogenesis and true MGRS nature remained elusive for years, until the discovery of a highly sensitive/specific putative antigen by MS, the DnaJ Heat Shock Protein Family Member B9 (DNAJB9) [26, 27]. Although representing a possible autoantigen in FGN and co-localizing with the IgG deposits in renal biopsies, circulating auto-antibodies directed against this protein have not been identified yet. The majority of DNAJB9-positive cases demonstrate the presence of polytypic deposits by standard frozen IF or after pronase/proteinase digestion IF, with a subset of negative cases showing atypical deposits characterized by the IgG component alone [28] or by monotypic restriction [29]. This led to postulate the possible MGRS nature of at least a subset of FGN cases [30], which should be carefully distinguished from the DNAJB9-positive cases to promptly initiate the most appropriate clone-directed therapy in these monotypic cases, leading some authors to propose an alternative and more specific nomenclature for this rare entity (nonamyloid immunoglobulin clonal fibril glomerulopathy) [31]. Currently, the best therapeutic strategy for these cases is still debated and the relatively poor effects of numerous immunosuppressive treatments and proteasome inhibitors are stressing the need for alternative approaches. Recent research has focused on the role of rituximab in FGN, showing a subset of patients who might benefit from it, with current efforts aimed at identifying that group [32]. However, the current lack of a circulating responsible antibody that would help in following up the depletion of pathogenetic B cell is still representing a limitation for monitoring treatment in FGN. Future efforts may be focused on the development of therapies aimed at reducing the impact of fibrils on the kidney.

Immunotactoid GN

As per FGN, the pathogenesis of clonal microtubule deposition in another rare MGRS, immunotactoid glomerulonephritis (ITG), has been poorly understood for years. Limited existing data suggest that polyclonal ITG has a different pathogenesis than monoclonal ITG. In particular, the formation of microtubules in monotypic forms of ITG can be due to physicochemical properties of the circulating monoclonal protein [33]. On the other hand, the pathogenesis of polyclonal cases is still debated and the deposition of an as-yet identified protein with polymerization capabilities has been postulated as in the DNAJB9-positive FGN cases. The employment of tandem LCM/MS on a series of ITG cases demonstrated the presence of immunoglobulins, monotypic LCs, complement factors of the classical and terminal pathway and small amount of serum amyloid P (SAP) component, apolipoprotein E (apoE), and clusterin in the context of the deposits [34]. Although it did not show the presence of a pathognomonic marker as in the case of FGN, the identification of proteins generally associated with amyloid deposition (e.g., apoE, SAP, and clusterin) suggests a common pathogenetic pathway of protein misfolding in the development of microtubules. As per the therapeutic approach, ITG has been considered an MGRS and thus treated following a clone-directed strategy. This treatment, especially with the association of bortezomib, has shown to improve outcomes, recapitulating the criteria of treatment already established for amyloidosis [35]. The common pathogenetic features between these diseases suggest also a possible similar response of ITG if treated with daratumumab, an anti-CD38 monoclonal antibody which has shown excellent results in treatment of amyloidosis [36].

Monoclonal Immunoglobulin Deposition Disease

A similar complexity can be noted in the pathogenesis of monoclonal immunoglobulin deposition disease (MIDD), which can be present in three different forms based on the integrity of the monoclonal immunoglobulin involved, namely, LC deposition disease (~75%, LCDD), light and heavy chain deposition disease (~14%), and heavy chain deposition disease (~11%, HCDD) [37–40]. Different genetic alterations affecting the circulating monoclonal LC have been advocated to explain the peculiar deposition in LCDD. These mainly affect the variable region of the protein, although no redundant mutations have been described to unify the pathogenetic mechanism of the disease [41, 42] and further murine models are contributing in elucidating the mechanism of renal precipitation [43]. On the other hand, HCDD cases al-

most invariably demonstrate the deletion of the first constant domain of the involved heavy chain [44], although recent studies suggested that this event is essential for the secretion and the deposition of the molecule but might not be sufficient for the development of glomerular injury [45]. Along with genetic studies, proteomics already proven its putative role as a complementary tool in the diagnosis of challenging cases of MIDD [46] characterized by a degree of immunoglobulin deposition under the detection threshold of standard IF or masked epitopes [47], as well as when IF antibodies are unavailable due to extremely rare heavy chains involved (e.g., IgD) [48].

Proliferative GN with Monoclonal Immunoglobulin Deposits

Another interesting and poorly understood entity with nonstructured deposits is represented by proliferative glomerulonephritis with monoclonal immunoglobulin deposit (PGNMID). Although the disease is characterized by the presence of monoclonal renal deposits, the rate of detection of the nephrotoxic monoclonal immunoglobulin in the serum or urine, and of an abnormal bone marrow B-cell clone, is only 30% [10]. The exact mechanisms of action of the monoclonal protein in PGNMID are still largely unknown, and different pathogenic hypotheses have been proposed to explain the development of this rare condition. The predominance of one of the most rare circulating immunoglobulins (IgG3) in the development of the disease [49], the similarity with the glomerular disease induced in murine models through the injection of IgG3 cryoglobulins [50, 51], and the high propensity of this immunoglobulin to aggregate through the Fc segment with great C1q-fixing ability suggest that the nephrotoxicity in these forms probably is derived from the molecular characteristics of the pathogenic monoclonal protein. However, in the small subset of cases without a detectable circulating clone, especially in young patients with spontaneous remission, an oligoclonal production of nephrotoxic IgG3 secondary to a skewed B-cell repertoire induced by viral or other antigenic stimulation could be responsible for the development of the disease. This prompted further efforts in the attempt to understand the development of “true” monoclonal PGNMID cases through the employment of proteomics tools. This allowed the identification of a subset of cases characterized by a LC-only composition of the deposits which are associated with an high detection rate of the pathogenic plasma cell clone, suggesting to restrict the MGRS role for these specific entities in the PGNMID group [52]. An even rare entity, recently reported in small

case series, is represented by the PGNMID with IgA deposits, of which two different forms have been described, the α -HCDD which share similarities with the γ -HCDD counterpart but with a higher frequency of extra-capillary proliferation and extra-renal involvement, and the more peculiar IgA-PGNMID [53]. This last needs particular attention for its partial morphological overlap with more frequent IgA-dominant forms, such as IgA nephropathy and IgA-dominant infection-related GN, which makes the differential diagnosis particularly challenging. However, the demonstration of monotypic IgA deposits with appropriate confirmation after IF on pronase-digested formalin-fixed tissue is of help in its discrimination. Similar to the IgG-PGNMID, the true MGRS nature of the IgA form is still debated; although recent evidences highlighted that overt hematological malignancy was infrequent, sensitive serum and bone marrow studies revealed a subtle plasma cell proliferation in most patients, which further stress the need of a careful clinico-pathological study of these challenging cases.

Amyloidosis

The mechanisms leading to the deposition of monoclonal protein-derived amyloid share common pathogenetic pathways with the other types of amyloidosis, with the already mentioned fibrillar formation and deposition. However, in the setting of light chain amyloidosis (AL), fibrils are composed of either fully intact LCs, including both constant and variable domains, or the variable domain only. Some evidence suggested that an increased amyloidogenic propensity can be conferred to the secreted LCs either by the presence of mutations in the N-terminus (contained within the variable domain) and of the V λ VI subgroup [54, 55] or by post-translational protein modification and proteolysis [56]. The pathogenesis of heavy chain amyloidosis (AH) and AHL is less understood, but similar mechanisms have been hypothesized [57]. In this complex setting, tandem LCM/MS has been proposed and extensively validated in all the cases in which IF fails to demonstrate a straightforward restriction of the deposits, either due to the presence of masked or alternative epitopes, or for trapping phenomena, as well as in the cases with concurrent heavy chain component, representing the upcoming gold standard for amyloid typing [16, 19, 25]. These advancements in the understanding of AL will further help in improving the therapeutic equipment of clinicians, by developing new monoclonal drugs (e.g., birtamimab, CAEL-101, miridesap, dezamizumab) which targets the fibril complex preventing further deposition and facilitating its elimination [58].

Other Rare Forms

Infrequent and atypical possible presentations of MGRS have been reported, although in the form of sporadic case reports or small case series, it is worth mentioning them for the similarities with more common forms of GN, proposing differential diagnosis issues. The question whether some of these entities should be included in the MGRS “family” is still under debate. As a general rule, in all the following occurrences, a strong correlation with serum data and clinical information is strictly needed for their right classification. The most striking example is represented by membranous nephropathy with light-chain-restricted deposits. Although considered secondary/PLA2R-negative form with predominant IgG1 deposits, its pathogenesis is still largely unknown, and the variable correlation with the presence of a detectable monoclonal Ig in serum/urine raises doubts about its real MGRS nature, leading some authors to suggest the presence of a serum MC under the limit of detection [59]. To further complicate the spectrum, membranous-like glomerulopathy with masked IgG kappa deposits, a recently described entity where deposits are masked in routine IF but strongly stain for IgG and kappa LC is shown after pronase digestion, has been provisionally added to the MGRS portfolio in the past. However, MS recently demonstrated the colocalization of these deposits with SAP, forcing us to reconsider the pathogenesis of these rare entities [60]. Finally, even anti-glomerular basement membrane (anti-GBM) disease has its own “monotypic” counterpart [61]. Luckily, this disease offers unusual and unique features, such as a milder clinical course, which help in distinguishing it from either a classical anti-GBM disease or other MGRS. The monotypic anti-GBM antibody inefficiency in triggering downstream events such as complement activation is thought to be linked with the unusual indolent course of this rare subtype of anti-GBM disease, which eventually shows a less acute and destructive pattern of damage.

Molecular Tools for the Study of MGRS: Liquid-Based Proteomics

Historically, serum and urine samples represented the original source of information for the definition of monoclonal gammopathies. Indeed, the first description of a paraprotein dates back to 1847, when Henry Bence-Jones identified an abnormal protein present in the urines of a subset of patients with renal disease (Bence-Jones proteinuria), lately recognized as a LC without the accompa-

nying heavy chain [62]. Although initially considered as an idiopathic [63] or even a benign condition [64], its subsequent link to monoclonal spikes and MM stressed the need to improve their routine assessment and early detection, prompting the development of more sensitive and reliable assays based on electrophoretic and immunofixation techniques [65, 66]. Recently, different alternative proteomics-based methods have been proposed to quantify the serum/urine-free LCs, the majority based on MALDI time-of-flight instruments and with good performances even in the setting of systemic AL [67]. Although the accurate quantification of free LCs has been proposed as a sensitive marker to monitor the response to therapy of AL cases [68], a reliable marker to be employed for the early detection of these patients is still lacking, with a relative delay in the implementation of serum/urines as possible “liquid biopsy” for the diagnosis of MGRS. Preliminary data suggest that the so-called amyloid universal signature (composed of SAP, apoE, and vitronectin) can be recognized, along with the responsible LC, in urinary exosomes (microvesicles obtained by sequential ultracentrifugation) in patients with plasma cell dyscrasias associated with amyloidosis and not in controls [69, 70]. The analysis of these extracellular vesicles demonstrated a different arrangement of the LCs in the urines of patients affected by AL, preferentially organized in high molecular weight oligomers, as compared to MM and MGUS cases that most frequently excrete urinary LC monomers [71]. Moreover, as already mentioned, structural modifications of the LCs predispose to the development of different types of MGRS, suggesting a sort of “specific” fingerprint starting from the amino acid sequence [20]. This has been demonstrated for amyloidosis by the injection of amyloidogenic λ LC into the rat, inducing the same types of fibrillar deposition [72], as well as for the Fanconi syndrome-associated tubulopathy, by using transgenic mouse overexpressing specific κ LC or by the exposition of mouse proximal tubule cells to low doses of the toxic LC [73]. This could represent the basis for the development in the future of dedicated tests to predict the specific nephrotoxic properties of clonal chains starting from the amino acid sequences.

Future Molecular Perspectives: Spatial Transcriptomics

The advent of new tissue-based technologies for the study of the transcriptome is enabling the investigation of the pathological modifications directly where they take

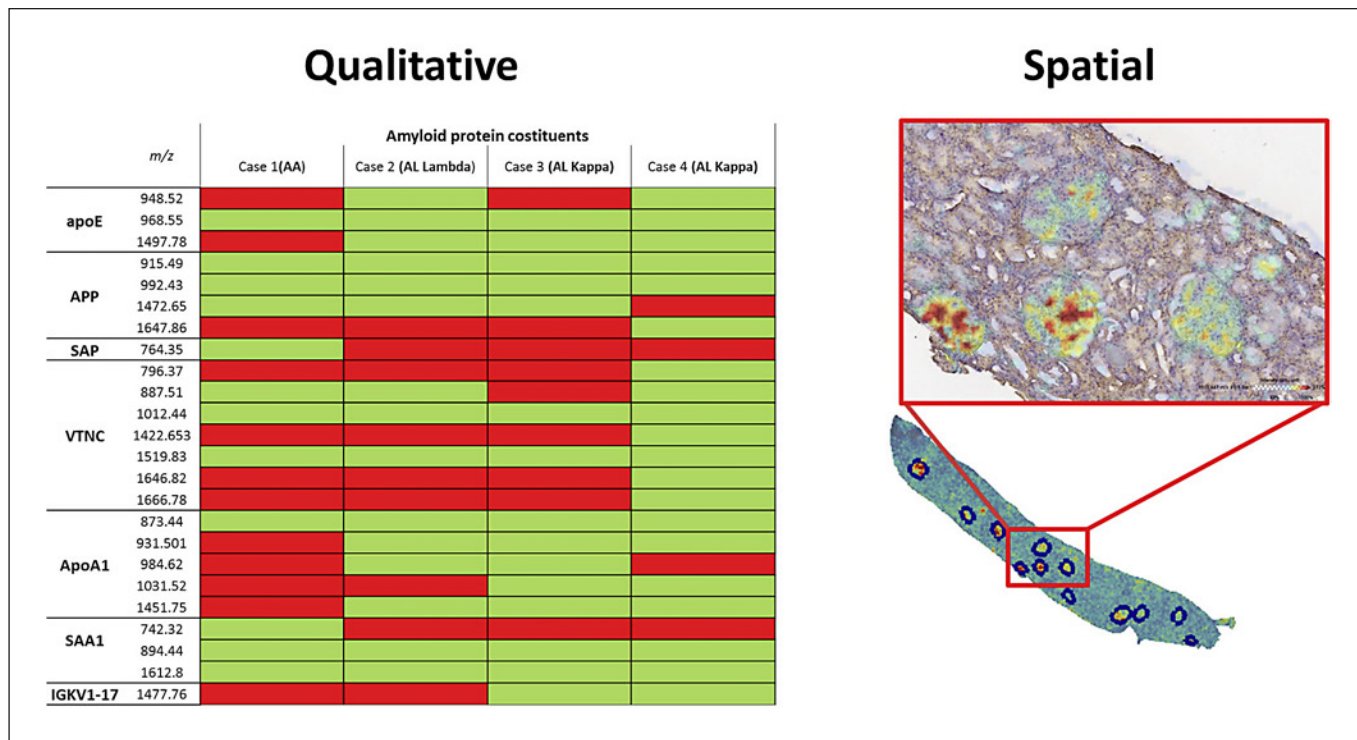


Fig. 3. The preliminary application of MALDI-MS on renal biopsies with different types of amyloidosis (AA, AL kappa, and AL lambda) demonstrated the capability of the technique to detect the shared and common “amyloid universal signature” (composed of SAP, apoE, and vitronectin). Moreover, specific forms such as the AA showed the exclusive expression of unique tryptic peptides

(e.g., m/z 742.32), which are absent in other types of amyloidosis. Finally, the analysis of AL kappa cases highlighted the presence of fragments of the kappa LC that were not present either in the AA and AL lambda forms, demonstrating the recurrence of specific domains of the variable regions (V1-17) that could have a role in the formation of AL kappa amyloid.

place. The application of digital spatial profiling is giving promising results in the study of hematological disorders due to its unprecedented capability of discovering subtle transcriptomic modifications in small regions of tissue that approximate the single-cell analysis [74]. This already found application on renal biopsies in different settings, such as ANCA-associated GN [75] and graft rejection [76], even showing interesting molecular modifications in murine models of acute kidney damage, elucidating region-specific loss of differentiation markers and their re-expression during repair [77]. This has also been applied to investigate the complex interaction between inflammatory cells and surrounding renal structures, such as in the case of LYVE1+ macrophages in the medulla human kidney and its putative protective role against fibrosis or the immunomodulatory role of macrophage Trem2 in damaged tissue [78, 79]. These represent the promising bases on which such tools can be in the future applied for the elucidation of pathogenetic mechanisms leading to the development of the different types of MGRS.

Future Molecular Perspectives: The Role of MALDI-MSI

The recent introduction of a new spatial proteomics approach, using MALDI-MSI technology, enables the molecular information unraveled by MS to be correlated with the morphological detail of a renal biopsy, without the strict need to dissect the tissue through LMD. Moreover, this is routinely performed using the commonly stored formalin-fixed paraffin embedded material. This helped shed light on different aspects of the pathogenesis, resistance to therapy, and diagnosis of different forms of GN [80–87]. This type of approach already demonstrated interesting results in the study of renal amyloidosis cases directly employing renal biopsy tissues without the strict need of a previous LCM [88, 89], allowing the definition of a so-called amyloid universal signature as well as defining the precursor protein involved in each case (as shown in Fig. 3), representing a promising tool for the future of MGRS characterization [90].

Conclusion

The renal biopsy represents a cornerstone in the definition of MGRS, helping in identifying patients with subdetectable neoplastic clones (MGUS) that would deserve aggressive chemotherapies. However, the rising complexity of this onco-nephrology field is significantly challenging the daily work of nephrologists and nephropathologists, leading to the formation of ultra-specialized international centers with dedicated personnel and instrumentation. Although these modifications are progressively but slowly changing the landscape of MGRS diagnosis and treatment, there is still a substantial lack of knowledge on the most rare MGRS forms. Digital nephropathology platforms may be a real-life solution for second opinion and diagnostic sharing with opinion leaders; moreover, a digital approach may be helpful for the application of innovative spatial proteomics technique (MALDI-MSI) to shed light on the pathobiology of MGRS and provide new insights in the diagnosis and prognosis.

References

- 1 Rosner MH, Jhaveri KD, McMahon BA, Perazella MA. Onconephrology: the intersections between the kidney and cancer. *CA A Cancer J Clin*. 2021 Jan;71(1):47–77.
- 2 Salahudeen AK, Bonventre JV. Onconephrology: the latest frontier in the war against kidney disease. *J Am Soc Nephrol*. 2013 Jan;24(1):26–30.
- 3 Leung N, Bridoux F, Hutchison CA, Nasr SH, Cockwell P, Ferman J-P, et al. Monoclonal gammopathy of renal significance: when MGUS is no longer undetermined or insignificant. *Blood*. 2012 Nov;120(22):4292–5.
- 4 Rajkumar SV, Dimopoulos MA, Palumbo A, Blade J, Merlini G, Mateos M-V, et al. International Myeloma Working Group updated criteria for the diagnosis of multiple myeloma. *Lancet Oncol*. 2014 Nov;15(12):e538–48.
- 5 Dimopoulos MA, Gertz MA, Kastritis E, Garcia-Sanz R, Kimby EK, Leblond V, et al. Update on treatment recommendations from the fourth international workshop on waldenström's macroglobulinemia. *J Clin Oncol*. 2009 Jan;27(1):120–6.
- 6 Hallek M, Cheson BD, Catovsky D, Caligaris-Cappio F, Dighiero G, Döhner H, et al. iwCLL guidelines for diagnosis, indications for treatment, response assessment, and supportive management of CLL. *Blood*. 2018 Jun;131(25):2745–60.
- 7 Leung N, Bridoux F, Nasr SH. Monoclonal gammopathy of renal significance. *N Engl J Med*. 2021 May;384(20):1931–41.
- 8 Ciochini M, Arbelbide J, Musso CG. Monoclonal gammopathy of renal significance

- (MGRS): the characteristics and significance of a new meta-entity. *Int Urol Nephrol*. 2017 Dec;49(12):2171–5.
- 9 Heilman RL, Velosa JA, Holley KE, Offord KP, Kyle RA. Long-term follow-up and response to chemotherapy in patients with light-chain deposition disease. *Am J Kidney Dis*. 1992 Jul;20(1):34–41.
- 10 Gumber R, Cohen JB, Palmer MB, Kobrin SM, Vogl DT, Wasserstein AG, et al. A clone-directed approach may improve diagnosis and treatment of proliferative glomerulonephritis with monoclonal immunoglobulin deposits. *Kidney Int*. 2018 Jul;94(1):199–205.
- 11 Steiner N, Göbel G, Suchecki P, Prokop W, Neuwirt H, Gunsilius E. Monoclonal gammopathy of renal significance (MGRS) increases the risk for progression to multiple myeloma: an observational study of 2935 MGUS patients. *Oncotarget*. 2018;9(2):2344–56.
- 12 Kyle RA, Durie BGM, Rajkumar SV, Landgren O, Blade J, Merlini G, et al. Monoclonal gammopathy of undetermined significance (MGUS) and smoldering (asymptomatic) multiple myeloma: IMWG consensus perspectives risk factors for progression and guidelines for monitoring and management. *Leukemia*. 2010;24(6):1121–7.
- 13 Ferman J-P, Bridoux F, Kyle RA, Kastritis E, Weiss BM, Cook MA, et al. How I treat monoclonal gammopathy of renal significance (MGRS). *Blood*. 2013 Nov;122(22):3583–90.
- 14 Picken MM. Proteomics and mass spectrometry in the diagnosis of renal amyloidosis. *Clin Kidney J*. 2015;8(6):665–72.

- 15 Sethi S, Rajkumar SV, D'Agati VD. The complexity and heterogeneity of monoclonal immunoglobulin: associated renal diseases. *J Am Soc Nephrol*. 2018;29(7):1810–23.
- 16 Leung N, Bridoux F, Batuman V, Chaidos A, Cockwell P, D'Agati VD, et al. The evaluation of monoclonal gammopathy of renal significance: a consensus report of the International Kidney and Monoclonal Gammopathy Research Group. *Nat Rev Nephrol*. 2019 Jan;15(1):45–59.
- 17 Requisti per la biopsia renale: diagnostica nefropatologica ed esecuzione clinica · Nephromeet [Internet]. [cited 2022 Apr 21]. Available from: <http://neuro.it/web/procedure/protocollo.cfm?List=WsIdEvento,WsPageNameCaller,WsIdRisposta,WsRelease&c1=00226&c2=%2Fweb%2Feventi%2FNEP HROMEET%2Findex%2Ecfm&c3=1&c4=1>.
- 18 L'Imperio V, Brambilla V, Cazzaniga G, Ferrario F, Nebuloni M, Pagni F. Digital pathology for the routine diagnosis of renal diseases: a standard model. *J Nephrol*. 2021;34(3):681–8.
- 19 Gonzalez Suarez ML, Zhang P, Nasr SH, Sathick IJ, Kittanamongkolchai W, Kurtin PJ, et al. The sensitivity and specificity of the routine kidney biopsy immunofluorescence panel are inferior to diagnosing renal immunoglobulin-derived amyloidosis by mass spectrometry. *Kidney Int*. 2019 Oct;96(4):1005–9.
- 20 Sirac C, Bridoux F. Mesangial cells as amyloid factory: a unique contribution of animal models. *Kidney Int*. 2014 Oct;86(4):669–71.

Conflict of Interest Statement

The authors do not have any conflict of interest to declare.

Funding Sources

This research received no external funding.

Author Contributions

Vincenzo L'Imperio devised the project, the main conceptual ideas, and proof outline; Giorgio Cazzaniga performed the review of the literature; Barbara Vergani provided a contribution on the electron microscopy details and perspective; Andrew James Smith and Federico Alberici contributed to the “future perspective” section; Vincenzo L'Imperio and Fabio Pagni critically revised the paper and provided the final version of the work; all the authors read and approved the submitted manuscript.

- 21 Ying W-Z, Allen CE, Curtis LM, Aaron KJ, Sanders PW. Mechanism and prevention of acute kidney injury from cast nephropathy in a rodent model. *J Clin Invest*. 2012 May; 122(5):1777–85.
- 22 Decourt C, Rocca A, Bridoux F, Vrtovsnik F, Preud'homme JL, Cogné M, et al. Mutational analysis in murine models for myeloma-associated Fanconi's syndrome or cast myeloma nephropathy. *Blood*. 1999;94(10):3559–66.
- 23 Teng J, Turbat-Herrera EA, Herrera GA. An animal model of glomerular light-chain-associated amyloidogenesis depicts the crucial role of lysosomes. *Kidney Int*. 2014 Oct;86(4): 738–46.
- 24 Bellotti V, Mangione P, Merlini G. Review: immunoglobulin light chain amyloidosis: the archetype of structural and pathogenic variability. *J Struct Biol*. 2000 Jun;130(2–3):280–9.
- 25 Dasari S, Theis JD, Vrana JA, Rech KL, Dao LN, Howard MT, et al. Amyloid typing by mass spectrometry in clinical practice: a comprehensive review of 16,175 samples. *Mayo Clin Proc*. 2020 Sep;95(9):1852–64.
- 26 Dasari S, Alexander MP, Vrana JA, Theis JD, Mills JR, Negron V, et al. DnaJ Heat Shock protein family B member 9 is a novel biomarker for fibrillary GN. *J Am Soc Nephrol*. 2018 Jan;29(1):51–6.
- 27 Nasr SH, Vrana JA, Dasari S, Bridoux F, Fidler ME, Kaaki S, et al. DNAJB9 is a specific immunohistochemical marker for fibrillary glomerulonephritis. *Kidney Int Rep*. 2018 Jan; 3(1):56–64.
- 28 Nasr SH, Sirac C, Bridoux F, Javaugue V, Bender S, Rinsant A, et al. Heavy chain fibrillary glomerulonephritis: a case report. *Am J Kidney Dis*. 2019;74(2):276–80.
- 29 Said SM, Leung N, Alexander MP, Cornell LD, Fidler ME, Grande JP, et al. DNAJB9-positive monotypic fibrillary glomerulonephritis is not associated with monoclonal gammopathy in the vast majority of patients. *Kidney Int*. 2020;98(2):498–504.
- 30 Kudose S, Canetta P, Andeen NK, Stokes MB, Batal I, Markowitz GS, et al. Diagnostic approach to glomerulonephritis with fibrillar IgG deposits and light chain restriction. *Kidney Int Rep*. 2021 Apr;6(4):936–45.
- 31 L'Imperio V, Barreca A, Vergani B, Sinico RA, Pagni F. Destructuring glomerular diseases with structured deposits: challenges in the precision medicine era. *J Nephrol*. 2021; 34(6):2151–4.
- 32 Erickson SB, Zand L, Nasr SH, Alexander MP, Leung N, Drosou ME, et al. Treatment of fibrillary glomerulonephritis with rituximab: a 12-month pilot study. *Nephrol Dial Transpl*. 2021 Jan;36(1):104–10.
- 33 Bridoux F, Hugué V, Coldefy O, Goujon J-M, Bauwens M, Sechet A, et al. Fibrillary glomerulonephritis and immunotactoid (microtubular) glomerulopathy are associated with distinct immunologic features. *Kidney Int*. 2002 Nov;62(5):1764–75.
- 34 Nasr SH, Fidler ME, Cornell LD, Leung N, Cosio FG, Sheikh SS, et al. Immunotactoid glomerulopathy: clinicopathologic and proteomic study. *Nephrol Dial Transpl*. 2012 Nov;27(11):4137–46.
- 35 Javaugue V, Dufour-Nourigat L, Desport E, Sibille A, Moulin B, Bataille P, et al. Results of a nation-wide cohort study suggest favorable long-term outcomes of clone-targeted chemotherapy in immunotactoid glomerulopathy. *Kidney Int*. 2021 Feb;99(2):421–30.
- 36 Lokhorst HM, Plesner T, Laubach JP, Nahi H, Gimsing P, Hansson M, et al. Targeting CD38 with daratumumab monotherapy in multiple myeloma. *N Engl J Med*. 2015;373(13):1207–19.
- 37 Pozzi C, D'Amico M, Fogazzi GB, Curioni S, Ferrario F, Pasquali S, et al. Light chain deposition disease with renal involvement: clinical characteristics and prognostic factors. *Am J Kidney Dis*. 2003 Dec;42(6):1154–63.
- 38 Nasr SH, Valeri AM, Cornell LD, Fidler ME, Sethi S, D'Agati VD, et al. Renal monoclonal immunoglobulin deposition disease: a report of 64 patients from a single institution. *Clin J Am Soc Nephrol*. 2012 Feb;7(2):231–9.
- 39 Bridoux F, Leung N, Hutchison CA, Touchard G, Sethi S, Ferman J-P, et al. Diagnosis of monoclonal gammopathy of renal significance. *Kidney Int*. 2015 Apr;87(4):698–711.
- 40 Ronco PM, Alyanakian M-A, Mougénot B, Aucouturier P. Light chain deposition disease: a model of glomerulosclerosis defined at the molecular level. *J Am Soc Nephrol*. 2001; 12(7):1558–65.
- 41 Denoroy L, Déret S, Aucouturier P. Overrepresentation of the V κ IV subgroup in light chain deposition disease. *Immunol Lett*. 1994; 42(1–2):63–6.
- 42 Vidal R, Gofii F, Stevens F, Aucouturier P, Kumar A, Frangione B, et al. Somatic mutations of the L12a gene in V- κ 1 light chain deposition disease: potential effects on aberrant protein conformation and deposition. *Am J Pathol*. 1999;155(6):2009–17.
- 43 Kaplan B, Livneh A, Gallo G. Charge differences between in vivo deposits in immunoglobulin light chain amyloidosis and non-amyloid light chain deposition disease. *Br J Haematol*. 2007 Mar;136(5):723–8.
- 44 Bridoux F, Javaugue V, Bender S, Leroy F, Aucouturier P, Debais-Delpech C, et al. Unravelling the immunopathological mechanisms of heavy chain deposition disease with implications for clinical management. *Kidney Int*. 2017 Feb;91(2):423–34.
- 45 Bonaud A, Bender S, Touchard G, Lacombe C, Srour N, Delpy L, et al. A mouse model recapitulating human monoclonal heavy chain deposition disease evidences the relevance of proteasome inhibitor therapy. *Blood*. 2015 Aug;126(6):757–65.
- 46 Jain D, Green JA, Bastacky S, Theis JD, Sethi S. Membranoproliferative glomerulonephritis: the role for laser microdissection and mass spectrometry. *Am J Kidney Dis*. 2014;63(2): 324–8.
- 47 Kasagi T, Nobata H, Suzuki K, Miura N, Banno S, Takami A, et al. Light chain deposition disease diagnosed with laser micro-dissection, liquid chromatography, and tandem mass spectrometry of nodular glomerular lesions. *Intern Med*. 2017 Jan;56(1):61–6.
- 48 Royal V, Quint P, Leblanc M, LeBlanc R, Duncanson GF, Perrizo RL, et al. IgD heavy-chain deposition disease: detection by laser microdissection and mass spectrometry. *J Am Soc Nephrol*. 2015;26(4):784–90.
- 49 Vidarsson G, Dekkers G, Rispens T. IgG subclasses and allotypes: from structure to effector functions. *Front Immunol*. 2014 Oct;5: 520.
- 50 Rengers JU, Touchard G, Decourt C, Deret S, Michel H, Cogné M. Heavy and light chain primary structures control IgG3 nephritogenicity in an experimental model for cryoglobulinemia. *Blood*. 2000;95(11):3467–72.
- 51 Sirac C, Herrera GA, Sanders PW, Batuman V, Bender S, Ayala MV, et al. Animal models of monoclonal immunoglobulin-related renal diseases. *Nat Rev Nephrol*. 2018 Apr;14(4): 246–64.
- 52 Nasr SH, Larsen CP, Sirac C, Theis JD, Domenger C, Chauvet S, et al. Light chain only variant of proliferative glomerulonephritis with monoclonal immunoglobulin deposits is associated with a high detection rate of the pathogenic plasma cell clone. *Kidney Int*. 2020 Mar;97(3):589–601.
- 53 Vignon M, Cohen C, Faguer S, Noel L-H, Guilbeau C, Rabant M, et al. The clinicopathologic characteristics of kidney diseases related to monotypic IgA deposits. *Kidney Int*. 2017 Mar;91(3):720–8.
- 54 Markowitz GS. Dysproteinemia and the kidney. *Adv Anat Pathol*. 2004 Jan;11(1):49–63.
- 55 Abraham RS, Geyer SM, Price-Troska TL, Allmer C, Kyle RA, Gertz MA, et al. Immunoglobulin light chain variable (V) region genes influence clinical presentation and outcome in light chain-associated amyloidosis (AL). *Blood*. 2003 May;101(10):3801–8.
- 56 Enqvist S, Sletten K, Westermark P. Fibril protein fragmentation pattern in systemic AL-amyloidosis. *J Pathol*. 2009;219(4):473–80.
- 57 Nasr SH, Said SM, Valeri AM, Sethi S, Fidler ME, Cornell LD, et al. The diagnosis and characteristics of renal heavy-chain and heavy/light-chain amyloidosis and their comparison with renal light-chain amyloidosis. *Kidney Int*. 2013;83(3):463–70.
- 58 Popkova T, Hajek R, Jelinek T. Monoclonal antibodies in the treatment of AL amyloidosis: co-targeting the plasma cell clone and amyloid deposits. *Br J Haematol*. 2020 Apr; 189(2):228–38.
- 59 Best Rocha A, Larsen CP. Membranous glomerulopathy with light chain-restricted deposits: a clinicopathological analysis of 28 cases. *Kidney Int Rep*. 2017 Nov;2(6):1141–8.

- 60 Larsen CP, Sharma SG, Caza TN, Kenan DJ, Storey AJ, Edmondson RD, et al. Serum amyloid P deposition is a sensitive and specific feature of membranous-like glomerulopathy with masked IgG kappa deposits. *Kidney Int.* 2020 Mar;97(3):602–8.
- 61 Coley SM, Shirazian S, Radhakrishnan J, D'Agati VD. Monoclonal IgG1κ anti-glomerular basement membrane disease: a case report. *Am J Kidney Dis.* 2015 Feb;65(2):322–6.
- 62 Grabar P, Williams CA. Method permitting the combined study of the electrophoretic and the immunochemical properties of protein mixtures; application to blood serum. *Biochim Biophys Acta.* 1953 Jan;10(1):193–4.
- 63 Kyle R, Therneau T, Dispenzieri A, Larson D, Plevak M, Melton LJ, et al. Idiopathic bence jones proteinuria: clinical course and prognosis. *Blood.* 2006;108(11):3493.
- 64 L'Imperio V, Fabbrini P, Ferrario F, Pieruzzi F, Tosoni A, Brivio R, et al. Monoclonal gammopathy of renal significance: systemic involvement by benign condition. *Kidney Int.* 2015;88(1):200–2.
- 65 Stevens FJ, Solomon A, Schiffer M. Bence Jones proteins: a powerful tool for the fundamental study of protein chemistry and pathophysiology. *Biochemistry.* 1991 Jul;30(28):6803–5.
- 66 Schieferdecker A, Hörber S, Ums M, Besemer B, Bokemeyer C, Peter A, et al. Comparison of three different serum-free light-chain assays-implications on diagnostic and therapeutic monitoring of multiple myeloma. *Blood Cancer J.* 2020 Jan;10(1):2.
- 67 Sharpley FA, Manwani R, Mahmood S, Sachchithanatham S, Lachmann HJ, Gillmore JD, et al. A novel mass spectrometry method to identify the serum monoclonal light chain component and infer organ involvement in systemic light chain amyloidosis. *Blood.* 2018;132(Suppl 1):4445.
- 68 Muchtar E, Gertz MA, Lacy MQ, Leung N, Buadi FK, Dingli D, et al. Refining amyloid complete hematological response: quantitative serum free light chains superior to ratio. *Am J Hematol.* 2020 Nov;95(11):1280–7.
- 69 Ramirez-Alvarado M, Barnidge DR, Murray DL, Dispenzieri A, Marin-Argany M, Dick CJ, et al. Assessment of renal response with urinary exosomes in patients with AL amyloidosis: a proof of concept. *Am J Hematol.* 2017 Jun;92(6):536–41.
- 70 Ramirez-Alvarado M, Ward CJ, Huang BQ, Gong X, Hogan MC, Madden BJ, et al. Differences in immunoglobulin light chain species found in urinary exosomes in light chain amyloidosis (AL). *PLoS One.* 2012;7(6):e38061.
- 71 Ramirez-Alvarado M, Ward CJ, Huang BQ, Gong X, Hogan MC, Madden BJ, et al. Detection of high molecular weight light chain oligomers in urinary exosomes of patients with AL amyloidosis. *Blood.* 2009;114(22):4886.
- 72 Solomon A, Weiss DT, Kattine AA. Nephrotoxic potential of bence jones proteins. *N Engl J Med.* 1991 Jun;324(26):1845–51.
- 73 Luciani A, Sirac C, Terryn S, Javaugue V, Prange JA, Bender S, et al. Impaired lysosomal function underlies monoclonal light chain-associated renal Fanconi syndrome. *J Am Soc Nephrol.* 2016 Jul;27(7):2049–61.
- 74 L'Imperio V, Morello G, Vegliante MC, Cancila V, Bertolazzi G, Mazzara S, et al. Spatial transcriptome of a germinal center plasmablastic burst hints at MYD88/CD79B mutants-enriched diffuse large B-cell lymphomas. *Eur J Immunol.* 2022 May;52(8):1350–61.
- 75 Ye L, Liu Y, Zhu X, Duan T, Wang C, Fu X, et al. Digital spatial profiling of individual glomeruli from patients with anti-neutrophil cytoplasmic autoantibody-associated glomerulonephritis. *Front Immunol.* 2022 Mar;13:831253.
- 76 Salem F, Perin L, Sedrakyan S, Angeletti A, Ghiggeri GM, Coccia MC, et al. The spatially resolved transcriptional profile of acute T cell-mediated rejection in a kidney allograft. *Kidney Int.* 2022 Jan;101(1):131–6.
- 77 Dixon EE, Wu H, Muto Y, Wilson PC, Humphreys BD. Spatially resolved transcriptomic analysis of acute kidney injury in a female murine model. *J Am Soc Nephrol.* 2022;33(2):279–89.
- 78 Melo Ferreira R, Sabo AR, Winfree S, Collins KS, Janosevic D, Gulbranson CJ, et al. Integration of spatial and single-cell transcriptomics localizes epithelial cell-immune crosstalk in kidney injury. *JCI Insight.* 2021 Jun;6(12):e147703.
- 79 Marshall JL, Noel T, Wang QS, Chen H, Murray E, Subramanian A, et al. High-resolution Slide-seqV2 spatial transcriptomics enables discovery of disease-specific cell neighborhoods and pathways. *iScience.* 2022 Apr;25(4):104097.
- 80 Smith A, L'Imperio V, De Sio G, Ferrario F, Scalia C, Dell'Antonio G, et al. α-1-Antitrypsin detected by MALDI imaging in the study of glomerulonephritis: its relevance in chronic kidney disease progression. *Proteomics.* 2016;16(11–12):1759–66.
- 81 L'Imperio V, Smith A, Ajello E, Piga I, Stella M, Denti V, et al. MALDI-MSI pilot study highlights glomerular deposits of macrophage migration inhibitory factor as a possible indicator of response to therapy in membranous nephropathy. *Proteomics Clin Appl.* 2019 May;13(3):e1800019.
- 82 Smith A, L'Imperio V, Ajello E, Ferrario F, Mosele N, Stella M, et al. The putative role of MALDI-MSI in the study of Membranous Nephropathy. *Biochim Biophys Acta Proteins Proteom.* 2017;1865(7):865–74.
- 83 L'Imperio V, Smith A, Chinello C, Pagni F, Magni F. Proteomics and glomerulonephritis: a complementary approach in renal pathology for the identification of chronic kidney disease related markers. *Proteomics Clin Appl.* 2016;10(4):371–83.
- 84 Rossi F, L'Imperio V, Marti H-P, Svarstad E, Smith A, Bolognesi MM, et al. Proteomics for the study of new biomarkers in Fabry disease: state of the art. *Mol Genet Metab.* 2021;132(2):86–93.
- 85 Smith A, L'Imperio V, Denti V, Mazza M, Ivanova M, Stella M, et al. High spatial resolution MALDI-MS imaging in the study of membranous nephropathy. *Proteomics Clin Appl.* 2019;13(1):e1800016.
- 86 Smith A, Galli M, L'Imperio V, Pagni F, Magni F. MALDI-MS imaging in the study of glomerulonephritis. *Methods Mol Biol.* 2017;1618:85–94.
- 87 L'Imperio V, Smith A, Pisani A, D'Armiento M, Scollo V, Casano S, et al. MALDI imaging in Fabry nephropathy: a multicenter study. *J Nephrol.* 2020;33(2):299–306.
- 88 Winter M, Tholey A, Kristen A, Röcken C. MALDI mass spectrometry imaging: a novel tool for the identification and classification of amyloidosis. *Proteomics.* 2017 Nov;17(22):1700236.
- 89 Casadonte R, Kriegsmann M, Deininger S-O, Amann K, Paape R, Belau E, et al. Imaging mass spectrometry analysis of renal amyloidosis biopsies reveals protein co-localization with amyloid deposits. *Anal Bioanal Chem.* 2015 Jul;407(18):5323–31.
- 90 Lavatelli F, Merlini G. Proteomics with mass spectrometry imaging: beyond amyloid typing. *Proteomics.* 2018;18(7):e1700353.