

# Parkinsonism management issues in a patient with exhausted subthalamic deep brain stimulation battery, stricken by severe acute respiratory syndrome coronavirus 2

Received: 19 May 2020  
Accepted: 27 July 2020

Seyed Amir Hassan Habibi<sup>1</sup>, Luigi Romito<sup>2</sup>, Oldooz Aloosh<sup>3</sup>, Mohammad Rohani<sup>1</sup>, Fatemeh Moghadas<sup>1</sup>, Mansour Parvaresh<sup>4</sup>, Gholamali Shahidi<sup>5</sup>, Mehdi Moghaddasi<sup>1</sup>, Ehsan Ziayi<sup>4</sup>, Maziar Emamikhah<sup>1</sup>

<sup>1</sup> Department of Neurology, Rasool-e Akram Hospital, Iran University of Medical Sciences, Tehran, Iran

<sup>2</sup> Department of Clinical Neurosciences, Movement Disorders Unit, Fondazione IRCCS Istituto Neurologico Carlo Besta, Milan, Italy

<sup>3</sup> Department of Internal Medicine, Rasool-e Akram Hospital, Iran University of Medical Sciences, Tehran, Iran

<sup>4</sup> Department of Neurosurgery, Rasool-e Akram Hospital, Iran University of Medical Sciences, Tehran, Iran

<sup>5</sup> Department of Neurology, Firoozgar Hospital, Iran University of Medical Sciences, Tehran, Iran

## Keywords

Deep Brain Stimulation; Case Management; Parkinson Disease; Severe Acute Respiratory Syndrome Coronavirus 2; Subthalamic Nucleus

## Abstract

**Background:** Nowadays, many neurological conditions, including Parkinson's disease (PD), are treated with deep brain stimulation (DBS). Life-threatening consequences can occur from DBS hardware failure or sudden implantable pulse generator (IPG) battery depletion. This issue may potentially worsen in concomitance with medical or infectious conditions, requiring stronger emergency management.

**Methods:** We present here a 58 year-old PD patient with DBS, whose IPG replacement surgery was complicated by severe acute respiratory syndrome

coronavirus 2 (SARS-CoV-2) infection and we report management of this patient along with recommendations for patients with similar situation.

**Results:** As the newly-emerged coronavirus disease 2019 (COVID-19) is now announced to be pandemic, new protocols and specific measures for each individual group of patients with chronic diseases seem obligatory. Regarding our recent experience with a patient suffering from PD, on DBS treatment, who needed hospitalization, we felt useful to share

**How to cite this article:** Habibi SAH, Romito L, Aloosh O, Rohani M, Moghadas F, Parvaresh M, et al. Parkinsonism management issues in a patient with exhausted subthalamic deep brain stimulation battery, stricken by severe acute respiratory syndrome coronavirus 2. Curr J Neurol 2020; 19(4): 211-4.

our experience as a recommended protocol for similar patients in the time of current pandemic.

**Conclusion:** Close monitoring of laboratory and clinical signs should be warranted in patients with PD awaiting IPG replacement in order to be prepared in these novel conditions that may precipitate an akinetic crisis/dystonic storm and to prevent life-threatening complications during the current pandemic.

### Introduction

Deep brain stimulation (DBS) has greatly expanded the treatment of off and on manifestations in selected patients with Parkinson's disease (PD). However, an increasing number of life-threatening conditions arising from DBS hardware failure or sudden or unexpected implantable pulse generator (IPG) battery depletion/exhaustion have been reported.<sup>1-3</sup> These issues may potentially worsen in concomitance with medical or infectious conditions, requiring stronger emergency management.

We report here a patient with PD with worsening of severe akinesia and tremor, associated with subthalamic nucleus DBS (STN-DBS) IPG battery depletion, who presented with further neurological worsening due to the impossibility to replace IPG after developing severe acute respiratory syndrome coronavirus 2 (SARS-CoV-2) infection.<sup>4</sup>

### Materials and Methods

We report herein a 58-year-old man who received a diagnosis of akinetic-rigid PD in 2006 and his symptoms were adequately controlled with medical management up to 2012. In 2014, he underwent a bilateral STN-DBS using an IPG model Activa PC (Medtronic, Minneapolis, Minnesota, USA) connected to leads model 3389. No adverse events occurred during or after surgery. Before the surgery, he was suffering from motor fluctuations, with wearing-off and no-on phenomena; off was characterized by severe rigidity and akinesia [Unified Parkinson's Disease Rating Scale (UPDRS-III) = 78/108, Hoehn and Yahr stage = 4]. He was treated with levodopa every three hours and pramipexole every 8 hours during the waking time with a total levodopa equivalent daily dosage (LEDD) of 1052 mg/day. On medication, patient's motor symptoms were dramatically improved (UPDRS-III = 38/108, Hoehn and Yahr stage = 3) but complicated by severe peak-dose dyskinesias.

### Results

STN-DBS allowed an excellent and prolonged

improvement of parkinsonism. The patient was stable and functional during serial outpatient visits and his on-medication and on-stimulation UPDRS-III was 17/108 and Yahr stage = 2, at 5-year post-DBS follow-up (FU) visit on January 2019. He was then treated with levodopa every four hours during the day with a LEDD of 400 mg/day. Upon the last two FU visits, the remaining voltage suggested the need for IPG replacement and even emergent replacement was expected to be encountered shortly, but unfortunately, there was IPG device shortage due to several political-economic obstacles. DBS parameters in the last FU visit are listed in table 1. On February 2020, the patient was admitted to our hospital because of an abrupt worsening of parkinsonism, with severe rigidity, bradykinesia, and dysphagia. His IPG had reached "end-of-life" status and an urgent IPG replacement was planned. His on-medication and off-stimulation UPDRS-III score was 34/108. Unfortunately, it took us about three weeks to prepare the battery due to local device shortage. During this period, the patient was closely monitored through performing serial neurological examinations and repeated serum creatine phosphokinase (CPK) levels, to capture any early sign of malignant STN-DBS withdrawal syndrome.<sup>1</sup> Antiparkinsonian therapy was increased to levodopa every three hours during the day with a LEDD of 1000 mg/day.

**Table 1.** Deep brain stimulation (DBS) parameters at last follow-up visit before implantable pulse generator (IPG) depletion

Parameters	Left side	Right side
Negative contact (case positive)	11.0	3.0
Voltage (mV)	2.9	3.2
Pulse width ( $\mu$ s)	60.0	60.0
Frequency (Hz)	130.0	130.0

On 29 February 2020, the patient was admitted to our hospital to undergo IPG replacement surgery. On examination, he presented fully alert and oriented, with a severe akinetic-rigid parkinsonism (on-med UPDRS-III of 37/108); his vital signs were unremarkable, and he had no complaints of fever, cough, respiratory distress, or diarrhea. No evidence of leukopenia or thrombocytopenia was detected in laboratory tests. C-reactive protein (CRP) was 24 and other laboratory tests, including serum creatinine level, CPK, liver function tests, and lactate

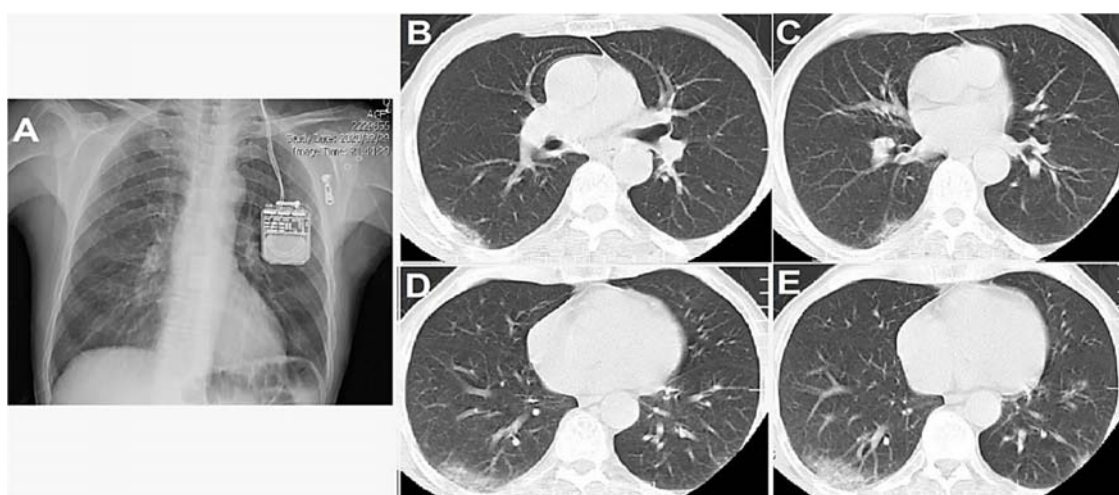
dehydrogenase (LDH) were normal.

However, we adopted a precautionary approach in evaluating this patient, due to the consideration that he came from Qom City, Iran, the site of the first Iranian case of novel coronavirus disease 2019 (COVID-19). Therefore, a spiral chest computed tomography (CT) scan was performed that showed multiple ground-glass infiltrates in peripheral zones of right and left lower lobes (Figure 1). On the following day, the patient developed fever (axillary temperature of 38 °C) and cough. We immediately activated the isolation precautions and an infectious disease specialist was consulted. The real-time polymerase chain reaction (RT-PCR) test on patient's throat specimen was positive for COVID-19. A combined treatment was instituted with oral Kaletra (ritonavir + lopinavir), oseltamivir, hydroxychloroquine, and also intravenous (IV) levofloxacin and vancomycin. One week later, he was discharged to be home-quarantined. He had stable vital signs, improved respiratory performance, and improved parkinsonism severity after increasing levodopa to a LEDD of 1400 mg/day. We decided to postpone the IPG replacement surgery until full recovery and continue close monitoring for signs of malignant STN-DBS withdrawal syndrome. No worsening of levodopa-associated adverse effects, including dyskinesia, was noticed.

### Discussion

Our observation since the early surge of cases of COVID-19 in Iran suggests that patients with PD

treated or not with DBS may present few or no worsening of motor symptoms even following COVID-19 infection, though some preliminary reports have indicated a strong neuroinvasive potential of the SARS-CoV-2.<sup>5</sup> However, we recommend enforcing pre-operative evaluation (i.e., chest CT scan, questionnaire about potential exposure to patients with SARS-CoV-2) before any surgical procedure on patients with PD, comprising IPG replacement, in order to halt unwanted and avoidable potential complications. Various factors in the time of pandemics complicate the urgent surgeries, especially the ones that require special devices such as IPG. The lockdown and restrictions both in the community and health care system make such patients susceptible to gaining access to treatments they need with considerable delay.<sup>6</sup> On the other hand, there is the issue of limited resources in the current situation; for example, the hospital beds with isolation settings, number of surgeries per facility with respiratory precautions, device supply rate (in this case IPG), and many other factors force the urgent IPG replacement surgeries (and other similar procedures) to be slowed or even interrupted. In the case of our patient, the economic and political issues regarding the sanctions at that time made the in time IPG availability much more complicated. In these circumstances, one should prevent the development of potentially life-threatening conditions such as DBS withdrawal syndrome, acute dystonic crisis, and the return of disabling tremor.<sup>1-3,6</sup>



**Figure 1.** Spiral chest computed tomography (CT) scan of the patient in scout (A) and axial (B-E) views showing multiple peripheral ground-glass opacities (GGOs) in peripheral zones of right and left lower lobes

## Conclusion

Close monitoring of laboratory and clinical signs should be warranted in patients with PD awaiting IPG replacement in order to be prepared in these novel conditions that may precipitate an akinetic crisis/dystonic storm and to prevent life-threatening complications during the current pandemic. Treating teams should be aware of the possible deterioration of parkinsonism in PD patients with initially asymptomatic SARS-CoV-2 infection, because this might result in potentially fatal outcomes. The risk factors making patients with PD vulnerable to COVID-19 infection and its associated complications are not fully understood, but it seems that appropriate medical treatment is a possible factor playing a part in better outcome

## References

1. Cossu G, Sensi M. Deep brain stimulation emergencies: How the new technologies could modify the current scenario. *Curr Neurol Neurosci Rep* 2017; 17(7): 51.
2. Hamed M, Ba F, Suhowersky O, Sankar T. Depleting implanted pulse generator (IPG) battery voltage is associated with worsening clinical symptoms in movement disorder patients receiving deep brain stimulation (DBS). *Clinical Parkinsonism and Related Disorders* 2019; 1: 98-9.
3. Hariz MI, Johansson F. Hardware failure in parkinsonian patients with chronic subthalamic nucleus stimulation is a medical emergency. *Mov Disord* 2001; 16(1): 166-8.
4. Zhu N, Zhang D, Wang W, Li X, Yang B, Song J, et al. A novel coronavirus from patients with pneumonia in China, 2019. *N Engl J Med* 2020; 382(8): 727-33.
5. Li YC, Bai WZ, Hashikawa T. The neuroinvasive potential of SARS-CoV2 may play a role in the respiratory failure of COVID-19 patients. *J Med Virol* 2020; 92(6): 552-5.
6. Holla VV, Neeraja K, Suriseti BK, Prasad S, Kamble N, Srinivas D, et al. Deep brain stimulation battery exhaustion during the COVID-19 pandemic: Crisis within a crisis. *J Mov Disord* 2020; 13(3): 218-22.
7. Fasano A, Elia AE, Dallochio C, Canesi M, Alimonti D, Sorbera C, et al. Predictors of COVID-19 outcome in Parkinson's disease. *Parkinsonism Relat Disord* 2020; 78: 134-7.

in the environment surrounded by COVID-19 risks.<sup>7</sup> It is unquestionably the case for DBS patients in the waiting list of surgery, whose IPG is about to die.

## Conflict of Interests

The authors declare no conflict of interest in this study.

## Acknowledgments

We acknowledge all the medical staff who are risking their lives, and hundreds of them who died in the time of current pandemic.

This research did not receive any specific grant from funding agencies in the public, commercial, or not-for-profit sectors.