

# A Case of Rectal Squamous Cell Carcinoma with Metachronous Diffuse Large B Cell Lymphoma in an HIV-Infected Patient

Heun Choi<sup>1</sup>, Hye Won Lee<sup>1</sup>, Hea Won Ann<sup>1</sup>, Jae Kyung Kim<sup>1</sup>, Hua Pyong Kang<sup>1</sup>, Sun Wook Kim<sup>1</sup>, Nam Su Ku<sup>1,2</sup>, Sang Hoon Han<sup>1,2</sup>, June Myung Kim<sup>1,2</sup>, and Jun Yong Choi<sup>1,2</sup>

<sup>1</sup>Department of Internal Medicine, and <sup>2</sup>AIDS Research Institute, Yonsei University College of Medicine, Seoul, Korea

Diffuse large B cell lymphoma (DLBCL) is one of the most common acquired immune deficiency syndrome (AIDS)-defining malignancies among human immunodeficiency virus -infected patients, and rectal cancer has recently emerged as a prevalent non-AIDS-defining malignancy. We report a case of rectal squamous cell carcinoma that was metachronous with DLBCL in an HIV-infected patient who was receiving highly active antiretroviral therapy. The patient was diagnosed with DLBCL and showed complete remission after chemotherapy. Follow-up imaging showed increased uptake at the rectum, previously treated as lymphoma. Repeated biopsy was performed and squamous cell carcinoma of the rectum was reported. After concurrent chemoradiation therapy, curative resection was performed.

**Key Words:** HIV; AIDS-related lymphoma; Squamous cell carcinoma; Oncogenic viruses

## Introduction

Human immunodeficiency virus (HIV) infection can cause defects in cell-mediated immunity, and these defects increase the incidence of various malignancies [1]. Acquired immune deficiency syndrome (AIDS)-defining malignancies include Kaposi's sarcoma, non-Hodgkin's lymphoma, primary central nervous system lymphoma, and invasive cervical cancer [2]. Highly active antiretroviral therapy (HAART) has led to a dramatic decrease in AIDS-related mortality as well as the inci-

dence of opportunistic infections and AIDS-defining malignancies [3]. However, many cancers not previously identified as AIDS-defining malignancies are now emerging as important causes of death in persons living with HIV [4-6]. Such non-AIDS-defining malignancies include anal, liver, skin, and other cancers.

The mechanisms underlying increased cancer risk are not completely understood. An increased prevalence of oncogenic viral coinfection can explain the higher incidence of particular cancers such as liver, cervical, and anal cancer, as well as

**Received:** July 25, 2013 **Revised:** September 17, 2013 **Accepted:** October 16, 2013

**Corresponding Author :** Jun Yong Choi, MD, PhD

Department of Internal Medicine, Yonsei University College of Medicine,

50 Yonsei-ro, Seodaemun-gu, Seoul 120-752, Korea

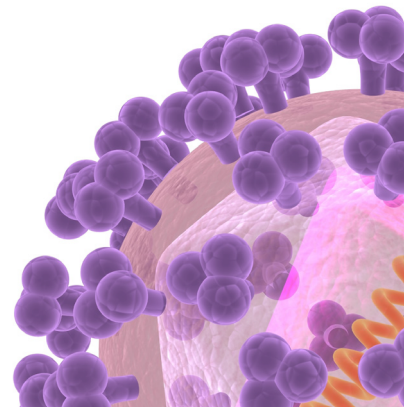
Tel: +82-2-2228-1974, Fax: +82-2-393-6884

E-mail: seran@yuhs.ac

This is an Open Access article distributed under the terms of the Creative Commons Attribution Non-Commercial License (<http://creativecommons.org/licenses/by-nc/3.0>) which permits unrestricted non-commercial use, distribution, and reproduction in any medium, provided the original work is properly cited.

Copyrights © 2014 by The Korean Society of Infectious Diseases | Korean Society for Chemotherapy

[www.icjournal.org](http://www.icjournal.org)



non-Hodgkin's lymphoma.

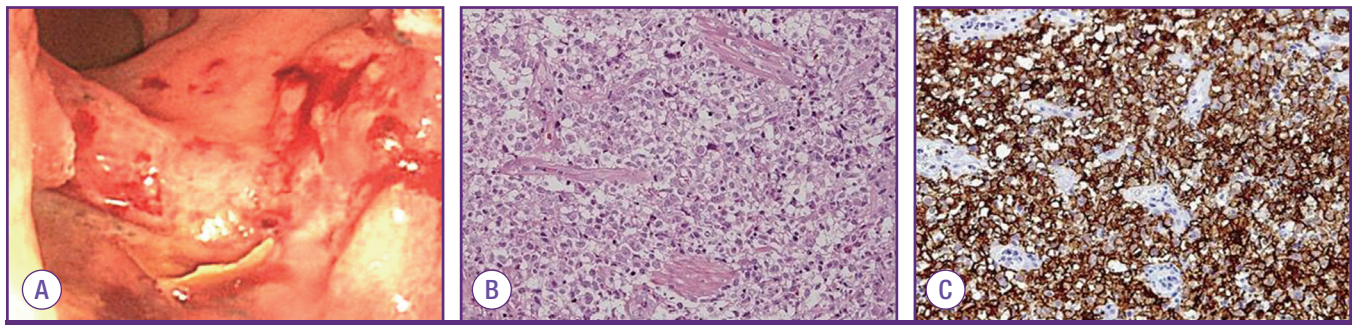
In South Korea, there are no clear patterns in the relative increase of non-AIDS-defining malignancies and the reduction of AIDS-defining malignancies after HAART [7, 8]. Non-Hodgkin's lymphoma is most frequently observed in AIDS-defining malignancies, and gastrointestinal malignancies are common among non-AIDS-defining malignancies [8]. Although men who have sex with men (MSM) are at highest risk for HIV acquisition in South Korea, the anal cancers associated with HPV infection are rarely reported. The concurrence of non-Hodgkin's lymphoma and squamous cell carcinoma in the rectum in HIV-infected MSM has not been reported yet.

We report a case of rectal squamous cell carcinoma that occurred with metachronous diffuse large B cell lymphoma in an HIV-infected MSM.

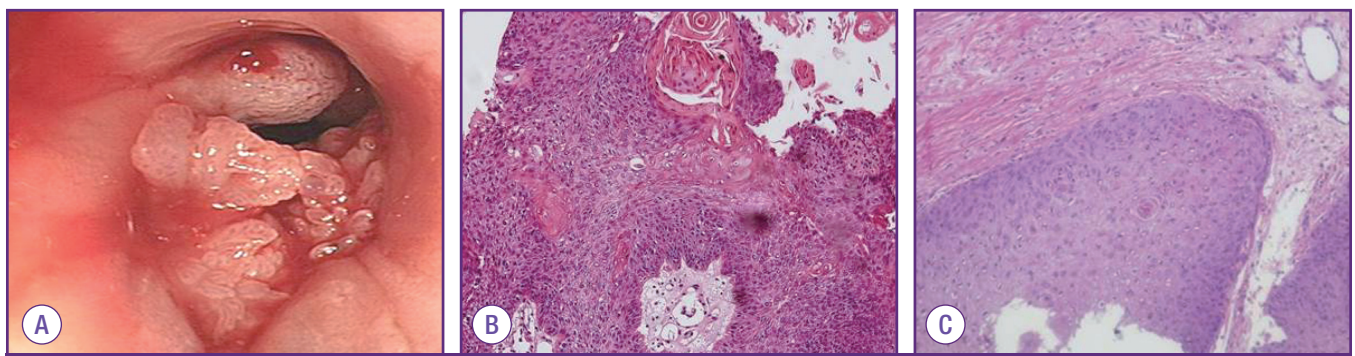
## Case Report

A 51-year-old homosexual male with 10-year history of HIV infection presented to the emergency department with complaints of repeated bloody stool (three instances). He had received HAART, but his HAART treatment regimen had to be

altered several times due to adverse events, poor adherence and virologic failure. He was taking lamivudine, stavudine, lopinavir-ritonavir and abacavir at the time of admission. He had no history of opportunistic infections since his diagnosis in 1997. He denied any symptoms, including fevers, chills, night sweats or weight loss, except hematochezia. On physical examination, the abdomen was soft and there were no palpable masses or tenderness. He had a notable mass on digital rectal examination. His CD4+ T cell count was  $116/\text{mm}^3$ , and his HIV viral load was 2,730 copies/mL. Epstein Barr virus (EBV) polymerase chain reaction (PCR) showed 27,750 copies/mL. Sigmoidoscopy demonstrated a 75% circumferential ulceroinfiltrative lesion in the rectum and a biopsy was performed (Fig. 1A). Pathologic diagnosis was diffuse large B-cell lymphoma with CD20 (+), CD3 (-), cytokeratin (-), and Ki-67 (90%) (Fig. 1B and C). The staging work-up including a bone marrow study revealed lymphoma of the anorectum, nasopharynx, upper neck lymph node, and bone marrow with Ann Arbor stage IV in July 2007. Chemotherapy was initiated with a regimen of rituximab combined with etoposide, vincristine, doxorubicin, cyclophosphamide, and prednisone for 4 cycles, and vincristine, doxorubicin, cyclophosphamide, and for 2 cycles. The patient achieved complete remission in February 2008.



**Figure 1.** (A) 75% circumferential ulceroinfiltrative lesion in the rectum. (B) H&E stain ( $\times 400$ ): Diffuse large B-cell lymphoma. (C) Immunohistochemical stain: CD 20 positive.



**Figure 2.** (A) Ulcerative polypoid lesion in the rectum. (B) H&E stain ( $\times 200$ ): Squamous epithelial dysplasia, high grade. (C) H&E stain ( $\times 400$ ): Squamous cell carcinoma.

Positron emission tomography-computed tomography performed in December 2011 showed higher fluorodeoxyglucose uptake in the rectum. In January 2012, a sigmoidoscopy and biopsy were performed and the pathologic diagnosis was high-grade squamous epithelial dysplasia (Fig. 2A and B). There was no continuity between rectal lesion and anal epithelium. At that time, the patient's HIV viral load titer was 80 copies/mL, and his CD4+ T cell count was 312/mm<sup>3</sup> with a regimen of lamivudine-abacavir, darunavir, ritonavir and etravirine. Well-differentiated squamous cell carcinoma could not be ruled out and the clinical stage was T2N1M0, IIIA. Concurrent chemoradiation therapy was initiated with 5-fluorouracil and mitomycin C. After treatment, there was no evidence of disease.

In February 2013, follow-up sigmoidoscopy showed a recurrent mass in the rectum. Well-differentiated squamous cell carcinoma was diagnosed with sigmoidoscopic biopsy and the patient was treated with laparoscopic-assisted abdominoperineal resection (Fig. 2C); the pathologic stage was determined to be T2N0M0, I. The patient continued to visit the outpatient department after discharge without significant complaint or sign of recurrence.

## Discussion

In the past, opportunistic infection was the main cause of death in HIV-infected patients; however, with the advent of HAART, HIV-infected patients are surviving for much longer and instead are facing chronic diseases such as cardiovascular disease, liver disease, and cancer [6]. HAART has led to a great decrease in the incidence of opportunistic infections and AIDS-defining malignancies [3]. In the HAART era, we can assume a decrease in the proportion of AIDS-defining malignancies, but an increase in non-AIDS-defining malignancies [9, 10].

In South Korea, there has been no evidence of change in the incidence of AIDS-defining malignancies or non-AIDS-defining malignancies [7, 8]. Seol et al. investigated the prevalence of malignancies in HIV-infected patients, and reported similar incidence of AIDS-defining and non-AIDS-defining malignancies during the pre-HAART and HAART period, respectively [8]. Cancer occurred in 27 (4%) out of 683 HIV-infected persons. Choe et al. reported approximately the same prevalence with cancer occurring in 33 patients (3.75%) out of 850 patients [7]. Choe et al. did not draw any conclusion about whether the incidence of AIDS-defining malignancies decreased after HAART, however, because of the small size of the study population. Two studies from South Korea showed only 3 rectal ad-

enocarcinoma cases among 59 HIV-infected patients with malignancies [7, 8]. One anal squamous cell carcinoma was reported but rectal squamous cell carcinoma was not reported.

The majority of colorectal malignancies both in the general population and among HIV-infected patients are adenocarcinomas. However, higher proportions of other cancer histologies were identified unlike those seen in the general population [11]. Compared to the general population, more HIV-infected patients were diagnosed with squamous cell carcinoma (2.5% vs. 0.04%, respectively), small cell carcinoma (1.6% vs. 0.08%, respectively), and leiomyosarcoma (0.9% vs. 0.04%, respectively).

HIV infection increases susceptibility to virally promoted cancers such as Burkitt's lymphoma and Hodgkin's lymphoma (EBV infection), Kaposi's sarcoma (human herpesvirus-8 [HHV-8] infection), and anogenital carcinoma (HPV infection) [12]. Several HPV types have been known as the oncogenic agents responsible for the cervical squamous carcinomas. Molecular mechanisms for HPV-associated carcinogenesis have been described, mediated by HPV E6 and E7 oncoproteins [13]. Recent studies reported that the most common HPV type detected in anal squamous cell carcinoma is HPV 16, but non HPV 16 subtypes were also detected [11, 14, 15]. Unfortunately, in this case, PCR test for HPV was not performed.

In the present case, the CD4+ T cell count was 116/mm<sup>3</sup> at DLBCL diagnosis and 312/mm<sup>3</sup> at squamous cell carcinoma diagnosis, respectively. A CD4+ T cell count below 200/mm<sup>3</sup> was reported to have a meaningful relationship with the occurrence of malignancy in Choe's study [7]. There was an increase in the proportion of patients with CD4+ T cell counts above 200/mm<sup>3</sup>, which emphasizes the risk of malignancy, even in the context of immune reconstitution [16]. It is clear that the importance of early diagnosis and prevention of cancer in HIV-infected patients should be emphasized.

Non-AIDS-defining malignancy such as HPV-associated anorectal cancer is an emerging problem for HIV-infected persons in South Korea. The screening and prevention of cancers should be included in the clinical care of HIV-infected individuals.

## Acknowledgment

This research was supported by the Basic Science Research-Program through the National Research Foundation of Korea (NRF) funded by the Ministry of Education, Science and Technology (NRF-2013R1A1A2005412).

## References

1. Goedert JJ, Coté TR, Virgo P, Scoppa SM, Kingma DW, Gail MH, Jaffe ES, Biggar RJ. Spectrum of AIDS-associated malignant disorders. *Lancet* 1998;351:1833-9.
2. Anonymous. 1993 revised classification system for HIV infection and expanded surveillance case definition for AIDS among adolescents and adults. *MMWR Recomm Rep* 1992;41:1-19.
3. Palella FJ Jr., Baker RK, Moorman AC, Chmiel JS, Wood KC, Brooks JT, Holmberg SD; HIV Outpatient Study Investigators. Mortality in the highly active antiretroviral therapy era: changing causes of death and disease in the HIV outpatient study. *J Acquir Immune Defic Syndr* 2006;43:27-34.
4. Patel P, Hanson DL, Sullivan PS, Novak RM, Moorman AC, Tong TC, Holmberg SD, Brooks JT; Adult and Adolescent Spectrum of Disease Project and HIV Outpatient Study Investigators. Incidence of types of cancer among HIV-infected persons compared with the general population in the United States, 1992-2003. *Ann Intern Med* 2008;148:728-36.
5. Crum-Cianflone N, Hullsiek KH, Marconi V, Weintrob A, Ganesan A, Barthel RV, Fraser S, Agan BK, Wegner S. Trends in the incidence of cancers among HIV-infected persons and the impact of antiretroviral therapy: a 20-year cohort study. *AIDS* 2009;23:41-50.
6. Sackoff JE, Hanna DB, Pfeiffer MR, Torian LV. Causes of death among persons with AIDS in the era of highly active antiretroviral therapy: New York City. *Ann Intern Med* 2006;145:397-406.
7. Choe PG, Song JS, Cho JH, Kim SH, Park KH, Bang JH, Park WB, Kim HB, Kim DW, Kim TY, Heo DS, Oh MD, Kim NJ, Choe KW. Malignancies in patients with human immunodeficiency virus infection in South Korea. *Infect Chemother* 2006;38:367-73.
8. Seol YM, Song MG, Choi YJ, Lee SH, Kim SI, Chung JS, Kwak IS, Cho GJ, Lee H, Jung DS, Moon CS, Park JY. Trends in cancer risk among South Korean patients infected with human immunodeficiency virus. *Korean J Med* 2009;76:554-63.
9. Besson C, Goubar A, Gabarre J, Rozenbaum W, Pialoux G, Châtelet FP, Katlama C, Charlotte F, Dupont B, Brousse N, Huerre M, Mikol J, Camparo P, Mokhtari K, Tulliez M, Salmon-Céron D, Boué F, Costagliola D, Raphaël M. Changes in AIDS-related lymphoma since the era of highly active antiretroviral therapy. *Blood* 2001;98:2339-44.
10. Matthews GV, Bower M, Mandalia S, Powles T, Nelson MR, Gazzard BG. Changes in acquired immunodeficiency syndrome-related lymphoma since the introduction of highly active antiretroviral therapy. *Blood* 2000;96:2730-4.
11. Varnai AD, Bollmann M, Griefingholt H, Speich N, Schmitt C, Bollmann R, Decker D. HPV in anal squamous cell carcinoma and anal intraepithelial neoplasia (AIN). Impact of HPV analysis of anal lesions on diagnosis and prognosis. *Int J Colorectal Dis* 2006;21:135-42.
12. Fakhry C, D'Souza G, Sugar E, Weber K, Goshu E, Minkoff H, Wright R, Seaberg E, Gillison M. Relationship between prevalent oral and cervical human papillomavirus infections in human immunodeficiency virus-positive and -negative women. *J Clin Microbiol* 2006;44:4479-85.
13. zur Hausen H. Papillomaviruses causing cancer: evasion from host-cell control in early events in carcinogenesis. *J Natl Cancer Inst* 2000;92:690-8.
14. Cornall AM, Roberts JM, Garland SM, Hillman RJ, Grulich AE, Tabrizi SN. Anal and perianal squamous carcinomas and high-grade intraepithelial lesions exclusively associated with "low-risk" HPV genotypes 6 and 11. *Int J Cancer* 2013;133:2253-8.
15. Wong AK, Chan RC, Aggarwal N, Singh MK, Nichols WS, Bose S. Human papillomavirus genotypes in anal intraepithelial neoplasia and anal carcinoma as detected in tissue biopsies. *Mod Pathol* 2010;23:144-50.
16. Barclay LR, Buskin SE, Kahle EM, Aboulafia DM. Clinical and immunologic profile of AIDS-related lymphoma in the era of highly active antiretroviral therapy. *Clin Lymphoma Myeloma* 2007;7:272-9.