



Conus Medullaris Syndrome Due to Missed Thoracolumbar Spinal Fracture in a Patient with Ankylosing Spondylitis who Underwent Hip Surgery

Ki Tae Jung¹ , Keum Young So¹ , Bo Hyun Jang² , Sang Hun Kim¹ 

¹Department of Anaesthesiology and Pain Medicine, Chosun University School of Medicine, Gwangju, Republic of Korea

²Department of Anaesthesiology and Pain Medicine, Chosun University Hospital, Gwangju, Republic of Korea

Cite this article as: Jung KT, So KY, Jang BH, Kim SH. Conus Medullaris Syndrome Due to Missed Thoracolumbar Spinal Fracture in a Patient with Ankylosing Spondylitis who Underwent Hip Surgery. Turk J Anaesthesiol Reanim 2020; 48(2): 160-4.

Abstract

Ankylosing spondylitis (AS) is vulnerable to fracture, and the missed diagnosis can lead to neurological deterioration. Herein, we present the conus medullaris syndrome due to aggravation of the missed spinal fracture in an 85-year-old woman with AS who underwent hip surgery. She underwent osteosynthesis in a supine position with supports under her shoulders and head due to spine deformity with AS, but was fully supine without supports after surgery. She showed complete paraplegia at postoperative 12 h. The re-reading radiological imaging showed the missed spinal fracture, of which the deteriorated dislocation was revealed on the re-examined radiological evaluation. This deterioration was not recovered ultimately despite an emergent surgery. A thorough preoperative assessment is essential to prevent the missed diagnosis of spinal fracture and minimise deterioration due to its dislocation, with specific spine precaution during transport, transfer and positioning.

Keywords: Ankylosing spondylitis, intramedullary fracture fixation, preoperative assessment, spinal cord compression, spinal fractures

Introduction

Ankylosing spondylitis (AS) has been known to be associated with the strong risk of spinal fracture even after minor trauma due to its changed biomechanical properties; it has a 35%-50% mortality rate, and 7.7 times chance of spinal fracture than the general population (1-4). These fractures are often neglected as a symptom of their chronic spinal pain resulting from AS itself and the pre-existed fracture without neurological complications, which does not need surgery (5). Furthermore, they can be frequently missed on simple X-ray in patients with osteoporosis, resulting in delayed diagnosis (3-5). Herein, we present the conus medullaris syndrome due to dislocation of missed thoracolumbar spinal fracture in a patient with AS who underwent osteosynthesis of femur intertrochanteric fracture.

Case presentation

An 85-year-old woman (height: 162 cm and weight: 55 kg) was scheduled for an elective closed reduction and intramedullary nailing of the right femur. She had progressive kyphosis due to AS requiring support of three or four pillows during sleep. Her preoperative laboratory examination was unremarkable except for haemoglobin of 8.1 g dL⁻¹. Her preoperative simple X-ray showed thoracic kyphoscoliosis, AS (negative rheumatoid factor and positive HLA-B27), L2 compression fracture and severe osteoporosis. There were no abnormal neurological signs and symptoms except for lumbar pain. Bone marrow densitometry showed severe osteoporosis with -3.6 YA T score in the femur and -4.8 YA T score in the L1 vertebra. Preoperative anaesthetic airway evaluation was non-specific.

She was premedicated with midazolam 2.0 mg intramuscularly 30 min before anaesthetic induction. After arriving at the operating room, she was in supine position after placing supports under her shoulders and head to fill the gap due to kyphoscoliosis, in which anaesthesia induction and endotracheal intubation were performed (Figure 1). Manual mask ventilation was performed successfully with propofol 120 mg with single dose, remifentanyl 4.0 ng mL⁻¹ with an effect-site target-controlled infusion system and desflurane 5 vol%. Intubation was successful at the first attempt after rocuronium bromide 0.6 mg kg⁻¹.

The surgery was performed in a supine position maintaining preanaesthetic folded blankets and pillows for support, and the ipsilateral arm was elevated in a sling while the left leg was in lithotomy position. For an adducted position of the right fractured leg, the trunk was pushed slightly to the contralateral side (Figure 1). During surgery, gentle reduction with minimal retraction force and gentle hammer blows to push down the nail was applied.

After reversal of neuromuscular blockade using sugammadex 200 mg, she was transferred to the recovery room and ward with the intraoperative same height of supports, in which she did not show any neurological deficits. However, she complained of complete paraplegia below the hip girdle and groin area 12 h after surgery, and the physicians and medical staff found her fully supine without support of pillows on the ward accidentally.

The physicians found the preoperative existed missed thoracolumbar spinal fracture (approximately 29.5° kyphotic angle) by re-reading the preoperative X-ray (Figure 2) and the more aggravated anteroinferior dislocation of the L1 vertebral body (approximately 2.5° kyphotic angle) on the postoperative thoracolumbar spine X-ray (Figure 3). The postoperative three-dimensional computed tomography (CT) and whole spine magnetic resonance imaging (MRI) also showed the same results with thoracolumbar spine X-ray, with discontinuous continuity of spinal columns and spinal canal (Figures 4 and 5). Whole spine MRI showed severe central canal stenosis in the level of T12-L1 interbody space (Figure 5). She was finally diagnosed with conus medullaris syndrome. Twelve

hours after recognising paraplegia, she underwent emergency posterior lumbar interbody fusion (PLIF) from T11 to L3 (approximately 23° restored kyphotic angle) (Figure 6). After PLIF surgery, she had suffered postoperative complications, such as multiple sores, pulmonary thromboembolism, pleural effusion and infections, which required flap surgery, anti-thrombotic therapy, chest drainage and antibiotic therapy for a long time. Unfortunately, she was discharged after 1 year with permanent paraplegia despite meticulous surgery, medical treatment and rehabilitations.

This report was approved by the Institutional Review Board of Chosun University Hospital (CHOSUN 2019-07-002). Consent was not necessary.

Discussion

The missed diagnosis of spine fracture can cause aggravated neurological deterioration because of the possibility of dislocation and instability. Therefore, the anaesthesiologists should pay attention to avoid the preoperative missed spine fracture diagnosis as well as to prevent the aggravating or iatrogenic spine fracture with specific spine precaution during transport and management of patients with AS and osteoporosis.

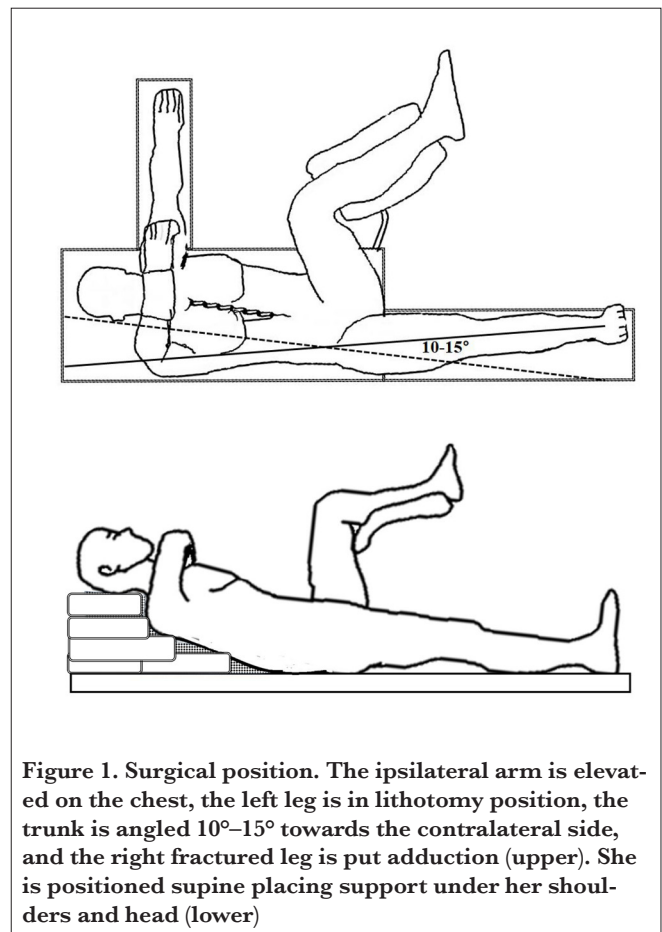


Figure 1. Surgical position. The ipsilateral arm is elevated on the chest, the left leg is in lithotomy position, the trunk is angled 10°–15° towards the contralateral side, and the right fractured leg is put adduction (upper). She is positioned supine placing support under her shoulders and head (lower)

Main Points:

- Ankylosing spondylitis is associated with the strong risk of spinal fracture even after minor trauma.
- A thorough preoperative assessment is essential to prevent the missed diagnosis of spinal fracture, which can lead to neurological deterioration.
- We should take the specific spine precaution into consideration during the perioperative period.

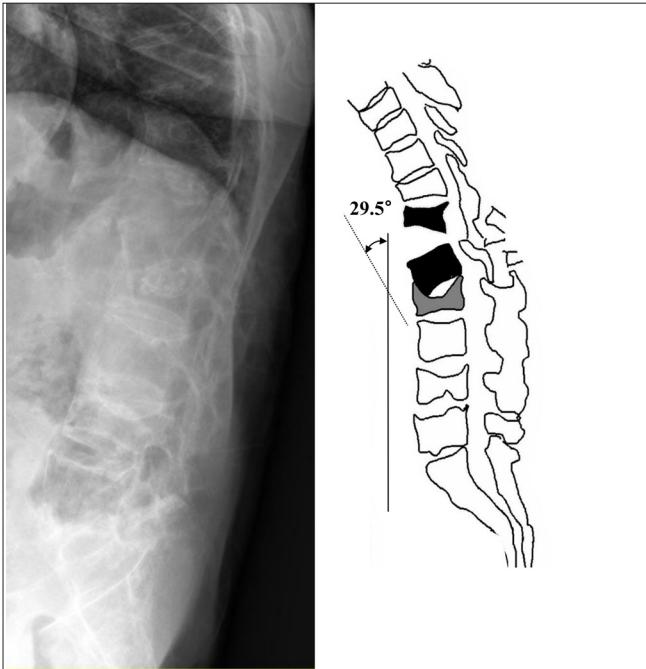


Figure 2. Preoperative lumbar X-ray (left) and linear diagram representing the lateral view of the spine (right) showing L2 compression fracture and spinal fracture between T12 and L1 with kyphotic angle approximately 29.5°. The dotted and solid lines are thoracic and lumbar alignment lines, respectively

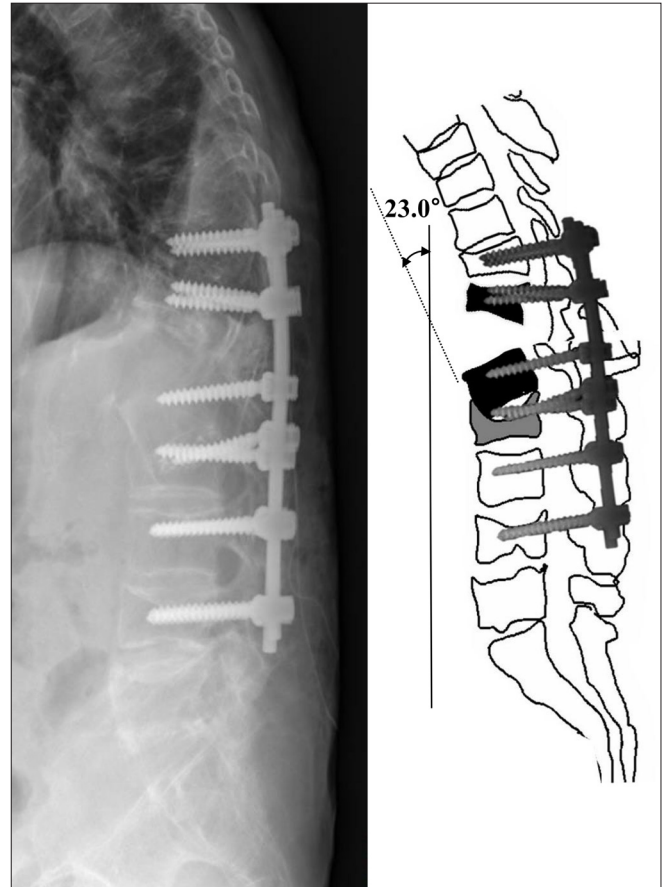


Figure 4. Postoperative three-dimensional computed tomography after hip surgery showing the anterior-inferior dislocation of thoracolumbar spinal fracture, left pedicle fracture, right transverse process fracture and spinous process fracture in sagittal (left and right) and axial views (middle)

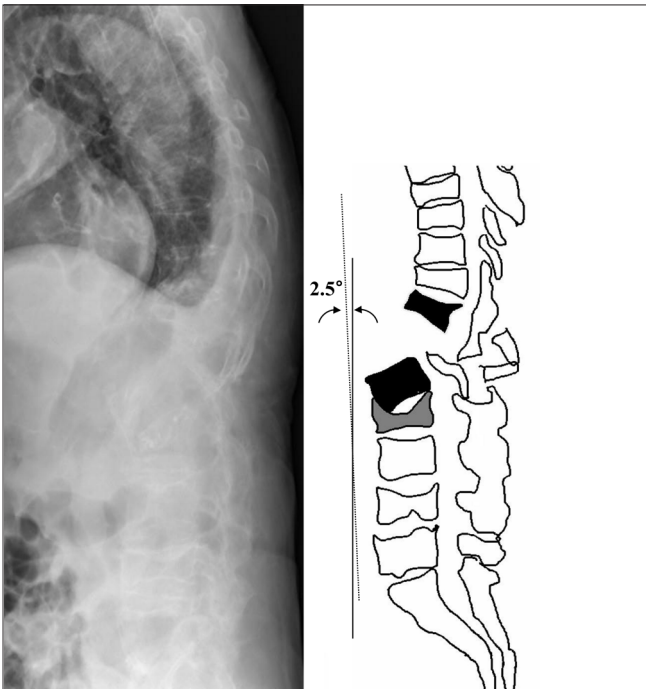


Figure 3. Postoperative thoracolumbar X-ray (left) and linear diagram representing the lateral view of the spine after hip surgery (right) showing more deteriorated anterior-inferior dislocation of spinal fracture with kyphotic angle approximately 2.5°. The dotted and solid lines are thoracic and lumbar alignment lines, respectively

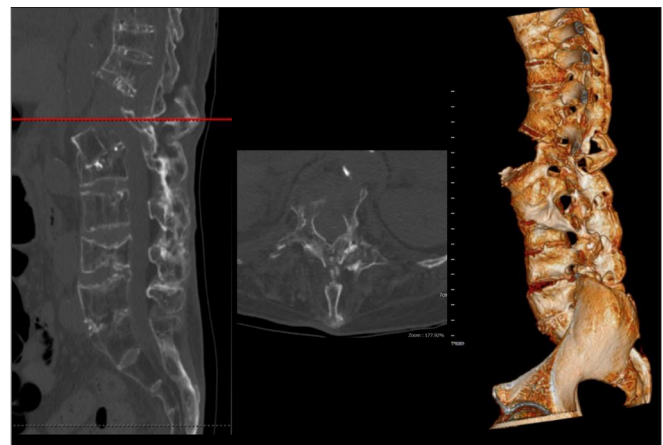


Figure 5. Postoperative spine magnetic resonance imaging after hip surgery showing the discontinuity of the spinal canal due to thoracolumbar spinal fracture and the dislocation of the L1 vertebral body showing cord oedema and the possibility of cord transection in the sagittal (left) and axial (right) T2-weighted images

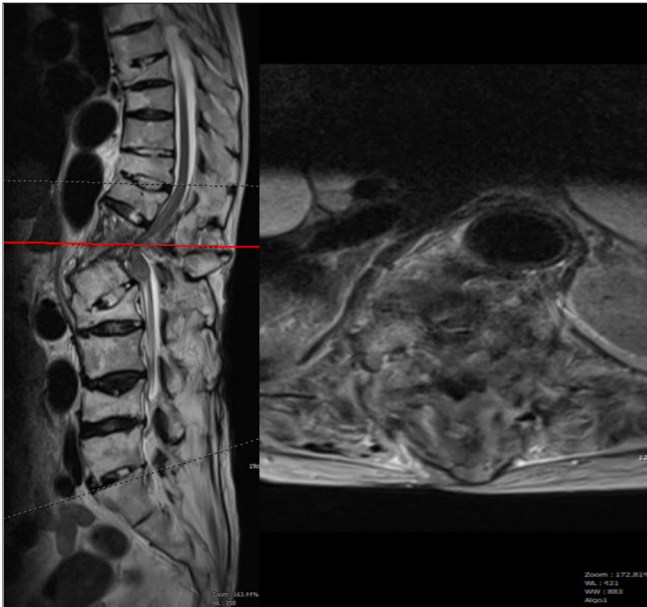


Figure 6. Postoperative lumbar X-ray (left) and linear diagram representing the lateral view of the spine after posterior lumbar interbody fusion (right) showing spine alignment of dislocated spinal fracture is restored with approximately 23.0° of kyphotic angle. The dotted and solid lines are thoracic and lumbar alignment lines, respectively

First, the missed diagnosis of fracture and even its dislocation is commonplace within 24 h from an initial assessment in 37% of patients with AS due to a very low suspicion of serious injury and a difficult interpretation of X-ray imaging (1, 4, 5). It can be frequently missed, especially in patients with significant osteoporosis or osteopenia, if the patients have the AS-related chronic pain itself or do not complain of neurological deficits (1, 5-7). Therefore, thorough preoperative CT and MRI scans as well as the exact interpretation should be recommended to avoid the preoperative missed diagnosis (7, 8).

Second, the inappropriate positioning is strongly related with aggravating or iatrogenic spine fracture with/without neurological deficits in patients with AS (1, 9-12). Any excessive hyperextension should be avoided with sufficient supporting and medical source to help maintain the pre-existing skeletal curvatures always all the time (1, 13). However, in this case, she was transported without any precaution and information about the possibility of spinal fracture presence. Furthermore, the specific surgical positioning and procedure might result in the dislocation of missed spinal fracture, which can be explained by the combined effect of excess distraction forces and compressive forces applied to the anterior and posterior vertebral columns, respectively, with the gentle traction and hammer blows (12). Therefore, the specific positional supports should be advised during transport into any place as

well as patient's positioning for examination and surgery to physicians and every medical staff (1, 14).

Conclusion

A thorough preoperative physiological and radiological evaluation with a high index of suspicion is essential to confirm the presence of spinal fracture or dislocation and to minimise deterioration, especially in patients with osteoporosis with AS. Furthermore, we should take the specific spine precaution into consideration during the perioperative period.

Informed Consent: This report and consent exemption were approved by the Institutional Review Board of Chosun University Hospital (CHOSUN 2019-07-002). Consent was not necessary.

Peer-review: Externally peer-reviewed.

Author Contributions: Concept - K.T.J., K.Y.S., B.H.J., S.H.K.; Design - K.T.J., S.H.K.; Supervision - K.Y.S., S.H.K.; Resources - K.T.J., B.H.J.; Materials - K.T.J., B.H.J.; Data Collection and/or Processing - K.T.J., B.H.J.; Analysis and/or Interpretation - K.T.J., K.Y.S., B.H.J., S.H.K.; Literature Search - K.T.J., K.Y.S., B.H.J., S.H.K.; Writing Manuscript - K.T.J., B.H.J.; Critical Review - K.Y.S., S.H.K.

Conflict of Interest: The authors have no conflicts of interest to declare.

Financial Disclosure: The authors declared that this study has received no financial support.

References

1. Reinhold M, Knop C, Kneitz C, Disch A. Spine Fractures in Ankylosing Diseases: Recommendations of the Spine Section of the German Society for Orthopaedics and Trauma (DGOU). *Global Spine J* 2018; 8: 56s-68. [\[CrossRef\]](#)
2. Shah NG, Keraliya A, Nunez DB, Schoenfeld A, Harris MB, Bono CM, et al. Injuries to the Rigid Spine: What the Spine Surgeon Wants to Know. *Radiographics* 2019; 39: 449-66. [\[CrossRef\]](#)
3. Westerveld LA, Verlaan JJ, Oner FC. Spinal fractures in patients with ankylosing spinal disorders: a systematic review of the literature on treatment, neurological status and complications. *Eur Spine J* 2009; 18: 145-56. [\[CrossRef\]](#)
4. Choi D. Fractures in Ankylosing Disorders of the Spine: Easy to Miss and High Risk of Deterioration. *World Neurosurg* 2015; 83: 1029-31. [\[CrossRef\]](#)
5. Schiefer TK, Milligan BD, Bracken CD, Jacob JT, Krauss WE, Pichelmann MA, et al. In-hospital neurologic deterioration following fractures of the ankylosed spine: a single-institution experience. *World Neurosurg* 2015; 83: 775-83. [\[CrossRef\]](#)
6. Maas F, Spoorenberg A, van der Slik BPG, van der Veer E, Brouwer E, Bootsma H, et al. Clinical Risk Factors for the Presence and Development of Vertebral Fractures in Patients With Ankylosing Spondylitis. *Arthritis Care Res* 2017; 69: 694-702. [\[CrossRef\]](#)

7. Vazan M, Ryang YM, Barz M, Torok E, Gempt J, Meyer B. Ankylosing Spinal Disease-Diagnosis and Treatment of Spine Fractures. *World Neurosurg* 2019; 123: e162-e70. [\[CrossRef\]](#)
8. Finkelstein JA, Chapman JR, Mirza S. Occult vertebral fractures in ankylosing spondylitis. *Spinal Cord* 1999; 37: 444-7. [\[CrossRef\]](#)
9. Danish SF, Wilden JA, Schuster J. Iatrogenic paraplegia in 2 morbidly obese patients with ankylosing spondylitis undergoing total hip arthroplasty. *J Neurosurg Spine* 2008; 8: 80-3. [\[CrossRef\]](#)
10. Ruf M, Rehm S, Poekler-Schoeniger C, Merk HR, Harms J. Iatrogenic fractures in ankylosing spondylitis--a report of two cases. *Eur Spine J* 2006; 15: 100-4. [\[CrossRef\]](#)
11. Tavaloro C, Ghaffar S, Zhou H, Nguyen QT, Bellabarba C, Bransford RJ. Is routine MRI of the spine necessary in trauma patients with ankylosing spinal disorders or is a CT scan sufficient? *Spine J* 2019; 19: 1331-9. [\[CrossRef\]](#)
12. Mahesh BH, Jayaswal A, Bhan S. Fracture dislocation of the spine after total hip arthroplasty in a patient with ankylosing spondylitis with early pseudoarthrosis. *Spine J* 2008; 8: 529-33. [\[CrossRef\]](#)
13. Oh JS, Doh JW, Shim JJ, Lee KS. Leading a Patient of Ankylosing Spondylitis to Death by Iatrogenic Spinal Fracture. *Korean J Spine* 2016; 13: 80-2. [\[CrossRef\]](#)
14. Werner BC, Samartzis D, Shen FH. Spinal fractures in patients with ankylosing spondylitis: etiology, diagnosis, and management. *J Am Acad Orthop Surg* 2016; 24: 241-9. [\[CrossRef\]](#)