



2020

Percutaneous Tricuspid Valve in Failed Annuloplasty Ring and Paravalvular Leak Closure for Mechanical Aortic Valve- A Case Report

Follow this and additional works at: <https://www.j-saudi-heart.com/jsha>



Part of the [Cardiology Commons](#)



This work is licensed under a [Creative Commons Attribution-Noncommercial-No Derivative Works 4.0 License](#).

Recommended Citation

Naeim, Hesham A.; Abuelatta, Reda; Alharach, Rifaat; Elhaj, Abderrahman; Alsuwayh, Abdulaziz; and Azmi, Mohamed (2020) "Percutaneous Tricuspid Valve in Failed Annuloplasty Ring and Paravalvular Leak Closure for Mechanical Aortic Valve- A Case Report," *Journal of the Saudi Heart Association*: Vol. 32 : Iss. 4 , Article 2.

Available at: <https://doi.org/10.37616/2212-5043.1141>

This Case Report is brought to you for free and open access by Journal of the Saudi Heart Association. It has been accepted for inclusion in Journal of the Saudi Heart Association by an authorized editor of Journal of the Saudi Heart Association.

Percutaneous Tricuspid Valve in Failed Annuloplasty Ring and Paravalvular Leak Closure for Mechanical Aortic Valve- A Case Report

Cover Page Footnote

Acknowledgment: The authors want to acknowledge Dr. Ibraheem Alharbi and Dr. Osama Amoudi for their support during the production of this article.

Percutaneous Tricuspid Valve in Failed Annuloplasty Ring and Paravalvular Leak Closure for Mechanical Aortic Valve

Hesham Abdo Naeim*, Reda Abuelatta, Rifaat Alharach, Abderrahman Elhaj, Abdulaziz Alsuwayh, Mohamed Azmi

Madinah Cardiac Center, Saudi Arabia

Abstract

Transcatheter valvular interventions are established as an alternative for surgery in selected patients in symptomatic high surgical risk patients. Tricuspid valve replacement after failed repair ring had limited experience to date. We report this case to highlight the procedure details and results.

Keywords: Tricuspid valve, Transcatheter valves, Paravalvular leak, Aortic valve, Case reports

1. Introduction

Most of the tricuspid valve (TV) surgical repair is due to functional tricuspid regurgitation (TR) due to annular dilatation as a result of left-sided lesions. The presence of significant TV disease is associated with poor outcomes including mortality [1]. Surgical TV repair rather than replacement has been steadily growing in frequency [2]. Management of patients with failed TV repair can be difficult because mortality for redo TV surgery remains high [3]. The long-term outcome of TV repair is suboptimal, with more than 25% of patients developing significant TR within 5 years of repair [4]. To date, experience with the transcatheter tricuspid valve in ring (TVIR) has been limited. The international VIVID registry (Valve-in-Valve International Database Registry), reported that transcatheter TV implantation after prior surgical repair or bioprosthetic valve replacement can be performed successfully

and safely, with good short-term outcomes [3]. Incomplete TV annuloplasty rings tend to develop progressive annular dilation, with dimensions that are large and geometrically heterogeneous [5]. We report a case with transcatheter TVIR plus paravalvular leak closure for mechanical aortic valve.

2. Cases Summary

A 52-year-old male with a history of rheumatic heart disease. He underwent caged ball mechanical aortic valve (AV) replacement in 1979 for severe aortic stenosis. In 1993 he underwent redo surgery with mechanical mitral valve (MV) replacement for severe mitral stenosis. In 2015 he underwent third cardiac surgery for MV replacement due to severe paravalvular leak and tricuspid valve (TV) annuloplasty for severe functional tricuspid regurgitation. He did well until May 2018 where he underwent fourth surgery for MV replacement due to infective endocarditis. The patient admitted in August 2018 with severe shortness of breath (SOB), recurrent

Received 29 June 2020; revised 11 October 2020; accepted 13 October 2020.
Available online 19 November 2020

* Corresponding author: Madinah Cardiac Center, Madina, Khalid Bin Waleed Street, 6167, Saudi Arabia.
E-mail address: heshamnieem@yahoo.com (H.A. Naeim).



pulmonary edema and manifestations of severe right sided failure despite optimal medications. Transesophageal echocardiogram (TEE) transgastric long axis aortic view revealed severe paravalvular leak (PVL) around the aortic prosthesis (Fig. 1A) evidenced by diastolic reversal in the thoracic and abdominal aorta and vena contracta of 0.6 cm. There was also failed TV annuloplasty with severe tricuspid regurgitation (TR) and severe pulmonary hypertension. The heart team decided he was a high surgical risk due to multiple redo surgeries. The team opted to do transcatheter PVL closure for AV and transcatheter TVIR.

The aortic valve showed two large PVLs, anteromedial one was first crossed using multipurpose catheter and angled Glide wire that replaced by stiff wire. The 8 F delivery sheath easily crossed the defect, 10 mm muscular VSD device deployed without affecting the mechanics of the AV (Fig. 1B and C). Still significant residual PVL was noted through the other defect. A vascular plug II size 12 was successfully sealed the residual leakage (Fig. 1D). Both devices were released (Fig. 1E) with trace residual aortic PVL.

Echo 2D measurement of TV ring was 29*25 mm, 3D C shaped TV ring, and color doppler of Severe TR showed at (Fig. 2A, B, and 2C). Sapien 3 valve size 29 was selected based on surgical report of the

ring type supported by the online mitral VIV application and confirmed by the 2D echo measurements of the TV ring. Sapien 29 mm valve deployed in the TV ring and positioned 85% ventricular and 15% atrial (Fig. 2D and E). After valve deployment residual significant PVL noted (Fig. 2F) so the valve was re-inflated after adding additional 4 mm to achieve 31 mm final valve size. Unfortunately, still residual TV PVL (Fig. 3A). To eliminate the residual PVL the defect was crossed and a muscular VSD device size 10 mm was deployed between the TV ring and the Sapien valve (Fig. 3B, C, and 3D). The mean RA-RV gradient by Doppler was 4 mmHg, Residual trace TV PVL showed at (Fig. 3E) The patient was treated with warfarin due to the presence of left-sided mechanical valves. After a year follow up TTE showed the tricuspid bioprosthesis had normal function with no leak and there was residual mild aortic PVL. The LV function remained at ejection fraction of 55%.

3. Discussion

TV implantation in incomplete TV rings is challenging than bioprosthetic valves because a circumferential landing zone is deficient and there is risk of valve embolization and PVL [6]. Evaluation of valve size is difficult because most rings are oval with a medial opening and surrounded by valvular

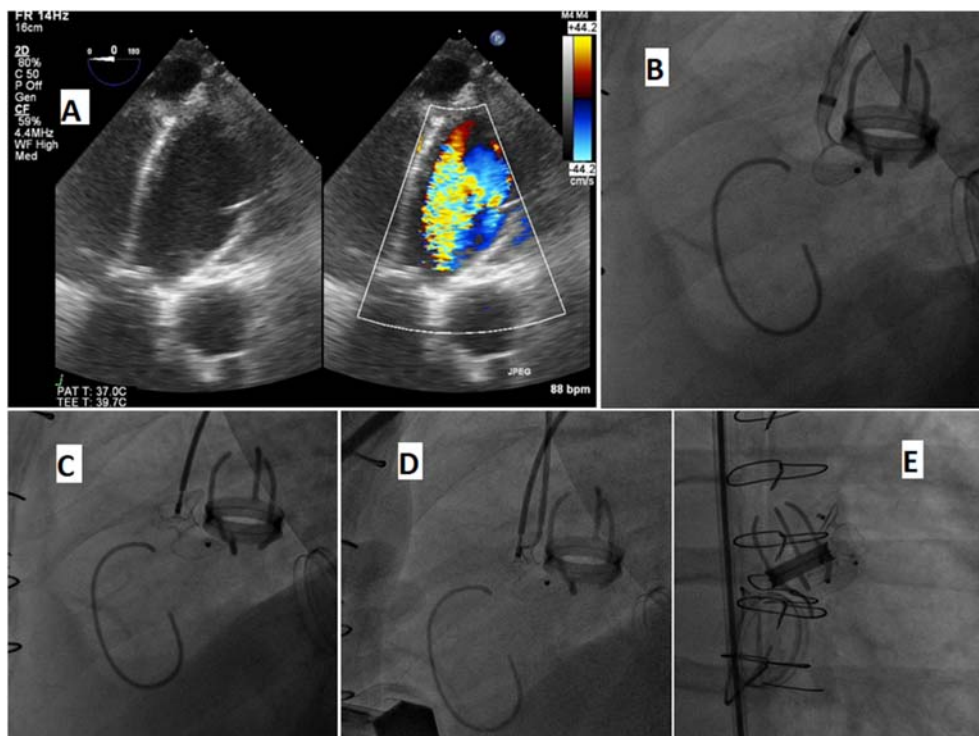


Fig. 1. A: TEE transgastric long axis aortic view showed severe paravalvular leak. B Deployment of the distal disc (LV disc) of an 10 mm muscular VSD device. C: Deployment of the proximal disc (aortic disc) of the device. D: Second wire for another device. E: Released both devices.

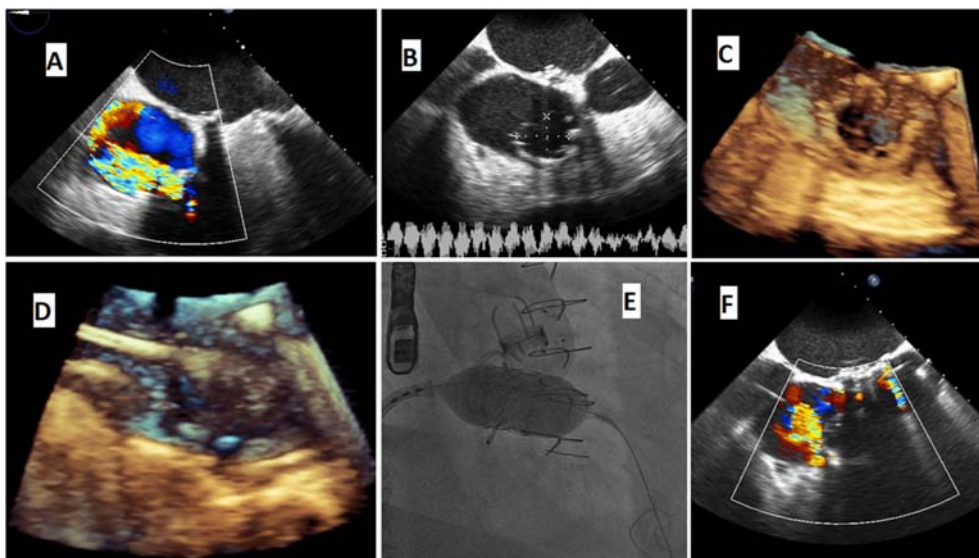


Fig. 2. A: Severe TR, failed annuloplasty ring. B: 2D measurement of TV ring. C: 3D C shaped TV ring. D: Deployment of 29 Sapien valve in TV ring. E: Balloon inflation of the valve. F: Residual moderate PVL.

tissue [7]. Electrocardiogram-gated computed tomography may be used to assess the ring dimensions, but cannot consider the presence of valvular tissue that may change the true dimensions. Bouleti et al. reported 3 cases of TVIR, immediate and 1-year follow-up outcome was good [7].

Jamil et al. reported rapid pacing in 56% of 22 patients he used balloon sizing to assess the true dimensions of the ring, and any residual TR [8]. In

prior reports, TVIR was associated with a high rate of technical success and few serious procedural complications, restoration of good TV function, and clinical improvement in most patients [8]. The mean TV gradient remained higher than in a normal native valve, similar to that reported for newly implanted surgical bioprosthesis in the TV position [9]. According to the American Society of Echocardiography guidelines, prosthetic TV stenosis should be considered when the peak velocity exceeds

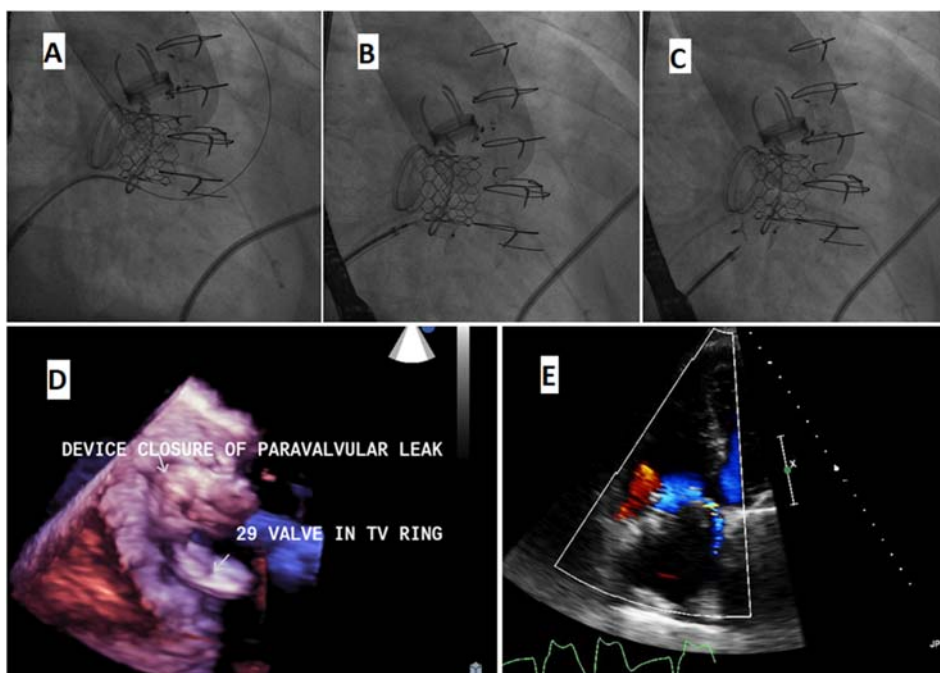


Fig. 3. A: Wire passed the residual PVL. B: deployment of a 10 mm muscular VSD device. C: Released PVL closure device. D: 3D of the implanted valve and the PVL closure device. E: Residual trace PVL.

1.7 m/s, the mean gradient is 6 mm Hg or greater, and the pressure halftime is 230 msec or longer [10].

4. Conclusion

Transcatheter implantation of tricuspid valve in-ring is an alternative to surgery in symptomatic high surgical risk patients. Larger series with longer follow-up are needed to assess the potential role of TVIR. Fixing the left-sided valves is mandatory before looking for the TV.

Author Contribution

Conception and design of Study; Funding for the research: Hesham Abdo Naeim; Reda Abuelatta. Literature review; Data collection; Supervision of the research: Hesham Abdo Naeim; Reda Abuelatta; Rifaat Alharach; Abderrahman Elhaj. Acquisition of data; Drafting of manuscript; Research coordination and management: Hesham Abdo Naeim; Reda Abuelatta; Abdulaziz Alsuwayh; Mohamed Azmi. Analysis and interpretation of data: Hesham Abdo Naeim; Rifaat Alharach; Abdulaziz Alsuwayh; Mohamed Azmi. Research investigation and analysis: Hesham Abdo Naeim; Reda Abuelatta; Abderrahman Elhaj; Mohamed Azmi. Revising and editing the manuscript critically for important intellectual contents: Hesham Abdo Naeim; Reda Abuelatta; Rifaat Alharach; Abdulaziz Alsuwayh. Data preparation and presentation: Reda Abuelatta; Rifaat Alharach; Abderrahman Elhaj; Mohamed Azmi.

Conflicts of Interest

None.

Acknowledgment

The authors want to acknowledge Dr Ibraheem Alharbi and Dr Osama Amoudi for their support during production of this article.

References

- [1] Lewis MJ, Ginns JN, Ye S, Chai P, Quaegebeur JM, Bacha E, et al. Postoperative tricuspid regurgitation after adult congenital heart surgery is associated with adverse clinical outcomes. *J Thorac Cardiovasc Surg* 2016;151:460–5. <https://doi.org/10.1016/j.jtcvs.2015.09.028>.
- [2] Kilic A, Saha-Chaudhuri P, Rankin JS, Conte JV. Trends and outcomes of tricuspid valve surgery in North America: an analysis of more than 50,000 patients from the society of thoracic surgeons database. *Ann Thorac Surg* 2013;96:1546–52. <https://doi.org/10.1016/j.athoracsur.2013.06.031>.
- [3] Taggart NW, Cabalka AK, Eicken A, Aboulhosn JA, Thomson JDR, Whisenant B, et al. Outcomes of transcatheter tricuspid valve-in-valve implantation in patients with Ebstein anomaly. *Am J Cardiol* 2018;121:262–8. <https://doi.org/10.1016/j.amjcard.2017.10.017>.
- [4] McCarthy PM, Bhudia SK, Rajeswaran J, Hoercher KJ, Lytle BW, Cosgrove DM, et al. Tricuspid valve repair durability and risk factors for failure. *J Thorac Cardiovasc Surg* 2004;127:674–85. <https://doi.org/10.1016/j.jtcvs.2003.11.019>.
- [5] Condado J, Leonardi R, Babaliaros V. Percutaneous tricuspid valve-in-ring replacement for the treatment of recurrent severe tricuspid regurgitation. *Catheter Cardiovasc Interv* 2015;86:1294–8. <https://doi.org/10.1002/ccd.25980>.
- [6] Kondo N, Shuto T, McGarvey JR, Koomalsingh KJ, Takebe M, Gomran RC, et al. Melody valve-in-ring procedure for mitral valve replacement: feasibility in four annuloplasty types. *Ann Thorac Surg* 2012;93:783–8. <https://doi.org/10.1016/j.athoracsur.2011.12.021>.
- [7] Bouletti C, Himbert D, Brochet E, Ou P, Lung B, Nejari M, et al. Transfemoral tricuspid valve-in-ring implantation using the Edwards Sapien XT valve: one year follow-up. *Circ Cardiovasc Interv* 2015;8:e002225. <https://doi.org/10.1161/CIRCINTERVENTIONS.114.002225>.
- [8] Aboulhosn J, Cabalka AK, Levi DS, Himbert D, Testa L, Azeem L, et al. Transcatheter valve-in-ring implantation for the treatment of residual or recurrent tricuspid valve dysfunction after prior surgical repair. *JACC Cardiovasc Interv* 2017;10(1):54–63. <https://doi.org/10.1016/j.jcin.2016.10.036>.
- [9] Blauwet LA, Danielson GK, Burkhart HM, Dearani JA, Malouf JF, Connolly HM, et al. Comprehensive echocardiographic assessment of the hemodynamic parameters of 285 tricuspid valve bioprostheses early after implantation. *J Am Soc Echocardiogr* 2010;23:1045–59. <https://doi.org/10.1016/j.echo.2010.08.007>.
- [10] Baumgartner H, Hung J, Bermejo J, Chambers JB, Evangelista A, Griffin BP, et al. Echocardiographic assessment of valve stenosis: EAE/ASE recommendations for clinical practice. *J Am Soc Echocardiogr* 2009;22:1–23. <https://doi.org/10.1093/ejechoard/jen303>.