

# Collateral or fistula? Coronary artery as the primary source of pulmonary blood flow in a patient with pulmonary atresia and ventricular septal defect

Anurag Yadav, Salil Bhargava, T B S Buxi, Krishna Sirvi

Department of Radiodiagnosis, Sir Ganga Ram Hospital, New Delhi, India

**Correspondence:** Dr. Anurag Yadav, Department of Radiodiagnosis, Sir Ganga Ram Hospital, Rajinder Nagar, New Delhi - 110 060, India.  
E-mail: anu\_nalin@hotmail.com

## Abstract

In patients with pulmonary atresia and ventricular septal defect (PA/VSD), a coronary artery being the primary source of pulmonary blood flow is a rare entity. We describe two cases of PA/VSD with coronary-to-pulmonary artery fistula with emphasis on the role of Computed Tomographic Angiography (CTA) in depicting all the sources of pulmonary blood supply, to predict surgical management and need for unifocalization of Major Aortopulmonary Collateral Arteries (MAPCA's).

**Key words:** Aortopulmonary collateral; coronary artery–pulmonary artery collateral; coronary artery–pulmonary artery fistula; pulmonary atresia; unifocalization; ventricular septal defect

## Introduction

Pulmonary atresia and ventricular septal defect (PA/VSD) is a complex congenital heart disease in which the lung derives its blood supply from systemic–pulmonary collaterals, more commonly arising from the aorta (MAPCAs) and its major branches. Other sources include a patent ductus arteriosus and an aortopulmonary window. Rarely, a collateral from the coronary artery to the pulmonary artery may be a source of blood supply to the lungs and is variously referred to as a coronary–pulmonary artery fistula (CPAF) or coronary artery–pulmonary artery collateral (CAPA).

Traditionally, catheter angiography is used to depict these multiple sources of pulmonary blood supply. However,

it is an invasive procedure, operator dependent, and is associated with significant radiation exposure. There is a dearth of literature regarding when to suspect and how to adequately demonstrate this congenital anomaly using CT angiography. We describe two cases of PA/VSD with coronary artery as a source of pulmonary blood flow highlighting the role of CT angiography in the diagnosis and management this entity.

## Case Report

A 22-year-old gentleman with chief complaints of long-standing effort intolerance and palpitations was examined and found to have cyanosis, oxygen saturation

This is an open access journal, and articles are distributed under the terms of the Creative Commons Attribution-NonCommercial-ShareAlike 4.0 License, which allows others to remix, tweak, and build upon the work non-commercially, as long as appropriate credit is given and the new creations are licensed under the identical terms.

**For reprints contact:** reprints@medknow.com

**Cite this article as:** Yadav A, Bhargava S, Buxi TB, Sirvi K. Collateral or fistula? Coronary artery as the primary source of pulmonary blood flow in a patient with pulmonary atresia and ventricular septal defect. Indian J Radiol Imaging 2018;28:433-5.

### Access this article online

#### Quick Response Code:



**Website:**  
www.ijri.org

**DOI:**  
10.4103/ijri.IJRI\_489\_17

of 75%, and a continuous murmur on clinical examination. Evaluation with transthoracic echocardiography showed evidence of a VSD and PA with a dilated left main coronary artery (LMCA). CT thoracic angiography was advised to demonstrate the pulmonary vasculature.

A prospectively ECG-gated CT angiography of the thorax was performed on a 128 slice Multidetector Computed Tomography (MDCT) scanner in a helical mode (slice thickness 0.75 mm, pitch 0.15, 120 kV/470 mA). Angiographic phase was obtained after injection of 80 ml of iodinated nonionic contrast (350 mg/ml at 5.5 ml/s using a dual head pressure injector) by bolus triggering. A venographic phase was also obtained including the upper abdomen to assess concomitant venous anomalies.

The CT angiography confirmed the findings of echocardiography [Figure 1A-1C], and the main pulmonary artery (MPA) was seen to arise from the dilated LMCA [Figure 1D]. The coronary-to-pulmonary artery communication measured approximately 10 mm in diameter, and the subsequent MPA measured 20 mm. It was seen to bifurcate into the right and left pulmonary arteries which showed good contrast opacification and normal luminal diameters. The LMCA showed normal division into the Left Anterior Descending artery (LAD) and Left Circumflex artery (LCX) which had normal course and caliber. The Right Coronary Artery (RCA) was seen to arise from the right coronary cusp and showed normal caliber and course. An aortopulmonary collateral (10.3 mm in diameter) was seen extending from the right lateral wall of the descending thoracic aorta at the D7 vertebral level to the right descending pulmonary artery [Figure 1E]. Given these imaging findings, a diagnosis of PA/VSD, CPAF, and a single MAPCA was made.

The patient underwent a surgical correction in which the connection between the blind pouch of the MPA and the LMCA [Figure 1F] was clamped, disconnected and LMCA

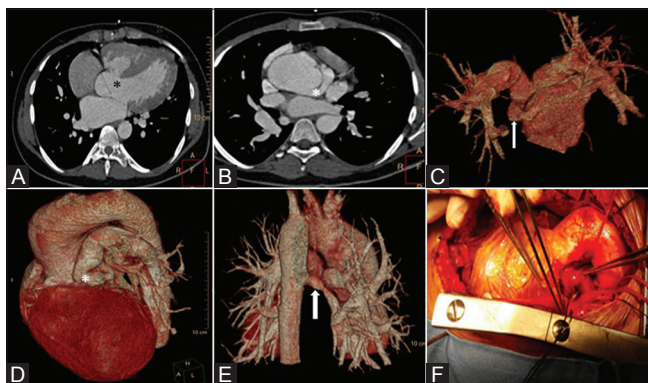
was repaired. VSD repair was then performed with a Dacron patch. Right ventricular muscle was cored out for the placement of a bovine jugular-valved conduit, to which the MPA was then anastomosed. The patient recuperated well and was discharged on the seventh postoperative day. At 1-year follow-up, patient was asymptomatic and echocardiography showed good flow in the LMCA and a functioning pulmonary conduit.

A companion case of a 19-year-old gentleman with PA/VSD [Figure 2A] and a CPAF from the LMCA is depicted on CT angiography [Figure 2B] and Volume Rendered image [Figure 2C]. In this case, the caliber of the CPAF (3.4 mm) and the MPA (10 mm) was smaller than observed in the previous case. Multiple aortopulmonary collaterals (ranging from 5 to 10 mm in diameter) were seen arising from the descending thoracic aorta on both sides [Figure 2D]. This case elegantly demonstrates the interdependence of the size of the CPAF and the number of MAPCAs.

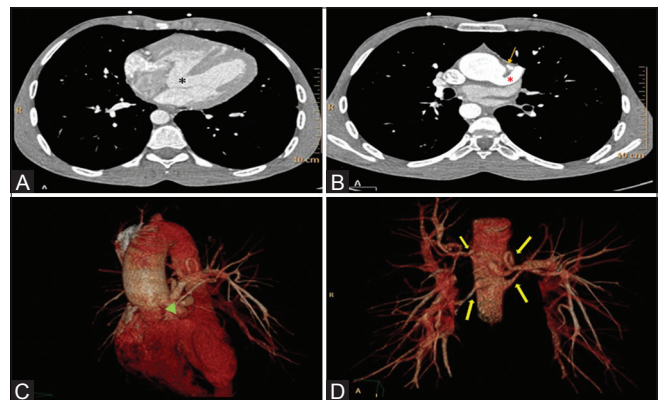
## Discussion

The reported incidence of PA/VSD and MAPCAs is 4.2–7.0/100,000 live births.<sup>[1-3]</sup> The pulmonary blood flow in this condition is derived from systemic circulation commonly via collaterals arising from the thoracic aorta, abdominal aorta, subclavian artery, and its branches.<sup>[4,5]</sup> Occasionally, coronary arteries can be a source of pulmonary blood flow.<sup>[5]</sup> The estimated incidence of CAPAs in such cases ranges from 1.3% to 10%.<sup>[6,7]</sup> To date, 52 cases of PA/VSD with CPAF have been reported in literature. The CPAF involved the LMCA in 34 cases, RCA in 12 cases, a single coronary artery in 5 cases, and both coronary arteries in 2 cases.<sup>[8]</sup>

Amin *et al.*<sup>[7]</sup> hypothesized that a communication between the coronary and pulmonary artery is physiologically and embryologically more similar to a ductus arteriosus than to systemic–pulmonary collaterals as this communicates in



**Figure 1 (A-F):** (A) Axial image demonstrating VSD (asterisk). (B) Shows Dilated LMCA (asterisk). (C-E) VR images showing communication between LMCA and the MPA (arrow in C, asterisk in D) and a single large MAPCA (white arrow). Intra-operative image (F) shows the communication between the LMCA and the MPA



**Figure 2 (A-D):** Axial (A) demonstrates VSD (asterisk). (B) Shows dilated LMCA (asterisk) and a small branch arising from LMCA continuing as MPA (arrow). Volume rendered (C and D) showing communication between the LMCA and MPA (green arrow) and multiple MAPCA's arising from the descending thoracic aorta (yellow arrows)

an antegrade fashion with the central pulmonary arteries. It is conceivable that a coronary-to-pulmonary artery communication with sufficient caliber can become the primary source of pulmonary blood flow in patients with PA/VSD. In this setting, whether such a communication should be referred to as a CAPA or fistula can be put up for debate. CAPA nomenclature is supported by the fact that no clinical evidence of coronary steal is found in the majority of patients with PA/VSD and coronary-pulmonary "fistula."<sup>[18,9]</sup>

In a patient with PA/VSD and MAPCAs, a segment of the lung may be supplied by the true pulmonary arteries, aortopulmonary collaterals (systemic origin), or both. The segment of the lung being supplied by systemic-pulmonary collaterals is subject to systemic arterial pressures, and the MAPCA may gradually undergo stenosis. The goal of unifocalization is to recruit the highest number of lung segments into the pulmonary circulation by anastomosing the MAPCAs to the central pulmonary artery/peripheral native pulmonary arteries/sizeable central collateral, that is, their origins are shifted from the aorta (systemic flow) to a central vessel with pulmonary arterial flow. This allows for the normal perfusion and development of lung segments which up to this point were being subject to systemic arterial pressures. The aim is generally to unifocalize at least one and a half lungs/15 lung segments. Ever since the introduction of the concept of early one staged unifocalization in the surgical management of patients with PA/VSD, accurate delineation of all the sources of pulmonary blood flow has become the most critical step of the preoperative evaluation.<sup>[10]</sup>

The two cases presented here demonstrate the interdependence of the size of the CPAF/CAPA and number of MAPCAs supplying the pulmonary bed. The first case had a larger sized communication from the coronary artery and a single collateral from the aorta. In this case, as a greater part of both the lungs were supplied by the native pulmonary arteries, unifocalization was not deemed necessary. Conversely, in the second case, there was a smaller sized communication from coronary artery and four collaterals from aorta supplying the pulmonary bed. The surgical plan, in this case, would have required a unifocalization of the MAPCAs to recruit as many lung segments as possible to the pulmonary circulation.

The CAPA/CPAF is addressed surgically depending on the distal artery with which it connects. If the distal end of the CAPA is connected to the MPA (as in our case), it is ligated and divided. If the distal end is connected to the right or left pulmonary arteries, it is unifocalized.

Cardiac catheterization, though very accurate in depicting all the possible sources of pulmonary blood flow, is an invasive procedure. With the advent of newer generation MDCT scanners, systemic-pulmonary collaterals can be delineated in a noninvasive manner with the added advantage of

detection of extracardiac anomalies like presence/absence of thymus (Di George Syndrome), tracheobronchial compression, vertebral fusion anomaly/skeletal dysplasia, and renal anomalies. Detection of these extracardiac findings can have a significant bearing on the outcome of the surgery and hence in deciding on surgery. As seen in these cases, CT angiography allowed for the accurate depiction of the CAPA and preoperative prediction of the need of unifocalization. It should be the investigation of choice in the preoperative workup of patients with PA/VSD.

#### Declaration of patient consent

The authors certify that they have obtained all appropriate patient consent forms. In the form the patient(s) has/have given his/her/their consent for his/her/their images and other clinical information to be reported in the journal. The patients understand that their names and initials will not be published and due efforts will be made to conceal their identity, but anonymity cannot be guaranteed.

#### Financial support and sponsorship

Nil.

#### Conflicts of interest

There are no conflicts of interest.

#### References

1. Talner CN. Report of the New England regional infant cardiac program, by Donald C. Fyler, MD, Pediatrics, 1980;65(suppl):375-461. Pediatrics 1998;102:258-9.
2. Hoffman JI, Kaplan S. The incidence of congenital heart disease. J Am Coll Cardiol 2002;39:1890-900.
3. Marelli AJ, Mackie AS, Ionescu-Ittu R, Rahme E, Pilote L. Congenital heart disease in the general population: Changing prevalence and age distribution. Circulation 2007;115:163-72.
4. Reddy VM, Liddicoat JR, Hanley FL. Midline one-stage complete unifocalization and repair of pulmonary atresia with ventricular septal defect and major aortopulmonary collaterals. J Thorac Cardiovasc Surg 1995;109:832-44.
5. Liao PK, Edwards WD, Julsrud PR, Puga FJ, Danielson GK, Feldt RH, *et al.* Pulmonary blood supply in patients with pulmonary atresia and ventricular septal defect. J Am Coll Cardiol 1985;6:1343-50.
6. Sathanandam SK, Loomba RS, Ilbawi MN, Van Bergen AH. Coronary artery-to-pulmonary artery fistula in a case of pulmonary atresia with ventricular septal defect. Pediatr Cardiol 2011;32:1017-22.
7. Amin Z, McElhinney DB, Reddy VM, Moore P, Hanley FL, Teitel DF, *et al.* Coronary to pulmonary artery collaterals in patients with pulmonary atresia and ventricular septal defect. Ann Thorac Surg 2000;70:119-23.
8. Alkhusi N, Al-Radi OO, Ajlan A, Abdelmohsen G, Attia W. Coronary-pulmonary arterial fistula in a neonate with pulmonary atresia-ventricular septal defect and single coronary artery. Echocardiography 2017;34:1536-9.
9. Kaneko Y, Okabe H, Nagata N, Kobayashi J, Murakami A, Takamoto S, *et al.* Pulmonary atresia, ventricular septal defect, and coronary-pulmonary artery fistula. Ann Thorac Surg 2001;71:355-6.
10. Reddy VM, McElhinney DB, Amin Z, Moore P, Parry AJ, Teitel DF, *et al.* Early and intermediate outcomes after repair of pulmonary atresia with ventricular septal defect and major aortopulmonary collateral arteries: Experience with 85 patients. Circulation 2000;101:1826-32.