OPEN

PRS GLOBAL OPEN

ORIGINAL ARTICLE

Hand/Peripheral Nerve

Conduit-assisted Allograft Neurorrhaphy for the Treatment of Intractable Lower Extremity Pain Due to Neuromas-in-continuity

Edgardo Rodriguez-Collazo, DPM
Kaitlyn Laube Ward, DPM

Background: We present a novel technique for the management of intractable lower extremity pain, due to neuromas-in-continuity of two peripheral nerves, through combined neurectomies proximal to the zone of initial injury and subsequent bridging utilizing an allograft-coupled conduit construct.

Methodology: A retrospective chart review of 36 patients (18 women and 18 men) with recalcitrant nerve pain secondary to neuromas-in-continuity of two peripheral nerves following lower extremity trauma was conducted. Subjects underwent superficial peroneal nerve (SPN) to deep peroneal nerve neurorrhaphy (19 patients) or SPN to sural nerve neurorrhaphy (17 patients) proximal to the zone of initial injury. Patient demographics, comorbidities, procedure details, complications, and preoperative and postoperative pain assessments using a visual analog scale were evaluated.

Results: Residual nerve pain from previous lower extremity trauma was included. Analysis of preprocedure and postprocedure visual analog scale scores demonstrated a mean decrease of 7.45 points (mean: pre 8.89, mean: post 1.44). All patients voiced satisfaction with postoperative ambulatory tolerance and pain relief at last follow-up (mean: 30.86 months).

Conclusions: The sequelae of neuromas-in-continuity of the SPN, deep peroneal nerve, and sural nerves were noted to have significantly improved with proximal neurectomy and subsequent bridging utilizing a nerve allograft and conduit construct. We present this coaptation technique as a viable treatment option for reduction in neurogenic pain involving peripheral nerve injury of two dermatome distributions. *(Plast Reconstr Surg Glob Open 2021;9:e3867; doi: 10.1097/GOX.0000000000003867; Published online 2 November 2021.)*

INTRODUCTION

Axonotmesis (Seddon Type II) involves damage to the myelin and the axon, resulting in complete Wallerian degeneration of the distal nerve segment.[16] Regeneration is possible in axonotmesis, as the epineurium and perineurium surrounding the nerve are preserved. Type II nerve injuries represent neuromas-in-continuity. In these injuries, internal degloving of the axon is present and amplitudes cannot normalize past the region of injury.

From the Department of Surgery, AMITA Health St. Joseph Hospital, Chicago, Ill.

Received for publication February 9, 2021; accepted August 16, 2021.

Copyright © 2021 The Authors. Published by Wolters Kluwer Health, Inc. on behalf of The American Society of Plastic Surgeons. This is an open-access article distributed under the terms of the Creative Commons Attribution-Non Commercial-No Derivatives License 4.0 (CCBY-NC-ND), where it is permissible to download and share the work provided it is properly cited. The work cannot be changed in any way or used commercially without permission from the journal.

DOI: 10.1097/GOX.0000000000003867

Traditionally, treatment for neuromas-in-continuity involving sensory or mixed nerves in the distal lower extremity is excision and subsequent repair. If the defect is less than 5 mm, end-to-end nerve coaptation is performed. If the resultant defect is between 5 and 70 mm, allograft repair is performed. Finally, if the defect is greater than 70 mm, autograft-assisted repair is performed.[5,13]

In this study, all injuries were Seddon Type II, affecting two peripheral nerves of the lower extremity (superficial peroneal nerve [SPN] and deep peroneal nerve [DPN] or SPN and sural), resulting in intractable pain within two dermatome distributions. To our knowledge, this is the first study identifying subjects with neuromas-in-continuity effecting two dermatome distributions.

The purpose of this study was to evaluate the efficacy of neurorrhaphy proximal to the zone of injury for neuromas-in-continuity of two peripheral nerves following traumatic injuries to the lower extremity. We present 36

Disclosure: *Dr. Rodriguez-Collazo is a paid consultant for Orthofix, Integra, and Isto Biologics. He is a nonpaid presenter for Axogen Speakers Bureau. The other author has no financial interest to declare.*

patients who underwent SPN nerve coaptation to DPN or SPN to sural nerve with allograft-coupled conduit repair.

METHODS

Patient Selection

After approval from the institutional review board and waiver of informed consent, a retrospective medical chart review was conducted on patients (>18 years old). All patients included in our study were referred to the primary surgeon's private practice with a history of prior trauma resulting in intractable neurogenic pain to the lower third of the affected lower extremity (zone of injury) in two dermatome distributions. Injuries included ankle fractures (10), metatarsal fractures (three), ankle sprains (10), calcaneal fractures (five), contusions (five), distal tibial intraarticular fracture (one), peroneal rupture (one), and Lisfranc fracture (one). All patients with a previous history of fracture had been treated via surgical intervention and osseous union was evidenced via radiographs before referral to the primary surgeon's practice. Soft-tissue compromise in the form of previous incisional scarring, adhesions, decreased skin turgor, and/or muscle atrophy within the zone of injury was noted in all cases. Previous conservative treatment included one or a combination of nonsteroidal anti-inflammatory drugs (NSAIDs), topical anesthetics, physical therapy, neuropathic pain medication, and narcotics, which were unsuccessful. No patient had prior nerve surgery.

Before surgical intervention, a thorough clinical and physical examination was conducted. All patients experienced localized pain with percussion and generalized pain to the dermatome distribution of the SPN, DPN, and/or sural nerves. Preoperative blocks with corresponding pain relief were used as a confirmatory test for nerve injuries. As part of the preoperative workup, all patients were seen by a neurologist who performed nerve conduction velocity and electromyography testing. In all cases, there was over 50% decrease in axon amplitudes as well as significant reduction in conduction velocities of two nerves. No muscle dysfunction or abnormalities were noted via electromyography. Finally, all patients were counseled that the goal of surgery was pain relief and not improvement of sensation. In fact, postoperatively some degree of numbness was to be expected.

We modified the previously suggested treatment recommendations for type II injuries, so that the procedure was performed proximal to the zone of initial injury, in an area without soft-tissue compromise and adequate cushioning. In doing so, both neuromas-in-continuity were bypassed and never actually identified or excised. We hypothesized that creation of this nerve bridge construct, proximal to neuroma locations, would allow for proximal neuronal death within the allograft and distal neuronal death via Wallerian degeneration, thus eliminating noxious stimulation and aberrant axon formation.

Operative Technique

Surgery was performed with the patient under general anesthesia without a central or peripheral nerve block. No tourniquet or muscle relaxing agents were utilized as nerve stimulation was required to distinguish the sensory and motor components. Hemostasis was achieved with electrocautery and hydrogen peroxide. The procedure was performed under surgical loupe magnification (3.5×–5×) for nerve dissection and reconstruction. When available, operative microscopy was utilized as well for the repair portion of the procedure. Neurorrhaphy was performed proximal to the zone of injury due to the extensive fibrosis and scar tissue that was common from previous trauma. Additionally, this facilitated more straightforward dissection and allowed neuronal tissue to glide without tension in a deeper plane of cushioning muscle. Care was taken to ensure all repairs were completed distal to the motor points for the anterior and lateral compartment muscles via intraoperative nerve stimulation to limit postoperative muscular deficits.

An incision was placed overlying the course of the SPN at the level of the midtibia. The nerve was identified and an external neurolysis was performed to have sufficient mobility for the transfer. The SPN was then transected after exiting the peroneus brevis. Healthy nerve tissue was evidenced by normal fascicular anatomy and neuronal bleeding. Dissection was continued until the DPN (anteriorly based) or sural nerve (posteriorly based) was identified, depending on which repair was to be completed (Figs. 1 and 2). After identification of the secondary nerve, subsequent external neurolysis and neurectomy were performed. Again, healthy nerve tissue was clinically evidenced by normal fascicular anatomy and healthy neuronal bleeding. Transection of the DPN was performed as far below the nerve's motor checkpoint as possible as noted with a nerve stimulator to prevent motor function impairment.

At this time, a nerve allograft (Advance nerve graft; AxoGen, Alachua, Fla.) was prepared by incorporating both ends with 9-0 nonabsorbable monofilament suture to a porcine submucosa nerve conduit of suitable caliber (AxoGard nerve connector; AxoGen) for both the SPN and DPN or sural nerve under magnification. An allograft was utilized to eliminate donor site morbidity and the need for additional procedure time. In the case of SPN to DPN repair, 30-mm length allograft was used. In SPN to sural repair, 70 mm length allograft was used. The required thickness was 3–4 or 4–5 mm depending on the caliber of the native nerve. The conduit diameter was just slightly larger than the allograft and native nerve ends.

Takeaways

Question: To evaluate the efficacy of neurorrhaphy proximal to the zone of injury for neuromas-in-continuity of two peripheral nerves following traumatic injuries to the lower extremity.

Findings: Analysis of pre- and postprocedure VAS scores demonstrated a mean decrease of 7.45 points (mean: pre- 8.89, mean: post- 1.44). All patients voiced satisfaction with postoperative ambulatory tolerance and pain relief at last follow-up (mean: 30.86 months).

Meaning: This technique is a viable and promising treatment option.

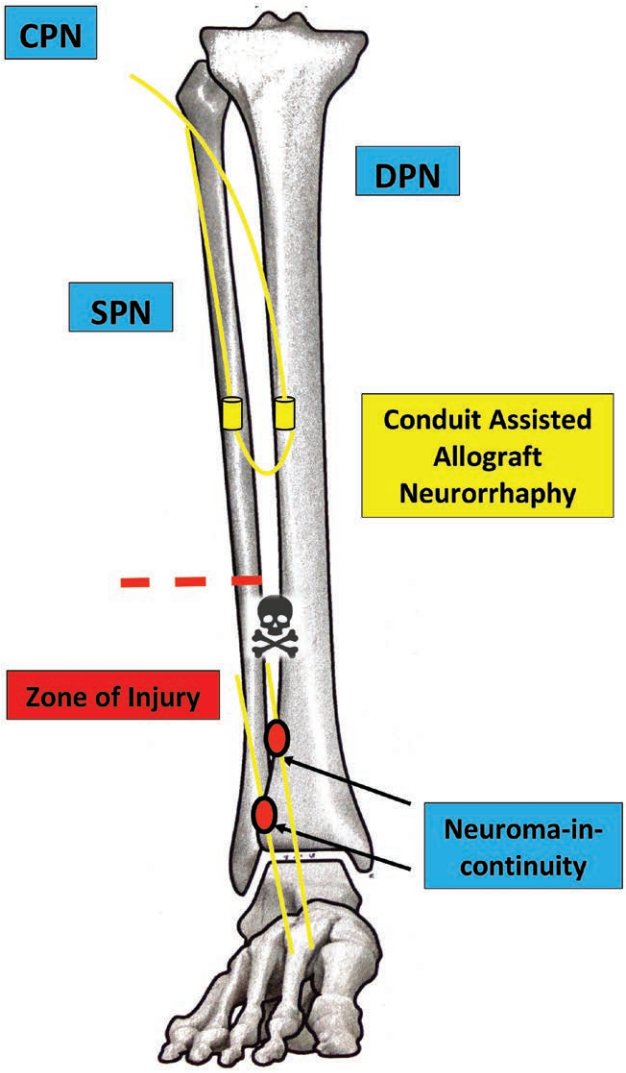

Fig. 1. SPN to DPN neurorrhaphy performed proximal to the zone of injury and concurrent neuromas-in-continuity.

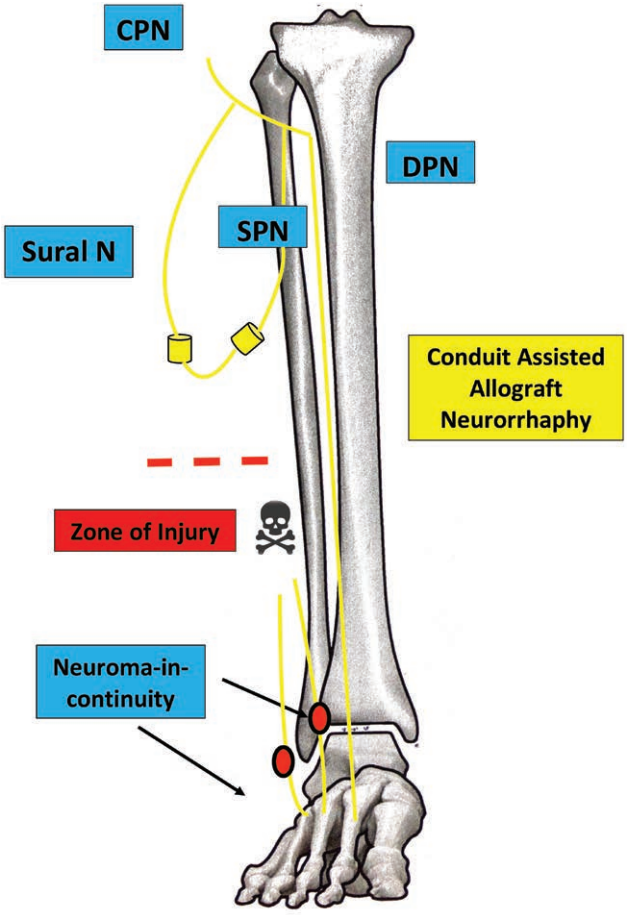

Fig. 2. SPN to sural neurorrhaphy performed proximal to the zone of injury and concurrent neuromas-in-continuity.

The conduit-allograft-conduit construct was then coupled with the free ends of the SPN and DPN or sural nerve and sutured together with 9-0 nonabsorbable monofilament suture at the 6-o'clock and 12-o'clock positions. It was imperative that the conduit-allograft-conduit bridge construct was created with an adequate amount of slack, under no tension to prevent repair site disruption. Within the conduits, the native nerve was positioned just shy of contact with the allograft, a distance of approximately 3 mm (Fig. 3).

All nerve coaptation sites were augmented with bone marrow aspirate (obtained from the proximal tibia) and platelet rich plasma for autologous stem cell implantation. Each patient underwent primary skin closure and a semi-compressive sterile dressing, with an elastic bandage as the top cover.

Postoperative Course

Postoperatively, patients were admitted for observation. They were encouraged to perform ankle dorsiflexion and plantarflexion and knee ROM to prevent fibrosis at the surgical site immediately. Physical therapy assisted with non-weightbearing gait training. Patients were instructed to elevate the surgical limb at the level of the heart as much as possible. Postoperative pain management consisted of a PCA pump, which was discontinued after 24 hours. Following this, all narcotics were eliminated, and a trimodal therapy approach including gabapentin 100–300 mg TID, tramadol (50 mg BID), and Tylenol (625 mg TID) was utilized. Patients were discharged when they were comfortable and could ambulate safely with the use of proper durable medical equipment. Upon suture or staple removal, approximately 2–3 weeks postoperatively, patients were encouraged to weight bear as tolerated in a fracture boot. Patients transitioned to normal shoe gear as tolerated at 4–6 weeks postoperatively.

RESULTS

Of the 36 patients, 18 were women and 18 were men; the mean patient age was 49 (range 30–76) years. No patients were diabetic or smoked. Residual nerve pain from the following preoperative injuries was included: five calcaneal fractures, 10 ankle sprains, 10 ankle fractures, three metatarsal fractures, five contusions, one Lisfranc fracture, one

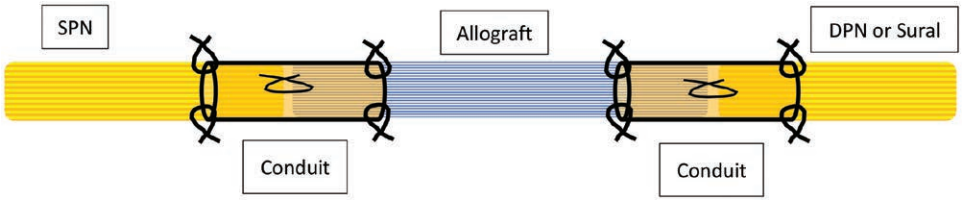

Fig. 3. Native nerve was positioned just shy of contact with the allograft, a distance of approximately 3 mm.

peroneal tendon rupture, and one distal tibial intraarticular fracture. All neuromas were type II. Nineteen patients underwent SPN to DPN neurorrhaphy with conduit and allograft. Seventeen patients underwent SPN to sural neurorrhaphy with conduit and allograft. No surgical site complications such as seroma, hematoma, infection, deep vein thrombosis, or incisional breakdown developed.

The mean final follow-up period was 30.86 (range 14–57) months. The mean preoperative visual analog scale (VAS) pain score was 8.89 (range 7–10). The mean postoperative VAS pain score was 1.44 (range 0–3). Analysis of preprocedure and postprocedure VAS scores demonstrated a mean decrease of 7.45 points (mean: pre 8.89, mean: post 1.44), which was statistically significant. All patients voiced satisfaction with postoperative ambulatory tolerance and pain relief at the last follow-up.

DISCUSSION

Recalcitrant neuromas are an inevitable pathology that lower extremity surgeons must be equipped to treat due to their devastating morbidity. Patients with significant nerve injuries are at an increased risk of functional deficits, socioeconomic debilitation, and narcotic abuse.[1,4,9,12,17]

As such, finding reproducible, durable procedures to treat these pathologies is paramount. The literature presents a variety of treatment options ranging from pharmacological therapy to neurostimulation, to surgical intervention.[5,10,13] Surgical intervention is comprised of two procedural groups, passive/ablative and active/reconstructive. Passive or ablative procedures include neurectomies, excision and implantation, and nerve relocation with grafting. Ablative procedures, while more commonly performed, often result in a recurrence of symptoms as they do not appropriately address the pathologic process.[10] Due to the shortcomings of passive procedures, a recent trend toward active/reconstructive procedures ("end-to-side" neurorrhaphy, targeted muscle reinnervation, regenerative peripheral nerve interfaces, and vascularized regenerative peripheral nerve interfaces) have been reported.[5–7,10,13,17]

In 2016, Souza et al[17] described the use of allograft nerve transfer for type II (neuromas-in-continuity) and type III (end neuromas) injuries of SPN, DPN, sural, lateral plantar, and digital nerve injuries. In their study, 22 patients experienced a mean decrease in pain of 2.6, utilizing the mean ordinal pain score at an average of 15.5 months postoperatively. Their results also demonstrated a 24%–31% decrease in the Patient-Reported Outcome Measurement Information System scale. All values were statistically significant.[17]

In 2017, Bibbo and Rodriguez[2] described the use of allograft transfers to treat recalcitrant lower extremity type II (neuromas-in-continuity) and type III (end neuromas). In their study, four patients experienced a mean VAS improvement from 9.5 to 1.25 at 26 months follow-up.[2] Unlike the present study, both type II and type III neuromas were treated. Additionally, the nerve reconstructive procedures were performed within the zone of injury.

In 2018, Bibbo et al[3] first described their use of allograft nerve transfer for type II (neuromas-in-continuity) injuries of SPN after ankle arthrodesis. In their study, 11 patients underwent SPN to DPN nerve transfer with allograft conduit repair proximal to the zone of injury. A mean VAS improvement from 7.9 to 2.45 at 31 months follow-up was noted.[3] Their technique was very similar to the one described in this article; however, the SPN was the only nerve affected. Unlike the present study, preoperative symptoms were only elicited along the SPN dermatome, and not two dermatomes, that is, only one neuroma-in-continuity was present in the 11 patients identified.

In the current study, multiple key advancements have been made as compared to previous studies. First is the fact that only one neuroma was present in previous studies and said neuroma was addressed within the zone of initial injury with the exception of Bibbo et al's work in 2018. In our technique, we are able to address two neuromas, affecting two dermatome distributions. Creation of this bridge construct proximal to the neuroma locations allowed for neuronal death proximally within the allograft and distally via Wallerian degeneration, thus eliminating noxious stimulation. Additionally, as previously stated, nerve coaptation was performed proximal to the zone of injury due to the extensive fibrosis and scar tissue that was common from previous trauma, facilitating more straightforward dissection. Also, this allows for neuronal tissue to glide without tension in a deeper plane of cushioning muscle. As previously mentioned, in most cases, 3.5–5× loupe magnification was used to perform neurolysis and repair was completed with operative microscopy; however, a smaller number were performed when the operative microscope was not available and loupe magnification was sufficient. Therefore, it is the surgeon's preference for which degree of magnification to utilize.

It should be noted that at the level of the midtibia (area of neurectomy), the SPN, DPN, and sural nerves have sensory and motor fibers; however, all three are largely sensory. The desired result of this procedure was to eradicate sensation due to intractable pain. The DPN has the most motor fibers at the midtibia; however, a neurectomy at this level causes denervation of the extensor digitorum brevis, which we consider negligible given the severity of patient's

Table 1. Procedure Results Including Patient Sex, Age, Neuroma Etiology, Preoperative and Postoperative VAS Scores, and Length of Follow-up

Superficial Peroneal Nerve to Deep Peroneal Nerve Conduit Allograft-assisted Transfer						
Patient	**Sex**	**Age (yrs)**	**Neuroma Etiology**	**Preoperative VAS**	**Final Follow-up VAS**	**Follow-up Time (mo)**
1	M	62	Ankle fracture	9	2	32
2	F	41	Ankle sprain	9	3	27
3	M	48	Ankle sprain	9	1	15
4	F	73	Fifth metatarsal fracture	10	0	41
5	F	54	Ankle sprain	7	3	31
6	F	53	Calcaneal fracture	10	3	47
7	M	39	Ankle fracture	9	3	23
8	F	31	Contusion	8	1	14
9	F	36	Ankle sprain	9	1	19
10	M	61	Third metatarsal fracture	8	3	20
11	F	44	Contusion	9	1	17
12	M	38	Ankle fracture	9	0	34
13	F	41	Ankle sprain	7	1	44
14	F	30	Ankle fracture	7	0	48
15	F	69	Ankle fracture	10	2	15
16	F	38	Ankle fracture	9	0	17
17	M	73	Ankle sprain	10	1	43
18	M	45	Distal tibial intraarticular fracture	10	1	50
19	M	52	Contusion	10	0	48
Superficial Peroneal Nerve to Sural Nerve Conduit Allograft-assisted Transfer						
Patient	**Sex**	**Age (yrs)**	**Neuroma Etiology**	**Preoperative VAS**	**Final Follow-up VAS**	**Follow-up Time (mo)**
20	M	37	Calcaneal fracture	8	3	18
21	F	33	Ankle fracture	8	0	52
22	F	69	Ankle sprain	7	1	22
23	M	67	Ankle sprain	10	2	23
24	M	41	Calcaneal fracture	8	1	33
25	M	73	Contusion	10	2	25
26	M	50	Ankle fracture	10	2	37
27	M	65	Lis franc fracture	8	2	43
28	F	44	Ankle fracture	9	3	22
29	M	39	Contusion	10	2	15
30	M	55	Peroneal tendon rupture	9	2	23
31	F	38	Ankle sprain	9	2	18
32	M	52	Ankle sprain	10	2	18
33	M	43	Fifth metatarsal fracture	9	1	48
34	F	33	Calcaneal fracture	8	1	18
35	F	34	Calcaneal fracture	8	0	57
36	F	63	Ankle fracture	10	0	54
		Average age = 49.0 yrs		Average preoperative VAS = 8.89	Average final follow-up VAS = 1.44	Average follow-up time = 30.86 mo

preoperative pain levels. Many of the included patients were contemplating proximal amputation. Moreover, a painful limb is a nonfunctional limb; therefore, sacrificing function of a small foot muscle is a trivial cost to obtain pain relief and rehab potential.

Previous studies do not mention if bone marrow aspirate, platelet rich plasma, and/or conduits were utilized in all cases. We find that these factors are vital for augmentation of the neurorrhaphy site to facilitate reliable, predictable outcomes. The literature clearly states that bone marrow aspirate and platelet rich plasma promote angiogenesis and neovascularization and decrease adhesion formation.[12] Moreover, pain reduction has been reported as a result of interfering with local interleukins. Finally, Ducic et al[8] clearly defined the advantages of connector-assisted coaptation in their 2017 review. Such benefits include offsetting tension and reducing suture irritation at the repair site, ensuring alignment of the nerve ends, protecting the construct, and forcing linear axonal growth, thereby eliminating stump neuroma formation. These additives are therefore mainstays in our protocol.[8]

Additionally, many of the patients included in this study were long standing opioid users due to intractable pain. By rewiring the nerves and essentially closing the circuit, this noxious stimulus was eliminated and, in all instances, pain was controlled with the trimodal approach previously described. This virtually eliminated the need for continued opioid use, reducing the risk of harmful side effects such as dependence and abuse, which result in 40,000 deaths per year.[15]

The main limitation of the present study was the small sample size. Another limitation was the nonstandardized completion of the VAS questionnaire. Standardized completion of the questionnaire would have allowed for a more systematic monitoring of the patient's postoperative course. Despite these limitations, the present study's follow-up period of 30.86 months demonstrates the consistent, reliable outcomes of our technique, which is very promising.

In conclusion, nerve allograft conduit-assisted coaptation of SPN to DPN or SPN to sural nerve, proximal the zone of initial injury, has been shown to effectively treat

intractable nerve pain following lower extremity trauma. This technique shows promise for management of neuromas-in-continuity resulting in predictable, significant, and long-lasting pain relief. Further studies are needed to address the limitations listed above to further validate its efficacy.

Kaitlyn Laube Ward, DPM
709 S. Harbor City Blvd.
Suite 100
Melbourne, FL 32901
E-mail: Kaitlynlward@gmail.com

REFERENCES

1. Alexandridis G, Gunning AC, Leenen LP. Patient-reported health-related quality of life after a displaced intra-articular calcaneal fracture: a systematic review. *World J Emerg Surg.* 2015;10:62.
2. Bibbo C, Rodriguez-Colazzo E. Nerve transfer with entubulated nerve allograft transfers to treat recalcitrant lower extremity neuromas. *J Foot Ankle Surg.* 2017;56:82–86.
3. Bibbo C, Rodrigues-Colazzo E, Finzen AG. Superficial peroneal nerve to deep peroneal nerve transfer with allograft conduit for neuroma in continuity. *J Foot Ankle Surg.* 2018;57:514–517.
4. Buckley R, Brauer C, Donaldson C, et al. An economic evaluation of operative compared with nonoperative management of displaced intra-articular calcaneal fractures. *J Bone Joint Surg Am.* 2005;87:2741–2749.
5. Dellon AL, Aszmann OC. Treatment of superficial and deep peroneal neuromas by resection and translocation of the nerves into the anterolateral compartment. *Foot Ankle Int.* 1998;19:300–303.
6. Dellon AL, Mackinnon SE, Pestronk A. Implantation of sensory nerve into muscle: preliminary clinical and experimental observations on neuroma formation. *Ann Plast Surg.* 1984;12:30–40.
7. Dellon AL, Mackinnon SE. Treatment of the painful neuroma by neuroma resection and muscle implantation. *Plast Reconstr Surg.* 1986;77:427–438.
8. Ducic I, Safa B, DeVinney E. Refinements of nerve repair with connector-assisted coaptation. *Microsurgery.* 2017;27:256–263.
9. Ditty B, Omar N, Rozzelle C. *Nerves and Nerve Injuries Vol 2: Pain, Treatment, Injury, Disease and Future Directions.* London: Academic Press. 2015:373–381.
10. Eberlin KR, Ducic I. Surgical algorithm for neuroma management: a changing treatment paradigm. *Plast Reconstr Surg Glob Open.* 2018;6:e1952.
11. Gaiovych I, Savosko S, Labunets I, et al. Sciatic nerve regeneration after autografting and application of the bone marrow aspirate concentration. *Georgian Med News.* 2019:145–152.
12. Haugsdal J, Dawson J, Phisitkul P. Nerve injury and pain after operative repair of calcaneal fractures: a literature review. *Iowa Orthop J.* 2013;33:202–207.
13. Hoeft D, Spingola H, Rodriguez-Collazo E. Double axonal crush, transection, and implantation of deep peroneal nerve for intractable pain. *Int J Orthop Surg.* 2019;2:23–28.
14. Phisitkul P, Dawson J, Haugsdal J. Nerve injury and pain after operative repair of calcaneal fractures: a literature review. *Iowa Orthop J.* 2013;33:202–207.
15. Public Affairs. What is the U.S. opioid epidemic? 2019. HHS.gov. Available at https://Plus.google.com/+HHS. Available at www.hhs.gov/opioids/about-the-epidemic/index.html. Accessed February 14, 2021.
16. Seddon H. Three types of nerve injury. *Brain.* 1943;66:237–288.
17. Souza JM, Purnell CA, Cheesborough JE, et al. Treatment of foot and ankle neuroma pain with processed nerve allografts. *Foot Ankle Int.* 2016;37:1098–1105.