

## OPEN

# Pulmonary Allograft Versus Host Disease

David W. Dai, MD,<sup>1</sup> Bryan Garber, MD,<sup>2</sup> S. Samuel Weigt, MD,<sup>2</sup> Scott Worswick, MD,<sup>3</sup> Bernard M. Kubak, MD, PhD,<sup>4</sup> Joseph P. Lynch 3rd, MD,<sup>2</sup> Michael Y. Shino, MD,<sup>2</sup> Ariss DerHovanesian, MD,<sup>2</sup> Rajan Saggarr, MD,<sup>2</sup> David J. Ross, MD,<sup>2</sup> and David M. Sayah, MD, PhD<sup>2</sup>

**G**raft-versus-host disease (GVHD) is an uncommon phenomenon in solid-organ transplant (SOT) recipients, first reported in a liver transplant patient in 1988.<sup>1</sup> GVHD associated with lung transplantation is particularly rare and associated with poor outcomes, with mortality rates in the published literature exceeding 80%.<sup>2-12</sup>

## CASE DESCRIPTION

A 52-year-old woman underwent bilateral lung transplantation for rheumatoid arthritis–associated interstitial lung disease. Her pretransplant course was notable for immunosuppressive therapy for rheumatoid arthritis with adalimumab, azathioprine, and prednisone. She exhibited extensive pretransplant allosensitization, including 3 low-intensity donor-specific antihuman leukocyte antigen antibodies predicted to react with the allograft, as well as a positive flow cytometric crossmatch at the time of transplant. As a result, her posttransplant induction immunosuppression included rabbit antithymocyte globulin (ATG), plasmapheresis, intravenous (IV) immunoglobulin, and rituximab. Maintenance immunosuppression consisted of tacrolimus, mycophenolate mofetil (MMF), prednisone, and monthly IV immunoglobulin. Antimicrobial

prophylaxis included atovaquone, valganciclovir, and posaconazole. She was discharged from the hospital on posttransplant day 25.

She was rehospitalized on posttransplant day 41 with fever, shortness of breath, and cough. Extensive evaluation revealed no evidence of infection or allograft rejection. Leukopenia developed and persisted despite stopping mycophenolate and valganciclovir.

On posttransplant day 62, while still hospitalized, she developed an erythematous maculopapular rash predominantly on the palms, soles, flanks and abdomen (Figure 1). Skin biopsy revealed interface dermatitis with perivascular and interstitial inflammation with rare eosinophils. She simultaneously developed an elevated serum alkaline phosphatase, transaminitis, and conjugated hyperbilirubinemia with total bilirubin peaking at 17 mg/dL. Ultrasound and magnetic resonance imaging of the liver were unremarkable. Transjugular liver biopsy revealed patchy nonzonal hepatocellular necrosis with focal bile duct injury, no cholestasis or portal inflammation, and negative viral studies.

On posttransplant day 76, a peripheral blood short tandem repeat (STR) study revealed that 58.1% of her circulating lymphocytes were derived from the lung allograft donor. A diagnosis of acute GVHD was made, and she was treated with high-dose corticosteroid therapy (methylprednisolone 500 mg IV daily for 3 days, followed by prednisone 40 mg daily for 1 month) with rapid resolution of her symptoms

Received 1 September 2017. Revision requested 29 September 2017.

Accepted 2 October 2017.

<sup>1</sup> Department of Medicine, David Geffen School of Medicine at UCLA, Los Angeles, CA.

<sup>2</sup> Division of Pulmonary and Critical Care Medicine, Department of Medicine, David Geffen School of Medicine at UCLA, Los Angeles, CA.

<sup>3</sup> Department of Dermatology, David Geffen School of Medicine at UCLA, Los Angeles, CA.

<sup>4</sup> Division of Infectious Diseases, Department of Medicine, David Geffen School of Medicine at UCLA, Los Angeles, CA.

The authors declare no funding or conflicts of interest.

D.W.D., B.G., S.S.W., S.W., B.M.K., J.P.L. 3rd., M.Y.S., A.D., R.S., D.J.R., and D.M.S. participated in the writing of the article.

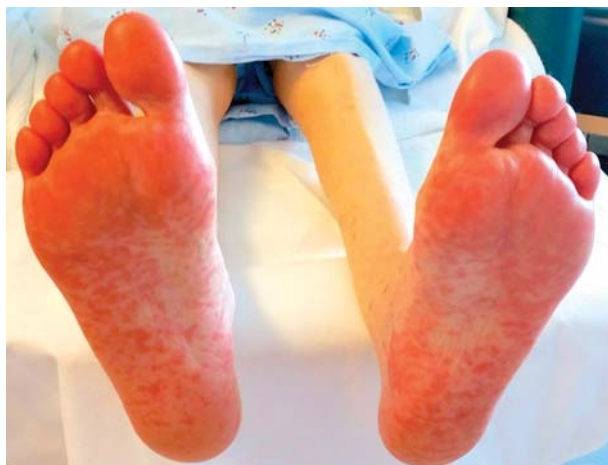Correspondence: David W. Dai, MD, UCLA Department of Internal Medicine, 757 Westwood Plaza, Suite 7501, Los Angeles, CA 90095. (ddai@mednet.ucla.edu).

Copyright © 2017 The Author(s). Transplantation Direct. Published by Wolters Kluwer Health, Inc. This is an open-access article distributed under the terms of the Creative Commons Attribution-Non Commercial-No Derivatives License 4.0 (CCBY-NC-ND), where it is permissible to download and share the work provided it is properly cited. The work cannot be changed in any way or used commercially without permission from the journal.

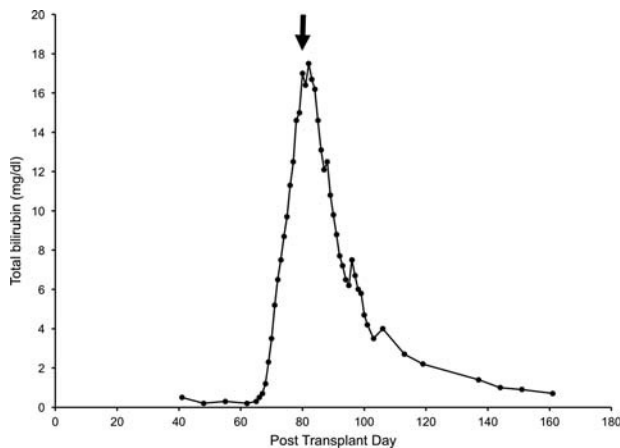
ISSN: 2373-8731

Transplantation Direct 2017;3: e333; doi: 10.1097/TXD.0000000000000749.

Published online 20 November, 2017.



**FIGURE 1.** A macular rash on bilateral soles.



**FIGURE 2.** Bilirubin trend posttransplantation. Arrow indicates initiation of high dose corticosteroids (posttransplant day 80).

and laboratory abnormalities (Figure 2). Prednisone was tapered over the next 3 months to 10 mg/day, tacrolimus was continued and mycophenolate was not restarted. A

repeat STR study 11 months posttransplant showed 1.1% circulating donor-derived lymphocytes. She remains well, without recurrent GVHD, 24 months after transplant.

## DISCUSSION

The requirements for developing GVHD described by Billingham in 1966 include the following: a graft must contain immunologically competent cells, the recipient must express tissue antigens not present in the donor, and the recipient must be incapable of mounting an effective immune response to destroy the transplanted cells.<sup>13</sup> The pathophysiology of GVHD involves allorecognition by passenger T lymphocytes from the allograft, leading to activation of these donor lymphocytes which then injure recipient tissues, often with skin, liver, or gastrointestinal tract involvement.<sup>14</sup> Among SOT recipients, small bowel recipients have the highest risk of GVHD, with an incidence of approximately 5% to 10%.<sup>15</sup> By comparison, GVHD in lung transplant recipients is extremely rare, with a literature search revealing only 8 previously reported cases in lung

**TABLE 1.**

### Reported cases of GVHD after lung transplantation with diagnosis, treatment and outcomes

Author	Age/Sex	Transplant	Diagnosis/treatment	Outcome
Hunt, 1993 <sup>6</sup>	15/M	Heart-lung transplant for congenital heart disease, and pulmonary hypertension	Diagnosed POD 20-39. Cessation of azathioprine, steroids continued.	Death, POD 59, sepsis.
Pfizzmann et al, 1997 <sup>8</sup>	28/F	Heart-lung transplant for congenital heart disease.	Diagnosed POD 10. ATG, high-dose steroids, cyclosporine and azathioprine.	Death, POD 34 due to intracerebral bleeding from bone marrow failure.
Chau et al, 1997 <sup>4</sup>	37/F	Heart-lung transplant for congenital heart disease.	Diagnosed POD 15-21. Cessation azathioprine. Continued steroids.	Death after POD > 28, from sepsis, DIC, gastrointestinal bleeding.
Luckraz et al, 2003 <sup>7</sup>	31/F	Heart-lung transplant for cystic fibrosis.	Diagnosed POD 33-40, treated with steroids, basiliximab, alemtuzumab and G-CSF.	Death POD 87 because of pulmonary hemorrhage.
	43/M	Heart-lung transplant for sarcoidosis.	Diagnosed POD 30, treated with steroids and G-CSF.	Death on POD 65 because of multiorgan failure.
	49/M	Heart-lung transplant for pulmonary sarcoidosis and cardiomyopathy.	Diagnosed POD 160, treated with steroids, G-CSF, ATG.	Death on POD 190, sepsis.
	52/F	Single lung transplant.	Diagnosed POD 113. Azathioprine changed to MMF, started on steroids, G-CSF, and basiliximab.	Death on POD 171, sepsis.
Smith et al, 2006 <sup>10</sup>	57/M	Single lung transplant for interstitial pneumonitis with pulmonary fibrosis.	Diagnosed POD 39-53, continued immunosuppression, started G-CSF.	Death on POD 64, sepsis.
Assi et al, 2006 <sup>2</sup>	25/M	Bilateral lung transplant for primary pulmonary hypertension	Diagnosed POD 17, treated with increased prednisone dose.	Alive, last follow-up 1 y after transplant.
Pavenski et al, 2008 <sup>12</sup>	35/F	Bilateral lung transplant for lymphangioid leiomyomatosis	Diagnosed POD 72, treated with steroids, ATG, tacrolimus	Death on POD 116, sepsis from bone marrow failure.
Worel et al, 2008 <sup>11</sup>	52/F	Single lung transplant for chronic obstructive pulmonary disease	Diagnosed POD 77, treated with high-dose steroids, extracorporeal photopheresis.	Death on POD 99 from multiorgan failure
Fossi et al, 2009 <sup>5</sup>	31/M	Bilateral lung transplant for primary ciliary dyskinesia	Diagnosed POD 38, treated with basiliximab, steroids, extracorporeal photopheresis.	Alive, last follow-up 19 mo after transplant.
Santos et al, 2014 <sup>9</sup>	22/F	Bilateral lung transplant for bronchiectasis	Diagnosed POD >113, treated with high-dose steroids.	Death ~ POD 180 from sepsis (aspergillus and enterococcus)
Ataya et al, 2016 <sup>3</sup>	48/M	Bilateral lung transplant for sarcoidosis	Diagnosed POD 84, treated with high-dose steroids, ATG, G-CSF.	Death on POD 163 from septic shock and multiorgan failure.
Current case	52/F	Bilateral lung transplant for rheumatoid arthritis-associated interstitial lung disease	Diagnosed POD 76, treated with high-dose steroids.	Alive, last follow-up 24 mo after transplant.

Adapted with permission from Pavenski et al.<sup>12</sup>

G-CSF, granulocyte colony-stimulating factor; POD, postoperative day; F, female; M, male; DIC, disseminated intravascular coagulation.

recipients and 6 additional cases after combined heart-lung transplantation.

Donor cells can be detected in the blood and tissue of allograft recipients years after SOT.<sup>16</sup> This chimeric state between recipient and donor leukocytes has been postulated to mitigate rejection by establishing a state of hyporeactivity against or tolerance to the transplanted organ.<sup>17</sup> However, when a high fraction of allogeneic donor lymphocytes are persistently present, acute GVHD can develop.<sup>18</sup> In our patient, we postulate that aggressive immunosuppression, both before and immediately after transplantation, may have allowed the engraftment of passenger lymphocytes and the development of GVHD. Another potential risk factor includes the age of the donor and recipient; in the liver transplant population, older recipients matched with younger donors are at higher risk for GVHD.<sup>19</sup> Notably, our recipient was 52 years old, whereas the donor was 27 years old.

Clinical manifestations of GVHD after SOT include fever, skin rash, diarrhea, liver function abnormalities, and bone marrow suppression.<sup>1</sup> Given that these nonspecific symptoms are commonly encountered in SOT recipients due to infection or medication side effects, the diagnosis of GVHD requires a high index of suspicion. STR-based chimerism assays of peripheral blood, in conjunction with a clinical syndrome consistent with GVHD, have generally been used to confirm the diagnosis of GVHD in SOT recipients.<sup>20</sup>

There is no consensus on treatment for GVHD after SOT. In case reports, therapy has been extrapolated from acute GVHD in hematopoietic stem cell transplant recipients, where corticosteroids are the first-line therapy. Still, 50% of hematopoietic stem cell transplant GVHD cases may be refractory to steroids<sup>21</sup> and alternative therapies including ATG,<sup>22</sup> alemtuzumab,<sup>23</sup> anti-interleukin 2 agents,<sup>24</sup> anti-TNF antibodies,<sup>25</sup> extracorporeal photopheresis,<sup>26</sup> MMF,<sup>27</sup> and sirolimus,<sup>28</sup> have been explored. One alternative approach to management of SOT GVHD, was attempted by Chinnakotla and colleagues<sup>29</sup> who withdrew immunosuppression in three cases of GVHD after liver transplantation. The rationale for this approach was to promote the recovery of the recipient immune system, thereby allowing recipient immune cells to clear the injurious donor lymphocytes. In this series, 2 of the 3 patients recovered rapidly, whereas the third patient progressed to severe GVHD and died. Given the markedly different and conflicting strategies for treating GVHD after SOT, more studies are needed to clarify the optimal approach.

To better understand GVHD after lung transplantation, we conducted a literature search and identified 11 publications documenting 14 cases of GVHD after lung transplantation. In this population, GVHD was associated with a high mortality rate, with only 2 of 14 previously reported cases surviving (Table 1). In most cases, as in the case presented here, there was a delay in diagnosis, with the presenting symptoms of rash, transaminitis, or leukopenia initially attributed to drug reaction. This frequent delay in diagnosis may contribute to the observed mortality. In the previously reported cases, many patients died of complications from marrow failure, presumably a result of progressive GVHD despite aggressive immunosuppressive therapy.

GVHD is an extremely rare and often fatal complication of lung transplantation. Diagnosis is challenging because

the clinical findings often mimic those of more common infectious and pharmacologic complications in the posttransplant period. Palmoplantar involvement of rash can be suggestive of a diagnosis of GVHD, but is not pathognomonic. A chimerism study can aid in identifying a suspected case of GVHD by detecting an elevated percentage of circulating donor lymphocytes.

## REFERENCES

- Burdick JF, Vogelsang GB, Smith WJ, et al. Severe graft-versus-host disease in a liver-transplant recipient. *N Engl J Med*. 1988;318:689–691.
- Assi MA, Pulido JS, Peters SG, et al. Graft-vs.-host disease in lung and other solid organ transplant recipients. *Clin Transplant*. 2007; 21:1–6.
- Ataya A, Biswas A, Chandrashekar S, et al. A 48-year-old man with leukopenia, jaundice, and skin rash after lung transplantation. *Chest*. 2016; 150:e167–e170.
- Chau EM, Lee J, Yew WW, et al. Mediastinal irradiation for graft-versus-host disease in a heart-lung transplant recipient. *J Heart Lung Transplant*. 1997;16:974–979.
- Fossi A, Voltolini L, Filippi R, et al. Severe acute graft versus host disease after lung transplant: report of a case successfully treated with high dose corticosteroids. *J Heart Lung Transplant*. 2009;28: 508–510.
- Hunt B. Graft versus host disease in heart and/or lung transplantation. In: Yacoub M, Rose ML, eds. *Immunology of Heart and Lung Transplantation*. London; Boston: E. Arnold; 1993:viii, 312 p.
- Luckraz H, Zagolin M, McNeil K, et al. Graft-versus-host disease in lung transplantation: 4 case reports and literature review. *J Heart Lung Transplant*. 2003;22:691–697.
- Pfizzmann R, Hummel M, Grauhan O, et al. Acute graft-versus-host disease after human heart-lung transplantation: a case report. *J Thorac Cardiovasc Surg*. 1997;114:285–287.
- Santos AS, Coelho R, Murinello N, et al. Graft Versus Host Disease In Lung Transplant—A Case Report. American Thoracic Society 2014 International Conference; May 18, 2014, 2014; San Diego, California.
- Smith DM, Agura ED, Ausloos K, et al. Graft-vs-host disease as a complication of lung transplantation. *J Heart Lung Transplant*. 2006;25: 1175–1177.
- Worel N, Bojic A, Binder M, et al. Catastrophic graft-versus-host disease after lung transplantation proven by PCR-based chimerism analysis. *Transpl Int*. 2008;21:1098–1101.
- Pavenski K, Kamel-Reid S, Wei C, et al. Lung transplantation complicated by graft-versus-host disease and confounded by incidental transfusion-associated macrochimerism. *Transfusion*. 2008;48: 2190–2196.
- Billingham RE. The biology of graft-versus-host reactions. *Harvey Lect*. 1966;62:21–78.
- Triulzi DJ, Nalesnik MA. Microchimerism, GVHD, and tolerance in solid organ transplantation. *Transfusion*. 2001;41:419–426.
- Mazariegos GV, Abu-Elmagd K, Jaffe R, et al. Graft versus host disease in intestinal transplantation. *Am J Transplant*. 2004;4:1459–1465.
- Starzl TE, Demetris AJ, Trucco M, et al. Cell migration and chimerism after whole-organ transplantation: the basis of graft acceptance. *Hepatology*. 1993;17:1127–1152.
- Starzl TE, Demetris AJ, Murase N, et al. Cell migration, chimerism, and graft acceptance. *Lancet*. 1992;339:1579–1582.
- Domati-Saad R, Klintmalm GB, Netto G, et al. Acute graft versus host disease after liver transplantation: patterns of lymphocyte chimerism. *Am J Transplant*. 2005;5:2968–2973.
- Smith DM, Agura E, Netto G, et al. Liver transplant-associated graft-versus-host disease. *Transplantation*. 2003;75:118–126.
- Taylor AL, Gibbs P, Sudhindran S, et al. Monitoring systemic donor lymphocyte macrochimerism to aid the diagnosis of graft-versus-host disease after liver transplantation. *Transplantation*. 2004;77: 441–446.
- Martin PJ, Schoch G, Fisher L, et al. A retrospective analysis of therapy for acute graft-versus-host disease: initial treatment. *Blood*. 1990;76: 1464–1472.

22. MacMillan ML, Weisdorf DJ, Davies SM, et al. Early antithymocyte globulin therapy improves survival in patients with steroid-resistant acute graft-versus-host disease. *Biol Blood Marrow Transplant*. 2002;8:40–46.
23. Gomez-Almaguer D, Ruiz-Arguelles GJ, del Carmen Tarin-Arzaga L, et al. Alemtuzumab for the treatment of steroid-refractory acute graft-versus-host disease. *Biol Blood Marrow Transplant*. 2008;14:10–15.
24. Przepiorka D, Kernan NA, Ippoliti C, et al. Daclizumab, a humanized anti-interleukin-2 receptor alpha chain antibody, for treatment of acute graft-versus-host disease. *Blood*. 2000;95:83–89.
25. Couriel D, Saliba R, Hicks K, et al. Tumor necrosis factor-alpha blockade for the treatment of acute GVHD. *Blood*. 2004;104:649–654.
26. Couriel DR, Hosing C, Saliba R, et al. Extracorporeal photochemotherapy for the treatment of steroid-resistant chronic GVHD. *Blood*. 2006;107:3074–3080.
27. Furlong T, Martin P, Flowers ME, et al. Therapy with mycophenolate mofetil for refractory acute and chronic GVHD. *Bone Marrow Transplant*. 2009;44:739–748.
28. Benito AI, Furlong T, Martin PJ, et al. Sirolimus (rapamycin) for the treatment of steroid-refractory acute graft-versus-host disease. *Transplantation*. 2001;72:1924–1929.
29. Chinnakotla S, Smith DM, Domiati-Saad R, et al. Acute graft-versus-host disease after liver transplantation: role of withdrawal of immunosuppression in therapeutic management. *Liver Transpl*. 2007;13:157–161.