



Transvaginal US vs. CT in non-pregnant premenopausal women presenting to the ED: clinical impact of the second examination when both are performed

Charles D. Viers¹ · Meghan G. Lubner¹ · Perry J. Pickhardt¹

Received: 23 November 2021 / Revised: 17 March 2022 / Accepted: 18 March 2022 / Published online: 8 April 2022
© The Author(s), under exclusive licence to Springer Science+Business Media, LLC, part of Springer Nature 2022

Abstract

Objective To determine the clinical impact of the second examination when both CT and TVUS are obtained in the same ED visit for acute pelvic/lower abdominal symptoms in non-pregnant premenopausal women.

Methods 200 consecutive non-pregnant premenopausal women (mean age, 31.8 years; range, 18–49 years) who underwent both ED-based TVUS and abdominopelvic CT evaluation for acute symptoms over a 12 month period were included; 107 women had TVUS first, followed by CT; 93 women had CT first. All relevant clinical, radiologic, and pathologic findings were reviewed to establish a final diagnosis. Any additional clinical impact provided by the second imaging test was assessed by two experienced abdominal radiologists.

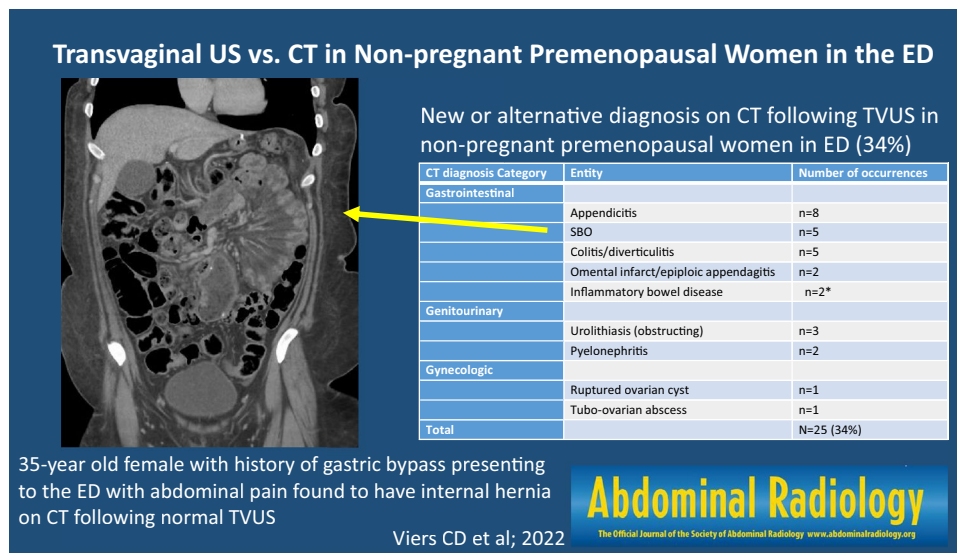
Results Initial TVUS was interpreted as normal ($n = 63$) or mentioned incidental findings ($n = 11$) in 69% (74/107); subsequent CT established a non-gynecologic GI/GU etiology in 25 (34%). For 37% (34/93) of CT exams interpreted as normal, TVUS added no new information. In 32 cases (34%), TVUS further excluded ovarian torsion/adnexal pathology when initial CT was indeterminate/equivocal. Overall, CT following TVUS provided a key new or alternative diagnosis in 26% (28/107), whereas TVUS after CT provided a relevant new/alternative diagnosis in only 1/93 cases ($p < 0.001$). In nine cases (8%), CT confirmed a positive US diagnosis but detected relevant additional diagnostic information.

Conclusion CT following negative TVUS frequently identified a non-gynecologic cause of acute pelvic or lower abdominal symptoms in non-pregnant premenopausal women, whereas the main benefit of TVUS after CT was more confident exclusion of ovarian torsion.

✉ Meghan G. Lubner
mlubner@uwhealth.org

¹ Department of Radiology, University of Wisconsin School of Medicine and Public Health, E3/311 Clinical Sciences Center, 600 Highland Ave, Madison, WI 53792, USA

Graphical abstract



Keywords Computed tomography · Ultrasound · Non-traumatic abdominal pain · Nonpregnant · Premenopausal

Introduction

Acute abdominal/pelvic pain is a common symptom that brings patients to the emergency department, accounting for 4–5% of ED visits [1]. Given that a spectrum of entities could represent the underlying cause, imaging is often performed [1–3]. In non-pregnant, pre-menopausal women, acute gynecologic pathology is often a consideration in the setting of acute lower abdominal or pelvic symptoms, and transvaginal ultrasound (TVUS) is considered the imaging modality of choice [4, 5]. For example, for a diagnosis like ovarian torsion, TVUS demonstrated a sensitivity and specificity of 70%/87%, respectively, in one series [6], and a diagnostic accuracy around 75% in another [7]. However, if a non-gynecological etiology is suspected, contrast-enhanced CT of the abdomen and pelvis (CT A/P) is often preferred. Appendicitis may be the most common non-gynecologic etiology in this age group, and multi-detector CT showed a sensitivity and specificity of 98%/98%, respectively, in a large series [8]. This is reflected in the current ACR Appropriateness Criteria for acute pelvic pain in the reproductive age group, where TVUS receives a top rating of 9 versus 4 for CT A/P for the former scenario, while the ratings are reversed for the latter scenario (ie, 9 for CT A/P, 4 for TVUS if non-gynecologic source suspected) [4, 5].

In theory, laboratory testing and clinical history can be helpful in deciding if a TVUS or CT A/P is the most appropriate first test. In practice, however, distinguishing an acute gynecologic from non-gynecologic etiology

on clinical grounds can be challenging. Ovarian torsion often mimics appendicitis, diverticulitis, or renal colic, making the imaging test of choice an educated guess in many cases [9]. Not infrequently, both U.S. and CT are performed sequentially, not necessarily in this order, when the initial test fails to adequately address the perceived clinical concern. When possible, utilizing a single, high-yield imaging examination is optimal, as it may decrease time to diagnosis, length of stay in the ED, and overall visit cost [10]. CT has been shown to frequently identify an alternative source of symptoms from the suspected indication, as shown in multiple series, including one where an alternative to suspected appendicitis was delineated by CT in up to 31.6% of patients or another where an alternative to mesenteric ischemia was identified in up to 61% of patients [11, 12]. Although non-gynecologic causes of pelvic pain can be identified on US, this may require alternative transducers, changes in patient position, use of graded compression, and scanning outside the normal range of structures indicated for the exam, which may not be routinely performed depending on institutional protocols [13]. However, despite providing a comprehensive imaging evaluation, CT has the added issues of exposure to ionizing radiation and iodinated contrast. Consequently, some groups recommend starting with US in this patient population, especially when radiation is a primary concern, followed by CT in cases where US is non-diagnostic [1, 14]. Therefore, it is important to determine if the potential added benefit outweighs the theoretical risk. Similarly,

little is known regarding potential added benefit of TVUS following negative CT A/P in this clinical setting.

To date, we have found no studies evaluating the utility of the second diagnostic test (TVUS or CT) in non-pregnant premenopausal women with acute lower abdominal or pelvic pain. The purpose of this study was to determine the clinical value added by this second examination and help formulate an imaging approach in this challenging population.

Materials and methods

Study cohort

This study was IRB-approved, HIPAA-compliant, and the need for informed consent was waived due to the retrospective nature. A review of PACS and the electronic medical record (EMR) was performed over a one year period (3/2019–2/2020). The inclusion criteria for this study consisted of non-pregnant, pre-menopausal women (18–49 years of age) presenting to the ED of a single academic center with acute pelvic pain who underwent (in either order) both TVUS and contrast-enhanced CT A/P within 24 h of presentation. A consecutive series of 200 patients were included; 107 women had TVUS first, followed by CT A/P; 93 had CT A/P first, followed by TVUS. The decision regarding which imaging study was performed first was made by the Emergency Department physician based on the clinical presentation.

All CT scans were performed on 16–256 MDCT scanners (GE Medical, Waukesha, WI), at 100–140 kV (size-based kV selection) with automatic tube current at 3.75 mm × 2.5 mm. IV contrast was administered based on weight (iohexol, Omnipaque 300, GE Healthcare, Waukesha WI) and images were obtained in the portal venous phase (roughly 70 s delay, Smart Prep) per the routine protocol. Oral contrast (Omnipaque 300, GE Healthcare, Waukesha WI) was administered per ED guidelines in some cases (BMI < 25, recent surgery, known cancer). Coronal and sagittal reformats are routinely performed (3 × 2 mm). Complete CT parameters are outlined in supplemental Table S1. Our median 50th percentile institutional radiation dose (CTDI_{vol}) for routine CT abdomen/pelvis in a medium sized patient with a water equivalent diameter of 310 is 12.2 mGy (95% confidence interval 12, 12.4), comparing favorably with the ACR Dose Index Registry of 12.0 mGy (supplemental Table S2) [15]. Of note, a limited number of scanners in our fleet have dual energy capabilities and none of the CT exams included was performed with dual energy.

The US female pelvis consists of a transabdominal component scanned using a curvilinear or sector transducer (2–7 MHz) to obtain survey images of the uterus, adnexa and both flanks (single image of each kidney) with a full bladder.

A transvaginal component is performed using an endovaginal transducer (5–9 MHz), where the uterus and ovaries are evaluated in 3 planes, the endometrium is measured, and any pathology identified is documented in 3 planes and evaluated with color Doppler. For all ED patients, or any patient where a question of torsion is raised, color and pulsed wave Doppler of both ovaries is obtained with documentation of both arterial and venous flow. Cine clips of these structures are routinely obtained in addition to still images, and the cul-du-sac is assessed for free fluid.

All relevant clinical, radiologic, and pathologic findings were reviewed to establish a final diagnosis for both TVUS and CT A/P. The final diagnosis for both imaging modalities was also assigned a retrospective confidence level on a scale of 1–3 (1- lowest, 3- highest), which was reviewed by two experienced abdominal radiologists (11, 21 years of experience). Any additional clinical value or impact provided by the second imaging test was categorized as (1) a clinically meaningful new or alternative diagnosis, (2) additional meaningful clinical information about a given diagnosis, (3) confirmation of a diagnosis, or (4) exclusion of a diagnosis, by the same two abdominal radiologists in consensus.

Additionally, the EMR was extensively reviewed for data relating to the clinical assessment in the ED (including clinical diagnosis, laboratory values), disposition of the patient (e.g., discharged to home or admitted to the hospital), management (e.g., conservative or surgical), and any further relevant work-up, treatment, or follow-up to aid in establishing a final diagnosis and disposition.

Statistical analysis

Fisher's exact test was used to test for differences in categorical variables, and Student's t-test was used to test for differences in continuous variables. A two-tailed *p*-value < 0.05 was used as the criterion for statistical significance.

Results

In total, 200 consecutive non-pregnant, premenopausal women (mean age 31.8; range 18–49 years) underwent both TVUS and CECT A/P during a single ED visit for acute presentation between May 2019 and February 2020 (date range was selected to avoid overlap from COVID-19 pandemic). TVUS was performed first in 107 cases, followed by CT A/P, and CT A/P was performed first in 93 cases, followed by TVUS. In the group that underwent TVUS as the first test, the study was interpreted as normal in 59% (63/107) or mentioned only unrelated incidental findings (*n* = 11) in 69% (74/107). Subsequent CT A/P in this group established a new non-gynecologic diagnosis in 34% of these cases (25/74). In three additional cases, TVUS identified

nonspecific findings (e.g., free fluid), where subsequent CT established a more specific diagnosis (e.g., right-sided colitis, ruptured ovarian cyst). Appendicitis was the most

common alternative diagnosis ($n = 8/28$, 28%). Overall, CT A/P following TVUS provided a key new or alternative diagnosis not identified at US in 28/107 cases (26%) (Tables 1

Table 1 New or alternative diagnosis on CT following TVUS in non-pregnant premenopausal women

CT diagnosis Category	Entity	Number of occurrences
Gastrointestinal	Appendicitis	$n = 8$
	SBO	$n = 5$
	Colitis/diverticulitis	$n = 5$
	Omental infarct/epiploic appendagitis	$n = 2$
	Inflammatory bowel disease	$n = 2^*$
Genitourinary	Urolithiasis (obstructing)	$n = 3$
	Pyelonephritis	$n = 2$
Gynecologic	Ruptured ovarian cyst	$n = 1$
	Tubo-ovarian abscess	$n = 1$

*Primary dx of SBO in one case

Table 2 Specific alternative diagnoses provided by CT following TVUS

US primary diagnosis	CT final diagnosis	Comments
Normal	2 mm right ureteral calculus	Hydronephrosis
Normal	Appendicitis	Uncomplicated
Normal	Colitis	Ascending colon
Normal	Right pyelonephritis	
Normal	Omental infarct	
Normal	High grade SBO	
Normal	SBO	Cystic fibrosis (DIOS)
Normal	Left mid ureteral calculus	Hydronephrosis
Normal	Internal hernia LUQ on CT	Gastric bypass
Normal	Appendicitis	Uncomplicated
Normal	3 mm right UVJ stone	Hydronephrosis, delayed nephrogram
Normal	Appendicitis	Perforated
Normal	Pyelonephritis	
Normal	Colitis	Transverse, descending colon
Normal	Appendicitis	Uncomplicated
Normal	Appendicitis	Uncomplicated
Normal	Diverticulitis	Uncomplicated, transverse colon
Normal	Appendicitis	Uncomplicated
Normal	Possible early tip appendicitis	
Normal	SB-SB intussusception	Long segment, nodal lead point
Normal	Colitis	Ascending colon
Endometrioma/hemorrhagic cyst	Appendicitis	Uncomplicated
Fibroids	Crohn disease	Ileocolic
Complex left ovarian cyst	Tuboovarian abscess	Additional pelvic collection
Complex left ovarian mass	SBO	Crohn stricture, perforated
Endometrioma/hemorrhagic cyst	Epiploic appendagitis	
Complex-free fluid	Colitis	Ascending colon
Free fluid	Ruptured ovarian cyst	

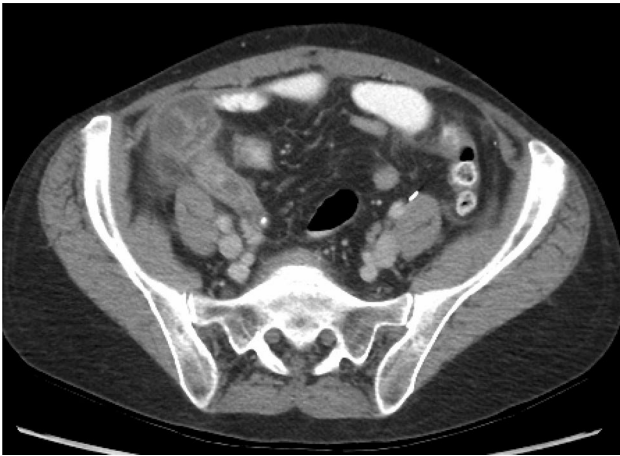

Fig. 1 47-year-old female who presented with right lower quadrant pain. Initial TVUS (not shown) was interpreted as normal, but CT demonstrated a dilated, fluid-filled, thick-walled enhancing appendix with appendicolith, compatible with acute uncomplicated appendicitis

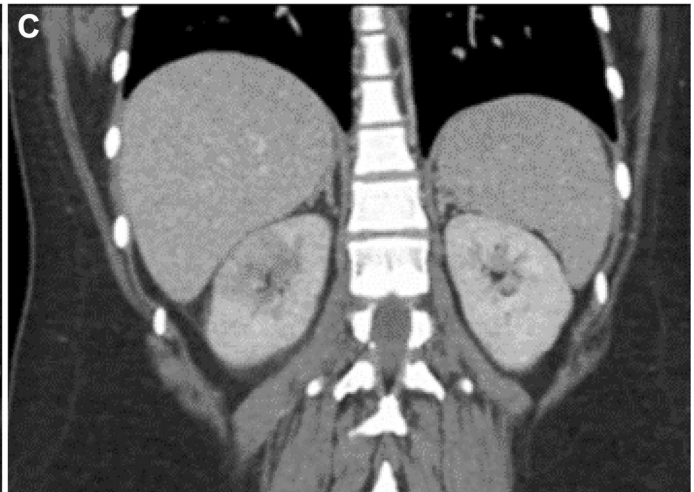
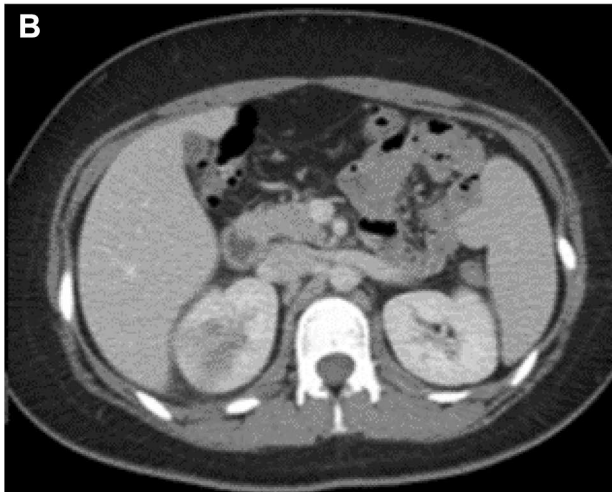
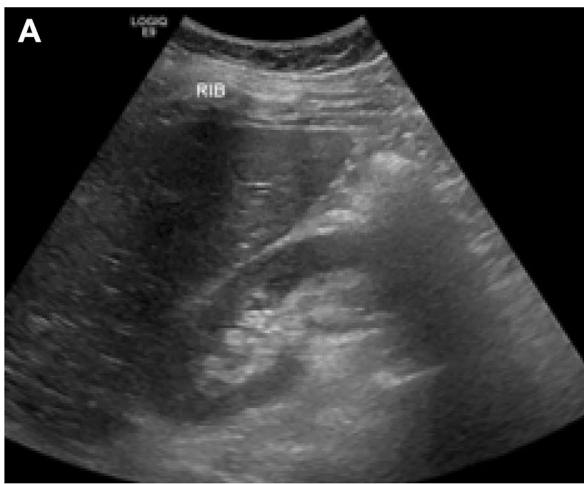


Fig. 2 19-year-old female who presented to the ED with right lower quadrant abdominal pain. Pelvic US (transabdominal/transvaginal approach per protocol) was initially performed to assess for ovarian torsion or tubo-ovarian abscess. US was read as normal; a survey gray-scale transabdominal image of the right kidney is shown (A).

and 2, Figs. 1, 2 and 3). In an additional nine cases (8%), CT following US both confirmed the diagnosis and provided clinically meaningful additional information. For example, in three cases, hydronephrosis was identified on US, but CT identified the size and location of the obstructing ureteral stone that could not be seen on US (Fig. 4). In two cases, complex fluid was seen, and appendicitis was established at CT (one perforated). In two additional cases, ovarian cysts were noted with complex pelvic fluid, but CT better established the extent of hemoperitoneum from ruptured hemorrhagic cysts.

In the group that underwent CT A/P first, 37% (34/93) were interpreted as normal, and the subsequent TVUS performed in these patients added no new relevant information. In another 1/3 of cases ($n=32/93$, 34%) where no clear etiology for pain was identified on CT, subsequent TVUS more confidently excluded ovarian torsion or other adnexal pathology. There was one case of ovarian torsion in the

Transvaginal images obtained (not shown) were also read as normal. Subsequent axial (B) and coronal (C) contrast-enhanced CT images demonstrate peripheral wedge-shaped low attenuation involving the upper pole parenchyma of the right kidney, compatible with uncomplicated pyelonephritis, which was confirmed at urinalysis

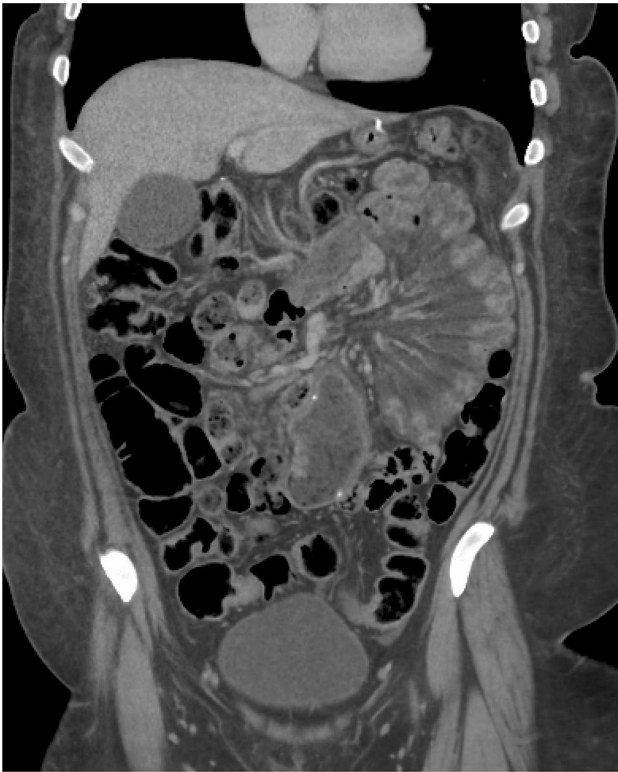

Fig. 3 35-year-old female with surgical history of gastric bypass presenting with abdominal pain. Initial TVUS (not shown) was interpreted as normal. Coronal contrast-enhanced CT demonstrates a radial configuration of congested small bowel loops in the left upper quadrant with prominent mesenteric edema in a configuration concerning for internal hernia, which was confirmed at surgery

entire cohort confirmed at surgery, and it was not prospectively identified on the initial CT or the follow-up TVUS (although both identified the dermoid that functioned as the lead mass) (Fig. 5). In retrospect, a twisted pedicle was identifiable on the CT. There were no cases where ovarian torsion was questioned on CT and confirmed with subsequent TVUS. In three cases, TVUS more confidently confirmed a diagnosis of hemorrhagic cyst and excluded associated torsion. In the group that underwent CT A/P first, TVUS provided a new or alternative diagnosis in only one of 93 cases (1%) (Fig. 6), which was a statistically significantly difference compared with the rate of new diagnoses provided by CT following TVUS ($p < 0.001$). In this case, an enlarged medialized ovary with cysts was seen on CT, with torsion raised as a leading concern. The US demonstrated arterial and venous flow to the ovary, making torsion less likely, and demonstrated that one of the cysts was hemorrhagic, possibly the source of the patient's symptoms. In four cases (4%), the TVUS performed after CT gave a discordant result to the CT, which was ultimately found to be misleading to the final diagnosis. For example, in one case, the CT suggested pelvic peritoneal thickening concerning for PID, while the US was

read as normal (Fig. 7). The patient's cervical cultures were positive for *Neisseria gonorrhoeae* compatible with PID. In another case, the CT was read as normal, and the subsequent US described debris in the bladder concerning for cystitis. The patient was treated for UTI despite no findings on CT and unimpressive urinalysis, but cervical cultures came back positive for *Chlamydia trachomatis* and the patient's antibiotics needed to be changed to treat PID. In a third case, CT demonstrated findings concerning for peritoneal carcinomatosis, later confirmed at biopsy, due to foregut primary. Subsequent TVUS described a complex adnexal lesion and suggested an ovarian primary, ultimately discordant with the pathologic diagnosis.

Discussion

In non-pregnant, premenopausal women presenting to the ED with acute pelvic pain, establishing a gynecologic vs a non-gynecologic etiology is clinically challenging, with women often undergoing both TVUS and CT A/P for evaluation. The main purpose of our study was to determine the clinical value added by this second examination in the ED, be it CT or US. It is widely accepted that if an acute gynecologic process is suspected, TVUS is considered the first-line imaging study, and if an acute non-gynecologic origin is suspected, CT A/P is preferred [4, 5]. At our institution both exams are generally not ordered concurrently, but at the discretion of the ordering provider's index of suspicion to the etiology of pain, with the follow up study ordered once the results of the first study are available. Prior smaller series have demonstrated that TVUS following a normal CT in this cohort provided no clinical benefit other than diagnosing uterine and endometrial abnormalities [16, 17]. However, to our knowledge, there has been no study to date evaluating non-pregnant, pre-menopausal women who underwent TVUS as their initial study followed by CT.

Our results show that TVUS following CT established a new or alternative diagnosis in less than 1% of our cohort, which is consistent with the existing literature. In about 1/3 of cases, TVUS was arguably useful in more confidently excluding the diagnosis of ovarian torsion in some cases. In contrast, when CT was performed following a normal TVUS, a new or alternative diagnosis was established in 34% of cases (26% of the entire cohort) and added clinically relevant information in another 8%. Our findings confirm that a normal CT has a very high negative predictive value (NPV) as suggested by prior studies, but also suggests that TVUS has a relatively low NPV for new or alternative relevant diagnoses (particularly non-gynecologic diagnoses) as the initial diagnostic test in this clinical setting. Presumably, a gynecologic etiology was favored by the referring ED physician for most or all of the women who initially

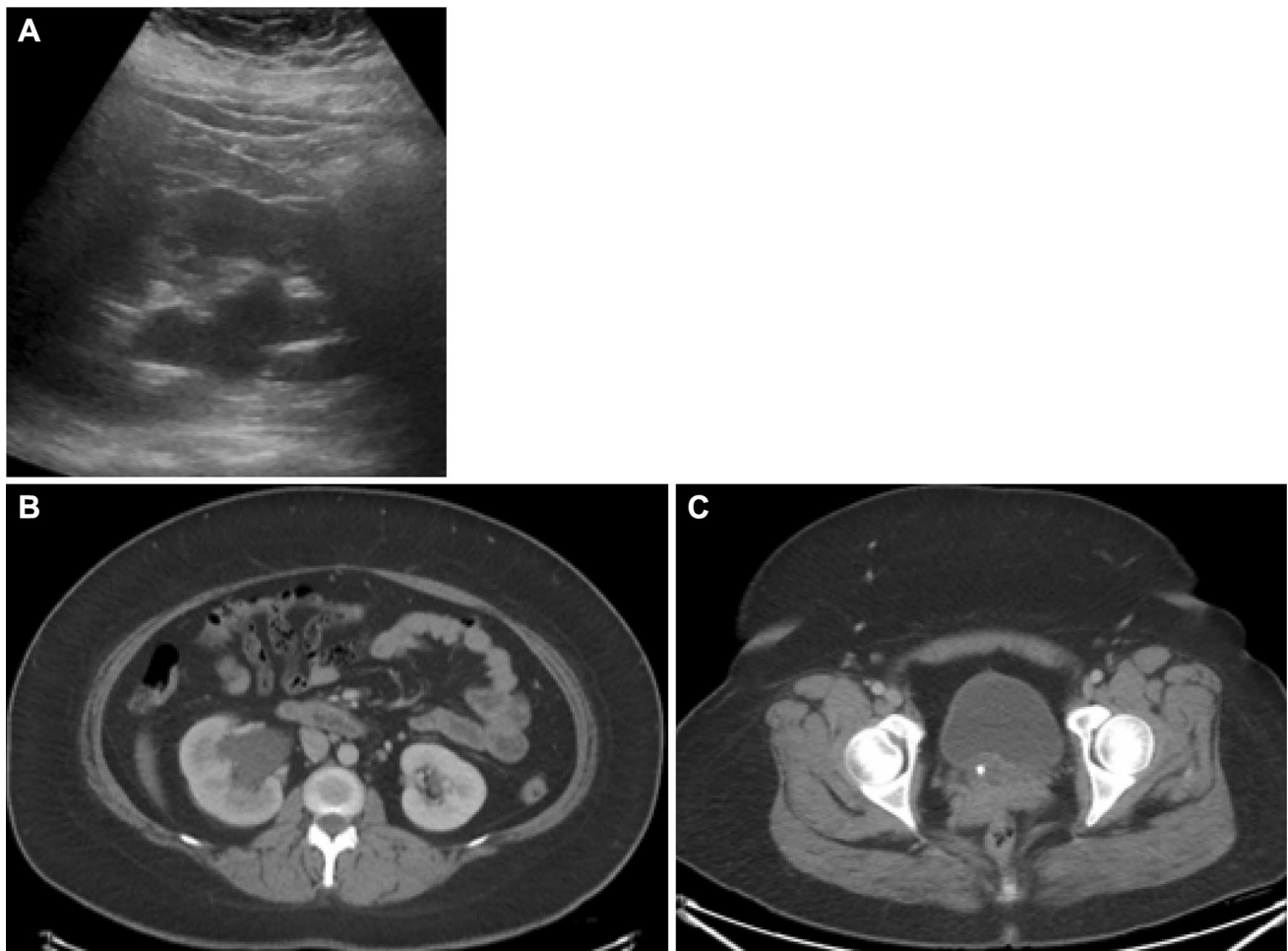


Fig. 4 28-year-old-female presented with right-sided abdominal pain. Transabdominal image from initial TVUS (A) demonstrates moderate right-sided hydronephrosis. Subsequent CT confirmed this, but

also demonstrated right renal enlargement and delayed nephrogram (B), with obstructing 3-mm stone identified at the right ureterovesicle junction (C). The calculus was not identified at TVUS

underwent TVUS. Although many of the non-gynecologic diagnoses missed by US could potentially be made with this imaging modality, they may require scanning with alternative transducers, repositioning the patient, or using graded compression, which may not be part of a standard TVUS protocol [13]. Non-gynecologic diagnoses at TVUS also require additional clinical suspicion and awareness on the part of sonographers and interpreting radiologists. It should be noted that at our institution, a limited evaluation of the flanks is performed in our standard TVUS exam, including single images of both kidneys. Although not required for billing, this allows for detection or absence of hemoperitoneum which may accumulate in Morrison's pouch, a dependent space. Additionally, if a Mullerian anomaly is detected, concurrent evaluation for gross urinary tract abnormalities can be documented (e.g., unilateral renal agenesis). Despite these additional views, the results of our study would remain

unchanged as CT further characterized and added information regarding the source of obstruction where only hydronephrosis was seen at TVUS. Overall, our findings support the use of CT as the most efficient and effective initial diagnostic imaging test in this cohort, especially when the cause of symptoms is unclear based on clinical grounds.

Some have argued that overutilization of CT in this scenario can result in higher cost, increased patient radiation dose, and increased length of hospital stay [1, 14, 18]. However, our data suggest the opposite; TVUS rarely added a new or alternative diagnosis in this cohort when CT was performed as the initial exam, and may lead to delays in diagnosis or sometimes even misleading information. Conversely, a significant number of alternative diagnoses were uncovered in the cohort when TVUS was performed first, followed by CT. Although some series have suggested that US should be performed first as a triage

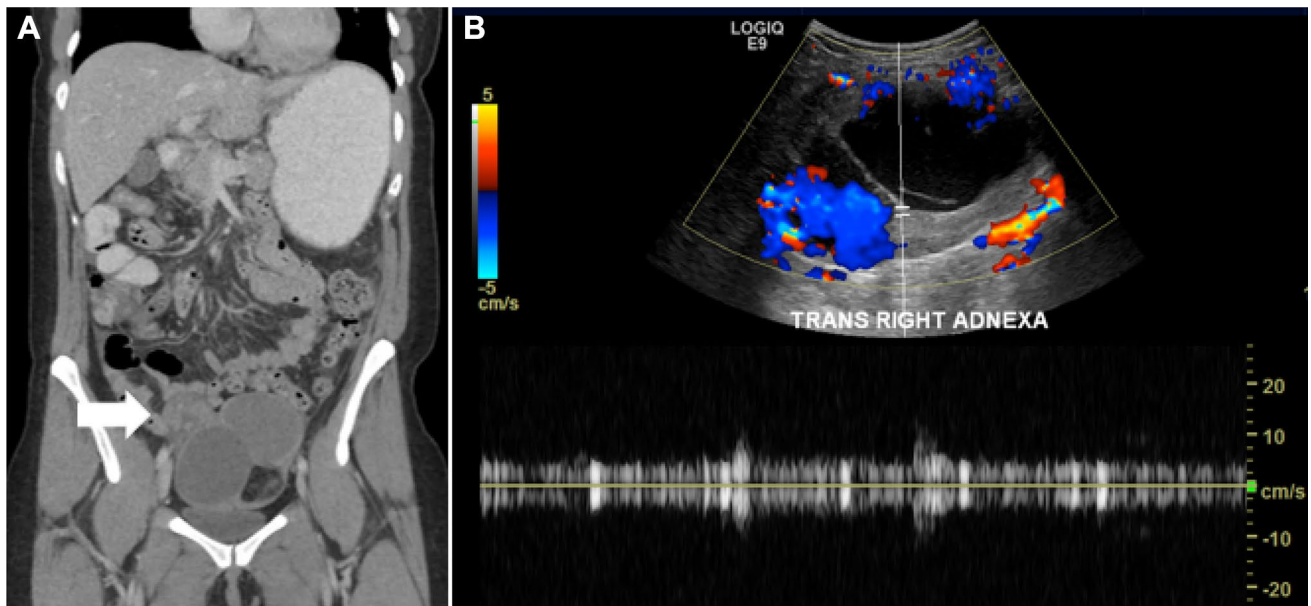


Fig. 5 29-year-old female who presented with right lower quadrant pain. Coronal contrast-enhanced CT (A) demonstrates an enlarged and medialized right ovary containing a large, complex fat-containing mass, compatible with dermoid. Prominent congested vascular pedi-

cle is present (arrow) but was not prospectively described. TVUS confirmed dermoid but showed presence of arterial and venous flow on pulsed Doppler (B). Torsion was found at surgery and surgical pathology demonstrated an infarcted dermoid (mature teratoma)

exam, and those with abnormal findings should go on to CT, in many cases the initial TVUS appeared normal and by this model, these women would not have been referred on to CT despite the presence of a clinically significant diagnosis. Our findings question the validity of such an approach, and further illustrate the challenges around using clinical features to discern whether the patient's pain is gynecologic or non-gynecologic in origin to inform the choice of imaging test. However, as these patients are young, concerns have been raised around radiation dose. One could argue that the risk of a single CT performed with optimized technical parameters with doses as low as reasonably achievable may be outweighed by the potential for diagnostic confusion or delay.

The benefit of CT for non-traumatic abdominal pain in the ED is well-documented [19, 20]. The non-pregnant, pre-menopausal female has sometimes been considered an exception given the prevalence of pain of suspected gynecologic origin in this group. However, CT performed well in this cohort and clinical setting in our study, identifying a statistically significantly higher number of new and alternate diagnoses that were not identified via TVUS. This is consistent with the current literature in other patient cohorts which supports the use of CT in making urgent diagnoses

in those with acute, non-traumatic abdominal pain, where the sensitivity of CT was 89% and the sensitivity of US was 70% ($p < 0.001$) [14]. It appears that the main role for secondary TVUS in our cohort was to evaluate for ovarian torsion when overall negative but "indeterminate or equivocal" adnexal findings were suggested at CT. However, there were no cases in our cohort where ovarian torsion was present and confirmed with TVUS.

Given the clear benefit of CT for ED patients with non-traumatic acute abdominal pain, could CT be used to reliably exclude ovarian torsion without a confirmatory TVUS? Patil et al. have shown that there are reliable CT-based indicators of ovarian torsion among cases that were confirmed surgically, of which a twisted pedicle was seen 100% of the time [21]. In most cases, the diagnosis of torsion may be readily made on CT; however, even if we reserved use of TVUS following CT for this indication, only 1/3 of patients in our series required this second exam. Using an algorithm where CT is performed first, followed by TVUS only if (truly) equivocal adnexal or gynecologic findings are present would streamline imaging evaluation of these patients and lead to decreased overall use of imaging in this group of patients. In our lone case of surgically proven ovarian torsion (with a teratomatous lead mass), both the initial CT and TVUS did

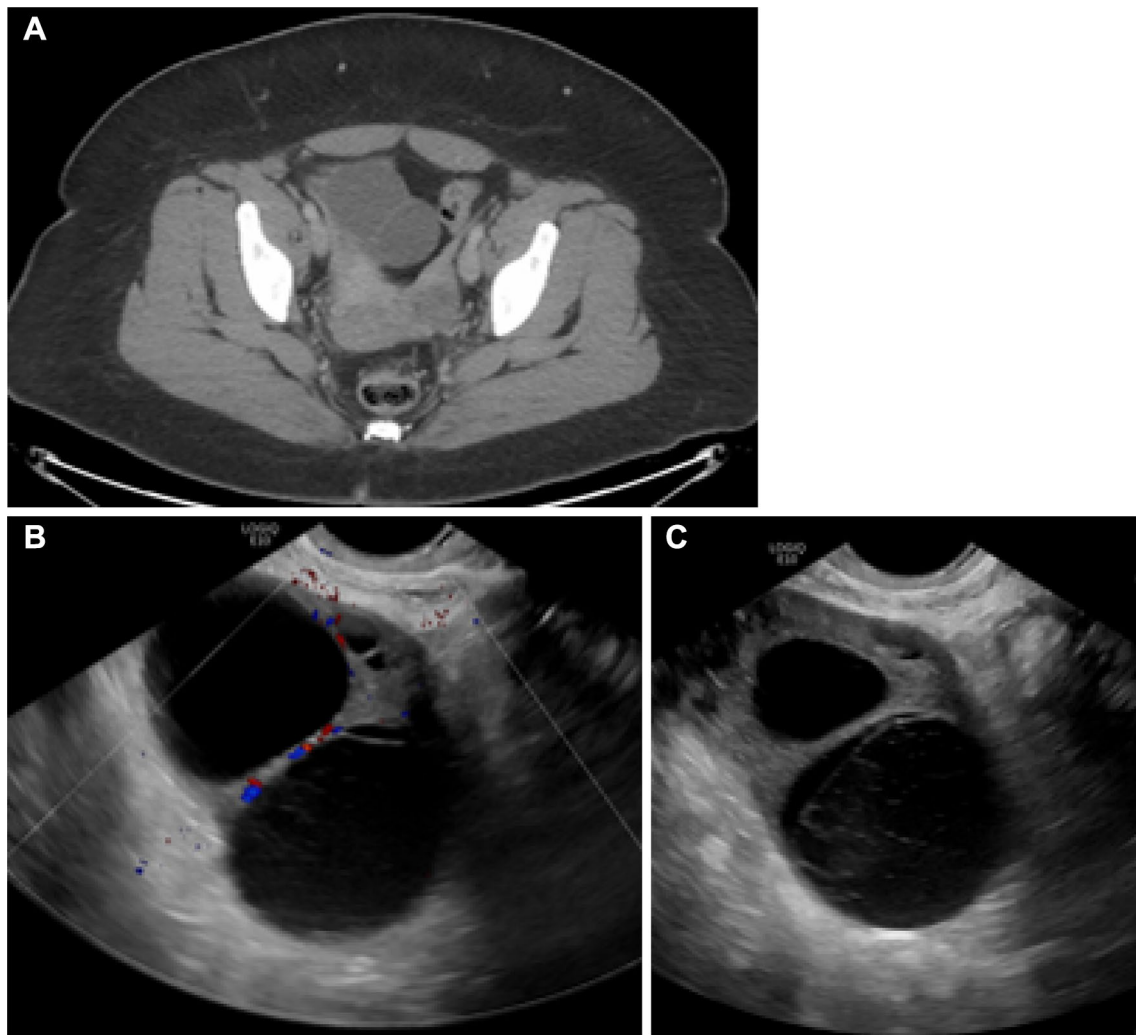


Fig. 6 40-year-old female who presented with right lower quadrant pain. CT (A) demonstrates two adjacent or single-bilobed cystic lesion involving the right ovary, which was enlarged and medialized, making torsion a leading concern. Subsequent TVUS showed pres-

ence of color Doppler flow (B) and lacy internal reticular echoes in one of the cysts, compatible with hemorrhage/retracting clot (C), making torsion less likely, and raising the possibility of the hemorrhagic cyst as the source of pain

not diagnose ovarian torsion. However, after further review, CT evidence of torsion was present, demonstrating a twisted pedicle. Interestingly, no findings were present on the subsequent TVUS. It is possible that the torsion was intermittent; however, the ovary was torsed at the time of surgery and surgical pathology demonstrated an infarcted dermoid, suggesting torsion of some duration.

We acknowledge limitations to this investigation, of which the most notable is selection bias. Our investigation required that both TVUS and CT A/P were performed in the same ED visit. This excludes the many cases where a clear

diagnosis was made with only CT A/P or TVUS alone, thus not requiring a second study. As such, the negative rate of the initial exams are predictably higher than normal. Additionally, our retrospective evaluation could not account for the decision-making by the ordering provider on whether they suspected or favored a gynecologic or non-gynecologic etiology for the patient's pain. Furthermore, there is undoubtedly inter-reader variability and confidence among our interpreting radiologists. It is also probable that the radiologist interpreting the second study knew the results of the first study, or garnered additional clinical history, thus

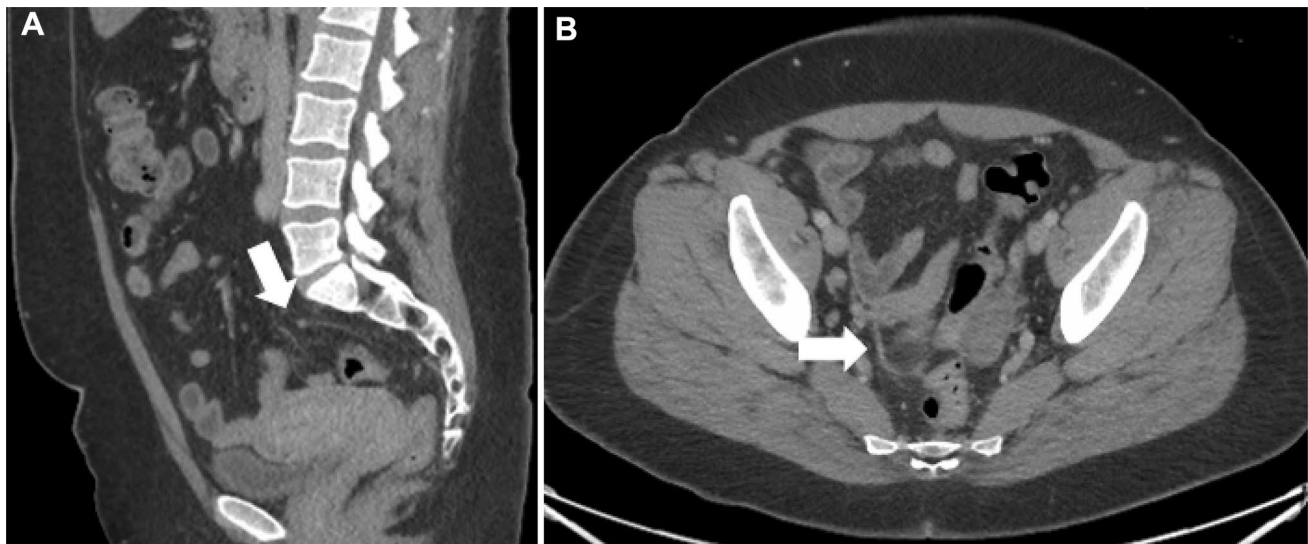


Fig. 7 34-year-old female who presented with bilateral lower quadrant pain. Sagittal (A) and axial (B) CT demonstrates subtle peritoneal thickening in the pelvis, with mild associated inflammatory

stranding (arrows), raising concern for PID. Subsequent TVUS (not shown) was interpreted as normal. Cervical cultures subsequently grew *Neisseria gonorrhoeae*

informing their final interpretation. This is a single institution study, and results may not be generalizable to other institutions or practice patterns. Finally, ED and hospital length of stay were not evaluated, nor were metrics impacting cost effectiveness.

Conclusion

CT following negative TVUS frequently identified a non-gynecologic cause of acute pelvic or lower abdominal symptoms in non-pregnant, pre-menopausal women presenting to the ED, whereas the main apparent benefit of TVUS after negative CT was more confident exclusion of ovarian torsion.

These findings in concert with clinical presentation may help prioritize which imaging test is ordered first, and depending on which study is ordered first, may help inform the utility of a second test. Further study, including cost effectiveness and impact on length of ED and hospital stay are warranted.

Supplementary Information The online version contains supplementary material available at <https://doi.org/10.1007/s00261-022-03504-6>.

Author contributions CV None, MGL Prior grant funding Philips, Ethicon, PJP Advisor to Bracco and Zebra; shareholder in Elucent and SHINE.

Funding None.

References

1. Stoker J, van Randen A, Lameris W, Boermeester MA. Imaging patients with acute abdominal pain. *Radiology*. 2009;253(1):31-46.
2. Potter AW, Chandrasekhar CA. US and CT evaluation of acute pelvic pain of gynecologic origin in nonpregnant premenopausal patients. *Radiographics*. 2008;28(6):1645-59.
3. Vandermeer FQ, Wong-You-Cheong JJ. Imaging of acute pelvic pain. *Clin Obstet Gynecol*. 2009;52(1):2-20.
4. Andreotti RF, Lee SI, Choy G, DeJesus Allison SO, Bennett GL, Brown DL, et al. ACR Appropriateness Criteria on acute pelvic pain in the reproductive age group. *J Am Coll Radiol*. 2009;6(4):235-41.
5. Andreotti RF, Lee SI, DeJesus Allison SO, Bennett GL, Brown DL, Dubinsky T, et al. ACR Appropriateness Criteria(R) Acute Pelvic Pain in the Reproductive Age Group. *Ultrasound Q*. 2011;27(3):205-10.
6. Grunau GL, Harris A, Buckley J, Todd NJ. Diagnosis of Ovarian Torsion: Is It Time to Forget About Doppler? *J Obstet Gynaecol Can*. 2018;40(7):871-5.
7. Mashiach R, Melamed N, Gilad N, Ben-Shitrit G, Meizner I. Sonographic diagnosis of ovarian torsion: accuracy and predictive factors. *J Ultrasound Med*. 2011;30(9):1205-10.
8. Pickhardt PJ, Lawrence EM, Pooler BD, Bruce RJ. Diagnostic performance of multidetector computed tomography for suspected acute appendicitis. *Ann Intern Med*. 2011;154(12):789-96, W-291.
9. Duigenan S, Oliva E, Lee SI. Ovarian torsion: diagnostic features on CT and MRI with pathologic correlation. *AJR Am J Roentgenol*. 2012;198(2):W122-31.
10. Hiatt KD, Ou JJ, Childs DD. Role of Ultrasound and CT in the Workup of Right Upper Quadrant Pain in Adults in the Emergency Department: A Retrospective Review of More Than 2800 Cases. *AJR Am J Roentgenol*. 2020;214(6):1305-10.
11. Pooler BD, Lawrence EM, Pickhardt PJ. Alternative diagnoses to suspected appendicitis at CT. *Radiology*. 2012;265(3):733-42.

12. Henes FO, Pickhardt PJ, Herzyk A, Lee SJ, Motosugi U, Derlin T, et al. CT angiography in the setting of suspected acute mesenteric ischemia: prevalence of ischemic and alternative diagnoses. *Abdom Radiol (NY)*. 2017;42(4):1152-61.
13. Mathur M, Scoutt LM. Nongynecologic Causes of Pelvic Pain: Ultrasound First. *Obstet Gynecol Clin North Am*. 2019;46(4):733-53.
14. Lameris W, van Randen A, van Es HW, van Heesewijk JP, van Ramshorst B, Bouma WH, et al. Imaging strategies for detection of urgent conditions in patients with acute abdominal pain: diagnostic accuracy study. *BMJ*. 2009;338:b2431.
15. Kanal KM, Butler PF, Sengupta D, Bhargavan-Chatfield M, Coombs LP, Morin RL. U.S. Diagnostic Reference Levels and Achievable Doses for 10 Adult CT Examinations. *Radiology*. 2017;284(1):120-33.
16. Gao Y, Lee K, Camacho M. Utility of pelvic ultrasound following negative abdominal and pelvic CT in the emergency room. *Clin Radiol*. 2013;68(11):e586-92.
17. Yitta S, Mausner EV, Kim A, Kim D, Babb JS, Hecht EM, et al. Pelvic ultrasound immediately following MDCT in female patients with abdominal/pelvic pain: is it always necessary? *Emerg Radiol*. 2011;18(5):371-80.
18. Lehtimäki T, Juvonen P, Valtonen H, Miettinen P, Paajanen H, Vanninen R. Impact of routine contrast-enhanced CT on costs and use of hospital resources in patients with acute abdomen. Results of a randomised clinical trial. *Eur Radiol*. 2013;23(9):2538-45.
19. Rosen MP, Sands DZ, Longmaid HE, 3rd, Reynolds KF, Wagner M, Raptopoulos V. Impact of abdominal CT on the management of patients presenting to the emergency department with acute abdominal pain. *AJR Am J Roentgenol*. 2000;174(5):1391-6.
20. Foinant M, Lipiecka E, Buc E, Boire JY, Schmidt J, Garcier JM, et al. [Impact of computed tomography on patient's care in nontraumatic acute abdomen: 90 patients]. *J Radiol*. 2007;88(4):559-66.
21. Raman Patil A, Nandikoor S, Chaitanya Reddy S. CT in the diagnosis of adnexal torsion: a retrospective study. *Journal of obstetrics and gynaecology : the journal of the Institute of Obstetrics and Gynaecology*. 2020;40(3):388-94.

Publisher's Note Springer Nature remains neutral with regard to jurisdictional claims in published maps and institutional affiliations.