



HHS Public Access

Author manuscript

Int J Obes (Lond). Author manuscript; available in PMC 2016 April 01.

Published in final edited form as:

Int J Obes (Lond). 2015 October ; 39(10): 1561–1564. doi:10.1038/ijo.2015.76.

A percutaneous needle biopsy technique for sampling the supraclavicular brown adipose tissue depot of humans

Palam Annamalai^{1,*}, Maria Chondronikola^{2,3,4,5,*}, Tony Chao^{2,3,4}, Craig Porter^{2,6}, Manish K. Saraf^{2,6}, Fernando Cesani⁷, and Labros S. Sidossis^{2,4,5,6,8,9,10}

¹Department of Interventional Radiology, University of Texas Medical Branch, U.S.A

²Metabolism Unit, Shriners Hospitals for Children-Galveston, U.S.A

³Department of Preventive Medicine and Community Health, University of Texas Medical Branch, U.S.A

⁴Department of Nutrition and Metabolism, Division of Rehabilitation Sciences, University of Texas Medical Branch, U.S.A

⁵Department of Nutrition and Dietetics, Harokopio University of Athens, Greece

⁶Department of Surgery, University of Texas Medical Branch, U.S.A

⁷Department of Nuclear Medicine, University of Texas Medical Branch, U.S.A

⁸Institute for Translational Sciences, University of Texas Medical Branch, U.S.A

⁹Sealy Center on Aging, University of Texas Medical Branch, U.S.A

¹⁰Department of Internal Medicine, University of Texas Medical Branch, U.S.A

Abstract

Brown adipose tissue (BAT) has been proposed as a potential target tissue against obesity and its related metabolic complications. Although the molecular and functional characteristics of BAT have been intensively studied in rodents, only a small number of studies have used human BAT specimens due to the difficulty of sampling human BAT deposits. We established a novel positron emission tomography and computed tomography-guided Bergström needle biopsy technique to acquire human BAT specimens from the supraclavicular area in human subjects. Forty-three biopsies were performed on 23 participants. The procedure was tolerated well by the majority of participants. No major complications were noted. Numbness (9.6%) and hematoma (2.3%) were the two minor complications noted, which fully resolved. Thus, the proposed biopsy technique can be considered safe with only minimal risk of adverse events. Adoption of the proposed method is

Users may view, print, copy, and download text and data-mine the content in such documents, for the purposes of academic research, subject always to the full Conditions of use:http://www.nature.com/authors/editorial_policies/license.html#terms

Corresponding author: Correspondence should be addressed to Dr. Labros S. Sidossis, address: 301 University Blvd, Rt 0177, Galveston, Texas, 77555, phone: 409-770-6609, fax: 409-770-6825, lasidoss@utmb.edu.

*These authors contributed equally to this work.

Conflict of interest: None

Clinical Trial Reg. No. NCT NCT01791114

expected to increase the sampling of the supraclavicular BAT depot for research purposes so as to augment the scientific knowledge of the biology of human BAT.

Keywords

brown adipose tissue; needle biopsy; safety

INTRODUCTION

The recent re-discovery of human brown adipose tissue (BAT) (1–4) has triggered intense scientific interest in the potential of this tissue as a target against obesity and its metabolic abnormalities. Numerous studies investigated the origin, plasticity, and metabolic characteristics of this tissue in animals (reviewed at (5)). However, these findings must be translated into humans in order for any therapeutic value to be realized. Currently, only a handful of studies have reported data from human BAT (1, 2, 4, 6–15) primarily using samples collected during surgeries (2, 4, 6), necropsies (7, 12, 14) or using an open biopsy technique (1, 8, 9, 13).

Hampering the effort to study the biology of human BAT is the lack of a safe method for the routine sampling of this tissue for research purposes. The Bergström needle has long been used for non-image guided biopsy of muscles/soft tissues (16), while computed tomography (CT)-guided biopsy technique is well known and refined over the past 30 years for all types of tissues (17). The purpose of this report is to describe a novel positron emission tomography (PET) and CT-guided Bergström needle technique to sample supraclavicular human BAT deposit.

METHODS

Supraclavicular BAT biopsies were obtained from healthy participants enrolled in clinical studies at the University of Texas Medical Branch at Galveston. Eligible participants underwent the supraclavicular biopsy procedure at least once. Informed written consent was obtained prior to inclusion in the studies from all participants in accordance with the Declaration of Helsinki. The Institutional Review Board and the Institute for Translational Science Scientific Review Committee at the University of Texas Medical Branch approved the experimental protocol.

After 2-6h of non-shivering cold exposure (10), a bolus injection of 185 MBq of 2-deoxy-2-[^{18}F]fluoroglucose (^{18}F -FDG) was administered to participants. Cold was used as a stimulus to activate BAT thermogenesis and ^{18}F -FDG uptake in BAT. One hour later, a PET/CT scan (General Electric Medical Systems, Milwaukee, WI) was performed to visualize supraclavicular BAT using the ^{18}F -FDG-PET/CT images (Figure 1a).

Participants were transferred to the CT procedure room (Figure 1b) and scout images of the lower neck (Figure 1c) were taken to visualize the anatomy of the supraclavicular area (General Electric Medical Systems, Milwaukee, WI). Using major anatomical landmarks, an experienced interventional radiologist (P.A.), identified the location of the supraclavicular

BAT depot in the CT images corresponding to the BAT in the PET/CT scan. Then, the skin over the area of the biopsy was thoroughly cleaned using chlorhexidine and covered with a sterile drape. A small amount (2–5 mL) of 2% lidocaine was injected in the dermis of the biopsy site and in the subcutaneous adipose tissue depot. The injection needle was advanced in the targeted adipose tissue area and an additional CT scan was performed to ensure the correct placement of the needle at the biopsy site, avoiding any adjacent superficial veins (Figure 1c). Subsequent measures were taken to determine the depth of the BAT deposit and the advancement of the biopsy needle.

Afterwards, an incision was made in the skin (<1cm) using a scalpel and a 6 mm Bergström needle (Stille, Lombard, IL) was inserted through the incision and advanced into the supraclavicular adipose tissue depot. Once the needle was positioned appropriately, a trained member of the research team applied suction using a 60 mL syringe and a suction catheter (Figure 1d). Precooled bacitracin ointment was applied to the top of the inner cannula to maintain suction and avoid leakage of air between the needle and the inner cannula. The needle was rotated 180° and the target depot was sampled. The procedure (Figure 1e) was repeated up to three times. Once the biopsy procedure was over, we applied manual compression for 3–5 min to minimize bleeding. Subsequently, the incision was closed using standard 2.0 silk sutures and a sterile dressing was applied. The duration of the BAT biopsy procedure was ~30–40 min.

The participants were instructed to avoid swimming and rigorous exercise for the first 72h after the biopsy. Further, they were instructed to inspect the wound daily, apply antibiotic ointment once or twice a day and take painkillers for discomfort as needed. The participants returned to the Clinical Research Center 5–8 days after the biopsy for suture removal. The clinical research notes and personal communication with the participants were used to evaluate the safety of the procedure and verify the incidence of adverse effects. Complications were categorized to major and minor according to the clinical practice guidelines of the Society of Interventional Radiology (17).

To establish our ability to sample the supraclavicular BAT depot using this method, we conducted the following analysis in a supraclavicular BAT and an abdominal subcutaneous white adipose tissue (WAT) sample (collected using the Bergström technique needle ~10 cm right or left from the umbilicus) using the following techniques:

- **Mitochondrial Respiration:** Adipose tissue samples were immediately submerged in a cold pH adjusted preservation buffer and transferred to the laboratory analysis. Respirometry was performed in an O2K oxygraph (Oroboros Instruments, Innsbruck, Austria). Experimental parameters used have been described elsewhere (10, 18). Briefly, BAT and WAT were weighed and suspended in the O2K chamber in 2ml of pH adjusted respiration buffer. Respiratory capacity and function were determined by the addition of substrates, inhibitors and uncouplers. Specifically, the UCP1 inhibitor GDP (30mM final concentration) was titrated into the O2K chamber to confirm the presence and quantify the function of UCP1.
- **Immunohistochemistry:** Formalin preserved adipose tissue was embedded in paraffin wax. Immunohistochemistry was performed using a standard protocol (19).

Anti-rabbit UCP1 antibody (Cat. No. U6382, Sigma-Aldrich, St Louis, MD, ABC kit and DAB kit Vector laboratories, Inc, Burlingame) were used in protocol. An Olympus microscope (BX41C) with cellSens Viewer 1.5 software (Olympus Soft Imaging Solutions GmbH, Munster, Germany) was used for slide imaging.

- **Gene expression:** RNA was extracted from adipose tissue using a pure link RNA isolation mini kit Total (Life Technologies, Carlsbad, CA). cDNA was synthesized by High-Capacity RNA-to-cDNA™ Kit (Life Technologies, Carlsbad, CA) and pre-amplified by TaqMan® PreAmp Master Mix Kit (Life Technologies, Carlsbad, CA). Quantitative real-time-PCR analyses were performed on an ABI PRISM 7900HT using the TaqMan® Gene Expression Master Mix (Life Technologies, Carlsbad, CA), pre-amplified cDNA and specific Taqman gene UCP1 expression assays (Hs00222453_m1, Life Technologies, Carlsbad, CA). GAPDH (Hs02758991_g1) was used as the housekeeping gene to normalize the expression of the target gene.

RESULTS AND DISCUSSION

The study sample consisted of 23 men, 44±3 years old, BMI 29±2 kg/m² who underwent a total of 43 supraclavicular biopsies. The vast majority of the participants tolerated the biopsy without any major complaints. On one occasion (2.3% of biopsies), the participant developed a subcutaneous hematoma, which fully resolved. On four occasions (9.6% of biopsies), the participants complained of numbness and tingling in the site of the biopsy, which resolved without further complaints.

The amount of supraclavicular BAT obtained using this PET and CT-guided needle biopsy was 100–200 mg of tissue. The amount was enough to conduct quantitative PCR, immunohistochemistry, and mitochondrial respiration analyses. Analyses conducted in one sample confirm that tissue collected had characteristics similar to animal BAT: (1) the gene expression of uncoupling protein 1 (UCP1) was 61 times higher than that of abdominal subcutaneous WAT from the same subject; (2) histology results show minimal UCP1 staining (0.99% strong positive) in the subcutaneous abdominal WAT (Figure 2a) and intense UCP1 staining (22% strong positive) in the supraclavicular BAT (Figure 2b); (3) the supraclavicular BAT samples had a higher uncoupled respiration compared to the abdominal adipose tissue in basal conditions and upon the addition of substrates (Figure 2c–d); and (4) in the supraclavicular BAT sample, O₂ consumption decreased following the addition of the UCP1 inhibitor GDP, indicating the presence of UCP1 (Figure 2c) (20).

The proposed method is of significance because it can be safely used to sample the supraclavicular BAT deposit for research purposes. The majority of previous studies that have sample the human BAT used either postmortem specimens (7, 12, 14) or samples obtained during surgeries (2, 4, 6). However, the fact the subjects sampled were either deceased or had an underlying pathological condition, may limit the generalizability of the results. Other studies conducted a limited number of open biopsies (1, 8, 9, 13). Although open biopsy techniques can also be used to biopsy human BAT, they are more invasive than the proposed technique.

To the best of our knowledge, this is the first report to describe and evaluate the safety of a minimally invasive method to routinely sample the supraclavicular human BAT depot. Our results demonstrate that the proposed method is well tolerated with only minimal risk. Further, this method yields adequate tissue for molecular and functional analysis of the tissue without damaging its morphological characteristics. Limitations of this method include its high cost, exposure to radiation, and the need for equipment and adequately trained personnel. Adaption of this method from investigators in the area of BAT research may increase the availability of human BAT specimens and accelerate the development of current scientific knowledge.

Acknowledgments

The authors want to thank the study participants and the nursing and administrative personnel at the Institute of Translational Sciences Clinical Research Center at the University of Texas Medical Branch and the Metabolism Unit, Shriners Hospital for Children, Galveston. We thank Sarah Toombs Smith of the Sealy Center on Aging, University of Texas Medical Branch, for manuscript editing; Sebastien M. Labbé for generating the PET/CT images; Nicholas M. Hurren for taking the pictures during the biopsy procedure; Rajesh Kumar of the Department of Nuclear Medicine, University of Texas Medical Branch, for performing the PET/CT scans.

Funding/financial support: This study was conducted with the support of the Institute for Translational Sciences at the University of Texas Medical Branch, supported in part by a Clinical and Translational Science Award (UL1TR000071) from the National Center for Advancing Translational Sciences, National Institutes of Health; the American Diabetes Association (1-14-TS-35 to LSS); Shriners Hospitals for Children (grants 84090 and 85310 to LSS); the John Sealy Memorial Endowment Fund for Biomedical Research (grant 66992 to LSS); Ajinomoto Co., Inc. (grant 445800 to LSS) and the Sealy Center on Aging (grant to LSS). MC is funded by the Onassis Foundation. CP is supported in part by a National Institute of Disability and Rehabilitation Research Postdoctoral Training Grant, National Institutes of Health (H133P110012).

References

1. Virtanen KA, Lidell ME, Orava J, Heglind M, Westergren R, Niemi T, et al. Functional brown adipose tissue in healthy adults. *N Engl J Med.* 2009; 360(15):1518–25. [PubMed: 19357407]
2. van Marken Lichtenbelt WD, Vanhommerig JW, Smulders NM, Drossaerts JM, Kemerink GJ, Bouvy ND, et al. Cold-activated brown adipose tissue in healthy men. *N Engl J Med.* 2009; 360(15):1500–8. [PubMed: 19357405]
3. Nedergaard J, Bengtsson T, Cannon B. Unexpected evidence for active brown adipose tissue in adult humans. *American journal of physiology Endocrinology and metabolism.* 2007; 293(2):E444–52. [PubMed: 17473055]
4. Cypess AM, Lehman S, Williams G, Tal I, Rodman D, Goldfine AB, et al. Identification and importance of brown adipose tissue in adult humans. *N Engl J Med.* 2009; 360(15):1509–17. [PubMed: 19357406]
5. Sidossis L, Kajimura S. Brown and beige fat in humans: thermogenic adipocytes that control energy and glucose homeostasis. *J Clin Invest.* 2015; 125(2):478–86. [PubMed: 25642708]
6. Cypess AM, White AP, Vernochet C, Schulz TJ, Xue R, Sass CA, et al. Anatomical localization, gene expression profiling and functional characterization of adult human neck brown fat. *Nat Med.* 2013; 19(5):635–9. [PubMed: 23603815]
7. Sharp LZ, Shinoda K, Ohno H, Scheel DW, Tomoda E, Ruiz L, et al. Human BAT possesses molecular signatures that resemble beige/brite cells. *PloS one.* 2012; 7(11):e49452. [PubMed: 23166672]
8. Lee P, Greenfield JR, Ho KK, Fulham MJ. A critical appraisal of the prevalence and metabolic significance of brown adipose tissue in adult humans. *American journal of physiology Endocrinology and metabolism.* 2010; 299(4):E601–6. [PubMed: 20606075]
9. Orava J, Nuutila P, Lidell ME, Oikonen V, Noponen T, Viljanen T, et al. Different metabolic responses of human brown adipose tissue to activation by cold and insulin. *Cell metabolism.* 2011; 14(2):272–9. [PubMed: 21803297]

10. Chondronikola M, Volpi E, Borsheim E, Porter C, Annamalai P, Enerback S, et al. Brown adipose tissue improves whole-body glucose homeostasis and insulin sensitivity in humans. *Diabetes*. 2014; 63(12):4089–99. [PubMed: 25056438]
11. Wu J, Bostrom P, Sparks LM, Ye L, Choi JH, Giang AH, et al. Beige adipocytes are a distinct type of thermogenic fat cell in mouse and human. *Cell*. 2012; 150(2):366–76. [PubMed: 22796012]
12. Hu HH, Tovar JP, Pavlova Z, Smith ML, Gilsanz V. Unequivocal identification of brown adipose tissue in a human infant. *J Magn Reson Imaging*. 2012; 35(4):938–42. [PubMed: 22180228]
13. Lee P, Zhao JT, Swarbrick MM, Gracie G, Bova R, Greenfield JR, et al. High prevalence of brown adipose tissue in adult humans. *J Clin Endocrinol Metab*. 2011; 96(8):2450–5. [PubMed: 21613352]
14. Lidell ME, Betz MJ, Dahlqvist Leinhard O, Heglund M, Elander L, Slawik M, et al. Evidence for two types of brown adipose tissue in humans. *Nat Med*. 2013; 19(5):631–4. [PubMed: 23603813]
15. Shinoda K, Luijten IH, Hasegawa Y, Hong H, Sonne SB, Kim M, et al. Genetic and functional characterization of clonally derived adult human brown adipocytes. *Nat Med*. 2015
16. Tarnopolsky MA, Pearce E, Smith K, Lach B. Suction-modified Bergstrom muscle biopsy technique: experience with 13,500 procedures. *Muscle Nerve*. 2011; 43(5):717–25. [PubMed: 21462204]
17. Gupta S, Wallace MJ, Cardella JF, Kundu S, Miller DL, Rose SC. Quality improvement guidelines for percutaneous needle biopsy. *J Vasc Interv Radiol*. 2010; 21(7):969–75. [PubMed: 20304676]
18. Porter C, Reidy PT, Bhattarai N, Sidossis LS, Rasmussen BB. Resistance Exercise Training Alters Mitochondrial Function in Human Skeletal Muscle. *Med Sci Sports Exerc*. 2014
19. Cox RA, Mlcak RP, Chinkes DL, Jacob S, Enkhbaatar P, Jaso J, et al. Upper airway mucus deposition in lung tissue of burn trauma victims. *Shock*. 2008; 29(3):356–61. [PubMed: 17693942]
20. Nicholls DG. Hamster brown-adipose-tissue mitochondria. The control of respiration and the proton electrochemical potential gradient by possible physiological effectors of the proton conductance of the inner membrane. *Eur J Biochem*. 1974; 49(3):573–83. [PubMed: 4442425]

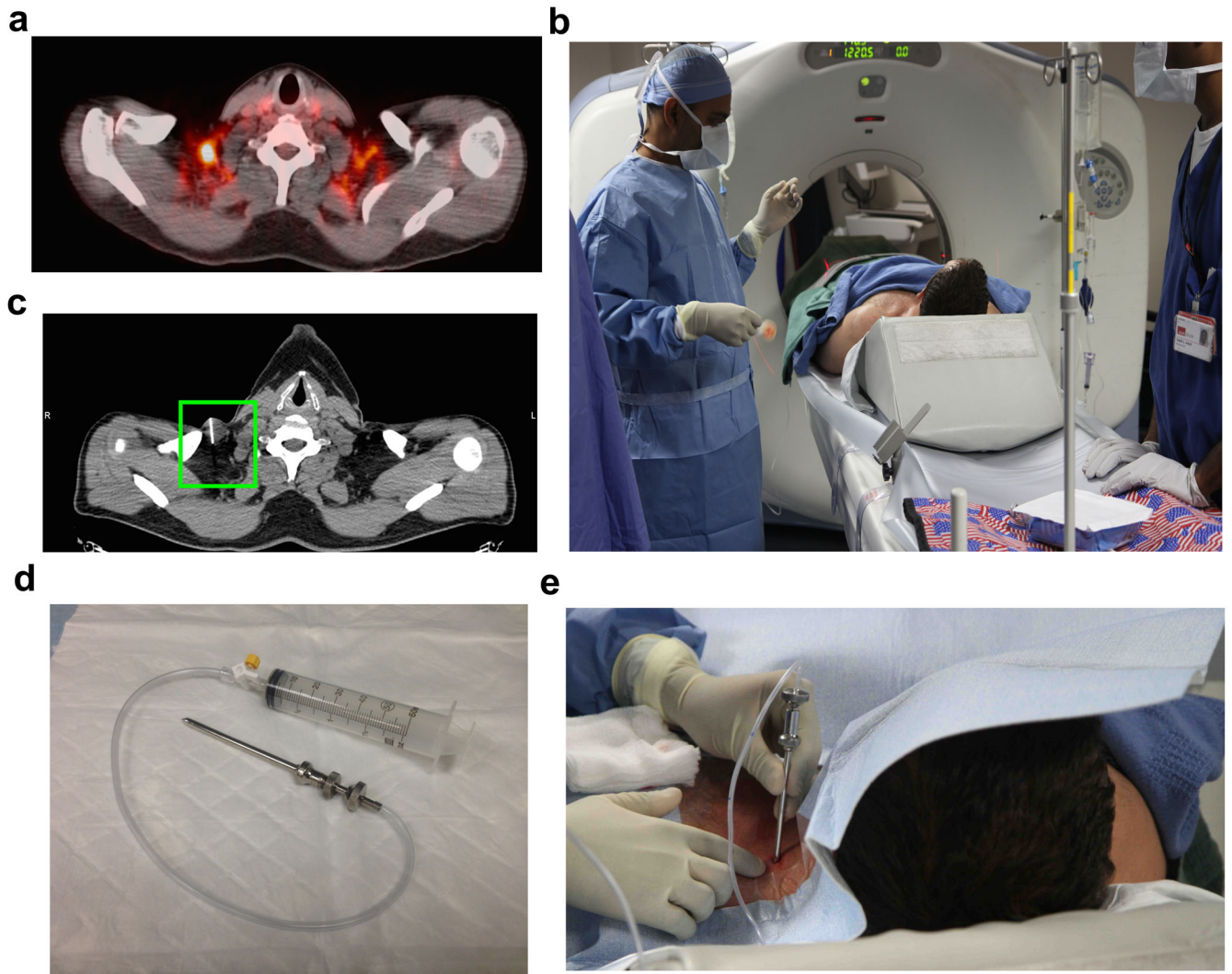


Figure 1. Biopsy procedure

(a) 2-deoxy-2-[18F]fluoro-D-glucose (18F-FDG)- Positron Emission Tomography/Computed Tomography image from a study participant. The intense orange color corresponds to metabolically active brown adipose tissue. (b) The study participant lying on the table of the computed tomography (CT) procedure room. (c) CT scout image corresponding to the supraclavicular area after the insertion of the injection needle to ensure its placement. (d) Tubing attached to the 6 mm Bergstrom needle and BD syringe to generate suction. (e) The study physician (P.A.) during the biopsy procedure. For Figures 1a and b informed consent to publish was obtained from the study participant.

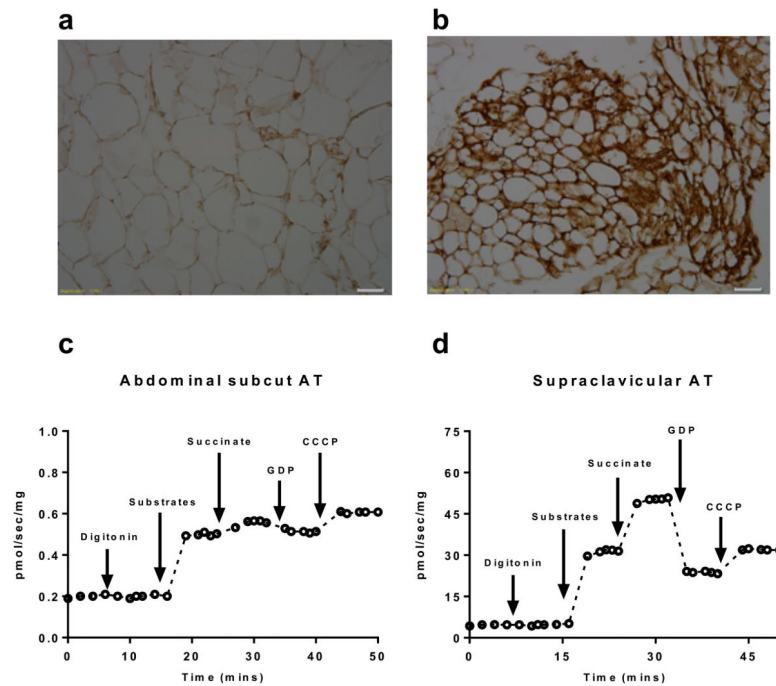


Figure 2. Molecular and functional data supporting the sampling of supraclavicular BAT deposit using the PET/CT guided needle biopsy method

(a–b) Uncoupling protein 1 (UCP1) staining (20x) in a abdominal subcutaneous (a) and supraclavicular adipose (b) tissue sample, demonstrating typical characteristic of brown adipose tissue (i.e. intense UCP1 staining and multi-locular cells) in supraclavicular adipose tissue. (c–d) Stages of mitochondrial respiration in an abdominal subcutaneous (c) and supraclavicular adipose (d) tissue sample, indicating a higher uncoupled respiration rate compared to the abdominal adipose tissue in basal conditions and upon the addition of oxidative substrates. GDP: Guanosine diphosphate, CCCP: Carbonyl cyanide m-chlorophenyl hydrazine.