



# Hemiatrophy of the Tongue with Contralateral Hemiparesis in a Patient with Multifocal Acquired Demyelinating Sensory and Motor Neuropathy

Susumu Ikenoshita\*  
Satoshi Yamashita\*  
Tetsuro Sakamoto  
Yohei Misumi  
Yukio Ando

Department of Neurology,  
Graduate School of Medical Sciences,  
Kumamoto University,  
Kumamoto, Japan

Dear Editor,

Multifocal acquired demyelinating sensory and motor neuropathy (MADSAM), also referred to as Lewis-Sumner syndrome, is an atypical form of chronic inflammatory demyelinating polyradiculoneuropathy (CIDP).<sup>1</sup> Cranial nerves are involved in some MADSAM cases. We report a case of a patient with MADSAM who showed hemiatrophy of the tongue with contralateral hemiparesis.

A 55-year-old Japanese man with consanguinity complained of difficulty in raising the right arm. A neurological examination revealed left-side hemiatrophy of the tongue with fasciculation (Fig. 1A). Muscle wasting was observed in the neck flexor, right upper limb, and thigh. Muscle weakness was prominent in the right proximal upper limb and iliopsoas muscles. Temperature, pain, and vibration sensations were disturbed in the lower limbs below the knees. Reflexes were absent in the upper limbs and decreased in the lower limbs. The Romberg sign was positive. Blood examinations revealed slight elevation of creatine kinase (175 IU/L). Cervical and lumbar MRI showed remarkable enlargement of the bilateral nerve roots (Fig. 1B, C). Brain MRI revealed no abnormal lesion on the medulla oblongata (Fig. 1D). A nerve conduction study produced segmental demyelination findings, including motor conduction blocks and temporal dispersion in the right median, ulnar, tibial, peroneal, and sural nerves (Fig. 1E) (Supplementary Table 1 in the online-only Data Supplement), which were consistent with the electrodiagnostic criteria for CIDP. CSF protein was elevated, at 63.2 mg/dL. Molecular genetic testing for the *androgen receptor* gene, *peripheral myelin protein 22* gene, and Charcot-Marie-Tooth-disease-related genes revealed no mutations. The patient was negative for antiganglioside antibodies including anti-GM1 antibody. He was diagnosed as MADSAM based on the electrodiagnostic criteria for CIDP, and then treated with corticosteroid and cyclosporine. However, both the muscle weakness and wasting gradually progressed. Administration of intravenous immunoglobulin was repeated every 3 months, and the manifestations remained limited to the left tongue and the right upper and lower limbs for 8 years after the initial presentation, although the nerve conduction study demonstrated involvement of the bilateral upper limbs (Supplementary Table 2 in the online-only Data Supplement).

Cranial nerves can be involved in ~15% of patients with MADSAM.<sup>2</sup> However, involvement of the hypoglossal nerve is comparatively rare, with hypoglossal neuropathies reported in only several cases of MADSAM.<sup>2-4</sup> A case report demonstrated hypoglossal neuropathy in a patient masquerading as motor neuron disease.<sup>4</sup> Inconsistent with that case, the symptoms in the present case were localized to hemiatrophy of the tongue and contralateral hemiparesis with generalized hyporeflexia. Déjérine's syndrome is a medial medullary infarction determined by lesions restricted to the anterior portion of the medial hemimedulla,

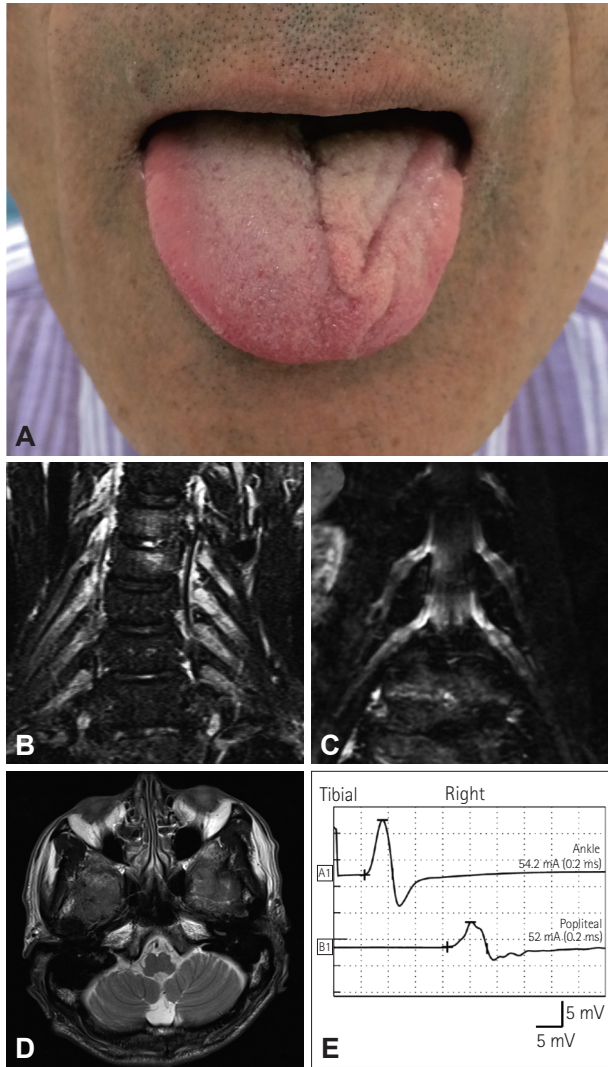
**Received** November 12, 2016  
**Revised** February 10, 2017  
**Accepted** February 13, 2017

## Correspondence

Satoshi Yamashita, MD, PhD  
Department of Neurology,  
Graduate School of Medical Sciences,  
Kumamoto University,  
1-1-1 Honjo, Kumamoto 860-8556,  
Japan  
**Tel** +81-96-373-5893  
**Fax** +81-96-373-5895  
**E-mail** y-stsh@kumamoto-u.ac.jp

\*These authors contributed equally to this work.

© This is an Open Access article distributed under the terms of the Creative Commons Attribution Non-Commercial License (<http://creativecommons.org/licenses/by-nc/4.0>) which permits unrestricted non-commercial use, distribution, and reproduction in any medium, provided the original work is properly cited.



**Fig. 1.** Clinical data of the patient with MADSAM. A: Left-side hemiatrophy of the tongue with fasciculation. B and C: Coronal T2-weighted MRI images of the cervical (B) and lumbar (C) roots. D: Axial T2-weighted MRI image of the brain. E: Findings of a nerve conduction study of the right tibial nerve.

and is characterized by hypoglossal nerve palsy and contralateral hemiparesis associated with hyperreflexia.<sup>5</sup> The present case indicates that hemiatrophy of the tongue with contralateral hemiparesis mimicking Déjerine's syndrome can be an atypical manifestation associated with MADSAM.

### Supplementary Materials

The online-only Data Supplement is available with this article at <https://doi.org/10.3988/jcn.2017.13.4.422>.

### Conflicts of Interest

The authors have no financial conflicts of interest.

### Acknowledgements

This work was supported by a Grant-in-Aid for Scientific Research (no. 24591269) from the Japan Society for the Promotion of Science (JSPS) and a Grant-in-Aid for Research on Intractable Diseases from the Ministry of Health, Labour and Welfare of Japan.

### REFERENCES

1. Sander HW, Latov N. Research criteria for defining patients with CIDP. *Neurology* 2003;60(8 Suppl 3):S8-S15.
2. Verschueren A, Azulay JP, Attarian S, Boucraut J, Pellissier JF, Pouget J. Lewis-Sumner syndrome and multifocal motor neuropathy. *Muscle Nerve* 2005;31:88-94.
3. Jeanjean AP, Duprez T, Van den Bergh PY. Massive peripheral nerve hypertrophy in a patient with multifocal upper limb demyelinating neuropathy (Lewis-Sumner syndrome). *Acta Neurol Belg* 2001;101:234-238.
4. Weiss MD, Oakley JC, Meekins GD. Hypoglossal neuropathy in Lewis-Sumner syndrome masquerading as motor neuron disease. *Neurology* 2006;67:175-176.
5. Pergami P, Poloni TE, Imbesi F, Ceroni M, Simonetti F. Déjerine's syndrome or Spiller's syndrome? *Neurol Sci* 2001;22:333-336.